Journal of Microscopy and Ultrastructure 2 (2014) 245–250

Contents lists available at ScienceDirect

Journal of Microscopy and Ultrastructure

journal homepage: www.elsevier.com/locate/jmau

Original Article

A comparative study of the histology and microanatomy of the stomach in *Mystus vittatus* (Bloch), *Liza parsia* (Hamilton) and *Oreochromis mossambicus* (Peters)

Padmanabha Chakrabarti*, Saroj Kumar Ghosh

Fisheries Laboratory, Department of Zoology, The University of Burdwan, Burdwan 713 104, West Bengal, India

ARTICLE INFO

Article history:
Received 7 May 2014
Received in revised form 8 July 2014
Accepted 15 July 2014
Available online 29 July 2014

Keywords:
Microarchitecture
Stomach
Mystus vittatus
Liza parsia
Oreochromis mossambicus

ABSTRACT

Histological and topological architectures in the mucosal epithelium of the stomach of *Mystus vittatus*, *Liza parsia* and *Oreochromis mossambicus* were studied. The mucosa of the sac like stomach of *M. vittatus* was made up of superficial epithelium and gastric epithelium. The superficial epithelium was made up of single layer of columnar epithelial cells while the gastric epithelium was composed of gastric glands. In *L. parsia* the mucosal epithelium of the gizzard like stomach consisted of single layer of columnar epithelial cells but gastric glands were totally absent. The caecal like stomach of *O. mossambicus* was made up of superficial columnar epithelial cells and tubular gastric glands. The topological characteristics of the entire mucosa of the stomach of *M. vittatus*, *L. parsia* and *O. mossambicus* were provided with mucosal folds forming empty concavities. However, the concavities were comparatively deeper in *O. mossambicus*. The mucosal surface of stomach also typified with columnar epithelial cells whose apical surfaces were provided with short and stubby microridges in *M. vittatus* and *L. parsia* while in *O. mossambicus* the microridges were fine and delicate. Physiological functions of the stomach of aforesaid fishes were discussed.

1. Introduction

The alimentary canal of fish is well developed and structurally adapted to accommodate a wide variety of diets. In fact, each fish species has its own structural peculiarities to the alimentary canal specially stomach towards its specific food habits which vary greatly in regard to the percentage of animal and plant food materials [1]. The stomach is absent in some teleosts [2,3] or modified as intestinal bulb [4,5]. Among large number of species, though the stomach is also defined as actual organ, consists of anterior cardiac region with gastric glands and posterior pyloric region without gastric glands [6–8]. Morphohistology of stomach of Indian freshwater teleosts has received considerable attention of many workers. Fish gastric histology is generally simpler than that of higher vertebrates in that the gastric glands contain only one cell type that secrete both pepsinogen and hydrochloric acid [9,10]. However, the information for the histophysiological features of the gastric epithelium and glands are sparse and incomplete. There is also lack of information about the role of fish stomach in digestion of animal and plant food materials except the works of Pasha [11] and Schmitz and Baker [12]. However, lacunae still remain relating to the precise digestive function of stomach of different Indian freshwater fishes having diverse feeding habits. The microarchitecture of stomach involving electron microscopical studies has rarely been done in Indian teleosts although Sinha and Chakrabarti

* Corresponding author. Tel.: +91 342 2634798; fax: +91 342 2657938.
E-mail address: dr.pchakrabarti@yahoo.in (P. Chakrabarti).

http://dx.doi.org/10.1016/j.jmau.2014.07.003
2213-879X/

[13], Chakrabarti and Sinha [14], Chakrabarti et al. [15], Carrasson et al. [16], Haloi et al. [17] made valuable contributions regarding the microanatomy of stomach.

Therefore, it would be naturally worthwhile to examine more closely the functional aspects involved in histological and microanatomical studies of the stomach of three Indian important food fishes, *Mystus vittatus* (Siluriformes, Bagridae), *Liza parsia* (Mugiliformes, Mugilidae) and *Oreochromis mossambicus* (Perciformes, Cichlidae) having different feeding habits. This study would help to get information regarding the precise cellular structure of various cells lining the stomach of Indian freshwater teleosts.

2. Materials and methods

Mature specimens of *M. vittatus* (10–11 cm in total length) and *O. mossambicus* (13–15 cm in total length) were obtained from the local freshwater body of Burdwan and *L. parsia* (15–17 cm in total length) were collected from Junput brackish water fish farm, Purba Midnapore, West Bengal, India. The fishes were anaesthetized with tricaine methanesulfonate (MS 222; Sigma Chemical Co.) solution (100 mg L^{-1}) and sacrificed following the guidelines given by the Institutional Ethical Committee. Stomach of aforesaid fishes were removed after dissection and immediately processed for the histological and scanning electron microscopical studies.

2.1. Histological study

The stomach portion was cut into small pieces and fixed in aqueous Bouin's fluid for 16–18 h. After fixation the tissues were washed repeatedly in 70% ethanol and dehydrated properly through ascending series of ethanol. Then the tissues were cleared with xylene and embedded in paraffin wax at 56–58 °C under a thermostat vacuum paraffin-embedding bath for a period of 1 h and 30 min. Sections were cut at 4 μm thick using a rotary microtome (Weswox). After routine histological procedure deparaffinized sections were stained in Delafield's haematoxylin–eosin (HE) and Mallory's triple (MT) stain. Staining slides were examined and photographed under Olympus-Tokyo PM-6 compound microscope.

2.2. Scanning electron microscopic (SEM) study

For scanning electron microscopy, the stomach of each fish species was incised longitudinally to expose the luminal surface, spread out and pinned with mucosal surface uppermost on the cork sheets. After rinsing them in heparinised saline (heparin sodium salt 10,000 IU dissolved in 0.67% NaCl solution) and 1% Tween 40 mixture to remove excess mucus, the tissues were washed in 0.2 M phosphate buffer. The tissues were then fixed in 2.5% glutaraldehyde in 0.2 M phosphate buffer (pH 7.3) and kept for 24–27 h at 4 °C. After fixation, the tissues were removed, rinsed in 0.2 M phosphate buffer, trimmed into 8–10 mm squares and post fixed for 2 h in 1% osmium tetroxide in 0.2 M phosphate buffer (pH 7.3). The tissues were then dehydrated using ascending series of acetone, followed by isoamyl acetate and dried with critical point drier (Hitachi 8CP2). The serosal surface of each tissue was mounted on metal stubs, coated with gold palladium by vacuum gold coater. The tissues were examined under Hitachi S-530 scanning electron microscope.

3. Results

3.1. Mystus vittatus

The stomach of *M. vittatus* is a U-shaped structure, can be divided into anterior cardiac and posterior pyloric portions. Histologically, the mucosal lining of the cardiac stomach is made up of a single layer of columnar epithelial cells with centrally placed nuclei and large number of gastric glands (Fig. 1A and B). The gastric glands are supported by connective tissue network, the tunica propria. The gastric cells are provided with zymogen granules stained with eosin. The crypts or faveculae projected from mucosal layer and are closely applied to the gastric glands (Fig. 1A).

Under SEM observation the luminal surface of the gastric mucosa has irregularly arranged mucosal folds enclosing zigzag pattern of concavities in between them (Fig. 1C). It is typified by the presence of the oval or elongated elevations corresponding to the apical surfaces of the columnar epithelial cells (Fig. 1D) which are densely packed with short and stubby microridges. Occasional gastric pits have been detected on to the mucosal surface and probably these are the openings of the so-called gastric glands (Fig. 1C and D).

3.2. Liza parsia

A true stomach is absent in *L. parsia* and in its place is present greatly thickened gizzard like stomach for trituration of food. Histologically, the mucosa of stomach is thrown into longitudinal folds forming numerous narrow and elongated villi (Fig. 2A). The gastric mucosa is lined with single layer of compactly arranged columnar epithelial cells which are almost equal in size with oval or rounded nuclei. The free border of epithelial cells secretes mucus substances (Fig. 2A). Gastric glands are absent in the gastric epithelium. The tunica propria is made up of connective tissue network traversed by blood vessels (Fig. 2B).

Under SEM the mucosal surface of stomach is provided with major folds which amalgamate with each other to form deep, empty concavities (Fig. 2C). The mucosal surface of this region is divided into oval and/or round elevation corresponding to the surfaces of columnar epithelial cells (Fig. 2D) which are densely packed with big but stubby microridges. Mucin substances and droplets are also found to be adhered to the epithelial surface.

3.3. Oreochromis mossambicus

The stomach of *O. mossambicus* is of caecal type. Corpus and pyloric parts are well differentiated with regard to histological details. Histologically, the mucosa is made up of two types of epithelium-superficial and glandular epithelium. The superficial epithelium is composed of compactly arranged columnar epithelial cells. The nuclei are oval in shape and are situated in the basal half of the cells (Fig. 3A).

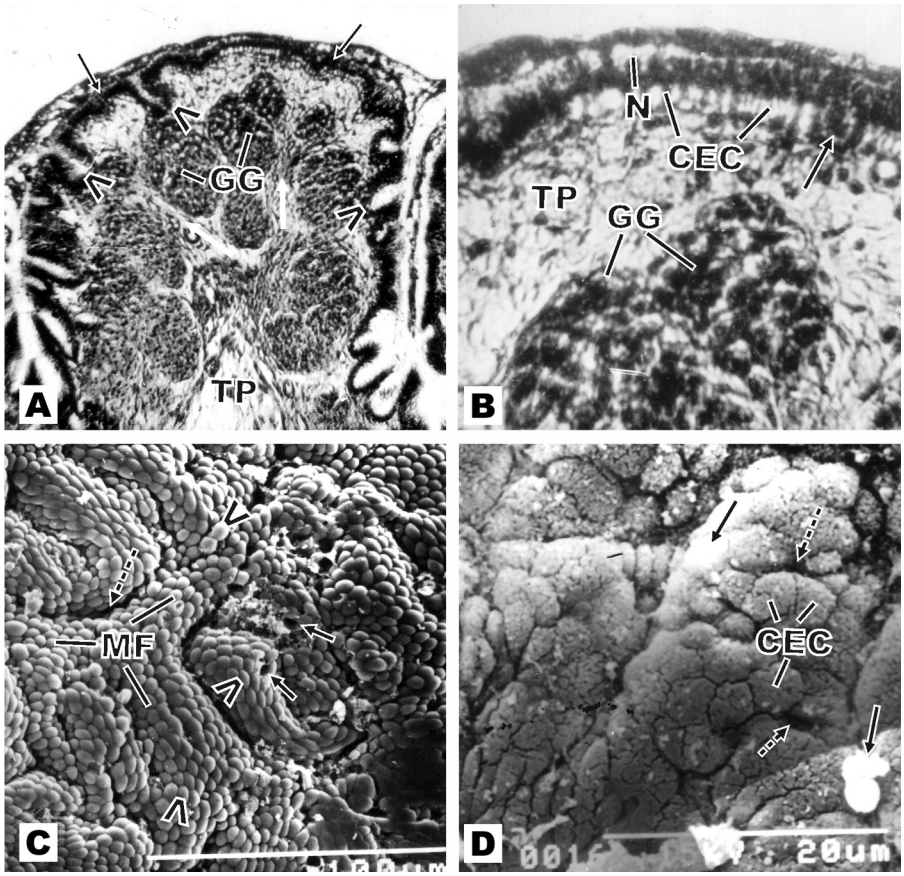

Fig. 1. Light and scanning electron microscopic (SEM) photographs of stomach of *M. vittatus*. (A) Section of stomach showing single layer of columnar epithelial cells (CEC) (solid arrows) and gastric glands (GG) with prominent zymogen granules (ZG). GG separated by connective tissue of tunica propria (TP) (broken arrows). Note crypts of mucous layer (arrow heads) adjacent to GG; Delafield's haematoxylin–Eosin (HE) 400×. (B) Showing single layer of CEC with centrally placed nuclei (N). Note the presence of GG with ZG which are supported by connective tissue of TP. Arrow indicates crypts leading to GG; (HE) 1000×. (C) Showing irregular arranged mucosal folds (MF) and narrow concavities (broken arrow) in between them. Note prominent gastric pits (GP) (solid arrows) encircled by rosette of CEC (arrow heads); (SEM) 100×. (D) Showing oval or rounded CEC provided with short and stubby microridges. Broken arrows indicate GP encircled by CEC. Note mucin mass (solid arrows) over CEC; (SEM) 400×.

The glandular epithelium consists of tubular gastric glands provided with rhomboidal shape of cells with spherical nucleus in each cell (Fig. 3B). Each gland is surrounded by a thin layer of tunica propria. There are no gastric glands in pyloric region.

Under SEM observation the mucosal surface of stomach is provided with major folds leaving empty and longitudinal concavities between them (Fig. 3C). The internal mucosa of the stomach exhibits densely packed oval or rounded columnar epithelial cells. Few gastric pits surrounded by the epithelial cells have also been detected in this region (Fig. 3C). The mucosal epithelial surface of stomach at higher magnification exhibits densely packed fine microridges encircling gastric pits (Fig. 3D).

4. Discussion

The alimentary canal of fish is well developed and structurally adapted to accommodate a wide variety of diets. In the present study a comparative account of the stomach of three fishes has revealed many variations that are undoubtedly correlated with differences in their food habits. In *M. vittatus* the stomach is U-shaped while muscular bulb is present in *L. parsia* and this muscular gizzard appears to be an adaptation for its diet. On the other hand *O. mossambicus* being an herbivorous feeder, the lining of the stomach is comparatively thin for retention of food materials for effective acid hydrolysis and so the stomach is caecal type. According to Al-Hussaini [18], the size of the stomach is influenced by two factors, the duration of intervals between the meals and the nature of the food ingested. In his opinion, fishes that feed at short intervals have large elastic stomach capable of great distension. However, in the present investigation in *M. vittatus* the stomach is sac like which feeds on small crustaceans, insect's larvae, oligochates, etc. that requires limited space to accommodate the ingested food item. Fishes living on coarse food of plant and sand or mud have gizzard like stomach provided with tough mucosal folds and helps in the trituration of food. In *L. parsia* the stomach is gizzard like and such gizzard like stomach was also reported in *Gadusia chapra* by Kapoor [19], *Hilsa ilisha* and *Mugil cephalus* by Khanna [20] which do not have a well formed pharyngeal masticatory apparatus. In the present histological study it has been observed

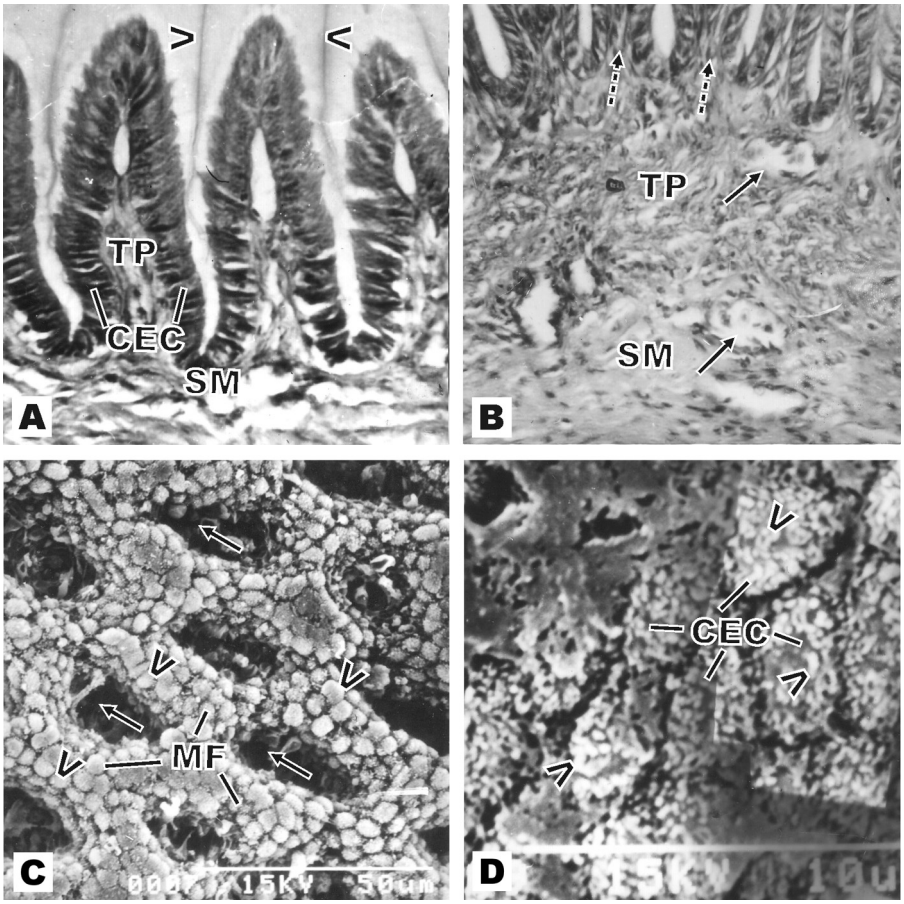

Fig. 2. Light and scanning electron microscopic (SEM) photographs of stomach of *L. parsia*. (A) Section of stomach showing elongated mucosal folds. Mucosal epithelium is made up of single layer of CEC with prominent nuclei. Note threads of mucin (arrow heads) secreted by the CEC. SM indicates submucosa from which connective tissue extend as tunica propria; (HE) 400×. (B) Showing no gastric gland (GG) in TP. Broken arrows indicate bases of mucosal villi. Note the presence of blood vessels (BV) (solid arrows) in TP and SM; Mallory's triple (MT) 400×. (C) Mucosal surface of the stomach showing mucosal folds (MF) which anastomose to form deep, empty concavities (solid arrows). Note prominent CEC (arrow heads) on the MF; (SEM) 150×. (D) Higher magnification of stomach showing oval or elongated CEC provided with big and stubby microridges (arrow heads); (SEM) 1000×.

that the gastric mucosa of all the three species consists of a superficial layer of columnar epithelium. These columnar epithelial cells are believed to contribute mucus and thus protect the surface of the stomach from the mechanical injury. The mucoid nature of columnar cells has also been demonstrated by Kapoor [19] and Pasha [11,21,22].

Under SEM study the complicated arrangement of mucosal folds in the stomach of *M. vittatus* would probably allow great distension to accommodate the ingested food for digestive activity. However, the most striking feature of the luminal surface of the epithelial cells of stomach is the presence of short and stubby microridges justifying its poor or no role in absorption process. On contrary, secretion of mucus by the epithelial cells which coating the microridges of the same may offer protective devices for preventing any chemical injury and autodigestion of the stomach wall. The anchorage of mucus film by microridges of the columnar epithelial cells of the stomach also advocated by Sinha et al. [23], Chakrabarti et al. [15] and Mandal and Chakrabarti [24]. Presence of gastric pits from the gastric glands, whose secretion is poured on the luminal surface of the stomach, suggests their role in the process of digestion. The well-developed mucosal folds in the stomach of *L. parsia* maintain a mechanical support to masticate all the food particles which the fish ingests. These highly developed mucosal folds in the gizzard like stomach in *L. parsia* is probably due to the presence of weak pharyngeal masticatory apparatus. In *L. parsia* this type of mucosal arrangement is a unique adaptational feature meant mainly for trituration of coarse plant food materials. However, the most striking feature of the luminal surface of the epithelial cells of the stomach is the presence of coarse stubby microridges which hold mucin film over gastric mucosa to protect the underlying epithelial mucosa from mechanical rubbing during trituration of food. Mehrotra and Khanna [1] have observed that the gizzard like stomach is present only in fishes which do not have a pharyngeal masticatory apparatus. They have further suggested that a highly developed musculature of the stomach is related to the need for efficient trituration.

In bony fishes both hydrochloric acid and pepsinogen are assumed to be secreted by the same gastric cells, consist of granular endoplasmic reticulum, an elaborate Golgi apparatus and zymogen like granules [10,1]. In *M. vittatus*

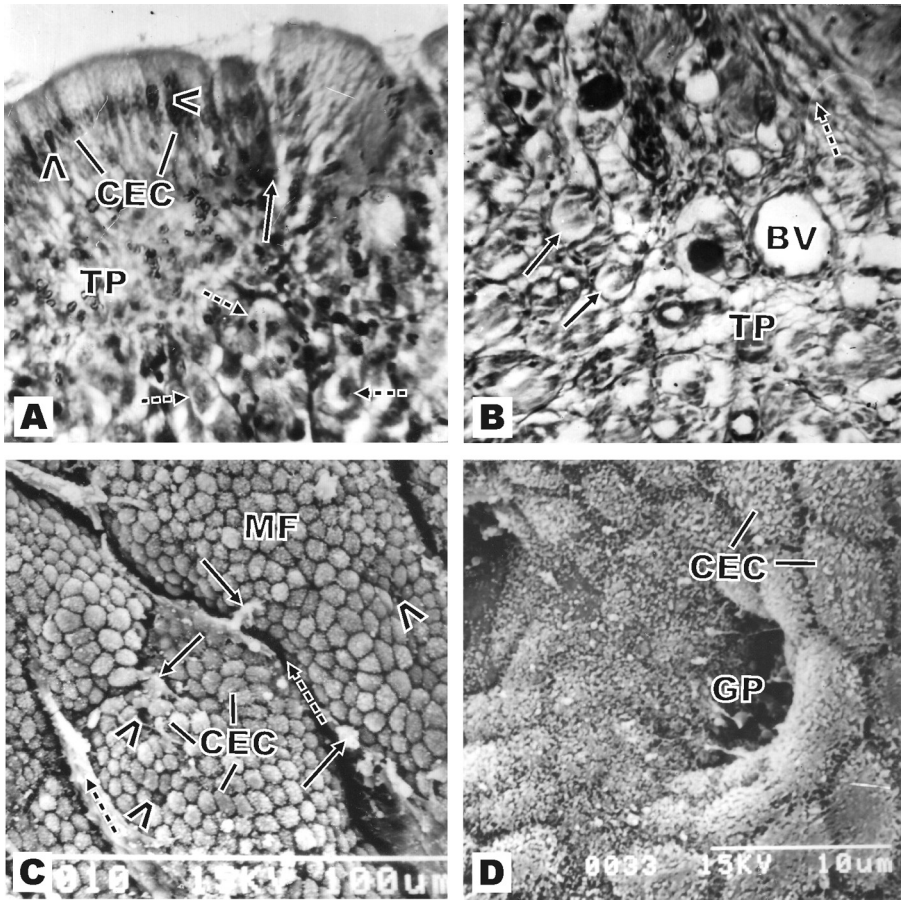

Fig. 3. Light and scanning electron microscopic (SEM) photographs of stomach of *O. mossambicus*. (A) Cardiac stomach showing superficial epithelium with single layer of CEC having prominent nuclei (arrow heads). Note narrow crypt in between mucosal epithelium (solid arrow). Note also gastric glands with prominent nuclei (broken arrows) in the gastric epithelium which are supported by tunica propria (TP); (HE) 400×. (B) Showing rhomboidal shape of gastric glands (solid arrows) at the base of mucosal villi (broken arrow). Note BV in TP; (MT) 400×. (C) Mucosal surface of cardiac stomach showing prominent mucosal folds (MF) leaving deep concavities in between (broken arrows). Note prominent gastric pits (arrow heads) surrounded by prominent CEC. Solid arrows indicate secreted mucin from CEC; (SEM) 150×. (D) Higher magnification of the mucosal surface of the stomach showing prominent CEC encircling the gastric pit (GP). Note fine and densely packed microridges over CEC; (SEM) 3000×.

the glandular cells of the stomach contain zymogen granules. On the contrary, glandular cells of *O. mossambicus* do not contain any ergastic substance or zymogen granules but they possess distinct cells in the gastric glands. This suggests that the stomach of *O. mossambicus* lacks the capacity to secrete peptic juice but the glandular cells have the capacity to secrete hydrochloric acid. Gargiulo et al. [25] noticed that glandular cells of tilapia stomach do not contain any granules, the presence of an extremely well developed tubular network of smooth membranes in the apical region of the cells and a great number of mitochondria being the most notable ultrastructural features. Several authors opined that in the initial stages of digestion in *Tilapia nilotica* and *Tilapia mossambica* require an acidic environment for acid lysis and digestion of algae and detrital bacteria in fishes that are lacking particular adaptations for trituration [26–29].

In *L. parsia* gastric glands are absent which do not have any role of gastric digestion. In the stomach of *O. mossambicus*, the deep concavities formed by the anastomosis of the major mucosal folds serve for the temporary retention of ingested food for considerable period of time. Presence of gastric pits whose secretion is poured on the lumen of the stomach suggests the positive role for effective breakdown of algal wall by secretion of acids and thereby helps in the process of digestion. The mucosal surface of the stomach in *O. mossambicus* is lined with densely packed oval or rounded columnar epithelial cells provided with fine microridges. The secretion of mucus by the epithelial cells coating the microridges of the same offers protective devices for preventing strong acid injury of the mucosal epithelial layer of stomach.

5. Conclusion

The sac like stomach of *M. vittatus* is thick walled and characterized with complicated inner mucosal folds, possibly confess considerable enlargement to furnish the captured food for temporary retention and effective digestion. In *L. parsia*, the stomach is reduced in size but is greatly thickened to become gizzard like for trituration of food along with mud and sand particles. The caecal like

stomach of algal feeder *O. mossambicus* is embossed with deep concavities of mucosal folds for temporary retention of food for effective hydrolysis of algal food materials. The gastric mucosa of all the aforesaid three fishes consists of superficial layer of columnar epithelial cells which secretes copious amount of mucus for easy lubrication of food materials and also protects the gastric epithelium against acid secretion. On contrary, gastric glands in the sub-epithelial portion of cardiac stomach in *M. vittatus* help in digestion of animal food substances.

Conflict of interest

The authors declare that there is no conflict of interest.

Acknowledgements

The authors are delightful to Dr. A. Basu, Head of the Department of Zoology, The University of Burdwan, Burdwan for necessary laboratory facilities and are thankful to Dr. S. Chakraborty, The Scientist-in-charge of the University Science Instrumentation Centre, The University of Burdwan, for his technical support in SEM analysis.

References

[1] Mehrotra DK, Khanna SS. Histomorphology of the oesophagus and the stomach in some Indian teleosts with inference on their adaptational features. Zool Beitraege Berl 1969;15:375–91.
[2] Steffens W. Principles of fish nutrition. New York: John Wiley and Sons; 1989.
[3] Grau A, Crespo S, Sarasquete MC, Gonzalez de Canales ML. The digestive tract of the amberjack *Seriola dumerili*, Risso: a light and scanning electron microscope study. J Fish Biol 1992;41:287–303, http://dx.doi.org/10.1111/j.1095-8649.1992.tb02658.x.
[4] Sinha BM, Moitra SK. Morpho-histology of the intestine in a freshwater major carp, *Cirrhinus mrigala* (Ham.) during the different life-history stages in relation to food and feeding habits. Anat Anz 1974;137:395–407.
[5] Chaves PTC, Vazzoler C. Aspectos biológicos de peixes amazônicos III anatomia microscópica do esôfago, estômago e cecos pilóricos de *Semaprochilodus insignia* (Characiformes, Prochilodontidae). Acta Amaz 1984;14:343–53.
[6] Yadav AN, Singh BR. The gut of an intestinal air-breathing fish, *Lepidocephalus guntea* (Ham.). Arch Biol 1980;91:413–22.
[7] Martin TJ, Blaber SJM. Morphology and histology of the alimentary tracts of Ambassidae (Cuvier) (Teleostei) in relation to feeding. J Morphol 1984;182:295–305, http://dx.doi.org/10.1002/jmor.1051820305.
[8] Murray HM, Wright GM, Goff GP. A comparative histological and histochemical study of the stomach from three species of pleuronectid, the Atlantic halibut, *Hippoglossus hippoglossus*, the yellowtail flounder, *Pleuronectes ferruginea*, and the winter flounder, *Pleuronectes americanus*. Can J Zool 1994;72:1199–210, http://dx.doi.org/10.1139/z94-161.
[9] Reifel CW, Travill AA. Structure and carbohydrate histochemistry of the stomach in eight species of teleosts. J Morphol 1978;158:155–67, http://dx.doi.org/10.1002/jmor.1051580203.
[10] Rebolledo IM, Vial JD. Fine structure of the oxynticopeptic cells in the gastric glands of an elasmobranch species (*Halaerurus chilensis*). Anat Rec 1979;193:805–21, http://dx.doi.org/10.1002/ar.1091930405.
[11] Pasha Kamal SM. Anatomy and histology of the alimentary canal of a herbivorous fish, *Tilapia mossambica*. Proc Ind Acad Sci 1964;59B:340–9, http://dx.doi.org/10.1007/BF03051972.
[12] Schmitz EH, Baker DC. Digestive anatomy of the gizzard shad, *Dorosoma cepedianum* and the threadfin shad, *D. petenense*. Trans Am Microsc Soc 1969;88:525–46.
[13] Sinha GM, Chakrabarti P. On topological characteristics of the mucosal surface in buccopharynx and intestine of an Indian freshwater major carp, *Catla catla* (Ham.): a light and scanning electron microscopic study. Zool Jb Anat 1985;113:375–89.
[14] Chakrabarti P, Sinha GM. Mucosal surface of the alimentary canal in *Mystus vittatus* (Bloch): a scanning electron microscopic study. Proc Ind Natl Acad Sci 1987;53B:317–22.
[15] Chakrabarti P, Mandal DK, Ganguli S. A scanning electron microscope study of the mucosal epithelium of the alimentary canal of stomach bearing herbivorous fish *Oreochromis mossambicus* (Peters). Eur Arch Biol 1992;103:265–70.
[16] Carrasson M, Garu A, Dopazo LR, Crespo S. A histological, histochemical and ultrastructural study of the digestive tract of *Dentex dentex* (Pisces, Sparidae). Histol Histopathol 2006;21:579–93.
[17] Haloi K, Kalita M, Nath P. The study on the histopathological changes of stomach of *Channa punctatus* (Bloch) by used pesticide endosulfan. Global J Sci Front Res Biol Sci 2013;13:1–6.
[18] Al-Hussaini AH. The anatomy and histology of the plankton-feeder, *Atherina forskali* Rüpp. J Morphol 1947;80:251–86, http://dx.doi.org/10.1002/jmor.1050800205.
[19] Kapoor BG. The morphology and histology of alimentary tract of a plankton-feeder, *Gadusia chapra* (Hamilton). Ann Museo civico Storia Nat Genova 1957;70:8–32.
[20] Khanna SS. Alimentary canal in some teleost fishes. J Zool Soc Ind 1961;113:206–19.
[21] Pasha Kamal SM. The anatomy and histology of alimentary canal of an omnivorous fish *Mystus* (=Macrones) *gulio* (Ham.). Proc Ind Acad Sci 1964;59B:211–21, http://dx.doi.org/10.1007/BF03052336.
[22] Pasha Kamal SM. The anatomy and histology of the alimentary canal of a carnivorous fish, *Megalops cyprinoides*. Proc Ind Acad Sci 1964;60B:107–15, http://dx.doi.org/10.1007/BF03052355.
[23] Sinha GM, Seth SK, Chakrabarti P. Effects of dimecron on the digestive system in an Indian freshwater teleost, *Mystus aor*. Zool Jb Anat 1988;117:65–89.
[24] Mondal DK, Chakrabarti P. Architectural pattern of mucosal epithelium of the alimentary canal of *Notopterus notopterus* (Pallas) and *Oreochromis mossambicus* (Peters): a comparative study. Acta Ichthyol Piscat 1996;26:15–23.
[25] Ling EA, Tan CK. Fine structure of the gastric epithelium of the coral fish, *Chelmon rostratus* Cuvier. Okajimas Folia Anat Jpn 1975;51:285–310.
[26] Gargiulo AM, Ceccarelli P, Dall'aglio C, Pedini V. Ultrastructure study on the stomach of *Tilapia* spp. (Teleostei). Anat Histol Embryol 1997;26:331–6, http://dx.doi.org/10.1111/j.1439-0264.1997.tb00144.x.
[27] Bowen SH. Detrital nonprotein amino acids are the key to rapid growth of *Tilapia* in Lake Valencia, Venezuela. Science 1980;207:1216–8, http://dx.doi.org/10.1126/science.207.4436.1216.
[28] Lobel PS. Trophic biology of herbivorous reef fishes: alimentary pH and digestive capabilities. J Fish Biol 1981;19:365–97, http://dx.doi.org/10.1111/j.1095-8649.1981.tb05842.x.
[29] Osman AHK, Caceici T. Histology of the stomach of *Tilapia nilotica* (Linnaeus, 1758) from the River Nile. J Fish Biol 1991;38:211–23, http://dx.doi.org/10.1111/j.1095-8649.1991.tb03107.x.