



ELSEVIER

SciVerse ScienceDirect

journal homepage: <http://www.elsevier.com/locate/rpor>

Original research article

Correlation between clinical findings and magnetic resonance imaging for the assessment of local response after standard treatment in cervical cancer[☆]



Izaskun Valduvieto^{a,*}, Albert Biete^a, Iván Rios^a, Ricardo Llorente^a,
Angels Roviroso^a, Jaume Pahisa^b, Laura Vidal^b,
Blanca Farrús^a, Pilar Samper^c

^a Radiation Oncology Department, Institute of Haematology and Oncology (ICMHO), Gynecologic Oncology Unit, Hospital Clínic Universitari of Barcelona, Institut d'Investigacions Biomèdiques August Pi i Sunyer (IDIBAPS), University of Barcelona, Barcelona, Spain

^b Gynecologic Oncology Unit, Hospital Clínic Universitari of Barcelona, Institut d'Investigacions Biomèdiques August Pi i Sunyer (IDIBAPS), University of Barcelona, Barcelona, Spain

^c Radiation Oncology Department, Hospital Rey Juan Carlos, Madrid, Spain

ARTICLE INFO

Article history:

Received 30 November 2012

Accepted 2 April 2013

Keywords:

Cervical cancer

Assessment of local response

Correlation clinical/radiological

ABSTRACT

Background: The aim of our study is to evaluate the correlation between gynecological examination and magnetic resonance (MRI) findings for the assessment of local response in cervical cancer patients treated with radiotherapy/chemotherapy (RT/ChT).

Patients and methods: This study is a retrospective review of 75 consecutive cervical cancer patients from April 2004 to November 2009 treated with RT/ChT. Clinical and radiological data were subsequently analyzed. Patient's median age was 51 with a FIGO stage from Ib to IVb. Individualized RT/ChT was administered with a median dose of 45 Gy. Sixty-three patients received a complementary brachytherapy. Seventy-one patients received chemotherapy on a weekly basis. Gynecological exam was performed 3 months and 6 months after treatment and these findings were compared to MRI results at the same time. **Statistic analysis:** We used the Spearman's Rho test to determine the correlation level between the clinical and radiological methods.

Results: A correlation of 0.68 (60%) was observed between the clinical and MRI findings at 3 months with a further increase of up to 0.86 (82.6%) at 6 months. In the few cases with a poor correlation, the subsequent assessment and the natural history of the disease showed a greater value of the clinical exam as compared with the MRI findings.

[☆] Presented in part at the 31st European Society for Radiotherapy and Oncology (ESTRO) Barcelona, Spain, May 9–13, 2012.

* Corresponding author at: Radiation Oncology Department. Hospital Clínic Universitari, Villarroel 170, 08036 Barcelona, Spain. Tel.: +34 93 2275542; fax: +34 93 2275542.

E-mail address: ivalduvi@clinic.cat (I. Valduvieto).

1507-1367/\$ – see front matter © 2013 Greater Poland Cancer Centre. Published by Elsevier Urban & Partner Sp. z o.o. All rights reserved. <http://dx.doi.org/10.1016/j.rpor.2013.04.026>

Conclusions: Physical exam remains an essential tool to evaluate the local response to RT/ChT for cervical cancer. The optimal clinical radiological correlation found at 6 months after treatment suggests that the combination of gynecological examination and MRI are probably adequate in patient monitoring.

© 2013 Greater Poland Cancer Centre. Published by Elsevier Urban & Partner Sp. z o.o. All rights reserved.

1. Background

Cervical cancer is a very important issue in women's health, representing the second most common malignancy with an incidence of 500,000 patients annually worldwide [1,2].

The patients with locally advanced disease are optimally treated with a combination of radio/chemotherapy (RT/ChT) [3,4]. However, there is no clear consensus for the optimal post-treatment evaluation.

The use of magnetic resonance imaging (MRI) for the evaluation of cervical cancer before and after treatment is well established but there are some important and difficult issues that must be addressed [5]. Some of them are the evaluation of tumor response to therapy and the distinction between post-radiation changes and viable tumor.

The differential between residual tumor and radiation changes cannot be done with conventional magnetic resonance images especially in the first 3 months after therapy [6]. When changes in tumor occur as a consequence of biological and molecular changes, functional imaging techniques are considered as an adjunctive tool in evaluating tumor features (Positron Emission Tomography, PET-scan).

We know that MRI may be superior to computed tomography (CT) for residual tumor detection because of its high contrast resolution. The residual disease has a high signal intensity on T2-weighted images, similar to the corresponding primary tumor [7]. Therefore, MRI is considered the method of choice for follow-up after surgery or radiation treatment recommended by the FIGO guidelines because of its usefulness in the detection of local disease recurrence. However, physician experience with radiological post-treatment changes is essential to prevent misinterpretations.

For these reasons, imaging techniques, especially magnetic resonance imaging, are widely used as a complement to the pelvic exam [8].

2. Aim

The purpose of our study is to determine the correlation degree between the clinical and radiological findings in the evaluation of treatment response to radio/chemotherapy in patients with locally advanced cervical carcinoma.

3. Patients and methods

A total of 75 consecutive patients presenting with a diagnosis of locally advanced cervical cancer treated with either radiation alone or concomitant radio/chemotherapy in our hospital between April 2004 and November 2009 were included. Median

age was 51 years (range: 29–81). Histopathological diagnosis was squamous carcinoma in 59/75 patients (78.7%), adenocarcinoma in 9/75 (12%) and other carcinomas (adeno-squamous, small cell) in 7/75 patients (9.3%).

Patients were staged using the 1988 FIGO classification (Fédération Internationale de Gynécologie Obstétrique) [9]. The main clinical characteristics are summarized in Table 1.

Node staging was performed prior to radiotherapy (RT) by laparoscopic lymphadenectomy in 64 patients (85.33%); pelvic lymphadenectomy in 29 patients (38.7%) and pelvic plus para-aortic lymphadenectomy in 35 patients (46.7%).

All patients were treated with external beam radiotherapy (EBRT): pelvic only in 60 patients and both pelvic and para-aortic in 15 patients. Treatment was performed using 6 MV or 18 MV photons from a Linear Accelerator with multileaf collimator after 3D planning. The total median dose was 45 Gy, with daily fractions of 1.8–2 Gy, once a day, 5 days per week. Seventy-one patients received concomitant RT–ChT based on platin compounds and only 4/75 patients did not undergo ChT (elderly and/or low performance status).

Sixty-three patients (84%) received brachytherapy (BT) in addition to EBRT. Within this group, 54 patients received low-dose rate BT (median dose: 30 Gy at point A) and the 9 remaining patients received high-dose rate BT (median dose: 22 Gy at point A). The treatment was completed with an EBRT parametrial boost with a median dose of 14 Gy in 41 patients (54.6%).

Magnetic Resonance Imaging and Abdominal CT scan were performed in all patients before RT. The treatment response was evaluated 3 and 6 months after the completion of therapy with a complete physical examination (including vaginal vault inspection plus bimanual pelvic examination) and radiological assessment with MRI. All the MRIs were analyzed in a tumor

Table 1 – Clinical characteristics of the 75 patients.

Age	
Median	51 years
FIGO stage	
Ib2	8 (10.7%)
IIb	26 (34.6%)
IIIb	33 (44%)
IV	8 (10.7%)
Pathology	
Squamous	59 (78.7%)
Adenocarcinoma	9 (12%)
Others	7 (9.3%)
Radiotherapy (median dose)	
Pelvic	60 (80%)
Paraaortic	15 (20%)
Chemotherapy	
Yes/no	71/4

board and were compared to physical examination. Patients underwent follow up every 3–4 months for the first 2 years and then every 6 months afterwards.

3.1. MRI protocol

MR imaging was performed using a 1.5-T (Siemens). The protocol, transverse and sagittal T1-weighted spin-echo (SE) images and transverse T1-weighted fat-saturated images of the pelvis were obtained before and after contrast enhancement. Transverse and sagittal T2-weighted fast SE sequences of the pelvis were also obtained. MR images were evaluated by gynecological radiologists and patients were classified as complete response (CR), partial response (PR), disease progression (DP) or stable disease (SD).

3.2. Assessment of the correlation

If physical examination and radiological evaluation shared the same features, this was considered as correlation. In the cases of no correlation, when physical examination findings showed a CR and MRI reported a PR, both examinations were repeated 3 months after or a PET-scan was performed. If there was a CR on MRI but a PR in the physical examination, we performed a vaginal vault cytology or biopsy of the suspicious area. Finally, if there was a DP on MRI not evidenced in the physical examination, we performed a PET-scan.

4. Statistical analysis

The correlation between the MRI and clinical findings was assessed by Spearman's rho (rank correlation) test. "r" values ≥ 0.75 , 0.74–0.50 and < 0.50 were considered to represent a very good correlation, good correlation, and poor correlation, respectively. Actuarial survival curves were plotted according to the Kaplan–Meier method. All statistical analyses were performed with the SPSS statistical package, version 18.0. *p*-Values < 0.05 were considered significant.

5. Results

Follow-up and clinical outcome data were available in 66 of the 75 patients treated (88%). The mean follow-up was 31.1 months (range: 3.2–74.2). Twenty-two patients died (29.3%), with a median survival time of 54.1 months (95% confidence interval (CI) 47.2–61 months).

Local relapse was observed in 21 patients (28%). Six patients had a vaginal compromise (28.6%); 3 of these received a BT rescue achieving local control. Seven patients had lymph node metastasis and 15 patients showed distant metastasis (6 liver metastasis, 2 lung, 3 bone, and 4 peritoneal carcinomatosis).

The median local relapse-free survival for the entire series was 54 months (95% CI 46.8–61.2) and the median metastasis-free survival was 52.6 months (95% CI 45.3–59.9).

5.1. Clinical–radiological correlation in cervical cancer 3 months after treatment

Gynecological exam and MRI results of 71 patients were available 3 months after treatment. Only 4 patients were lost at follow-up: one patient died due to febrile neutropenia and sepsis, one patient had a peritonitis and could not be properly followed, one patient went to another institution and the last one did not finally receive standard treatment due to small cell histology. The assessment of local response to treatment with physical exam and MRI correlated in 45 patients (60%) and was discordant in [26] patients (34.7%). According to the Spearman's rho test, the correlation of clinical–radiological assessment at 3 months was considered good ($r = 0.658$, $p < 0.0001$) (Table 2a).

5.2. Clinical–radiological correlation in cervical cancer 6 months after treatment

The second assessment was carried out at 6 months after completion of treatment. 60 patients were available for the analysis. Eleven patients were lost at follow-up between the first and second assessment; 8 of them with disease progression and the remaining 3 were followed in other institutions.

The clinical and radiological assessment had a positive correlation in 55/60 patients (91.67%). Within the five non correlated cases, four patients initially had both clinical and radiological partial response to the treatment in the first assessment but the second MRI showed a residual tumor in the cervix (low-uptake and persistence of pelvic fat parametrium changes) and the gynecological exam showed complete response (Fig. 1). In the remaining patient, the discordance between clinical and radiological results was related to the presence of pelvic infection hindering adequate clinical assessment.

According to the Spearman's rho test, the clinical and radiological correlation in the second assessment was considered very good ($r = 0.86$, $p < 0.0001$) (Table 2b).

6. Discussion

Accurate evaluation of local tumor response is essential to determine the probability of disease control in locally advanced cervical cancer. The lack of local control usually precedes the development of widespread disease [10].

The incorporation of MRI in a routine practice has provided a more precise evaluation of cervical tumors in terms of volume, localization, presence of parametrial and/or uterosacral infiltration and regional lymph node involvement [11]. To accurately localize relapse, clinical examination may not be enough and there are no established MRI parameters for the same purpose [12].

Therefore, MRI is widely accepted as a useful imaging tool for the diagnosis, staging, planning and follow-up for cervical cancer. There are many clinical trials on MRI in the diagnosis and staging of locally advanced cervical cancer. However, these trials do not evaluate the monitoring and assessment issues after radiation therapy.

Table 2a – The correlation between the MRI and clinical findings was assessed by Spearman’s rho test. A good correlation were observed between the clinical and MRI findings at 3 months.

		MRI 3 months					Total
		Lost	CR ^a	PR ^b	SD ^c	PD ^d	
Clinical 3 months	Lost	4	0	0	0	0	4
	CR	0	25	17	0	0	42
	PR	0	2	15	1	1	19
	SD	0	0	0	1	0	1
	PD	0	0	3	1	5	9
	Total	4	27	35	3	6	75

^a CR: complete response.

^b PR: partial response.

^c SD: stable disease.

^d PD: progression disease.

Table 2b – The correlation increased to a very good correlation at 6 months.

		MRI 6 months					Total
		Lost	CR	PR	SD	PD	
Clinical 6 months	Lost	15	0	0	0	0	15
	CR	0	38	3	1	2	44
	PR	0	0	7	0	0	7
	SD	0	0	0	0	0	0
	PD	0	0	0	0	9	9
	Total	15	37	10	1	11	75

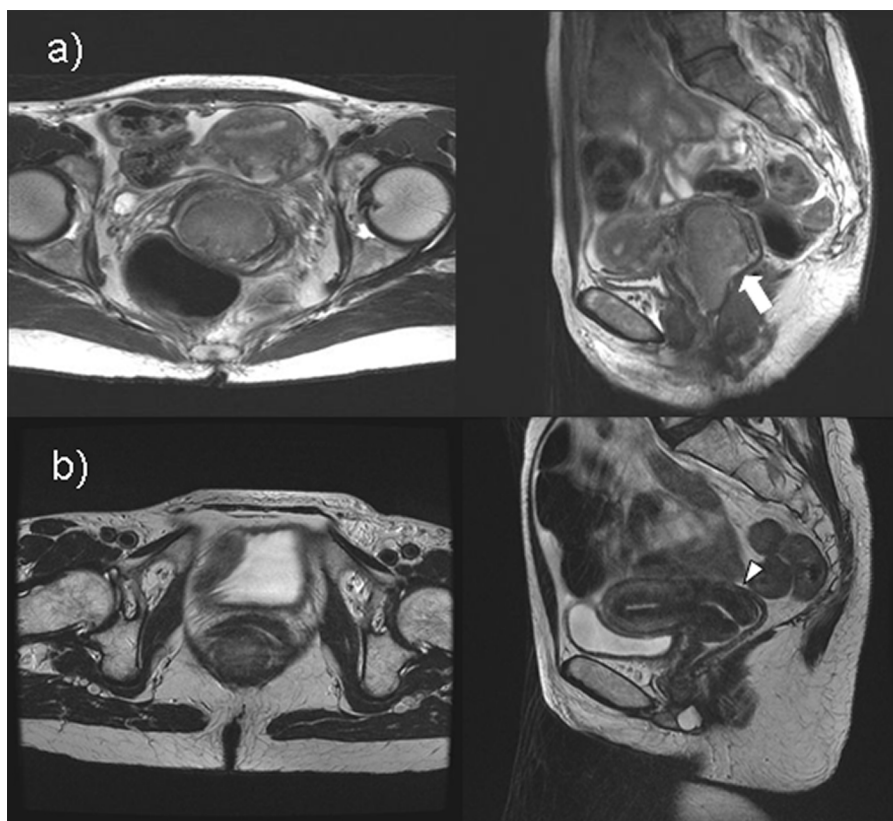


Fig. 1 – MRI shows a patient in whom physical examination and imaging test is not consistent. (a) Para-axial and sagittal MRI diagnosis. Bulky cervical tumor sample occupies 2/3 of vagina without infiltrating it. No parametrial infiltration. (b) Para-axial and sagittal MRI after treatment, showing persistent hypointense image in the cervix, which is classified as a partial response. However, the physical examination reported complete response.

Until recently, physical examination and cytology were the only methods for disease follow-up, despite the lack of sensitivity in differentiating fibrosis from residual tumor. MRI (before, during and after treatment) represents an invaluable tool because it allows differentiation of healthy tissue, tumor and post-irradiation fibrosis [13–15]. Ma et al. observed the signal intensity changes through the implementation of MRI-T2 before treatment and at week 4 (a half of treatment). These authors concluded that persistent high signal intensities in the tumor at mid treatment predicted a high risk for treatment failure, while a large reduction in signal intensity predicted a favorable outcome. These authors did not perform an evaluation at the end of treatment [16]. As pointed out by Vincens et al. [17], MRI assessment of residual post-ChT/RT disease continues to be difficult and the risk of false positives is high. These authors reported a false positive rate of up to 50%.

Although the use of MRI in daily practice is to assess tumor response in cervical cancer patients, its real value in properly assessing tumor outcome during follow-up still needs to be elucidated. For this reason, we proposed the current study in order to find the grade of correlation between clinical examination and MRI with tumor response evaluation at 3 and 6 months.

Literature review provides few data on this subject with regard to both follow-up and clinical–radiological correlation. In a recent study of 36 cases published in 2011, Engin et al. [12] reported a correlation of 88.9% (32/36) r : 0.674 in the evaluation of response to treatment at 6 months. The presence of edema, inflammatory phenomena, fibrosis, necrosis or hemorrhage may induce incorrect MRI interpretation. These authors recommend definitive evaluation of post-irradiation response with MRI 6 months after therapy. In the case of clinical–radiological discordance, they recommend transvaginal echo-guided biopsy or computerized tomography-guided biopsy.

The clinical–radiological correlation found in our series at 3 months was 60% which is considered good with the Spearman rho test (r : 0.658). At 6 months correlation improved up to 91.7% (very good correlation, r : 0.860). Engin et al. obtained similar results to our study in a single assessment at 6 months, albeit with fewer cases (n : 36) (88.9%). The histologist and staging features between their series and the present series were similar [12]

Rizzo et al. [18] reviewed the post-irradiation MRI in a series of 17 patients and concluded that at 3 months conventional MRI inadequately differentiates the post-irradiation changes of the residual tumor. They concluded that Diffusion Weighted Magnetic Resonance (DWMR) should be considered as an additional tool in the follow-up of non-surgical cases. Levy et al. [19] reported a similar conclusion.

Not all the studies coincide in indicating the importance of MRI. Ryu et al. [20] concluded that PET scan was effective in detecting early recurrences in cervical cancer patients and that it could be a useful follow-up tool for cervical cancer. In addition, a recent study by Yen [21] showed that for recurrent cervical cancer, the benefit of PET scan exceeded that of MRI owing to PET's ability to identify extrapelvic metastases and to its higher sensitivity and specificity. In a review study, Elit et al. [22] described the limited and heterogeneous results of MRI

and post-irradiation cytology in the detection of recurrence in asymptomatic women.

New functional MRI tools have also been evaluated. Harry et al. [23] studied the effectiveness of DWMR in the early evaluation of response to RT–ChT at 14 days after initiation. Despite the promising results as a predictor of response, larger studies are needed because their series only included 25 cases. In this sense, Saida et al. [24] studied a series of 46 cases measuring the volume of the areas of high signal intensity in T2 immediately after finishing the treatment. They concluded that local control depends more on the diminishment of volume registered than the initial volume. As in other trials, no mention was made of the clinical–radiological correlation. In a series of 14 patients Zhang et al. [25] also studied the value of DWMR in the immediate evaluation of radiological response without assessing the grade of reliability on posterior outcome.

Much more recently, the criteria of the American College of Radiology insisted on MRI and PET scan as the most effective method for post-ChT–RT follow-up of locally advanced cervical cancers [4]. However, the value of all these imaging techniques in the follow-up of these patients is being discussed and should be evaluated in large multicenter studies prior to their inclusion in a usual clinical practice.

None of the studies cited, except that of Engin et al. [12], investigated the clinical–radiological correlation. In our series of 75 correlative cases, the concordance at 6 months was of 91.7%. The four cases with initial discordance showed CR on posterior MRI, coinciding with the clinical finding of no persistence. This fact indicates a great value and reliability of the optimal gynecological examination. This confirms the opinion of other authors [17] with regard to false positives in the early post-treatment MRI.

7. Conclusion

Gynecological examination is an essential part in the early assessment of the local response to the treatment of RT/ChT in cervical cancer. The MRI limitation in the first 3 months after treatment suggests the need to include other imaging tools to improve the accuracy in this time period. The optimal clinical radiological correlation found at 6 months after treatment suggests that the combination of gynecological examination and MRI are probably adequate in patient monitoring.

Financial disclosure

None declared.

Conflict of interest

The authors declare that there are no conflicts of interest.

REFERENCES

- [1]. Ferlay J, Shin HR, Bray F, et al. Estimates of worldwide burden of cancer in 2008: GLOBOCAN 2008. *Int J Cancer* 2010;15:127.

- [2]. Hoskins WC, Perez CA, Young RC, et al. *Principles and practice of gynecologic oncology*. 4th ed. Philadelphia: Lippincott Williams and Wilkins; 2005.
- [3]. Heinzelmann F, Henke G, von Grafenstein M. Adjuvant radiochemotherapy in patients with locally advanced high-risk cervical cancer. *Strahlenther Onkol* 2012;**188**:568-75.
- [4]. Roszak A, Wareńczak-Florczak Z, Bratos K, Milecki P. Incidence of radiation toxicity in cervical cancer and endometrial cancer patients treated with radiotherapy alone versus adjuvant radiotherapy. *Rep Pract Oncol Radiother* 2012;**17**(6):332-8.
- [5]. Brocker KA, Alt CD, Eichbaum M, Sohn C. Imaging of female pelvic malignancies regarding MRI, CT, and PET/CT. Part 1. *Strahlenther Onkol* 2011;**187**:611-8.
- [6]. Flueckiger F, Ebner F, Poschauko H, et al. Cervical cancer: serial MR imaging before and after primary radiation therapy a 2 year follow-up study. *Radiology* 1992;**184**:89-93.
- [7]. Jeong YY, Kang HK, Chung TW, et al. Uterine cervical carcinoma after therapy: CT and MR imaging findings. *Radiographics* 2003;**23**:969-81.
- [8]. Hatano K, Han I, Deppe G, et al. Evaluation of the therapeutic effect of radiotherapy on cervical cancer using MRI. *Int J Radiat Oncol Biol Phys* 1999;**45**:639-44.
- [9]. TMN Classification of Malignant Tumours. In: Sobin LH, Wittekind, editors. *Union Internationale Contre le Cancer*. Washington, DC: Wiley-Liss; 2002.
- [10]. Biete A, Batlle P, Fuentes J, et al. Cáncer de cuello uterino: análisis de 343 pacientes. *Clín Investig Ginecol Obstet* 1988;**15**:28-36.
- [11]. Lee DW, Kim YT, Kim JH, et al. Clinical significance of tumor volume and lymph node involvement assessed by MRI in stage IIB cervical cancer patients treated with concurrent chemoradiation therapy. *J Gynecol Oncol* 2010;**21**:18-23.
- [12]. Engin G, Küçüçük S, Ölmez H, Haşiloğlu ZI, Dişçi R, Aslay I. Correlation of clinical and MRI staging in cervical carcinoma treated with radiation therapy: a single-center experience. *Diagn Interv Radiol* 2011;**17**:44-51.
- [13]. Kaur H, Silverman PM, Iyer RB, Verschraegen CF, Eifel PJ, Charnsangavej C. Diagnosis, staging, and surveillance of cervical carcinoma. *AJR Am J Roentgenol* 2003;**180**:1621-31.
- [14]. Flueckiger F, Ebner F, Poschauko H, Tamussino K, Einspieler R, Ranner G. Cervical cancer: serial MR imaging before and after primary radiation therapy a 2-year follow-up study. *Radiology* 1992;**184**:89-93.
- [15]. Ebner F, Kressel HY, Mintz MC, et al. Tumor recurrence versus fibrosis in the female pelvis: differentiation with MR imaging at 1.5 T. *Radiology* 1988;**166**:333-40.
- [16]. Ma DJ, Zhu JM, Grigsby PW. Change in T2-fat saturation MRI correlates with outcome in cervical cancer patients. *Int J Radiat Oncol Biol Phys* 2011;**81**:707-12.
- [17]. Vincens E, Balleyguier C, Rey A, et al. Accuracy of magnetic resonance imaging in predicting residual disease in patients treated for stage IB2/II cervical carcinoma with chemoradiation therapy: correlation of radiologic findings with surgicopathologic results. *Cancer* 2008;**113**:2158-65.
- [18]. Rizzo S, Summers P, Raimondi S, et al., Diffusion-weighted MR. imaging in assessing cervical tumour response to nonsurgical therapy. *Radiol Med* 2011;**116**:766-80.
- [19]. Levy A, Caramella C, Chargari C, et al. Accuracy of diffusion-weighted echoplanar MR imaging and ADC mapping in the evaluation of residual cervical carcinoma after radiation therapy. 2011;**123**:110-5.
- [20]. Ryu SY, Kim MH, Choi SC, et al. Detection of early recurrence with 18F-FDG PET in patients with cervical cancer. *J Nucl Med* 2003;**44**:347-52.
- [21]. Yen TC, Lai CH, Ma SY, et al. Comparative benefits and limitations of (18)F-FDG PET and CT-MRI in documented or suspected recurrent cervical cancer. *Eur J Nucl Med Mol Imaging* 2006;**33**:1399-407.
- [22]. Elit L, Fyles AW, Devries MC, Oliver TK, Fung-Kee-Fung M. Follow-up for women after treatment for cervical cancer: a systematic review. *Gynecology Cancer Disease Site Group. Gynecol Oncol* 2009;**114**:528-35.
- [23]. Harry VN, Semple SI, Gilbert FJ, Parkin DE. Diffusion-weighted magnetic resonance imaging in the early detection of response to chemoradiation in cervical cancer. *Gynecol Oncol* 2008;**111**:213-20.
- [24]. Saida T, Tanaka YO, Ohara K, et al. Can MRI predict local control rate of uterine cervical cancer immediately after radiation therapy? *Magn Reson Med Sci* 2010;**9**:141-8.
- [25]. Zhang Y, Chen JY, Xie CM, et al. Diffusion-weighted magnetic resonance imaging for prediction of response of advanced cervical cancer to chemoradiation. *J Comput Assist Tomogr* 2011;**35**:102-7.
- [26]. Wolfson AH, Varia MA, Moore D, et al. ACR Appropriateness Criteria® role of adjuvant therapy in the management of early stage cervical cancer. *Gynecol Oncol* 2012;**125**:256-62.