



REVISTA BRASILEIRA DE REUMATOLOGIA

www.reumatologia.com.br



Case report

Reduced activation and CD3 lymphocyte recruitment after TNF-inhibitor use: evaluation of clinical and 99mTc-OKT3 scintigraphic response in a patient with juvenile idiopathic arthritis

Redução da ativação e do recrutamento de linfócito CD3 com o uso de anticorpo anti-tnf-alfa: avaliação da resposta clínica e cintilográfica com okt3-99mTc em paciente com artrite idiopática juvenil

Flavia Paiva Proença Lobo Lopes^a, Sergio Augusto Lopes de Souza^{a,*},
Blanca Elena Rios Gomes Bica^b, Lea Mirian Barbosa da Fonseca^a,
Mario Newton Leitão de Azevedo^b, Bianca Gutflen^a

^a Cell and Molecule Labelling Laboratory (CMLL), Department of Radiology, Medicine School, Universidade Federal do Rio de Janeiro (UFRJ), Rio de Janeiro, RJ, Brazil

^b Department of Rheumatology, Hospital Universitário Clementino Fraga Filho, Universidade Federal do Rio de Janeiro (UFRJ), Rio de Janeiro, RJ, Brazil

ARTICLE INFO

Article history:

Received 5 August 2014

Accepted 1 March 2015

Available online xxx

Introduction

The immune response in inflammatory connective tissue diseases depends on the antigen presentation by the T cell receptor complex (TCR) and cell Major Histocompatibility Complex (MHC), of the cytoplasmic signal transduction involving CD3 complex leading to activation, of the proliferative response of T lymphocytes and of cytokine production.¹

The CD3 molecular complex is critical and must necessarily be present on the surface of T lymphocytes for the occurrence TCR expression by the cell,² while the absence of CD3 chain blocks the development of T lymphocytes, preventing TCR expression and T-cell activation.³

CD3 blockage by anti-CD3 monoclonal antibodies prevents the expression of TCR and activation of T lymphocytes, extending transplant survival.⁴ There is an intrinsic relationship among antigen presentation, T cell activation,

* Corresponding author.

E-mail: sergioalsouza@gmail.com (S.A. Lopes de Souza).

<http://dx.doi.org/10.1016/j.rbre.2015.08.011>

2255-5021/© 2015 Elsevier Editora Ltda. This is an open access article under the CC BY-NC-ND license (<http://creativecommons.org/licenses/by-nc-nd/4.0/>).

transplanted tissue rejection, and production of TNF- α , depending on the presence of a CD3 molecule.⁵

In Juvenile idiopathic arthritis (JIA), the antigen presentation by dendritic cells and the lymphocyte activation depend on the relation TCR/MHC, and consequently on CD3 complex, acting on TNF- α production – a fact of great importance in the pathophysiology of the disease and in perpetuating mechanisms of a chronic synovial inflammation process.⁶ Currently, the treatment with anti-TNF inhibitors has been used to control JIA; the use of this antibody allows the decrease of the inflammatory process and bone injury, with an effective control of the signs and symptoms of the disease.⁷ This medication acts on circulating molecules and also in those molecules present on the surface of the cell membrane, inducing apoptosis of cells that produce TNF- α .⁸

Often is difficult to carry out a clinical joint evaluation, making it impossible to verify the disease activity. Thus, the continuity of treatment proceeds on empirically, and not based on pathophysiological characteristics. It is noteworthy that the disease usually accompanies the patient for life, with periods of exacerbation and inactivity, and in many cases, one cannot differentiate these stages only with clinical assessment.⁹

Based on the specific binding ability of anti-CD3 complex monoclonal antibodies present in joint inflammatory reactions when the disease is active, as in JIA, it was possible to devise a diagnostic method using gamma-emitting radionuclide (technetium-99m-^{99m}Tc) coupled to these molecules.

The aim of this study was to demonstrate the potential of ^{99m}Tc-OKT3 scintigraphy to assess disease activity and the therapeutic response in a female patient with juvenile idiopathic arthritis.

Case report

Female Caucasian patient, 16 years old, 46 kg, 1.63 m, diagnosed eight years ago with severe systemic onset polyarticular course JIA refractory to multiple DMARDs, and in continuous treatment with prednisone and azathioprine. The difficult-to-control disease was active and with an intense inflammatory reaction: polyarthritis of small and large joints, presence of synovial cysts, fever and deterioration of general condition. Laboratory tests: RBC $4.69 \times 10^6 \text{ mm}^{-3}$, hematocrit 37.9%, leukocytes $8.1 \times 10^3 \text{ mm}^{-3}$, platelets $569 \times 10^3 \text{ mm}^{-3}$, negative serology for hepatitis B and C, CRP 12.1 mg/dL (normal < 0.5 mg/dL), erythrocyte sedimentation rate (ESR) 90 mm (normal < 10 mm). Rheumatoid factor, ANA, and VDRL were negative. She presented arthritis (pain and swelling) in 21 joints; global assessment by visual analogue scale (VAS): patient 8/physician 8; DAS 28 (ESR) 7.94 – (high disease activity). Due to the intense inflammatory activity, the patient had been treated with intravenous immunoglobulin plus deflazacort, prednisone, methotrexate, azathioprine, and leflunomide. With this severe condition, treatment with an anti-TNF inhibitor at a dose of 5 mg/kg every 8 weeks was indicated. The initial evaluation with chest X-ray was normal and the PPD test was negative (with BCG scar). Before the use of biological medication, a baseline ^{99m}Tc-OKT3 scintigraphy was performed. The parents signed an informed consent form for

both procedures and the study was approved by the Research Ethics Committee of HUCFF/UFRJ (protocol 080/03). The initial scintigraphy (Fig. 1A) with anterior and posterior whole-body scans were obtained 1 h and 3 h after intravenous administration of ^{99m}Tc-OKT3, showed normal biodistribution of the radiopharmaceutical in the liver and kidneys, with areas of increased uptake in hands-phalanges, lower limbs, knees and ankles (more pronounced in wrists, ankles and knees). By comparing early (1 h) and late (3 h) images, a significant increase in radiopharmaceutical uptake was noted. This procedure detects inflammatory polyarticular involvement, but it is worth mentioning that its specificity for CD3T cells demonstrates the intense activity and the presence of these cells in joint tissues.

After a 10-month treatment with anti-TNF blocker at a dose of 5 mg/kg every 8 weeks, and with the patient in use of stable doses of azathioprine, prednisone and a non-steroidal anti-inflammatory agent, improvement of the clinical parameters was observed. The fever disappeared. Laboratory tests: RBC $4.74 \times 10^6 \text{ mm}^{-3}$, hematocrit 36.2%, leukocytes $10.1 \times 10^3 \text{ mm}^{-3}$, platelets $458 \times 10^3 \text{ mm}^{-3}$, CRP 12.3 mg/dL, erythrocyte sedimentation rate (ESR) 64 mm. Arthritis (pain and swelling) was observed in two joints; global assessment scale – patient 2/physician 2; DAS 28 (ESR) 3.99 – moderate disease activity. In the post-treatment scintigraphy (ten months after the use of anti-TNF- α [Fig. 1, lower segment]), areas of uptake in feet, ankles, knees, wrists and hands were observed. In the comparative analysis versus the pretreatment study, there is intense inflammatory activity (but to a lesser degree) in feet, ankles, knees, wrists and hands, showing a decrease in the inflammatory process, but with persistent active disease despite clinical and laboratory improvement.

Discussion

Following treatment with an anti-TNF-inhibitor, our patient improved her clinical parameters and also with respect to: DAS 28, a 49.8% decrease; VAS by patient and physician, 75%. As to acute phase reactants, CRP denoted no change, with ESR decreasing 29%. It can be noted that, in the face of a very aggressive disease, the clinical and laboratory parameters improved with the patient's treatment. Baseline ^{99m}Tc-OKT3 scintigraphy (Fig. 1, upper segment) showed sensitivity to the presence of a rheumatoid inflammatory process, with intense uptake at the level of inflamed joints, in agreement with the patient's initial clinical status, joint examination and tests for acute phase reactants. The scintigraphy study also demonstrated an ability to qualify the presence of CD3-dependent inflammatory reaction, caused by the intense presentation and activation of immune cells, thus characterizing the presence of CD3 in the joint. The scintigraphy study carried out after 10 months of treatment with TNF blocker (Fig. 1, lower segment) revealed significant decrease in CD3 uptake in joints, paralleling the clinical and joint improvement, as well as ESR. This fact supports the reduction of inflammatory activity, particularly that dependent on CD3. Another important factor is that, notwithstanding the important objective clinical response observed, ^{99m}Tc-OKT3 scintigraphy made it

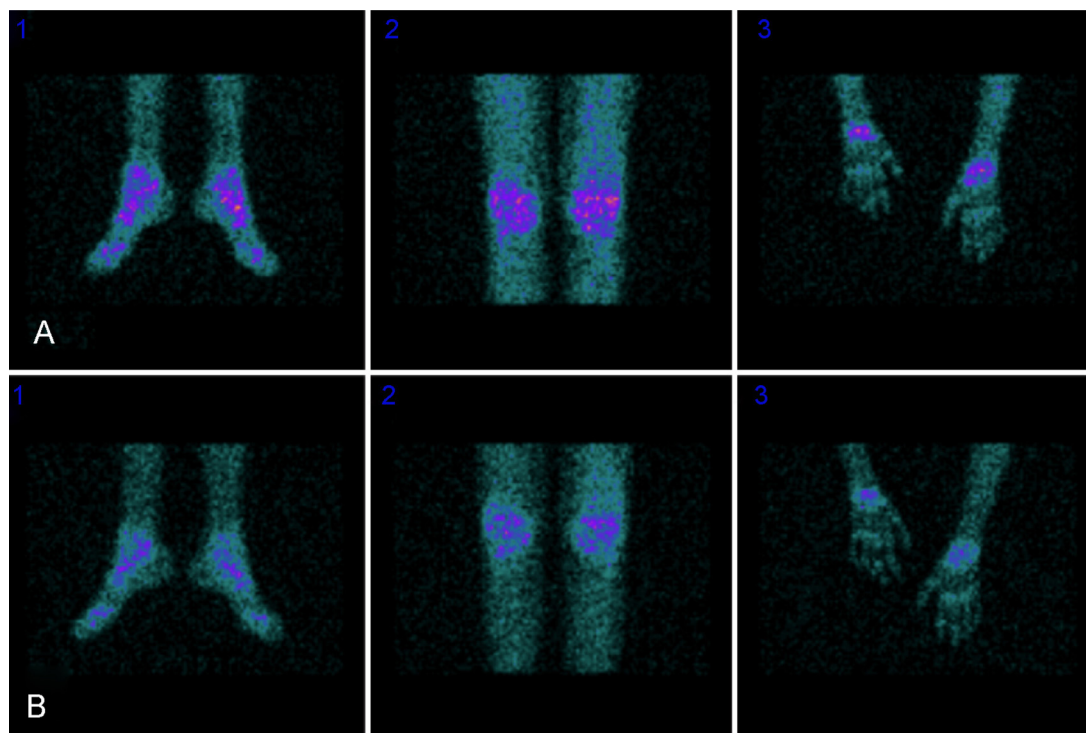


Fig. 1 – 99mTc-OKT3 scintigraphy images before (A) and after (B) the use of anti-TNF-inhibitor, demonstrating ankles, knees and wrists uptake.

possible to detect activity of the still present disease, leading to a continuation of treatment with anti-TNF-inhibitor, until remission was achieved.

The study with anti-CD3 monoclonal antibody (OKT3) targeted against human CD3-cell molecules and labelled with Technetium-99m in JIA patients showed marked radiotracer uptake in inflamed joints, secondarily to lymphocyte activation and proliferation, especially with respect to CD3, related to the severity of synovial inflammation.¹⁰ The purpose of this observation is to evaluate, using 99mTc-OKT3 scintigraphy, the aggression to joint and synovial structures, the clinical action of anti-TNF-inhibitor, its effects on the inflammatory joint process, and the recruitment and activation of CD3 lymphocytes in the joints of a patient with rheumatoid disease.

Although other studies have described the occurrence of side effects after administration of 99mTc-OKT3, these drawbacks were not observed after the use of 99mTc-OKT3 in this study. It is noteworthy that the OKT3 labelling methods described by other authors¹¹ were different, implying even differences in the accumulation and clearing of radiotracers.

These results demonstrate improvement of signs and symptoms with anti-TNF alpha monoclonal antibody therapy, with marked decrease in inflammatory activity in synovial tissues of the rheumatoid arthritis patient. The 99mTc-OKT3 scintigraphy study was able to demonstrate sensitivity, indicating increased presence of CD3 in joint structures, and its decline after specific treatment, with a decrease in inflammatory activity in synovial tissues, and also demonstrates disease activity, despite a marked clinical and laboratory improvement. The results showed that this method was able to capture the recruitment restriction, activation of CD3 molecule and

decrease of activity of inflammatory cells such as CD4 and CD8 cells,¹² secondary to the use of anti-TNF-inhibitor. Thus, we presume that this method could become an important adjuvant in the diagnosis and monitoring of treatment of patients with rheumatoid arthritis, especially in those difficult-to-evaluate cases; and also, perhaps, in optimizing the therapy for patients who, at the time of the examination, demonstrate inactivity of the disease (absence of abnormal uptake of the radiopharmaceutical).

Conflict of interests

The authors declare no conflict of interests.

REFERENCES

1. Janeway CA, Traves P, Walport M, Sclomchik MJ. *Immunobiology: the immune system in health and disease*. 6th ed. New York: Garland Science Publishing; 2005.
2. Sun ZJ, Kim KS, Wagner G, Reinher EL. Mechanism contributing to T cell receptor signaling and assembly revealed by the solution structure of an ectodomain of the CD3 heterodimer. *Cell*. 2001;105:913–23.
3. de Saint Basile G, Geissmann F, Flori E, Urung-Lambert B, Soudais C, Cavazzana-Calvo M, et al. Severe combined immunodeficiency caused by deficiency in either the δ or the ϵ sub unit of CD3. *J Clin Investig*. 2004;114:1512–7.
4. Hamawy MM, Tsuchida M, Cho CS, Manthei ER, Fechner JH, Knechtle SJ. Immunotoxin FN 18-CRM9 induces stronger T cell signaling than unconjugated monoclonal antibody FN18. *Transplantation*. 2001;72:496–503.

5. Smith JB, Haynes MK. Rheumatoid arthritis – a molecular understanding. *Ann Intern Med.* 2002;136:908–22.
6. Thomas R, Davis LS, Lipsky PE. Rheumatoid synovium is enriched in mature antigen-presenting dendritic cells. *J Immunol.* 1994;152:2613–23.
7. Smolen JS, Steiner G. Therapeutic strategies for rheumatoid arthritis. *Nat Rev Drug Discov.* 2003;2:473–88.
8. Hove TT, van Montfrans C, Peppelenbosch MP, van Deventer SJH. Infliximab treatment induces apoptosis of lamina propria T lymphocytes in Crohn's disease. *Gut.* 2002;50:206–11.
9. Bica BERG, Ruiz DG, Magalhães PA, Barcellosa MG, Azevedo MNL. Associação entre artrite idiopática juvenil e osteogenesis imperfecta – Relato de caso. *Rev Bras Reumatol.* 2013;53:535–7.
10. Lopes FPPL, Azevedo MNL, Marchiori E, Fonseca LMB, Souza SAL, Gutfilem B. Use of 99m-anti-CD3 scintigraphy in the differential diagnosis of rheumatic diseases. *Rheumatology.* 2010;49:933–9.
11. Martins FP, Gutfilem B, de Souza SA, de Azevedo MN, Cardoso LR, Fraga R, et al. Monitoring rheumatoid arthritis synovitis with 99mTc-anti-CD3. *Br J Radiol.* 2008;81:25–9.
12. Sakkas LI, Platsoucas CD. Immunopathogenesis of juvenile rheumatoid arthritis: role of T cells and MHC. *Immunol Res.* 1995;14:218–36.