

## Oncology

# A Case of Long-term Survival of Advanced Paratesticular Rhabdomyosarcoma Treated With a Multimodal Therapy Including a Combination of Cyclophosphamide, Vincristine, Doxorubicin and Dacarbazine



Makoto Isono, Akinori Sato\*, Tomohiko Asano

Department of Urology, National Defense Medical College, 3-2 Namiki, Tokorozawa, Saitama, 359-8513, Japan

## ARTICLE INFO

## Article history:

Received 4 March 2016

Accepted 14 March 2016

## Keywords:

Paratesticular rhabdomyosarcoma

CYVADIC chemotherapy

## ABSTRACT

There is no established treatment for advanced rhabdomyosarcoma (RMS) with metastases at the time of diagnosis. A 17-year-old male was referred to our hospital because of a right scrotal mass. Computed tomography showed multiple lung metastases with pleural effusion and retroperitoneal lymph node metastasis, and bone scintigraphy revealed multiple bone metastases. Right high orchiectomy was performed and the tumor was diagnosed as paratesticular embryonal RMS. He was treated with a multimodal therapy including 17 cycles of combination chemotherapy consisting of cyclophosphamide, vincristine, doxorubicin and dacarbazine (CYVADIC) and achieved a long-term survival of 4 years.

© 2016 The Authors. Published by Elsevier Inc. This is an open access article under the CC BY-NC-ND license (<http://creativecommons.org/licenses/by-nc-nd/4.0/>).

## Introduction

Rhabdomyosarcoma (RMS) is the most common soft tissue sarcoma in childhood and adolescence.<sup>1</sup> It progresses rapidly, and the prognosis is poor when the patient has metastases at the time of diagnosis.<sup>2</sup>

We herein report a case in which a patient with advanced paratesticular RMS was treated with a multimodal therapy including 17 cycles of combination chemotherapy consisting of cyclophosphamide (CPA), vincristine (VCR), doxorubicin (ADM), and dacarbazine (DTIC) (CYVADIC) and survived for 4 years.

## Case presentation

A 17-year-old male presented to the outpatient clinic of a nearby hospital with shortness of breath in June 2006. He had a 6 cm × 5 cm non-tender, firm nodular right scrotal mass that he had first noticed 6 months earlier. Chest X-rays showed pleural effusion, and the cytological examination of the pleural effusion was positive for cancer cells. Computed tomography and bone scintigraphy revealed lung, pleura, bone and abdominal lymph node metastases

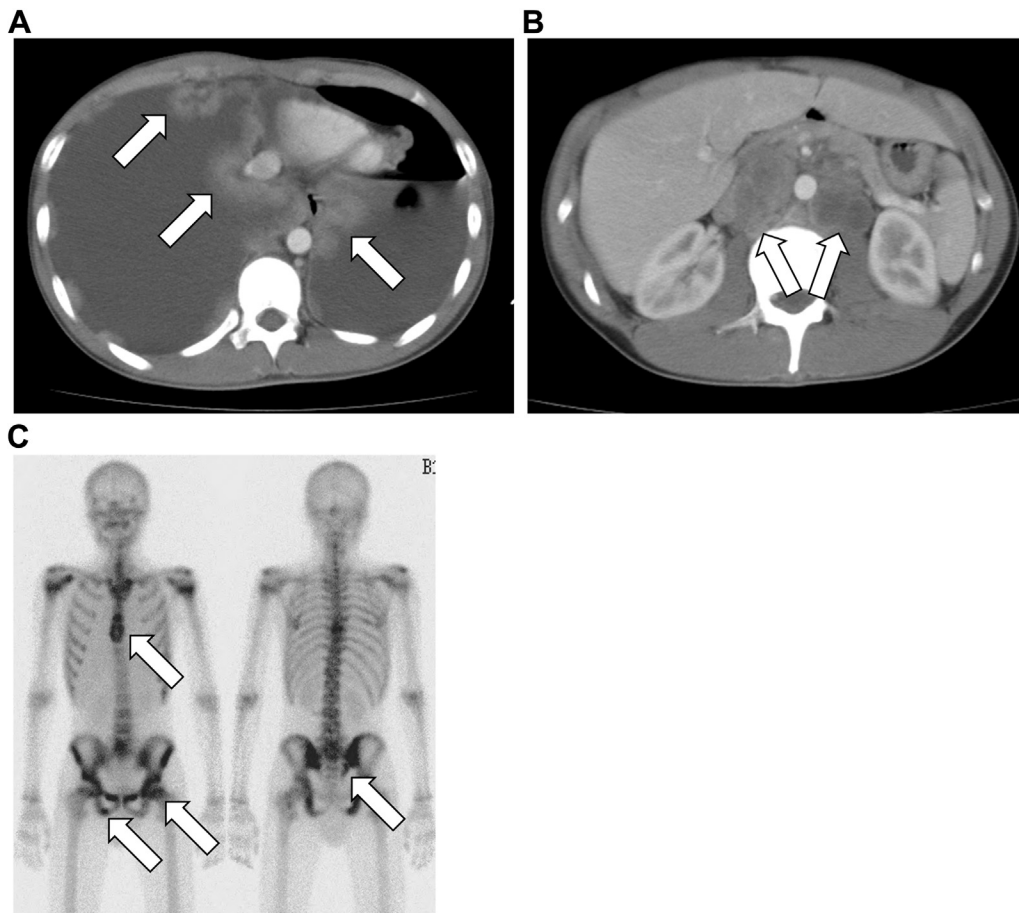
(Fig. 1). He was referred to our hospital under suspicion of a right testicular tumor with multiple metastases.

Right high inguinal orchiectomy and exploratory thoracoscopy were performed. A 6.0 × 4.0 × 2.5 cm mass in the paratesticular region was compressing the right testicle (Fig. 2A). Microsections revealed a cellular sarcoma with round to spindle-shaped cells having scanty cytoplasm and high mitotic activity (Fig. 2B). On immunohistochemistry, the tumor was positive for desmin and myogenin, and was diagnosed as embryonal RMS. The exploratory thoracoscopy showed a pleural dissemination, which was pathologically confirmed to be metastatic RMS.

After surgery, the patient was given five cycles of CYVADIC chemotherapy (CPA 400 mg/m<sup>2</sup>, VCR 1 mg/m<sup>2</sup>, ADM 40 mg/m<sup>2</sup>, DTIC 200 mg/m<sup>2</sup>) and complete remission was obtained (Fig. 2C). Because the tumor recurred in the pleura and paraaortic lymph node in March 2007, another cycle of CYVADIC chemotherapy was given. Thereafter, he received a salvage chemotherapy consisting of CPA 1200 mg/m<sup>2</sup>, VP-16 100 mg/m<sup>2</sup>, VCR 1.5 mg/m<sup>2</sup>, pirarubicin 60 mg/m<sup>2</sup>, cisplatin 20 mg/m<sup>2</sup>, ifosfamide 1800 mg/m<sup>2</sup> and actinomycin D 20 mg/kg accompanied with peripheral blood stem cell transplantation at the department of pediatrics, and again, complete remission was obtained. For the prevention of recurrence, radiotherapy was performed (36 Gy to the right scrotum to para-aortic region, 10 Gy to the lung) in September 2007. In February 2009, however, he was found to have pleural effusion and

\* Corresponding author. Tel.: +81 4 2995 1676; fax: +81 4 2996 5210.

E-mail address: [zenpaku@ndmc.ac.jp](mailto:zenpaku@ndmc.ac.jp) (A. Sato).



**Figure 1.** CT and bone scintigraphy at presentation. CT imaging showed lung, pleura (A, arrows) and abdominal lymph node metastases (B, arrows) and bone scintigraphy revealed multiple bone metastases (C, arrows).

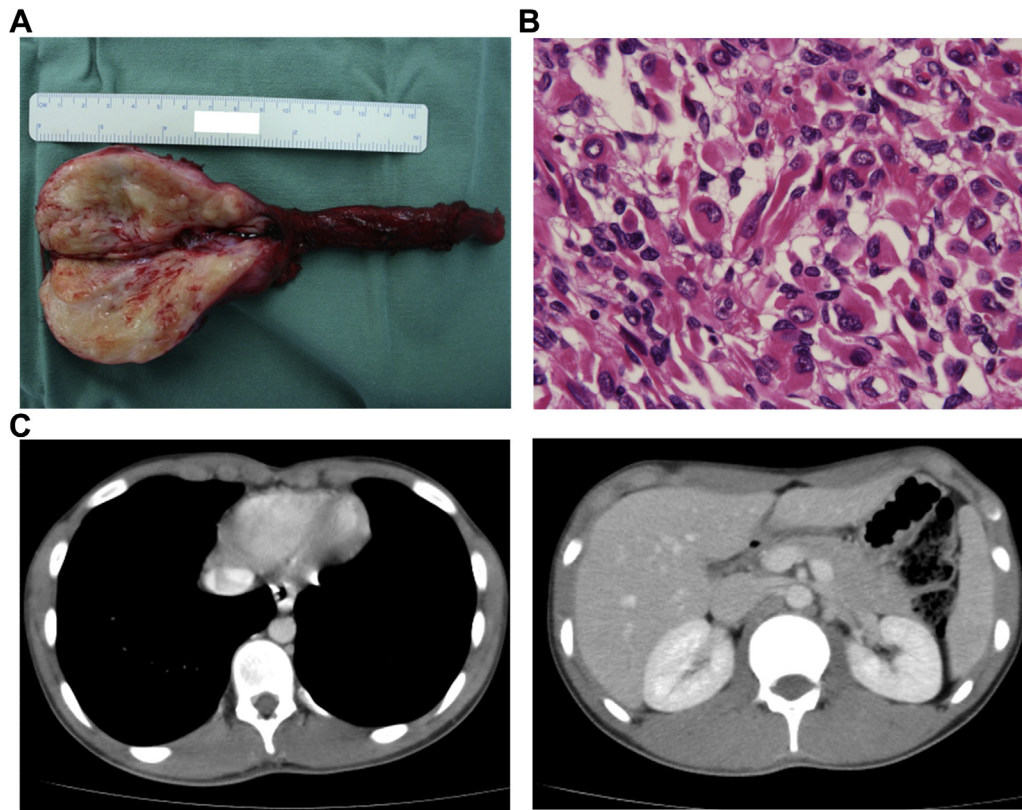
paraaortic lymph node recurrence. Two cycles of CYVADIC chemotherapy were given, and the local recurrence lesions clearly shrank. In June 2009, three cycles of additional CYVADIC chemotherapy were given because of a lung metastasis and in December 2009 another cycle of CYVADIC chemotherapy was given because of pleural dissemination and mediastinum recurrence. In February 2010 the patient developed obstructive jaundice due to pancreatic metastasis, and endoscopic retrograde drainage was performed. Despite another five cycles of CYVADIC chemotherapy being given, the tumor progressed, and in July 2010 the patient died because of the progression of the metastases (Fig. 3).

## Discussion

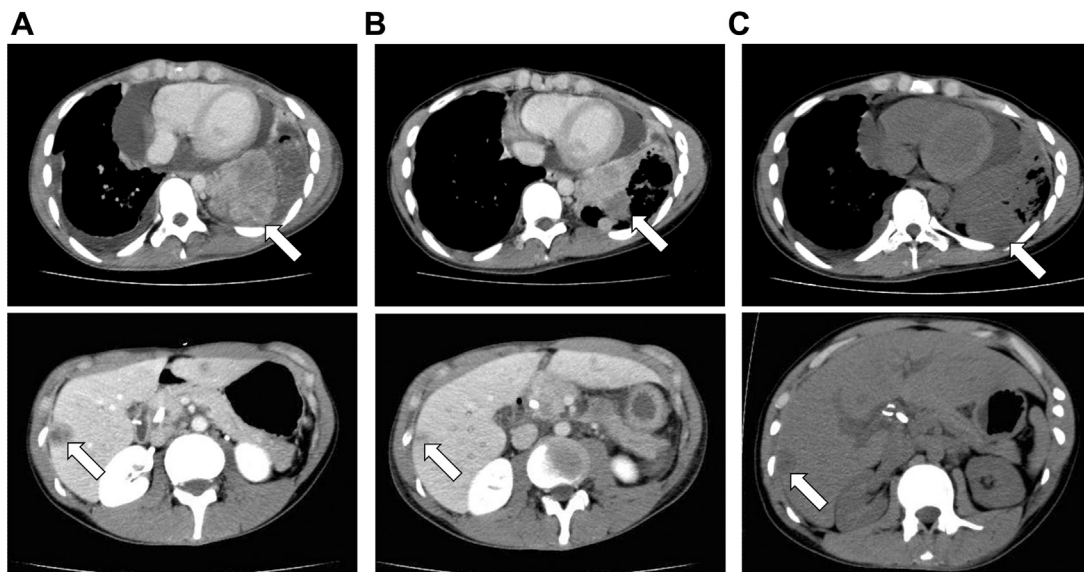
RMS is the most common type of soft tissue sarcoma in the first 2 decades of life.<sup>1</sup> The Intergroup Rhabdomyosarcoma Study Group (IRSG) staging system separates patients by site of the primary tumor, tumor size and the presence or absence of tumor-involved regional lymph nodes and distant metastases.<sup>1</sup> The presence of metastatic disease is the strongest predictor of clinical outcomes in patients with RMS. The treatment outcome for patients with distant metastases at diagnosis is extremely poor.<sup>2</sup> Even with aggressive multimodal treatments only 27% are expected to be event-free 3

years after diagnosis, and the overall survival (OS) at 3 years is only 34%.<sup>2</sup> Oberlin et al reported that several patient characteristics contributed significantly to poor event-free survival in patients with metastases: presence of bone metastases, age of 10 years old or more, and presence of three or more metastatic sites.<sup>2</sup> OS at 3 years is also influenced significantly by number of metastatic sites. When the patient has 4 or more metastatic sites at diagnosis as the present case, 3 year OS is less than 15%.<sup>3</sup>

Approximately 15% of children and adolescence with RMS present with metastatic disease, and their prognosis has not improved significantly over the last 15 years.<sup>3</sup> There is no standard treatment for high-risk patients. Although a recent clinical trial using ifosfamide, etoposide, vincristine, doxorubicin, cyclophosphamide, irinotecan and radiation was conducted, high-risk patients had a 3 year OS of 14%.<sup>4</sup> In this case, we used a CYVADIC chemotherapy shown to be effective against soft tissue sarcomas.<sup>5</sup> The patient was able to undergo a total of 17 cycles of CYVADIC chemotherapy and the tumor growth could be controlled for 4 years so that his quality of life was maintained (i.e., he was admitted to a university and could study even during the treatments). Although CYVADIC chemotherapy is thus considered to be useful against high-risk paratesticular RMS, it is not a curative regimen. Finding a novel effective therapy against advanced RMS will require further investigations.



**Figure 2.** Pathological findings and CT after five cycles of CYVADIC chemotherapy. Macroscopic image of the surgically resected specimen (A). Microscopic examination showed embryonal rhabdomyosarcoma composed of round to spindle-shaped cells having scanty cytoplasm and high mitotic activity (B). CT showed a complete response after five cycles of CYVADIC chemotherapy (C).



**Figure 3.** CT at the tumor progression despite CYVADIC chemotherapy. CT revealed that the tumor progressed in February 2010 (A, arrows), shrank after CYVADIC chemotherapy in April (B, arrows) and again progressed despite additional chemotherapy in July (C, arrows).

## Conclusion

We experienced a case in which treating metastatic paratesticular RMS with a multimodal therapy including 17 cycles of CYVADIC chemotherapy resulted in relatively long-term survival.

## Consent

Written informed consent was obtained from the patient's father for publication of this case report.

## Conflict of interest

We have no conflict of interest to declare.

## References

1. Raney RB, Maurer HM, Anderson JR, et al. The Intergroup Rhabdomyosarcoma Study Group (IRSG): major lessons from the IRS-I through IRS-IV studies as background for the current IRS-V treatment protocols. *Sarcoma*. 2001;5:9–15.
2. Oberlin O, Rey A, Lyden E, et al. Prognostic factors in metastatic rhabdomyosarcomas: results of a pooled analysis from United States and European cooperative groups. *J Clin Oncol*. 2008;26:2384–2389.
3. Breneman JC, Lyden E, Pappo AS, et al. Prognostic factors and clinical outcomes in children and adolescents with metastatic rhabdomyosarcoma—a report from the Intergroup Rhabdomyosarcoma Study IV. *J Clin Oncol*. 2003;21:78–84.
4. Weigel BJ, Lyden E, Anderson JR, et al. Intensive multiagent therapy, including dose-compressed cycles of ifosfamide/etoposide and vincristine/doxorubicin/cyclophosphamide, irinotecan, and radiation, in patients with high-risk rhabdomyosarcoma: a report from the Children's Oncology Group. *J Clin Oncol*. 2016;34:117–122.
5. Gottlieb JA, Benjamin RS, Baker LH, et al. Role of DTIC (NSC-45388) in the chemotherapy of sarcomas. *Cancer Treat Rep*. 1976;60:199–203.