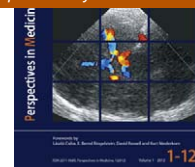

ELSEVIER
URBAN & FISCHERBartels E, Bartels S, Poppert H (Editors):
New Trends in Neurosonology and Cerebral Hemodynamics – an Update.
Perspectives in Medicine (2012) 1, 404–407journal homepage: www.elsevier.com/locate/permed

B-mode sonography of the optic nerve in neurological disorders with altered intracranial pressure

Jochen Bäuerle*, Max Nedelmann

Department of Neurology, Justus-Liebig-University, Giessen, Germany

KEYWORDS

Optic nerve sheath diameter;
Optic nerve sonography;
Traumatic brain injury;
Idiopathic intracranial hypertension;
Spontaneous intracranial hypotension

Summary B-mode sonography of the optic nerve is a promising new technique in the field of neurology. It may serve as an additional diagnostic tool in different diseases with altered intracranial pressure. The aim of this article is to give an overview on this technique and on its possible clinical applications.

© 2012 Elsevier GmbH. Open access under [CC BY-NC-ND license](http://creativecommons.org/licenses/by-nc-nd/4.0/).

Introduction

Over the past few decades the sonographic investigation of the eye and the adjacent structures in the orbit has become an important and well established tool in ophthalmology. It is crucial in the clinical work-up of patients suffering from a wide variety of ocular and orbital disorders.

Additionally, a growing body of literature demonstrates the usefulness of transbulbar B-mode sonography of the optic nerve for detecting raised intracranial pressure (ICP) in patients requiring neurocritical care. Therefore,

neurologists increasingly take interest in this non-invasive and cost-effective bedside method. Even today ICP assessment continues to be a challenging task in critical care medicine. Invasive devices remain the cornerstone for measuring ICP in comatose or sedated patients but may not always be feasible due to a lack of neurosurgeons or contraindications such as coagulopathy or thrombocytopenia. Noninvasively, evaluation of pressure elevation relies on clinical symptoms or repeated CT or MR scanning to monitor for complications of raised ICP.

As part of the central nervous system the optic nerve is surrounded by cerebrospinal fluid and by meninges designated as optic nerve sheath. Hayreh shed light on the communication between the intracranial cerebrospinal fluid spaces and the subarachnoid space of the optic nerve sheath [1]. In his investigations in rhesus monkeys he described the development of papilledema in different situations of elevated ICP. Helmke and Hansen confirmed that ICP changes have an influence on the optic nerve sheath diameter (ONSD) [2]. In intrathecal infusion tests they found that the

Abbreviations: ICP, intracranial pressure; ONSD, optic nerve sheath diameter; IIH, idiopathic intracranial hypertension; CSF, cerebrospinal fluid.

* Corresponding author at: Department of Neurology, University of Freiburg, Breisacher Straße 64, D-79106 Freiburg, Germany. Tel.: +49 761 27053060; fax: +49 761 27053100.

E-mail address: jochenbaeuerle@gmx.de (J. Bäuerle).

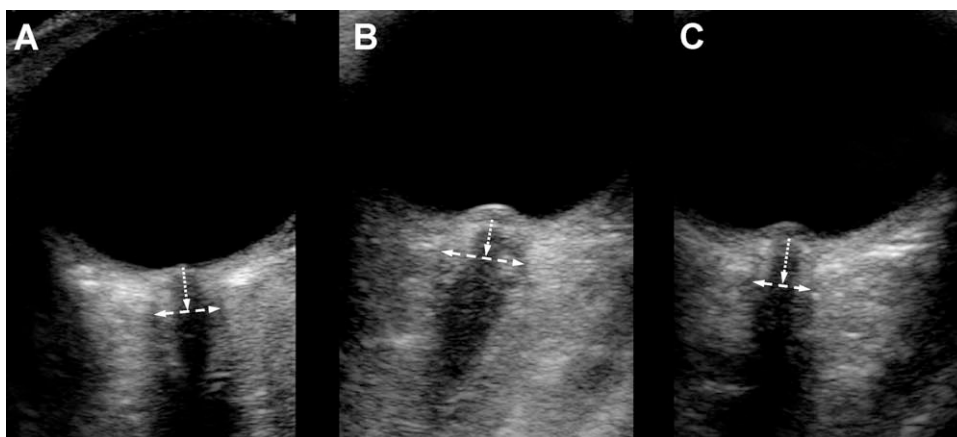


Figure 1 ONSD in IIH before and after lumbar puncture. (A) ONSD is measured 3 mm behind the base of the papilla (dotted arrow) in an axial plane showing the optic nerve in its longitudinal course. The dashed arrow denotes the ONSD. The picture for this figure was obtained from a healthy adult. Panel B shows the optic nerve sheath in a patient suffering from IIH. After lumbar puncture with therapeutic removal of CSF a normalization of the ONSD into the normal range could be observed without an apparent change of the optic disk elevation (C).

sonographic ONSD assessment is not suitable to evaluate exact ICP values, but may be used as surrogate variable of raised ICP. In contrast to the evolution of papilledema, ONSD changes correlated well with short-term ICP variations. This has been recently reproduced in an ultrasound-based study on brain injured patients [3]. Moreover, Helmke and Hansen developed a standardized transbulbar sonography technique for measuring the ONSD [4,5].

Transbulbar sonography

In our ultrasound laboratory we use a 9–3 MHz linear array transducer for transbulbar sonography of the optic nerve. Patients are examined in supine position with the upper part of the body and the head elevated to 20–30°. For safety reasons of biomechanical side effects we reduce the mechanical index to 0.2. The probe is placed on the temporal part of the closed upper eyelid using a thick layer of ultrasound gel. The retrobulbar part of the optic nerve can be depicted in an axial plane showing the papilla and the optic nerve in its longitudinal course. By convention the ONSD is assessed 3 mm behind the papilla. In order to gauge the ONSD, the distance between the external borders of the hyperechoic area surrounding the optic nerve should be quantified (Fig. 1).

Several studies reproduced a high intra- and interobserver reliability of the sonographic ONSD assessment [6–8]. However, data on normal values vary considerably, especially in former publications [9]. This may be explained by differing ultrasound equipments and their influence on sonographic findings and measurement criteria different from the ones stated above. Therefore, several authors emphasized the necessity of correctly used measuring points and clearly displayed optic nerve structures for reliable results [10,11].

In our study on this topic, using above criteria, the mean ONSD was 5.4 ± 0.6 mm in healthy adults that matches closely with results derived from two MRI studies [7]. Rohr et al. found a value of 5.3 ± 0.6 mm in patients with mental disorders but without intracranial lesions or signs of

elevated ICP [12]. Geeraerts et al. indicated a mean ONSD of 5.1 ± 0.5 mm in healthy volunteers [13]. Accordingly, a cadaver study illustrated a good correlation between the evaluation of the ONSD by MRI and transbulbar sonography. Despite the unfavorable angle between the course of the optic nerve and the insonation direction in transbulbar sonography Steinborn et al. observed an acceptable agreement between MRI and the sonographic approach [11]. These results have been verified in an investigation of sixty-five children, recently [10].

Neurocritical care

In comatose or sedated patients with intracranial bleeding and traumatic head injury sonographic ONSD evaluation has been proven to be feasible in predicting raised ICP [3,14,15]. An MRI-based investigation confirmed this observation [13]. Geeraerts et al. found a mean ONSD of 6.3 ± 0.6 mm in brain injured adults using sonography [14]. By means of MRI they indicated a mean ONSD of 6.3 ± 0.5 mm [13]. The threshold of ONSD predicting an elevated ICP was proposed to be between 5.7 and 5.9 mm [3,13–15]. In a metaanalysis of six studies with data on a total of 231 patients with traumatic brain injury or intracranial hemorrhage the technique had a sensitivity of 90% and a specificity of 85% [16].

Furthermore, transbulbar ONSD assessment has been suggested for follow-up examinations of children with internal hydrocephalus and ventriculoperitoneal shunt systems [17]. Moreover, two sonographic investigations observed a correlation between the severity of acute mountain sickness and ONSD [18,19].

Idiopathic intracranial hypertension

Only few results were published on the sonographic ONSD evaluation in idiopathic intracranial hypertension (IIH) [20]. One MRI based retrospective study described a mean ONSD of 6.5 ± 0.9 mm in patients suffering from IIH and quote a cut-off value for raised ICP of 5.8 mm [21].

In a prospective study we examined the ONSD in ten adults with newly diagnosed IIH by transbulbar sonography before and after lumbar puncture [22]. Patients were recruited according to the updated diagnostic criteria of IIH and papilledema was documented in all subjects by an ophthalmological examination including funduscopy. Twenty-five individuals with other neurological disorders served as controls. Sonographic evaluation of the optic nerve was possible in all participants.

Compared to controls the ONSD was significantly enlarged among patients with IIH bilaterally [6.4 ± 0.6 mm vs. 5.4 ± 0.5 mm]. After lumbar puncture with a therapeutic removal of 30–50 ml of CSF we observed a significant decrease of the ONSD on both sides (right ONSD 5.8 ± 0.7 mm, left ONSD 5.9 ± 0.7 mm) (Fig. 1). However, in some patients with IIH, the ONSD was not altered or only slightly altered, e.g. a decline of 0.4 mm or more was only documented in five individuals. This may possibly be related to findings of a defective CSF circulation in the optic nerve sheath in this disorder, a state that is referred to as optic nerve compartment syndrome [23]. The ROC curve analysis revealed an optimal cut-off value for predicting raised ICP of 5.8 mm with a sensitivity of 90% and a specificity of 84%. The mean optic disk elevation in subjects with IIH was 1.2 ± 0.3 mm. Nevertheless, one patient showed no evidence of optic disk elevation in transbulbar sonography but had signs of papilledema in funduscopy. Corresponding to previous studies, we found no decrease of the optic disk elevation after lumbar puncture in the observation period of 24 h.

As a result sonographic ONSD evaluation may be useful in detecting raised ICP in patients with presumed IIH. Furthermore, our data suggest a potential usefulness of this technique for monitoring of treatment effects. In addition, ONSD values and optic disk levels were slightly asymmetric, reflecting the complex anatomy of the subarachnoid space of the optic nerve and its possible influence on the cerebrospinal fluid dynamics. For this reason we recommend that each eye should be evaluated separately and mean ONSD values should be designated for both eyes.

Intracranial hypotension

Predominantly, the relationship of ONSD alterations and ICP changes was verified in clinical situations with raised ICP. One case series and one prospective study investigated the ONSD in spontaneous intracranial hypotension [24,25]. Examining the orbit with T2-weighted MRI techniques, they observed a collapsed optic nerve sheath.

Dubost et al. published an ultrasound study on ten patients with postdural puncture headache after lumbar puncture or epidural anesthesia [26]. Consistent with the mentioned MRI-results a small ONSD of 4.8 mm was detected before treatment. After successful therapy with a lumbar epidural blood patch a marked enlargement of the ONSD was found. Accordingly, in one patient in whom the intervention failed to resolve the headache they recorded no ONSD distension.

Recently, we examined a patient with spontaneous intracranial hypotension due to a cervical cerebrospinal fluid leakage in our ultrasound laboratory [27]. On admission

transbulbar sonography revealed reduced ONSD of 4.1 mm on the right and 4.3 mm on the left side. After failure of medical treatment three consecutive targeted epidural blood patches were performed and a gradual extension of the ONSD was observed in both optic nerves [right 5.2 mm, left 5.3 mm]. In this article we documented changes of ONSD that were in line with initial clinical improvement and secondary worsening under conservative treatment and final improvement after occlusion of the cervical CSF leakage.

Limitations

Many studies on normal values found a relatively wide interindividual range of ONSD measurements [7,9,12]. Thus, as described previously absolute measurements of ICP will not be possible by transbulbar sonography [2]. Furthermore, with a false-negative rate of approximate 10%, ONSD values should only be interpreted in conjunction with clinical data and neuroimaging results.

Killer et al. found a decreased CSF circulation along the optic nerve in patients with IIH that seems to be a consequence of the complex trabecular architecture of the subarachnoid space of the optic nerve [23]. They proposed a compartment syndrome of the optic nerve sheath in sustained ICP elevation, as in IIH. In addition, Hayreh described varying degrees of communication between the intracranial subarachnoid space and the optic nerve sheath in different individuals [1]. This variety of the optic nerve sheath compliance and CSF fluid dynamics may limit the sonographic ONSD assessment in its value, especially for follow-up examinations, but on the other hand, may possibly allow to identify individual patients with continuing optic nerve compression albeit therapeutic lumbar puncture. Thus, studying long-term changes of the ONSD in different neurological disorders may be an interesting issue of future investigations.

With respect to the high variation of normal ONSD values published it is urgently necessary to determine consistent sonographic data in larger multicenter studies.

Conclusion

In summary, as a noninvasive and cost-effective bedside method transbulbar B-mode sonography is a promising technique for clinical neurologists. It may serve as an additional tool in neurocritical care medicine for detection of raised ICP. The method is of particular interest in situations when invasive ICP monitoring is contraindicated or when the expertise for invasive monitor placement is not immediately available.

Furthermore, it aids in the diagnostic work-up and in the follow-up of patients with IIH and in conditions of decreased ICP.

References

- [1] Hayreh SS. Pathogenesis of oedema of the optic disc (papilloedema). A preliminary report. *Br J Ophthalmol* 1964;48:522–43.
- [2] Hansen HC, Helmke K. Validation of the optic nerve sheath response to changing cerebrospinal fluid pressure: ultrasound findings during intrathecal infusion tests. *J Neurosurg* 1997;87(1):34–40.

- [3] Geeraerts T, Merceron S, Benhamou D, Vigue B, Duranteau J. Non-invasive assessment of intracranial pressure using ocular sonography in neurocritical care patients. *Intensive Care Med* 2008;34(11):2062–7.
- [4] Helmke K, Hansen HC. Fundamentals of transorbital sonographic evaluation of optic nerve sheath expansion under intracranial hypertension. I. Experimental study. *Pediatr Radiol* 1996;26(10):701–5.
- [5] Helmke K, Hansen HC. Fundamentals of transorbital sonographic evaluation of optic nerve sheath expansion under intracranial hypertension. II. Patient study. *Pediatr Radiol* 1996;26(10):706–10.
- [6] Ballantyne SA, O'Neill G, Hamilton R, Hollman AS. Observer variation in the sonographic measurement of optic nerve sheath diameter in normal adults. *Eur J Ultrasound* 2002;15(3):145–9.
- [7] Bäuerle J, Lochner P, Kaps M, Nedelmann M. Intra- and inter-observer reliability of sonographic assessment of the optic nerve sheath diameter in healthy adults. *J Neuroimaging* 2012;22(1):42–5.
- [8] Shah S, Kimberly H, Marill K, Noble VE. Ultrasound techniques to measure the optic nerve sheath: is a specialized probe necessary? *Med Sci Monit* 2009;15(5):63–8.
- [9] Lagreze WA, Lazzaro A, Weigel M, Hansen HC, Hennig J, Bley TA. Morphometry of the retrobulbar human optic nerve: comparison between conventional sonography and ultrafast magnetic resonance sequences. *Invest Ophthalmol Vis Sci* 2007;48(5):1913–7.
- [10] Steinborn M, Fiegler J, Ruedisser K, Hapfelmeier A, Denne C, Macdonald E, et al. Measurement of the optic nerve sheath diameter in children: comparison between transbulbar sonography and magnetic resonance imaging. *Ultraschall Med* 2011 [Epub ahead of print].
- [11] Steinborn M, Fiegler J, Kraus V, Denne C, Hapfelmeier A, Wurzinger L, et al. High resolution ultrasound and magnetic resonance imaging of the optic nerve and the optic nerve sheath: anatomic correlation and clinical importance. *Ultraschall Med* 2010 [Epub ahead of print].
- [12] Rohr A, Riedel C, Reimann G, Alfke K, Hedderich J, Jansen O. Pseudotumor cerebri: quantitative in vivo measurements of markers of intracranial hypertension. *Rofo* 2008;180(10):884–90.
- [13] Geeraerts T, Newcombe VF, Coles JP, Abate MG, Perkes IE, Hutchinson PJ, et al. Use of T2-weighted magnetic resonance imaging of the optic nerve sheath to detect raised intracranial pressure. *Crit Care* 2008;12(5):R114.
- [14] Geeraerts T, Launey Y, Martin L, Pottecher J, Vigue B, Duranteau J, et al. Ultrasonography of the optic nerve sheath may be useful for detecting raised intracranial pressure after severe brain injury. *Intensive Care Med* 2007;33(10):1704–11.
- [15] Soldatos T, Karakitsos D, Chatzimichail K, Papatheasiou M, Gouliamos A, Karabinis A. Optic nerve sonography in the diagnostic evaluation of adult brain injury. *Crit Care* 2008;12(3):R67.
- [16] Dubourg J, Javouhey E, Geeraerts T, Messerer M, Kassai B. Ultrasonography of optic nerve sheath diameter for detection of raised intracranial pressure: a systematic review and meta-analysis. *Intensive Care Med* 2011;37(7):1059–68.
- [17] Brzezinska R, Schumacher R. Diagnosis of elevated intracranial pressure in children with shunt under special consideration of transglobe sonography of the optic nerve. *Ultraschall Med* 2002;23(5):325–32.
- [18] Sutherland AI, Morris DS, Owen CG, Bron AJ, Roach RC. Optic nerve sheath diameter, intracranial pressure and acute mountain sickness on Mount Everest: a longitudinal cohort study. *Br J Sports Med* 2008;42(3):183–8.
- [19] Fagenholz PJ, Gutman JA, Murray AF, Noble VE, Camargo Jr CA, Harris NS. Optic nerve sheath diameter correlates with the presence and severity of acute mountain sickness: evidence for increased intracranial pressure. *J Appl Physiol* 2009;106(4):1207–11.
- [20] Galetta S, Byrne SF, Smith JL. Echographic correlation of optic nerve sheath size and cerebrospinal fluid pressure. *J Clin Neuroophthalmol* 1989;9(2):79–82.
- [21] Degnan AJ, Levy LM. Narrowing of Meckel's cave and cavernous sinus and enlargement of the optic nerve sheath in Pseudotumor cerebri. *J Comput Assist Tomogr* 2011;35(2):308–12.
- [22] Bäuerle J, Nedelmann M. Sonographic assessment of the optic nerve sheath in idiopathic intracranial hypertension. *J Neuro* 2011;258(11):2014–9.
- [23] Killer HE, Jaggi GP, Flammer J, Miller NR, Huber AR, Mironov A. Cerebrospinal fluid dynamics between the intracranial and the subarachnoid space of the optic nerve. Is it always bidirectional? *Brain* 2007;130:514–20.
- [24] Rohr A, Jensen U, Riedel C, van Baleen A, Fruehauf MC, Bartsch T, et al. MR imaging of the optic nerve sheath in patients with craniocervical hypotension. *AJNR* 2010;31(9):1752–7.
- [25] Watanabe A, Horikoshi T, Uchida M, Ishigame K, Kinouchi H. Decreased diameter of the optic nerve sheath associated with CSF hypovolemia. *AJNR* 2008;29(5):863–4.
- [26] Dubost C, Le GA, Zetlaoui PJ, Benhamou D, Mercier FJ, Geeraerts T. Increase in optic nerve sheath diameter induced by epidural blood patch: a preliminary report. *Br J Anaesth* 2011;107(4):627–30.
- [27] Bäuerle J, Gizewski ER, Stockhausen KV, Rosengarten B, Berghoff M, Grams AE, et al. Sonographic assessment of the optic nerve sheath and transorbital monitoring of treatment effects in a patient with spontaneous intracranial hypotension: case report. *J Neuroimaging* 2011, doi:10.1111/j.1552-6569.2011.00640.x.