



Contents lists available at ScienceDirect

Trauma Case Reports

journal homepage: www.elsevier.com/locate/tcr



Case Report

Simultaneous bilateral femoral neck fracture in a patient with renal osteodystrophy

Anderson Freitas*, Silvio Leite de Macedo Neto,
Fabiano Bolpato Loures, Eugênio dos Santos Neto,
Leonardo Coelho de Alencar Barreto, Maurício Siqueira Camilo

Hospital Ortopédico e Medicina Especializada (HOME), SGAS Quadra 613 Conjunto C, 70200-730 Brasília, DF, Brazil

ARTICLE INFO

Article history:

Accepted 28 May 2016

Available online 18 June 2016

Keywords:

Bilateral

Femoral neck fracture

Renal osteodystrophy

ABSTRACT

We present a unique case of displaced simultaneous bilateral fractures, Garden 3 type, in a 49 year woman treated with non-cemented total hip arthroplasty. The patient showed a Harris hip score of 86 on the right hip and a 81 on the left side on the fourth postoperative year, besides a bilateral Trendelenburg gait, more pronounced on the right side. She needed a cane to walk, and felt pain in the left thigh. The X-ray showed a shortening of 0.9 cm and a left femoral varus. The other arthroplasty components showed good osseointegration and position.

We found that the use of the uncemented total hip arthroplasty to treat a simultaneous bilateral fracture in renal osteodystrophy patients has satisfactory results at a four year follow-up.

According to the OCEBM Levels of Evidence Working Group, this study is graded as a Level of Evidence IV.

© 2016 The Authors. Published by Elsevier Inc. This is an open access article under the CC BY-NC-ND license

(<http://creativecommons.org/licenses/by-nc-nd/4.0/>).

Introduction

Cases of bilateral simultaneous fracture of the femoral neck due to electric shock or epileptic episodes have already been well described [1–3]. However, such condition as a consequence of renal osteodystrophy is rare and has few reports [4,5], especially when treated with uncemented total arthroplasty. The chronic kidney dialysis (CKD) patients have usually poor bone quality and present a high rate of complications during treatment of femoral neck fracture by osteosynthesis [5]. The outcomes are not different for treatment by

* Corresponding author. Tel.: +55 61 3878 2878.

E-mail address: andfreitas28@gmail.com (A. Freitas)

arthroplasty, since there are high rates of early aseptic cemented or non-cemented implant loosening [6], a fact that represents a relevant question upon defining the surgery technique to be used. In this situation, describing a case of spontaneous and simultaneous bilateral fracture, treated with non-cemented total hip replacement, can help define conduct in similar cases.

Case report

A 49 year old, chronic renal diseased female patient, on regular dialysis for 15 years, with major complaints of pain in both hips, reported sudden pain in the hip when trying to wear her pants by standing on her right single leg. It came to a fall on the ground and the impossibility of moving both hips. She was brought to the emergency room complaining of severe pain and immobility of both hips. We performed the scrolling test of the lower limbs that denoted an important aggravation of the pain. The X-ray revealed a fracture on both femoral necks and very poor bone quality, which prevented a proper assessment of the fracture. The CT scan of the pelvis clearly showed the presence of displaced fracture (Garden 3) on both femoral necks (Fig. 1A, B). In her preoperative preparation, we noticed significant changes in leukocyte levels and red series, besides clinical repercussions of heart failure, a fact that delayed her release to surgery. Hypocalcemia (6.8 mg/dL; normal level, 8.4–10.5 mg/dL) was also noticed, as well as elevated levels of parathyroid

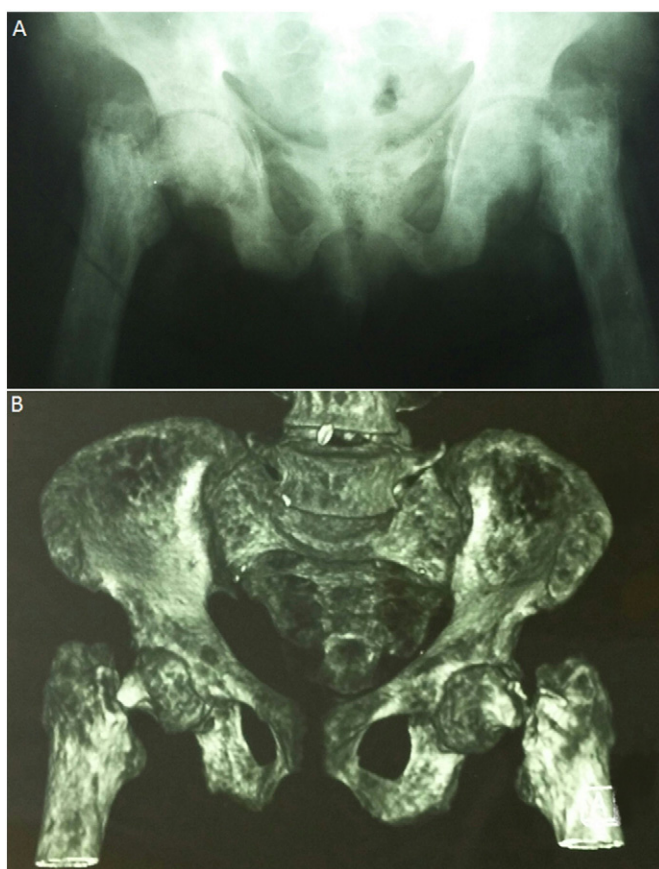

Fig. 1. (A) X-ray images showing poor bone quality and deformity on both hips; (B) computed tomography image of the pelvis clearly demonstrating displaced fractures of both femoral necks.

hormone, characterising a secondary hyperparathyroidism. Hemodialysis was maintained, as in her previous routine, on alternate days.

By day four of her admittance, after clinical stabilisation, we requested a pelvic MRI in order to assess the vascular viability of femoral heads, considering the elapsed time after trauma and the deviation of the fracture. The exam denoted necrotic areas on both femoral heads, (Fig. 2) leading us to indicate total hip arthroplasty procedures in both hips. Bilateral hip replacement was scheduled, and the use or not of cement would be determined by the bone quality and adaptation of the implants.

The surgical technique we used on the right hip included a Kocher Langenbeck (KL) approach with the patient in the left lateral decubitus. Depending on the clinical evolution of the patient during surgery, a change to the right decubitus would be made to proceed with the left hip replacement through an identical access. Since the evolution of the patient was favorable, we chose to exchange all surgical instruments at the time of decubitus change.

Surgical time was counted from primary access to final skin suture. The volume of blood loss was estimated as follows: difference of pack weights before and after use added to the volume obtained in the vacuum container and subtracted from the volume of saline used for cleaning the surgical wound during surgery.

In the right hip surgery, there were no access difficulties. Preparation of acetabulum and femur occurred likewise, with major bleeding during these surgical steps. We used a 50 mm acetabular component, impregnated with hydroxyapatite, with a good press fit and a metaphyseal fixation femoral component, also impregnated with hydroxyapatite with good bone occupation intraoperatively observed by fluoroscopy. It was difficult to obtain perfect centering of this component, which presented a slight varus, due to a deformed, arched, femur. Surgery lasted 53 min and there was a blood loss of approximately 750 mL. Transfusion with two units of red blood cell concentrates was indicated. There were no significant changes in clinical parameters, a fact that lead us to proceed with the left hip surgery, as planned.

The left side approach and preparation occurred with the same degree of difficulty than the right side, with similar bleeding volume, same implant dimensions and characteristics as the right side. We observed good acetabular accommodation and the same difficulty in centralising the femoral component. Surgery lasted

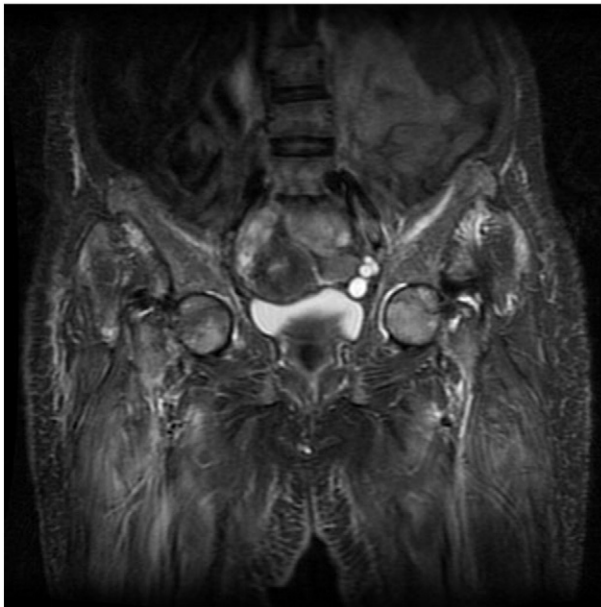


Fig. 2. Magnetic resonance image showing necrotic area in both femoral heads.

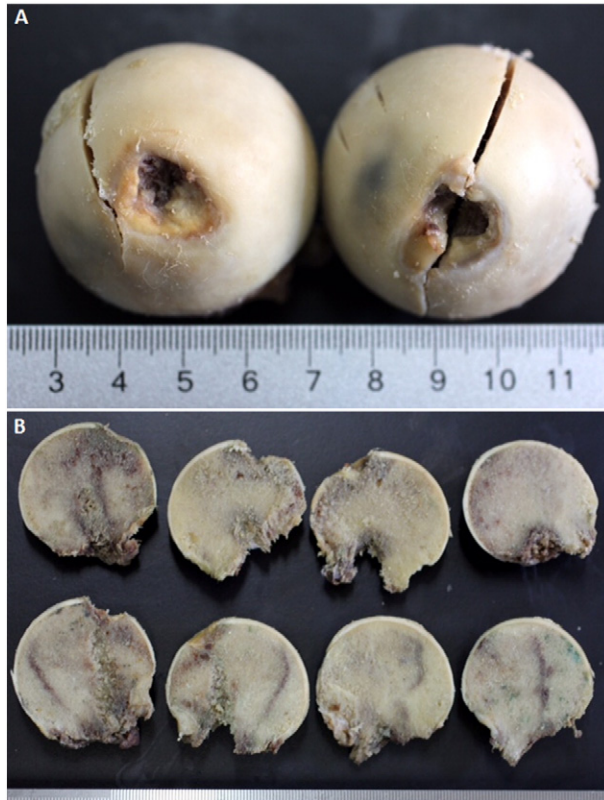

Fig. 3. (A) Picture of the femoral heads in position, according to each side. (B) (Upper) Slices of the femoral head to the left; (lower) slices of the femoral head to the right, both featuring extensive areas of necrosis.

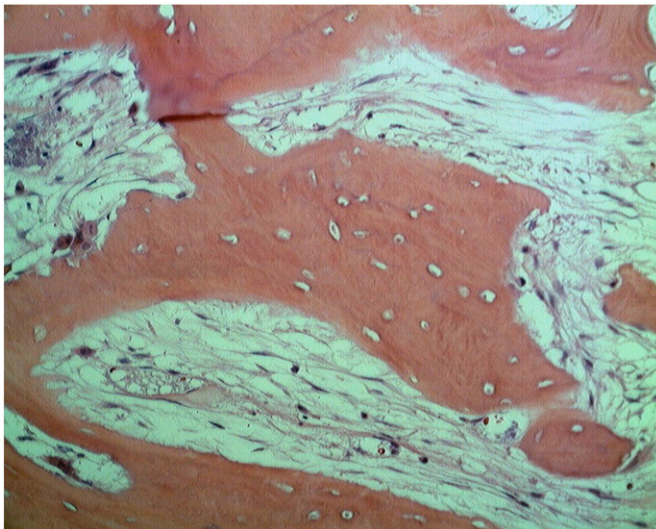


Fig. 4. Histological slide showing a bone trabeculae devoid of periosteum and osteocytes with loss of nuclear basophilia and empty lacuna featuring coagulative necrosis (400× HE).

for 58 min and blood loss was of 800 mL. After surgery, hematocrit was 26% and hemoglobin 8.2 g/dL. Since the patient presented low blood pressure and increased cardiac frequency we started transfusion of two units of red blood cell concentrates.

The tribological pair used in both surgeries was ceramic and cross-linked polyethylene. Femoral heads were evaluated macro and microscopically. Large necrotic areas were observed in both femoral heads (Fig. 3A, B), which were confirmed in the microscopic assessment (Fig. 4).

The postoperative period occurred in the intensive care unit. Hemodialysis was needed on the night of the surgery due to alteration of kidney function. On the first postoperative day we started active and passive physical therapy in bed, which was well tolerated by the patient. On the second postoperative day the suction drains were removed from both sides. The volume contained in both recipients was approximately 250 mL. Deambulation was allowed at the bedside, assisted by a walker. Patient had no complaints but it required her much effort.

During the seven days of hospitalisation we administered intravenously 3rd generation cephalosporin 1 g every 8 h and low molecular weight subdermal heparin 40 mg/day for 30 days. The patient, however, was advised not to use the same class of drugs during dialysis. Motor physical therapy was maintained and gait showed improvement after 15 days, when deambulation was allowed with two crutches. After 45 days, one of the crutches was removed, keeping that on left side. The patient was able to make short displacement with no cane but without precision, a characteristic that remains to the present day. Clinical stability, better gait and mobility were observed after 6 months of surgery. These standards remain unchanged at present.

After a 4 year follow-up, the Harris hip score was 86 (good) on the right hip and 81 (good) on the left hip, with bilateral Trendelenburg gait, more pronounced to the right. The patient complained of pain on the middle third of the left thigh, without functional loss. The X-ray showed 0.9 cm distal migration of the left femoral component and increased varus when compared to previous exams. Besides that, there was good osseointegration of the acetabular components with no signs of osteolysis and no change of the right femoral component (Fig. 5).

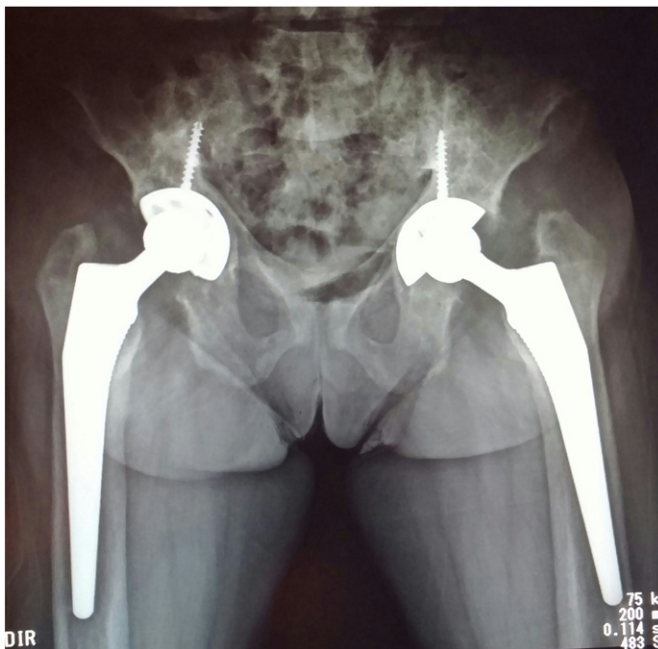

Fig. 5. X-ray image showing the absence of osteolysis, good osseointegration of prosthetic components to the right and acetabular components to the left, with migration of the femoral component and increased left femoral varus.

Discussion

Hip fracture in the elderly is considered a public health issue worldwide [7,8]. Increased mortality and morbidity, besides increased treatment costs, with very poor results have been described [6,9]. There are few reports in the literature that assess the results and costs of this condition in chronic kidney dialysis patients.

Patients with chronic kidney disease present risk factors for this type of fracture. Major bone fragility and its consequences are caused by renal osteodystrophy (primarily caused by secondary hyperparathyroidism and 1,25-dihydroxycholecalciferol deficiency) associated with increased cytokines that promote the disruption of the bone microarchitecture, such as interleukins 1, 6 and 11, and α tumor necrosis factor [10].

Garden type 3 femoral neck fractures treated with osteosynthesis, as proven by the case here described, show high rate of complications in chronic renal patients [5]. The decision for bilateral prosthesis in one or two stages is justified by anesthesia and clinical parameters and depends on a less aggressive surgical technique [7,10].

Sakalkale and coworkers performed cemented total hip arthroplasty in chronic kidney disease patients on dialysis and observed high mortality rates (58%) and high rate of early complications (58%) in 132 months follow-up. Their study, which included 10 arthroplasties, six cemented, three uncemented and one hybrid, showed one acetabular component loosening in a cemented arthroplasty, one acetabular component loosening after graft failure in non-cemented procedure and a good stability in the hybrid procedure [6].

It's well known that the patients with chronic kidney disease have alteration of the bone microarchitecture, being prejudicial to cement interdigitating and one advantage of using non-cemented technique in this case was that the effect of cementation on the cardiovascular system was avoided, preventing hemodynamic complications during the procedure.

An improvement of the results with uncemented implants in chronic kidney dialysis patients is expected with improvement of design and materials used in the manufacture of non-cemented hip arthroplasty components and trabecular metal arthroplasty components. Therefore, clinical trials are needed to confirm this fact.

Conflict of interest

The authors declare that they have no conflict of interest.

Ethical standards

The patient gave informed consent to the publication of the case study.

References

- [1] A. Freitas, H.I. da Costa, B.A.S. Azevedo, J.S. de Oliveira, Simultaneous bilateral fractures of the femoral neck, *Curr. Orthop. Pract.* 26 (1) (2015) 75–77.
- [2] M.M. Rahman, A. Adnan, Bilateral simultaneous hip fractures secondary to an epileptic seizure, *Saudi Med. J.* 24 (11) (2003) 1261–1263.
- [3] H.S. Sohal, G. Darsh, Simultaneous bilateral femoral neck fractures after electrical shock injury: a case report, *Clin. J. Traumatol.* 16 (2) (2013) 126–128.
- [4] F.L. Garcia, R.B. Dalio, A.T. Sogo, C.H.F. Picado, Bilateral spontaneous fracturing of the femoral neck in a patient with renal osteodystrophy, *Rev. Bras. Ortop.* 49 (5) (2014) 540–542.
- [5] G. Mataliotakis, M.G. Lykissas, A.N. Mavrodontidis, V.A. Kontogeorgakos, A.E. Beris, Femoral neck fractures secondary to renal osteodystrophy. Literature review and treatment algorithm, *J. Musculoskelet. Neuronal Interact.* 9 (3) (2009) 130–137.
- [6] D.P. Sakalkale, W.J. Hozack, R.H. Rothman, Total hip arthroplasty in patients on long-term renal dialysis, *J. Arthroplast.* 14 (5) (1999) 571–575.
- [7] T.S. Wei, C.H. Hu, S.H. Wang, K.L. Hwang, Fall characteristics, functional mobility and bone mineral density as risk factors of hip fracture in the community-dwelling ambulatory elderly, *Osteoporos. Int.* 12 (2001) 1050–1055.
- [8] S.R. Cummings, L.J. Melton, Epidemiology and outcomes of osteoporotic fractures, *Lancet* 359 (2002) 1761–1767.
- [9] F.B. Loures, A. Chaoubah, V.S. Maciel, E.P. Paiva, P.P. Salgado, A.C. Netto, Custo-efetividade do tratamento cirúrgico de fratura do quadril em idosos no Brasil, *Rev. Bras. Ortop.* 50 (1) (2015) 38–42.
- [10] K.A. Hruska, L.T. Steven, Renal osteodystrophy, *N. Engl. J. Med.* 333 (3) (1995) 166–175.