

Radiology Case Reports

Volume 8, Issue 3, 2013

Successful use of Onyx® for transcatheter arterial embolization of a scrotal arteriovenous malformation refractory to traditional embolic agents

Ryan Key, BS, and Thomas Bishop, MD

A scrotal arteriovenous malformation (AVM) is a rare condition representing an abnormal connection between the arterial and venous systems of vessels supplying the scrotum. Scrotal AVMs are usually treated via transcatheter embolization, surgical extirpation, or a combination of the two approaches. A 41-year-old man developed a life-threatening hemorrhage from a scrotal AVM. After hemodynamic stability was attained, multiple transcatheter embolization procedures were performed (over the course of several months) to eliminate blood flow through the AVM. Traditional embolic agents including microcoils, Embospheres®, and Gelfoam® were used, with only temporary reduction of blood flow through the AVM. Onyx®, a liquid embolic agent, was used successfully as an adjunct treatment to achieve blood flow cessation. Onyx® demonstrates efficacy in the treatment of scrotal AVMs, and is a viable alternative to traditional embolic agents.

Case report

A 41-year-old man presented to the Emergency Department (ED) with right hip pain after sustaining a trauma at home. CT scan revealed a comminuted right acetabular fracture with associated retroperitoneal hemorrhage. He underwent open reduction and internal fixation of the fracture. In the postoperative setting, he developed progressive scrotal swelling, ecchymosis, and pain. On postoperative day 10, he was found lying in a large pool of blood with hypotension to 32/22. He was resuscitated with normal saline, and given blood products, octreotide, and tranexamic acid with appropriate response.

A small tear in the right scrotal skin was noted. A scrotal ultrasound demonstrated significant right-sided scrotal wall edema and hypervascularity, with marked arterial and venous flow on color Doppler (Fig. 1). In the interventional radiology suite, catheter-based angiography confirmed a large right-sided scrotal AVM (Fig. 2). The nidus of the AVM was approximately 7.5 mm x 10 mm x 8 mm. The major feeding vessels to the AVM were identified as the distal right internal pudendal artery and the right medial femoral circumflex artery, with a lesser supply from the distal left internal pudendal artery. Superselective microcatheterization and microcoil placement was sequentially performed for each of these three arteries. A total of six microcoils were placed. Angiography showed marked reduction in flow through the AVM (Fig. 3).

Two months later, the patient returned to the ED with spontaneous bleeding from the scrotum. Physical exam was remarkable for new varicosities of the scrotum and penis. The bleeding stopped with direct pressure to the area. Angiography demonstrated brisk flow through the same AVM (Fig. 4). Embospheres® were injected into the right external pudendal artery via microcatheter until the flow became more stagnant, followed by microcoiling. A second feeding artery was embolized using Gelfoam® particles to

Citation: Key R, Bishop T. Successful use of Onyx® for transcatheter arterial embolization of a scrotal arteriovenous malformation refractory to traditional embolic agents. *Radiology Case Reports*. (Online) 2013;8:846.

Copyright: © 2013 The Authors. This is an open-access article distributed under the terms of the Creative Commons Attribution-NonCommercial-NoDerivs 2.5 License, which permits reproduction and distribution, provided the original work is properly cited. Commercial use and derivative works are not permitted.

Mr. Key is a medical student and Dr. Bishop is an Assistant Professor in the Department of Radiology, both at Virginia Tech Carilion School of Medicine, Roanoke VA. Contact Mr. Key at srkey@carilionclinic.org.

Competing Interests: The authors have declared that no competing interests exist.

DOI: 10.2484/rcr.v8i3.846

Successful use of Onyx® for transcatheter arterial embolization of a scrotal AVM

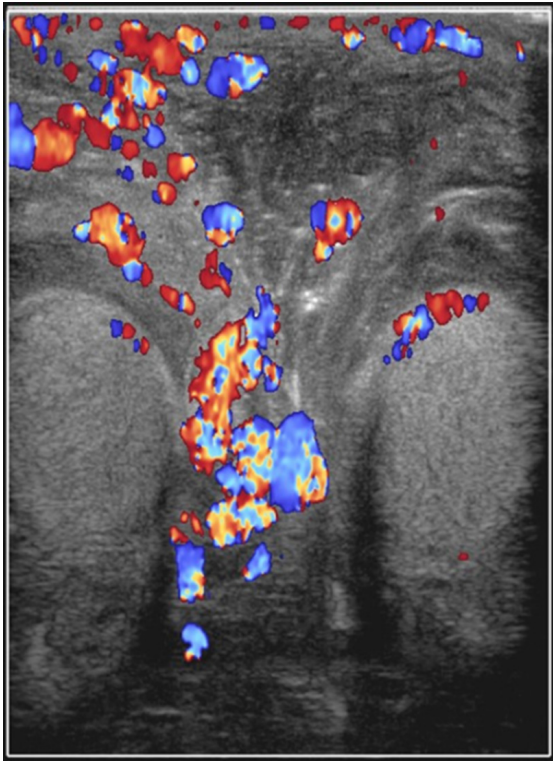


Figure 1. 41-year-old man with scrotal AVM. Doppler ultrasound demonstrates abnormally increased flow through the right scrotal vasculature.

reduce flow, followed by microcoiling. Angiography exhibited decreased but persistent flow through the AVM (Fig. 5).

One month later, a planned third embolization procedure was performed. Angiography revealed a dominant feeding artery originating from the right external pudendal

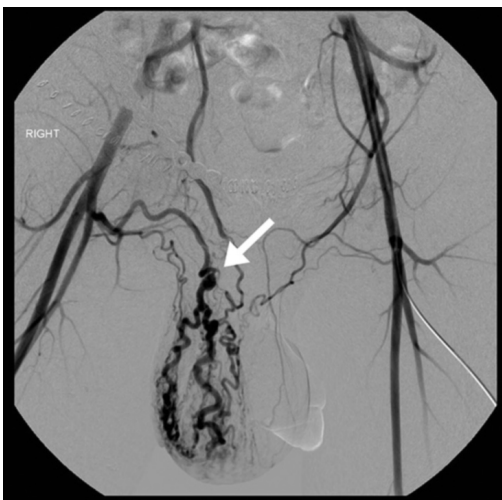

Figure 2. 41-year-old man with scrotal AVM. Pelvic angiography on initial presentation demonstrates a right-sided scrotal AVM and prominent scrotal vasculature (arrow).

artery, despite coiling one month prior (Fig. 6). The AVM also received significant blood supply from a branch of the right profunda femoris. Onyx® was injected into this artery

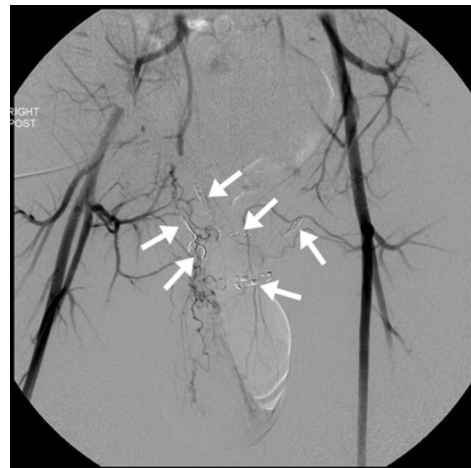


Figure 3. 41-year-old man with scrotal AVM. During the initial treatment, flow through the AVM is occluded following the placement of six microcoils (arrows).

via microcatheter. This successfully occluded a major portion of the AVM (Fig. 7). On followup exams through 18 weeks, the patient reported no new bleeding or symptoms, and physical exam revealed no varicosities, ecchymoses, or tenderness to palpation.

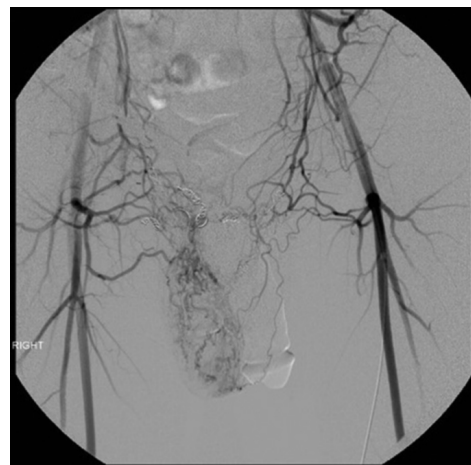

Figure 4. 41-year-old man with scrotal AVM. Increased flow through the AVM and right scrotal vasculature following the second bleeding episode.

Discussion

Scrotal vascular lesions include varicoceles, hemangiomas, lymphangiomas, vascular mesenchymomas, and AVMs (1). While varicoceles are relatively common, the other four conditions are rarer. Fewer than 20 scrotal AVMs have been reported in the literature. Scrotal vascular

Successful use of Onyx® for transcatheter arterial embolization of a scrotal AVM

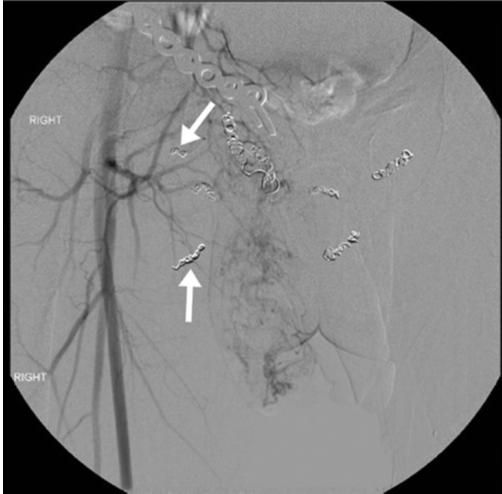


Figure 5. 41-year-old man with scrotal AVM. Following the second bleeding episode, treatment with more microcoils, Embospheres®, and gelfoam (arrows) results in decreased but persistent flow through the right scrotal vasculature.

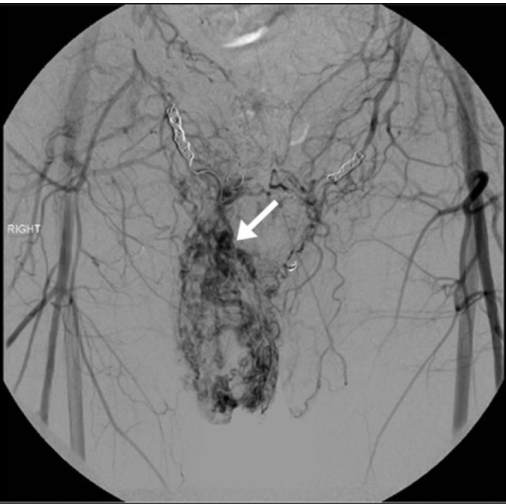

Figure 6. 41-year-old man with scrotal AVM. One month following the second embolization procedure, there is markedly increased flow through the AVM and right scrotal vasculature (arrow).

lesions can present with similar clinical signs and symptoms, including perineal heaviness or a “bag of worms” sensation. A distinguishing feature of scrotal AVMs is the presence of a bruit or thrill. Scrotal AVMs may present with pain, scrotal swelling, ulceration, and bleeding.

Most AVMs are congenital. Less common etiologies include trauma, infection, and surgical complication. This patient reported no history of scrotal trauma, bleeding, or other abnormalities. It is possible that his preceding acetabular fracture either enlarged a preexisting congenital AVM or directly caused the AVM.

Several imaging modalities may be used in the diagnosis and treatment of a scrotal AVM (2). Ultrasonography with

color Doppler is ideal for the initial evaluation of a suspected lesion. An AVM is characterized by hypervascularity, with increased arterial and venous flow on color Doppler. CT or MRI can demonstrate the extent of the lesion and the nature of the vascularity. CTA or MRA can elucidate the arterial feeders, nidus, and draining veins. Catheter-based angiography is more appropriate when there is high clinical suspicion for an AVM, as it allows for immediate treatment.

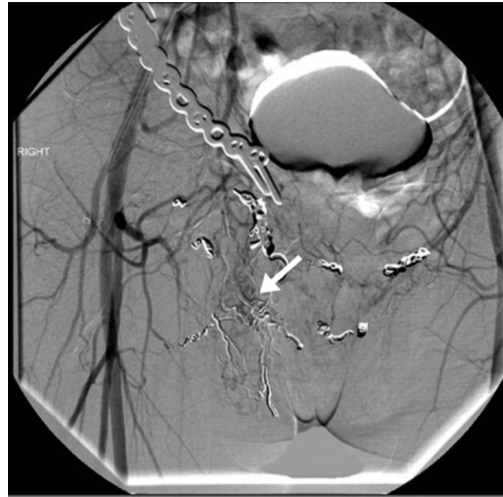

Figure 7. 41-year-old man with scrotal AVM. Following Onyx® embolization, flow through the AVM is almost entirely occluded (arrow).

A scrotal AVM should be managed emergently in the cases of continued bleeding or progressive enlargement of the scrotum. Direct pressure should be applied to the site of bleeding. If there is an open wound, an attempt should be made to identify and ligate the bleeding vessel(s). A topical hemostatic material such as Surgicel® or Gelfoam® can be applied and then covered with pressure dressing (3). If hemostasis is not achieved, catheter-based angiography should be performed.

Treatment options for a scrotal AVM include transcatheter arterial embolization (4), surgery, or a combination of the two (5). A scrotal AVM that presents with bleeding should be treated. A scrotal AVM is often large, ill-defined, and not easily accessible by surgical means, precluding resection as the sole treatment. Transcatheter embolization may be used to emergently control bleeding, as a preoperative procedure to reduce bleeding, or as the exclusive treatment. Necrosis of skin or gluteal muscles is a potential complication (2). Superselective embolization with the catheter as close to the nidus as possible helps prevent necrosis.

Traditional embolizing agents including coils, polyvinyl alcohol particles, and N-butyl cyanoacrylate have been described in the treatment of a scrotal AVM (2). Coils are most commonly used. Onyx® is a liquid embolic agent used to treat AVMs of the central nervous system (6). It has

Successful use of Onyx® for transcatheter arterial embolization of a scrotal AVM

been described in limited capacity in the treatment of peripheral AVMs and other peripheral vascular lesions (7, 8). Two concentrations of Onyx® are available: Onyx® 18 and Onyx® 34. Onyx® 18, a lower viscosity formulation, was used in this case, owing to its ability to penetrate more deeply into the nidus (9).

We believe that Onyx® is an effective and safe treatment for scrotal AVMs, particularly for AVMs refractory to traditional coiling treatment. Higher cost and lower availability may currently render Onyx® a second-line agent in many cases (8). We expect that more research will support the relatively new application of Onyx® in treating peripheral vascular lesions.

References

1. Hubert K, Elder JS, MacLennan GT. Benign vascular lesions of the scrotum. *J Urol*. 2006 Nov;176(5): 2245. [PubMed]
2. Jaganathan S, Gamanagatti S, Mukund A, Dhar A. Bleeding scrotal vascular lesions: interventional management with transcatheter embolization. *Cardiovasc Intervent Radiol*. 2011 Feb;34 Suppl 2: S113-116. [PubMed]
3. Hatten BW, Bryant E. Bleeding scrotal arteriovenous malformation. *J Emerg Med*. 2012 Jun;42(6): e133-135. [PubMed]
4. Bezirjdjian DR, Reznikov PD, Tisnado J. Transcatheter embolization of an arteriovenous malformation of the scrotum. *Cardiovasc Intervent Radiol*. 1989 Sep-Oct;12(5):267-269. [PubMed]
5. Zachariah JR, Gupta AK, Lamba S. Arteriovenous malformation of the scrotum: Is preoperative angioembolization a necessity? *Indian J Urol*. 2012 Jul;28(3): 329–334. [PubMed]
6. Leonardi M, Simonetti L, Cenni P, Raffi L. Brain AVM embolization with Onyx(R): Analysis of treatment in 34 patients. *Interv Neuroradiol*. 2005 Oct 5;11(Suppl 1): 185-204. [PubMed]
7. Wendel M, Beheshti M, Yousaf M, Erdem E. Transcatheter arterial embolization of a uterine artery pseudoaneurysm with Onyx® following D&C for uterine bleeding. *Radiology Case Reports*. (Online) 2013;8:630. DOI: 10.2484/rcr.v8i2.630
8. Carberry G, Dalvie P, Ozkan O. Onyx as a second-line embolic agent in peripheral applications. *JVIR*. 2013 Apr;24(4):S103. DOI :10.1016/j.jvir.2013.01.252
9. Pan JW, Zhou HJ, Zhan RY, et al. Supratentorial brain AVM embolization with Onyx-18 and post-embolization management. A single-center experience. *Interv Neuroradiol*. 2009 Sep;15(3): 275-282. [PubMed]

Successful use of Onyx® for transcatheter arterial embolization of a scrotal AVM