



Bilateral clavicle osteomyelitis: A case report



Fevzi Saglam^{a,*}, Seymanur Saglam^b, Deniz Gulabi^a, Engin Eceviz^a,
Nurzat Elmali^a, Mustafa Yilmaz^b

^a Dr. Lütfi Kırdar Kartal Training and Research Hospital, Kartal, İstanbul 34890, Turkey

^b Infectious Diseases and Clinical Microbiology, Dr. Lütfi Kırdar Kartal Training and Research Hospital, Kartal, İstanbul 34890, Turkey

ARTICLE INFO

Article history:

Received 11 March 2014

Received in revised form 13 October 2014

Accepted 13 October 2014

Available online 23 October 2014

Keywords:

Osteomyelitis

Clavicle infection

Clavicle osteomyelitis

ABSTRACT

INTRODUCTION: Osteomyelitis of the clavicle is rare. Infection occurs from hematogenous spread or trauma. In adults infection is usually secondary due to an exogenous cause such as open fractures, surgery (iatrogenic) or spread from local tissue with infection.

PRESENTATION OF CASE: The case is presented here of a 50-year old female with bilateral clavicular fractures, who was operated on with open reduction and internal fixation. At the 6-month follow-up, she had complaints of bilateral osteomyelitis which was successfully treated with resection of the infected segment of the bone, and antibiotic impregnated collagen.

DISCUSSION: Predisposing factors include diabetes, intravenous drug abuse, tuberculosis or immune suppression. Management involves the removal of bone fixation, debridement of the bone and if there is a defect, coverage with a muscle flap is applied.

CONCLUSION: In cases of clavicular osteomyelitis where infection continues despite debridement and antibiotic therapy, excision of the sequestered clavicular section is a successful treatment approach and has been seen to improve quality of life without any functional loss.

© 2014 Published by Elsevier Ltd. on behalf of Surgical Associates Ltd. This is an open access article under the CC BY-NC-SA license (<http://creativecommons.org/licenses/by-nc-sa/3.0/>).

1. Introduction

It is estimated that fractures of the clavicle represent 4% of extremity fractures.¹ These fractures are usually treated conservatively with a broad arm sling and have a good functional outcome.² Another treatment of clavicular fractures is surgery, there have started to be reports of complications such as non-union, injury to the subclavian vessels and hemopneumothorax after surgical treatment.^{3,4} Another rare complication is osteomyelitis. Although laboratory findings are useful in diagnosis, changes in bone structure in early stage osteomyelitis may not be seen on direct radiographs.⁵ Magnetic resonance imaging (MRI) is more useful as sensitivity and specificity are higher.^{3,5}

Despite modern surgical techniques and advanced antimicrobial therapy, osteomyelitis remains a difficult and challenging problem.^{6,7} In the treatment of clavicular osteomyelitis which occurs following surgery, the fixation material is removed and following aggressive debridement and a long period of antibiotic therapy, if there is defective soft tissue, a muscle flap can be applied.^{3,4}

* Corresponding author. Tel.: +90 216 4413900x1419/5455361461; fax: +90 216 3520083.

E-mail addresses: fvzisaglam@hotmail.com (F. Saglam), symnrtrprkl@gmail.com (S. Saglam), dgulabi@yahoo.com (D. Gulabi), engineceviz@yahoo.com (E. Eceviz), nelmali@hotmail.com (N. Elmali), drmustafayilmaz29@hotmail.com (M. Yilmaz).

<http://dx.doi.org/10.1016/j.ijscr.2014.10.056>

2210-2612/© 2014 Published by Elsevier Ltd. on behalf of Surgical Associates Ltd. This is an open access article under the CC BY-NC-SA license (<http://creativecommons.org/licenses/by-nc-sa/3.0/>).

2. Case report

Following a traffic accident as a vehicle passenger, a 50-year old female patient with a 10-year history of diabetes mellitus was monitored for 10 days in the Intensive Care Unit (ICU) with a diagnosis of multiple rib fractures, minimal pleural fluid, bilateral clavicular, right sacrum and left superior pubis arm fractures and haemorrhagic contusion in the left temporal area. According to AO classification the clavicular fractures were type 15-B2.3 on the right side and type 15-B1.3 on the left side (Fig. 1). With a diagnosis of fragmented fracture in the mid third section of both clavicles, open reduction under general anaesthesia and fixation with anatomic locking clavicular plate (TST, Kurtkoy, İstanbul) (Fig. 2a and b) was applied to the patient on the 13th day after post-trauma. 30 min preoperatively, 1 gr cefazolin iv was administered to the patient. Postoperatively, cefazol 1 gr 3 × 1 iv was continued for 2 days. On postoperative Day 3 the patient was discharged with the recommendation of bedrest.

After discharge, the patient was followed up in the polyclinic and sutures were removed 3 weeks postoperatively. The patient did not attend further follow-ups and at the 6th month postoperatively she presented at the polyclinic with complaints, which had started first in the left and 2 days later in the right clavicle, of swelling, redness, skin heat and high temperature. Physical examination determined a temperature of 38 °C, sensitivity, increased heat and limited shoulder movement in both clavicles. Serological test results showed sedimentation 95, CRP 147, WBC 18,000,

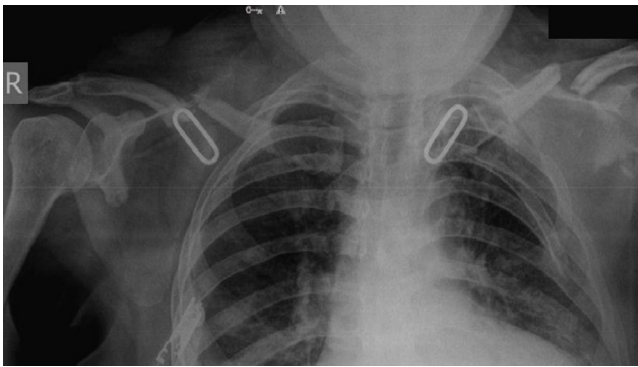


Fig. 1. 50-year old female with a 10-year history of diabetes mellitus with mid-third section fragmented bilateral clavicular fractures following a traffic accident within the vehicle. According to AO classification, right side fracture was 15-B2.3 and left-side was 15-B1.3.

nitrite positivity in the urine test, and abundant leukocytes. In the urine culture taken from the patient, 100,000 colonies *Escherichia coli* reproduction was seen. On the MRI taken of both shoulders, abscess formation and appearance compatible with osteomyelitis were seen (Fig. 3). During the operation, cultures were taken from soft tissue and the clavicles and the clavicular plates were removed. 2.7 mm drilling was made with forage on the osteomyelitis skip foci determined on the preoperative MRI, and cleaning was made with curettes and plentiful saline solution. Postoperatively, cefazol 1 gr 3 × 1 and genta 160 mg 1 × 1 iv were started. As *E. coli* and *Pseudomonas* reproduction was determined in the cultures taken intraoperatively, Targocid 400 mg 1 × 1 and Meronem 1 gr 3 × 1 iv were started from the 5th day conforming with the Infectious Diseases Dept. antibiogram. On the 20th day of antibiotherapy, the patient was again admitted for surgery due to discharge in the wound areas, which was more pronounced on the left side.

As the mid-third of the left clavicle was seen to be sclerotic and infected, a piece approximately 20 mm in size was excised as far as bleeding bone (paprika sign) from the left clavicle and washed with plentiful saline (Fig. 4). The wounds were closed by placing collagen with gentamycin wrapped around both clavicles. Reproduction of *E. coli* and *Pseudomonas* was seen in the cultures of the material taken intraoperatively. After consultation with the Infectious Diseases Department, the patient was admitted to the relevant clinic for planned treatment. A 45-day period of Tazocin 4.5 2 × 1 iv was started. Antibiotherapy was terminated when the wound sites were clinically problem-free and laboratory findings returned to normal values after the par-enteral antibiotherapy. The patient was discharged with follow-up appointments at the polyclinic. At the follow-up 26 weeks after the trauma, there were no findings of infection. The movements of both shoulders were normal and the DASH score was measured at 40 (Fig. 5a–c).

3. Discussion

Although clavicular osteomyelitis is seen very rarely, it has been reported as a complication following subclavian vein catheterization and head and neck surgery.^{8–11} Systemic causes which create a predisposition to osteomyelitis include the use of corticosteroids, dependence on iv drugs, tuberculosis, mitral cover prosthesis, diabetes and lung cancer.^{12,13,14} There are both medical and surgical treatment approaches. There are studies reporting very successful results from long-term (6–8 weeks) iv antibiotic therapy in the treatment of haematogenously spread clavicular osteomyelitis.¹⁵ No benefit is seen from antibiotic therapy in extensive surgical

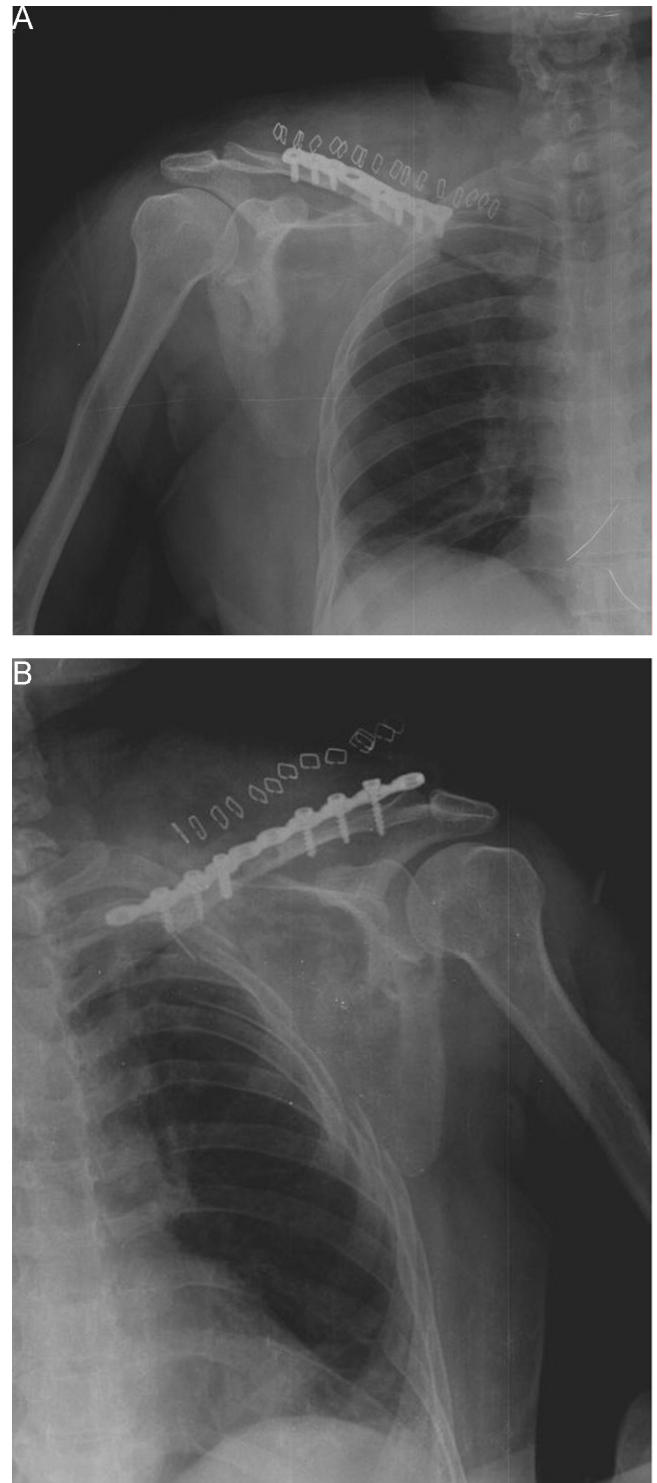


Fig. 2. (a) With a diagnosis of fragmented fracture in the mid third section of the right clavicle, open reduction under general anaesthesia and fixation with anatomic locking clavicular plate (TST, Kurtkoy, Istanbul) was applied to the patient on the 13th day post-trauma. (b) With a diagnosis of fragmented fracture in the mid third section of the left clavicle, open reduction under general anaesthesia and fixation with anatomic locking clavicular plate (TST, Kurtkoy, Istanbul) was applied to the patient on the 13th day post-trauma.

debridement but it is useful in the treatment of chronic osteomyelitis. In chronic osteomyelitis patients with a drain, if soft tissue defects have developed in the wound site, a muscle flap may be applied in these areas.

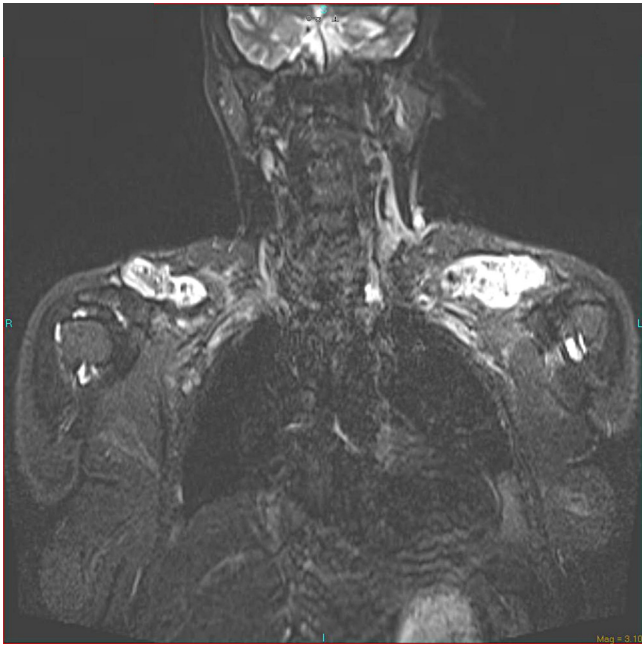


Fig. 3. MRI image taken at postoperative 6 months showing abscess formation and appearance consistent with osteomyelitis in both clavicles.

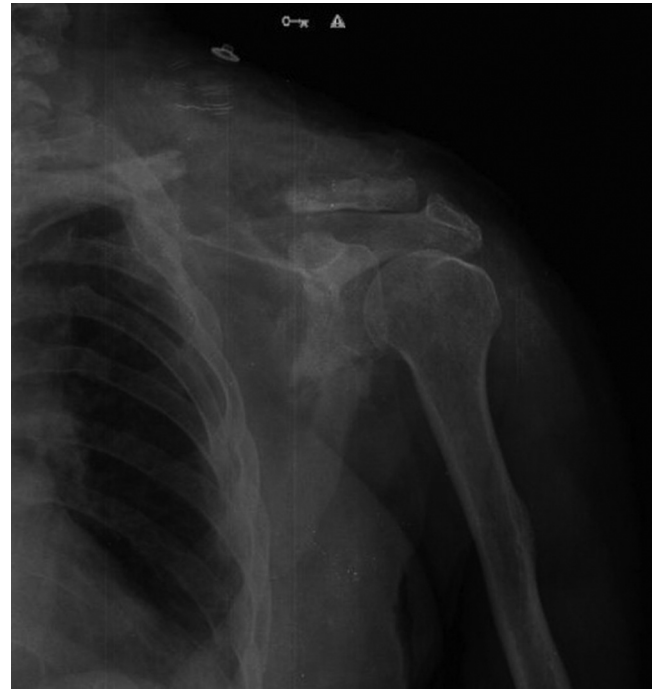
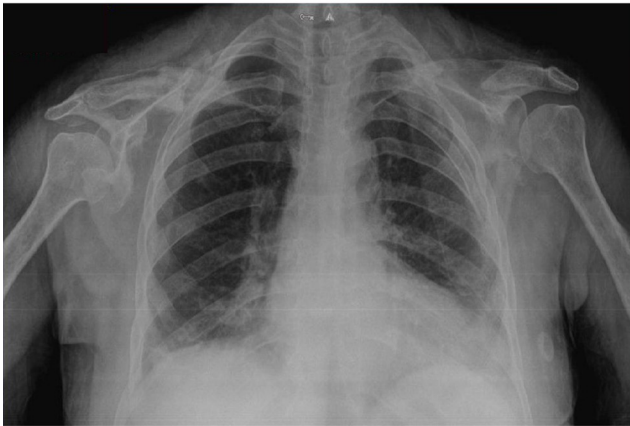
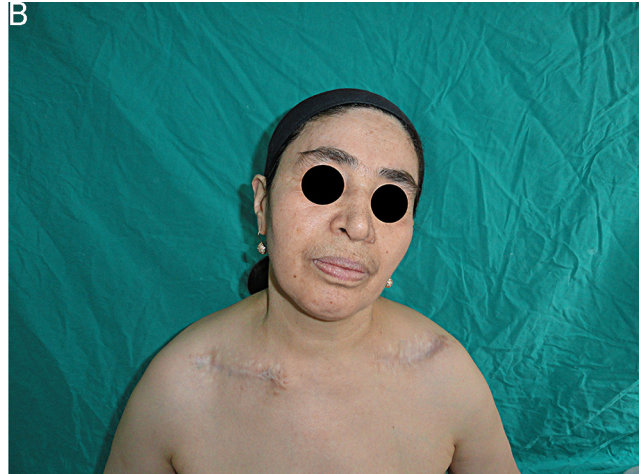
Fig. 4. During debridement the mid-third of the left clavicle was seen to be sclerotic and infected, so a piece approximately 20 mm in size was excised as far as bleeding bone (paprika sign) from the left clavicle.

A



B



C

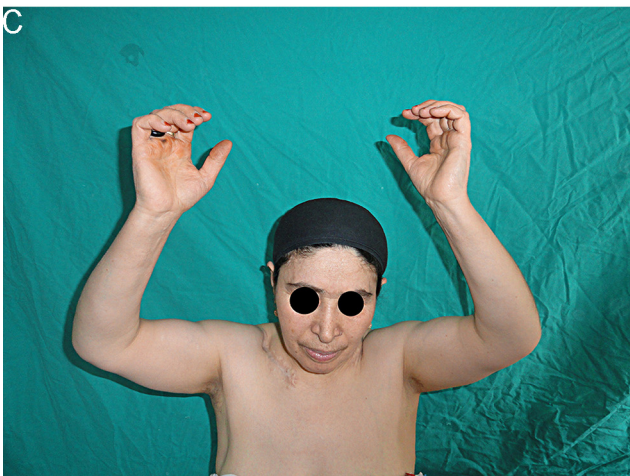

Fig. 5. (a) AP clavicular radiograph 15 months post-trauma. (b) Image of the wound site 15 months post-trauma. (c) Shoulder movements 15 months post-trauma.

The routine treatment of chronic osteomyelitis is long-term antibiotherapy together with excision of the sequestrum including aggressive and if necessary, repeated surgical debridement.^{6,16}

In a study by Schnetzke et al. of implant use in the shoulder region in the treatment of osteomyelitis which developed following surgery in 27 patients (14 proximal humerus fracture, 10 clavicular fracture, 7 acromioclavicular separation), it was reported from a 1-year follow-up that healing was achieved in 83% of cases with the application of debridement and irrigation and leaving the implant in place with a temporary irrigation system until recovery.⁴ As the case presented here was a 52-year old with a 10-year history of diabetes mellitus, from the *E. coli* reproduced in the urine samples and the cultures taken intraoperatively from the wound site, it was thought that the urinary tract was the primary focus of infection in the patient and the infection in the clavicle had formed by a secondary hematogenous route.

The diagnosis of osteomyelitis was made from the addition of MRI to the clinical and laboratory findings of the patient. Despite the removal of the fixation material that was initially applied to the patient, plentiful irrigation and aggressive debridement, the patient was again admitted for surgery in the postoperative 7th month due to continued discharge on both clavicles and the sclerotic and infected areas on the left clavicle were excised. After the second operation, which stopped the discharge from the wound site, the sedimentation and CRP values of the patient returned to normal limits in the 2nd month. At 26 weeks after the first operation, the patient had no complaints and the range of movement of both shoulders was normal.

In conclusion, in cases of clavicular osteomyelitis where infection continues despite debridement and antibiotic therapy, excision of the sequestered clavicular section is a successful treatment approach and has been seen to improve quality of life without any functional loss.

Conflict of interest

None.

Funding

None.

Ethical approval

Written informed consent was obtained from the patient and her family for publication of this case report and accompanying images.

Author contributions

Fevzi Saglam and Seymanur Saglam performed the design and the writing of the study. Deniz Gulabi and Nurzat Elmalı executed the writing and the review of the manuscript. Engin Eceviz and Mustafa Yılmaz performed the data collection.

References

1. Dath R, Nashi M, Sharma Y, Muddu BN. Pneumothorax complicating isolated clavicle fracture. *Emerg Med J* 2004;**3**(May):395–6.
2. Brinker MR, Edwards TB, O'Connor DP. Estimating the risk of nonunion following nonoperative treatment of a clavicular fracture. *J Bone Joint Surg Am* 2005;**87**(March (3)):676–7.
3. Balakrishnan C, Vashi C, Jackson O, Hess J. Post-traumatic osteomyelitis of the clavicle: a case report of the clavicle: a case report and review of literature. *Can J Plast Surg* 2008;**16**(2):89–91.
4. Schnetzke M, Aytac S, Herrmann P, Wölfl C, Grützner PA, Heppert V, et al. Postoperative implant-associated osteomyelitis of the shoulder: hardware-retaining revision concept using temporary drainage. *Unfallchirurg*; 2013, October.
5. Girschick HJ, Krauspe R, Tschammler A, Huppertz HI. Chronic recurrent osteomyelitis with clavicular involvement in children: diagnostic value of different imaging techniques and therapy with non-steroidal anti-inflammatory drugs. *Eur J Pediatr* 1998;**157**:28–33.
6. Srivastava KK, Garg LD, Kochhar VL. Osteomyelitis of the clavicle. *Acta Orthop Scand* 1974;**45**:662–7.
7. Burns P, AFRCSI, Sheahan P, FRCS (ORL), Jaime Doody MD, Kinsella J. *Clavicle osteomyelitis: a rare complication of head and neck cancer surgery*, vol. 30. Wiley Periodicals, Inc.; 2008. p. 1124–7.
8. Garcia S, Combalia A, Segur JM, Llovera AJ. Osteomyelitis of the clavicle: a case report. *Acta Orthop Belg* 1999;**65**(3).
9. Klein B, Mittelman M, Katz R, Djaldetti M. Osteomyelitis of both clavicles as a complication of subclavian venipuncture. *Chest* 1983;**83**:143–4.
10. Alessi DM, Sercarz JA, Calceterra TC. Osteomyelitis of the clavicle. *Arch Otolaryngol Head Neck Surg* 1988;**11**:1000–2.
11. Winslow CP, Meyers AD. Clavicle osteomyelitis as a complication of head and neck surgery. *Ann Otol Rhinol Laryngol* 1998;**107**:720–5.
12. Cremieux AC, Carbon C. Experimental models of bone and prosthetic joint infections. *Clin Infect Dis* 1997;**25**:1295–302.
13. Gerscovich EO, Greenspan A. Osteomyelitis of the clavicle: clinical, radiologic, and bacteriologic findings in ten patients. *Skeletal Radiol* 1983;**23**:205–10.
14. Krespi YP, Monsell EM, Sisson GA. Osteomyelitis of the clavicle. *Ann Otol Rhinol Laryngol* 1983;**92**:525–7.
15. Cierny G, Mader JT. Adult chronic osteomyelitis. *Orthopedics* 1984;**7**:1554–64.
16. Kochnar VL, Srivastava KK. Anatomical and functional considerations in total claviclectomy. *Clin Orthop Relat Res* 1976;**118**:199–201.

Open Access

This article is published Open Access at sciedirect.com. It is distributed under the [IJSCR Supplemental terms and conditions](#), which permits unrestricted non commercial use, distribution, and reproduction in any medium, provided the original authors and source are credited.