Available online at www.sciencedirect.com
ScienceDirect
Procedia Computer Science 79 (2016) 344 – 350
Procedia Computer Science

7th International Conference on Communication, Computing and Virtualization 2016

Markov random field segmentation based sonographic identification of prenatal ventricular septal defect

S.Nirmala[a] *, S.Sridevi[b]

[a] *Professor, Muthayammal Engineering College, Rasipuram, Namakkal, Tamilnadu – 637408.*
[b]*Department of Electronics and Communication Engineering, Dhirajlal Gandhi College of Technology, Salem, Tamilnadu- 636309.*

Abstract

Ventricular Septal Defect (VSD), a hole in chamber wall that separates right ventricle and left ventricle, is the most common congenital heart defect (CHD) among fetuses of India with 33% of occurrence range. In this paper, we present a method for image analysis to identify the VSD from the fetal heart 2 dimensional ultrasound images. Ultrasonography is the safest and essential imaging modality to infer the growth status of the fetus in womb. Generally making diagnosis from the fetal heart ultrasound images is a most difficult task for the physicians because of the image is highly corrupted with speckle noise and moreover the anatomical structure identification of fetal heart remains a big issue due to the fast pumping nature of fetal heart. The boundaries of ultrasound images appears with irregular edge structures due to the inconsistent appearance of speckle noise, and hence conventional segmentation approaches based on pixel intensity fails to delineate the clinical ultrasound structure boundaries. The sonographic marker used clinically to identify VSD is the H-shaped symbol seen in the ultrasound fetal heart 4 chamber view image plane. We combine a robust pre-processing methodology and segmentation approach based on unsupervised Markov Random Field (MRF) model to highlight the sonographic marker for VSD screening from the 2 dimensional ultrasound images. The experimental result shows that the average segmentation error obtained for this combined approach was around 9.83% while compared with the results of expert sonographologist.

Peer-review under responsibility of the Organizing Committee of ICCCV 2016

Keywords: Congenital heart defects, ventricular septal defect, markov random field, image segmentation, speckle noise suppression.

1. Introduction

CHD is a birth defect formed during fetus conception, which can be classified as structural and functional heart defects. Most of the CHDs are critical and requires early surgical intervention within few days of the infant birth[1]. It

* Corresponding author: *E-mail address:* nirmala.ramkamal@gmail.com

Peer-review under responsibility of the Organizing Committee of ICCCV 2016
doi:10.1016/j.procs.2016.03.045

is difficult to genuinely illustrate the hospital statistics for CHD in India, because countless of births happen at home in our nation with majority of it unsupervised by a qualified physician. Roughly 10% of present infant mortality in India may be represented by innate congenital heart diseases alone[2]. Hence more emphasis is given in performing thorough CHD screening for every trimester among pregnant mothers. Earlier diagnosis and identification of the type of CHD helps to save the life of infants. In spite of enhanced medicinal consideration accomplished for screening pre-birth CHDs, still the variables of CHD prevalence rate remains as a preeminent reason for birth defect related with life undermining sickness. In India, the incidence of VSD CHD among fetuses is more common and records for 20 to 33% of all CHDs with reported pervasiveness of 0.3 to 3.3 per 1000 live births. So it is more essential to take healing measures to manage the life of newborns with VSD to prevent serious life threatening problems[3]. VSD is more basic among preterm newborn children and stillborn fetuses. VSD in the growing fetus forms due to a delay in closure of the inter-ventricular septum beyond the first 7 weeks of intrauterine life. The cause for this late or partial closure remains unknown. VSD is associated with other few types of CHDs such as Tetralogy of Fallot and Pulmonary Atresia.

Employing ultrasonography in CHD screening requires exclusive exposure in anatomical structure identification of fetal heart chambers and blood vessels[4]. Experienced radiologists can only be able to interpret pathological point of interested details from clinical ultrasound pictures. Obstetricians and gynecologists who are new to the clinical practice finds it as a very difficult task to extract various planes of ultrasound modality and it is too hard for them to infer the diagnostic details from image planes. The impact of inherent speckle noise present in ultrasound images obscures the physicians to take diagnostic decision. This situation provides an uprooting need to use appropriate despeckling algorithm which removes the speckle pattern present in ultrasound images. Moreover, it makes the image more appropriate to apply various higher level image processing algorithms. Thus the image becomes clearer to take clinical diagnostic decisions from ultrasound images. So far there are no research papers available in the literature to analyze and to delineate the diagnostic details for identification of prenatal VSD CHD from 2 dimensional ultrasound images. Hence there exists a significant need to contrive suitable image analysis algorithms to highlight the sonographic markers from ultrasound images to screen out VSD CHD.

The conspicuous purpose of ultrasound speckle suppression pre-processing is to better suppressing the undesired visual impacts of speckled noisy patches while preserving the image edge structures. Appropriate statistical assumption made to model the inherent speckle pattern in ultrasound images helps in contriving better despeckling algorithm[5]. In this context, it is very optimal to model the ultrasound speckle pattern with Nakagami-Rayleigh joint probability density function[6]. Probabilistic patch based Weighted Maximum Likelihood Estimation (PPBMLE) based image denoising methodology proposed by Charles et al[7] uses the assumption of modeling the speckle noise with Nakagami-Rayleigh joint probability density function. Moreover, this despeckling method efficiently removes the speckle noise and meanwhile preserves the diagnostically important edge structures of clinical images. Hence, PPBMLE based despeckling is used for pre-processing the clinical ultrasound image. Despite the fact that literature reports large number of ultrasound image segmentation techniques, delineating the fetal heart chambers and blood vessels from ultrasound images still exists as a research problem. Lassige et al used the active contour segmentation strategy to depict the fetal heart septal malformations from 2 dimensional and 3 dimensional ultrasound images[8]. Dindoyal et al used enhanced level set segmentation approach with shape prior model to highlight the fetal heart chambers[9]. In the previous work we utilized fuzzy connectedness based image segmentation strategy to highlight the fetal heart blood vessels[10]. Fuzzy connectedness based segmentation can be accomplished only with the help of user interventional reference seed points. This proposed work involves the use of unsupervised markov random field model based image segmentation to automatically segment the heart chambers and to highlight the sonographic marker to easily identify the prenatal VSD from 4 chamber view visualization plane of ultrasound images.

2. Clinical data collection and background of prenatal ventricular septal defect

VSD is one of the most common CHD and is formed during initial 8 weeks of the conception of fetus. VSD appears as a hole or slit between the two (left and right) ventricular chambers of the fetal heart. Muscular VSD is the one among four types of VSD. Generally sonographologists perform thorough prenatal CHD screening by basic cardiac ultrasound examination. Various ultrasound imaging planes visualized during screening prenatal CHD defects are 3 Vessel view, 4 Chamber view, 5 chamber view, Left ventricle outflow tract, Right ventricle outflow tract and

tracheal view. Among which 4 chamber view visualizes all the four chambers of the fetal heart and is ultimately enough to screen out majority of various prenatal CHD defects[11]. Normally sonographologists produce Doppler color visualization from the 4 chamber view to screen out the prenatal ventricular septal defect. Medical sonographic marker for screening VSD CHD is done routinely by finding the H-shaped appearance from the fetal heart ultrasound 4 chamber view[12 – 13]. Fig. 1(a) shows schematic representation of the fetal heart ultrasound 4-chamber view with VSD and (b) shows the clinical color Doppler ultrasound 4 chamber view of normal fetal heart (c) shows clinical color doppler ultrasound 4 chamber visualization plane with H-shaped marker for identification of VSD.

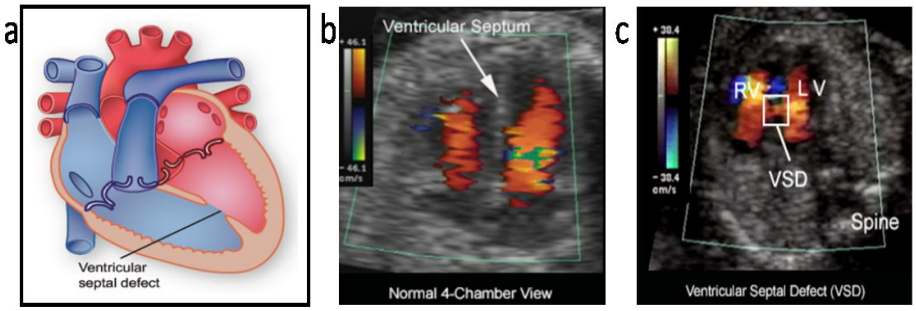

Fig.1. (a) Schematic diagram of ultrasound image with VSD (b) Clinical ultrasound color Doppler image for normal fetal heart (c) Clinical ultrasound color Doppler image with H-Shaped marker to identify VSD

The proposed work comprises of appropriate speckle suppression and unsupervised automatic segmentation algorithm applied to process fetal heart ultrasound images, which facilitates the untrained sonographologists to easily categorize the normal heart and the heart with VSD. The image datum used to implement this proposed work were collected from the pregnant mothers with fetus of varying gestational ages ranging from 15 – 30 weeks. The collection of datum is highly followed as per Helsiniki declarations.

3. Methodology

The methodology adopted in this proposed work involves cropping out the region of interest followed by PPBMLE based image pre-processing to evacuate the noisy speckle patterns. Then Markov random field image segmentation approach is utilized to highlight the fetal heart chambers from ultrasound images. The architecture scheme of the proposed work is shown in Fig.2.

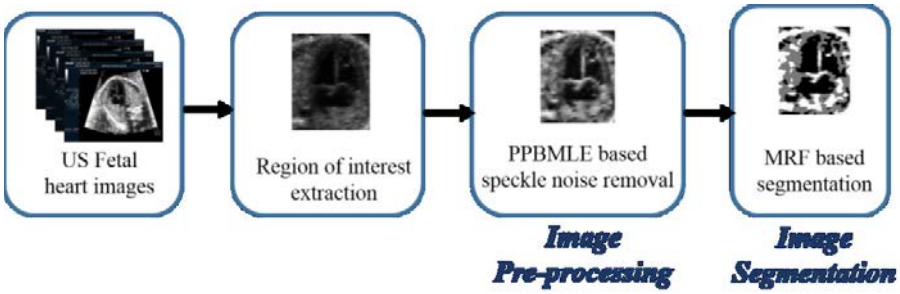

Fig.2. Architecture flow of the methodology involved in the proposed work

3.1. Probabilistic Patch based Weighted Maximum Likelihood Despeckling

As the speckle noisy patches innately developed during image formation in ultrasound imaging modality, it makes the diagnostic screening process into an ambiguous process. Hence, the proposed work of prenatal VSD defect diagnosis process involves the use of robust PPBMLE based pre-processing to remove the speckle patches

from clinical fetal heart ultrasound images.

With the use of PPBMLE despeckling methodology, the amplitude of the backscattered signal from ultrasonic transducer A_s can be well modelled by identical and independently distributed joint probability density function of Nakagami – Rayleigh distribution defined by

$$p(A_s \mid R_s^*) = \frac{2L^L}{\Gamma(L) R_s^{*L}} A_s^{2L-1} \exp\left(-\frac{LA_s^2}{R_s^*}\right) \quad (1)$$

where A_s – Pixel amplitude, R_s^* - Reflectivity image and L – Shape parameter.

Maximum likelihood estimation (MLE) is the most robust parameter estimation procedure, in which the noisy pixel intensities can be replaced by solving appropriately assumed statistical noise model representing the speckle pattern inherently present in ultrasound images. MLE accomplishes the good estimate of the true intensity of image signal by utilizing the appropriate weights $w(s,t)$ updated with respect to Probabilistic patch based (PPB) similarity measure.

Considering small region defined by rectangular kernel of 3x3 window Ω with the cardinality of 9 pixels. Let us assume v_s be image intensity inside $s\epsilon\Omega$. The noise free pixel intensities $\widehat{R_S}$ were estimated from reflectivity image by the relationship defined as

$$\widehat{R_S} = \frac{\sum_t w(s,t) A_t^2}{\sum_t w(s,t)} \quad (2)$$

Maximum Likelihood Estimator (MLE) deduces a robust estimate $\widehat{R_S}$ from the original reflectivity image intensities R_s^* denoted by

$$\widehat{R_S}^{(MLE)} \triangleq argmax_{R_S} \sum_{s\epsilon\Omega} log(v_t|R_S) \quad (3)$$

MLE framework given in equation (3) is modified with suitable PPB weights described by Weighted Maximum Likelihood Estimation (WMLE) method. It proposes to reduce the mean square error of the approximate and is given by

$$\widehat{R_S}^{(WMLE)} \triangleq argmax_{R_S} \sum_{s\epsilon\Omega} w(s,t)\, log(v_t|R_S) \quad (4)$$

The similarity measure used to extract noise less pixel intensity from underlying speckled pixel intensities is called as Probabilistic patch based (PPB) weights. The weight of the estimates is described image region patches namely $\Delta_s$and Δ_t approximating the values for centre pixel. The weights of patch based similarity measure is given by

$$w(s,t)^{(PPB)} \triangleq p(R_{\Delta_s}^* = R_{\Delta_t}^* v)^{1/h} \quad (5)$$

where $R_{\Delta_s}^*$and $R_{\Delta_t}^*$denotes sub-image extracts of R^* from Δ_s and Δ_t, h is a scalar parameter.

3.2. Markov Random Field Image Segmentation

Markov Random Field (MRF) unsupervised segmentation approach comprises of two stages. The initial step is to pick an appropriate arrangement of components which can recognize the same-content features and in the mean time separate distinctive substance features and the second step is to apply a region growing method over the selected features to accomplish a segmented map[14-15]. MRF model based segmentation approach visualizes an image with majority of homogeneous neighboring pixels with similar properties or features such as intensity, color and texture. MRF model captures those similar features among the pool of pixel intensities to accomplish segmentation process. Multitude of research works have reported with the application of MRF model based segmentation and its generalization for segmenting images such as synthetic aperture radar images and ultrasound images corrupted with

speckle noise[16-18]. Hence it is optimal to make use of MRF based unsupervised segmentation approach to be chosen as the best choice for performing automatic segmentation of fetal heart images.

Let us consider an image in the form of lattice $S=\{\{i,j\}|1\le i\le R;1\le j\le C\}$ with pixels as nodes and path connectivity as edges in the site, where R represents number of rows in image and C represents number of columns in image. The neighborhood with cliques and clique sets in the site in a homogeneous region of image is called as neighborhood system $N=\{N_S, s\in S\}$. Let us assume a small neighborhood system with a connection of pixel intensities as y and the corresponding pixel values by P(Y).

The MRF model based segmentation approach follows the Bayes theorem and Maximum A posteriori criterion, which are given by

$$P(Y=y|F=f)=\frac{P(F=f|Y=y)F(Y=y)}{P(F=f)} \tag{6}$$

Where $P(Y=y|F=f)$ represents posterior probability of Y conditioned in F and $P(F=f|Y=y)$ represents the posterior probability of F conditioned in Y and P(F=f) is the measure of feature vector in the respective neighborhood.

In this MRF segmentation model, we need to take into account of two major assumptions. The first assumption is that every feature component of F=f be independent with respect to Y=y (output segmented image).

If for an instance, there are K feature measures in the feature vector $f=\{f^K|K=1,2,....K\}$ then equation (6) can be written as

$$P(Y=y|F=f)=\frac{\prod_{K=1}^{K}P(f^K|Y=y)F(Y=y)}{P(F=f)} \tag{7}$$

Where $P(f^K|Y=y)$ represents the probability distribution of the feature component.

The second assumption is that the distributions of all feature vectors need to follow a Gaussian distribution function with varying mean and standard deviation measures. That is

$$P(f_s^K|Y_s=m)=\frac{1}{\sqrt{2\pi\sigma_m^{k\,2}}}\exp\left[-\frac{(f_s^K-\mu_m^K)^2}{2\sigma_m^{K\,2}}\right] \tag{8}$$

Where μ and σ represents mean and standard deviation for mth class in the Kth feature vector.

Under the basis of MRF model based segmentation process, Expectation-Maximization algorithm is utilized to estimate mean and standard deviation values for the purpose of feature vectors. This Expectation-Maximization procedure for unsupervised MRF segmentation model involves the following steps:

Step-1: Initialization with random segmentation image.

Step-2: Expectation step performs estimation of mean and standard deviation from the feature vector F of the image lattices, which is given by

$$\mu_m^K=\frac{1}{N}\sum_{s,Y_S=m}f_s^K,\sigma_m^K=\sqrt{\frac{1}{N-1}\sum_{s,Y_S=m}f_s^K-\mu_m^K} \tag{9}$$

Step-3: Maximization step utilizes the estimates of mean and standard deviation to optimize the segmentation process by minimizing the energy function of the derived segmented output image.

$$E=\sum\nolimits_s\left[\beta\sum\delta(y_s,y_t)\right]+\alpha\sum\nolimits_{s.m=y_s}\left\{\sum_{k=1}^{K}\left[\frac{(f_s^K-\mu_m^K)^2}{(2\sigma_m^K)^2}+\log\sqrt{2\pi\sigma_m^K}\right]\right\} \tag{10}$$

Step-4: Repeat the steps 2 & 3 until satisfying the stopping criterion.

4. Results and Discussion

This section describes the results obtained from processing the fetal heart ultrasound images. The prominent intent of this proposed works is to automatically segment and identify the H-shaped sonographic marker from the ultrasound fetal heart images in order to correctly identify the prenatal VSD defect. Figure.3 shows the images processed with PPBMLE despeckling procedure and MRF based image segmentation. Figure.3 (a,d,g,j) shows extracted region of interest (ROI) from clinical ultrasound images. Among which first image is the normal fetal heart image and rest of the images shows the VSD between right and left ventricular chambers. The inherent speckle noise present in ultrasound images are suppressed by pre-processing those clinical images using PPBMLE method of despeckling. The efficacy of the pre-processing scheme is clearly obvious. The visual quality of the image after pre-processing is improved and is shown in Figure.3 (b,e,h,k). Markov Random Field image segmentation is adopted to segment the fetal heart chambers and is shown in Figure.3 (c,f,i,l). Among them the Figure.3 (c) shows the segmented result for normal image and remaining shows the H-shaped marker in the abnormal images with VSD defect.

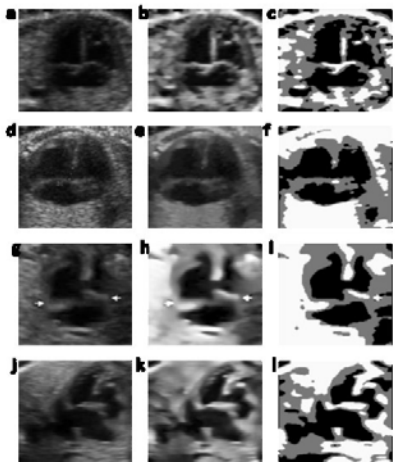

Fig.3. (a) Ultrasound normal fetal heart image (d)(g)(j) Ultrasound fetal heart images with VSD (b)(e)(h)(k) PPBMLE filtered images (c) MRF segmentation result for normal fetal heart(f)(i)(l) MRF segmentation result for fetal heart with VSD & H-shaped sonographic marker.

Table 1. Quantitative error analysis of MRF segmentation in comparison with physician segmentation

Image number	Segmentation type	Area of heart chambers	Segmentation error in percentage
Image 1	Physician	4452	12.22%
	MRF model	5072	
Image 2	Physician	3789	8.18%
	MRF model	4127	
Image 3	Physician	3986	7.51%
	MRF model	4310	
Image 4	Physician	4317	11.39%
	MRF model	4872	
		Average Error	9.83%

Table.1 shows the quantitative error analysis in terms of segmentation error percentage performed for the proposed work with unsupervised MRF model segmentation approach. This automatic segmentation is compared with the manual physician approach of segmentation process by measuring the area of segmented fetal heart chamber of both manually segmented image and MRF model based automatically segmented image. Error percentage is calculated

for both area measurements of manual and automatic method. The average error for all the four images shown in figure.3 is obtained around 9.83%.

5. Conclusion

Prenatal VSD detection from 2 dimensional ultrasound fetal heart images is not only a challenging task and it requires diverse screening experience and diagnostic skills. This proposed work is an attempt made to help the untrained sonographologists to interpret diagnostic information from ultrasound images and to draw unambiguous decision about the presence or absence of prenatal VSD CHD. The experimental results show that the proposed work helps to quickly identify the H-shaped sonographic marker to diagnose the prenatal VSD heart defect. PPBMLE speckle suppression technique effectively enhances the image structures making the clinical ultrasound images more suitable for application of automatic image analysis techniques for extracting automatic decision about the disease diagnosis. Moreover, the performance of the chosen Markov random field segmentation is compared with the results of manually segmentation results collected from the experts (trained sonographologists). Unsupervised MRF model based segmentation approach yields segmentation error percentage of around 9.83% of error in the segmentation task over the fetal heart ultrasound images. Thus the proposed work would be obviously helpful in assisting the sonographologists in the point of providing secondary observation.

References

1. Maron, B. J., Towbin, J. A., Thiene, G., Antzelevitch, C., Corrado, D., Arnett, D., ... & Young, J. B. (2006). Contemporary definitions and classification of the cardiomyopathies an American heart association scientific statement from the council on clinical cardiology, heart failure and transplantation committee; quality of care and outcomes research and functional genomics and translational biology interdisciplinary working groups; and council on epidemiology and prevention. Circulation, 113(14), 1807-1816.
2. Khalil, A., Aggarwal, R., Thirupuram, S., & Arora, R. (1994). Incidence of congenital heart disease among hospital live births in India. Indian pediatrics,31(5), 519-528.
3. Bhardwaj, R., Rai, S. K., Yadav, A. K., Lakhotia, S., Agrawal, D., Kumar, A., & Mohapatra, B. (2014). Epidemiology of Congenital Heart Disease in India.Congenital heart disease.
4. Rychik, J., Ayres, N., Cuneo, B., Gotteiner, N., Hornberger, L., Spevak, P. J., & Van Der Veld, M. (2004). American Society of Echocardiography guidelines and standards for performance of the fetal echocardiogram.Journal of the American Society of Echocardiography, 17(7), 803-810.
5. Nirmala, S., & Sridevi, S. (2013, February). Modified rayleigh maximum likelihood despeckling filter using fuzzy rules. In Information Communication and Embedded Systems (ICICES), 2013 International Conference on (pp. 755-760). IEEE.
6. Sampath, Sridevi, and Nirmala Sivaraj. "Fuzzy Connectedness Based Segmentation of Fetal Heart from Clinical Ultrasound Images." Advanced Computing, Networking and Informatics-Volume 1. Springer International Publishing, 2014. 329-337.
7. Deledalle, C. A., Denis, L., & Tupin, F. (2009). Iterative weighted maximum likelihood denoising with probabilistic patch-based weights. Image Processing, IEEE Transactions on, 18(12), 2661-2672.
8. Lassige, T. A., Benkeser, P. J., Fyfe, D., & Sharma, S. (2000). Comparison of septal defects in 2D and 3D echocardiography using active contour models. Computerized Medical Imaging and Graphics, 24(6), 377-388.
9. Dindoyal, I., Lambrou, T., Deng, J., & Todd-Pokropek, A. (2007, April). Level set snake algorithms on the fetal heart. In Biomedical Imaging: From Nano to Macro, 2007. ISBI 2007. 4th IEEE International Symposium on (pp. 864-867). IEEE.
10. Sridevi, S., & Nirmala, S. (2015). ANFIS based decision support system for prenatal detection of Truncus Arteriosus congenital heart defect. Applied Soft Computing.
11. Allan, L. D., Crawford, D. C., Chita, S. K., & Tynan, M. J. (1986). Prenatal screening for congenital heart disease. BMJ, 292(6537), 1717-1719.
12. https://sonoworld.com/Client/Fetus/html/doppler/capitulos-html/chapter_12.html
13. http://www.fetal.com/Genetic%20Sono/03_gen%20us%20color%20dopp.html
14. Barker, S. A., & Rayner, P. J. (2000). Unsupervised image segmentation using Markov random field models. Pattern Recognition, 33(4), 587-602.
15. Deng, H., & Clausi, D. A. (2004). Unsupervised image segmentation using a simple MRF model with a new implementation scheme. Pattern recognition, 37(12), 2323-2335.
16. Wang, F., Wu, Y., Fan, J., Zhang, X., Zhang, Q., & Li, M. (2014). Synthetic aperture radar image segmentation using fuzzy label field-based triplet Markov fields model. IET Image Processing, 8(12), 856-865.
17. Wang, F., Wu, Y., Fan, J., Zhang, X., Zhang, Q., & Li, M. (2014). Synthetic aperture radar image segmentation using fuzzy label field-based triplet Markov fields model. IET Image Processing, 8(12), 856-865.
18. Xu, H., Wang, W., & Liu, X. (2010, October). A novel SAR fusion image segmentation method based on Markov Random Field. In Image and Signal Processing (CISP), 2010 3rd International Congress on (Vol. 3, pp. 1297-1300). IEEE.