

# Caso Clínico

## Clinical Case

Anabela Marinho<sup>1</sup>  
Beatriz Lima<sup>2</sup>  
Idalina Araújo<sup>3</sup>  
Pedro Bastos<sup>4</sup>  
J Agostinho Marques<sup>5</sup>  
Isabel Gomes<sup>6</sup>

### Pneumotórax espontâneo num pulmão vicariante

#### *A spontaneous pneumothorax in a “buffalo chest”*

Recebido para publicação/received for publication: 06.11.28

Aceite para publicação/accepted for publication: 07.01.29

#### Resumo

O pneumotórax contralateral após pneumonectomia é uma situação rara. É necessário um alto índice de suspeição para um correcto diagnóstico, na ausência de exames complementares de diagnóstico. O tratamento é um desafio, uma vez que a intervenção cirúrgica, se necessária, é um procedimento de risco. A pleurodese química pode ser uma medida simples e eficaz, em casos sem fístula broncopleurais importante.

Descrevemos o caso clínico de uma doente de 21 anos com pneumotórax espontâneo em pulmão único, que colocou várias dificuldades, diagnósticas e terapêuticas. A presença de pulmão vicariante dificultou a interpretação inicial do RX torácico. A doente apresentava fístula

#### Abstract

Spontaneous contralateral pneumothorax after pneumonectomy is a rare condition. A high index of suspicion is required for a correct diagnosis. Management can be challenging, as surgical intervention, if necessary, is a very high risk procedure. Chemical pleurodesis can be a simple and effective measure in cases with no major air leak. We describe the case of a 21-year-old female with spontaneous pneumothorax in a single lung, which posed several diagnostic and therapeutic problems. The presence of a “buffalo chest” made the initial chest x-ray interpretation difficult. The patient had an important air leak without complete pulmonary

<sup>1</sup> Interna Complementar de Pneumologia do Hospital de S. João

<sup>2</sup> Assistente Hospitalar de Pneumologia do Hospital de S. João

<sup>3</sup> Assistente Hospitalar Graduada de Pneumologia do Hospital de S. João

<sup>4</sup> Chefe de Serviço de Cirurgia Torácica do Hospital de S. João; Professor Associado Convidado da Faculdade de Medicina da Universidade do Porto

<sup>5</sup> Chefe de Serviço de Pneumologia do Hospital de S. João; Professor Catedrático da Faculdade de Medicina da Universidade do Porto

<sup>6</sup> Assistente Hospitalar Graduada de Pneumologia do Hospital de S. João

Director do Serviço de Pneumologia: Professor Doutor J. Agostinho Marques

Director do Serviço de Cirurgia Torácica: Professor Doutor Pedro Bastos

#### Correspondência:

Anabela Marinho

Serviço de Pneumologia do Hospital de S. João

Alameda Professor Hermâni Monteiro,

4202-451 Porto, Portugal.

Telefone: 225512100 ou 963311481

E-mail: [a.n.marinho@vtel.pt](mailto:a.n.marinho@vtel.pt)

Fax: 00351225512215

broncopleural de alto débito, sem expansão pulmonar completa, mesmo após colocação de um segundo dreno torácico, e a cirurgia torácica foi considerada de risco.

Foi efectuada instilação de talco através de um dos drenos torácicos, com posterior resolução.

Estamos convencidos de que a resolução da fístula broncopleural foi facilitada pela talcagem, mesmo sem expansão pulmonar total, que nunca se tinha conseguido.

**Rev Port Pneumol 2007; XIII (4): 613-617**

**Palavras-chave:** Pneumotórax, pneumonectomia, pulmão vicariante, fístula broncopleural, *slurry talc*.

expansion and thoracic surgery was considered of risk. Accordingly, instillation of talc slurry through one of the thoracic drains was undertaken with eventual resolution. We are convinced that bronco-pleural fistula resolution was facilitated by slurry talc, despite complete lung expansion never having been achieved.

**Rev Port Pneumol 2007; XIII (4): 613-617**

**Key-words:** Pneumothorax, pneumonectomy, “buffalo-chest”, air-leak, slurry talc.

### Abreviation list

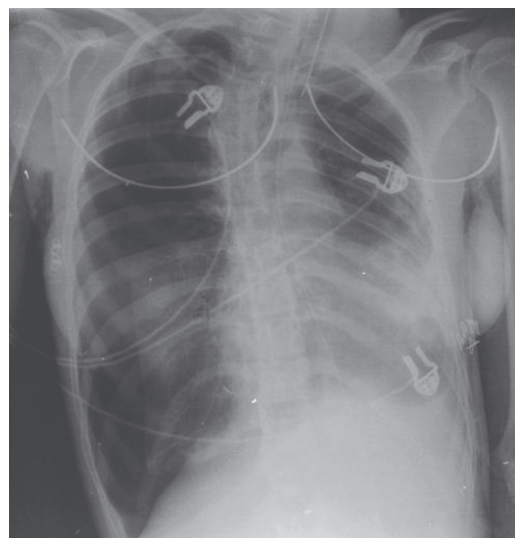
PTX = pneumothorax

PMN = pneumonectomy

### Case report

A 21-year-old female was admitted to the hospital with sudden onset of right chest pain and progressive dyspnea, abdominal discomfort and vomiting. She arrived at the emergency room in syncope and imminent respiratory arrest. A thoracic scar suggesting previous left lung surgery was present. A chest x-ray was performed, showing a right-sided total pneumothorax (PTX), a tension PTX. On the left, lung parenchyma was observed on the upper field, with retractile obliteration of the lower half (Fig. 1). A chest tube was immediately placed on the right hemithorax and a high debit bronco-pleural leak was noted.

After chest drainage, the control x-ray showed incomplete lung expansion and a line of left



**Fig. 1** – Chest X-ray at the admission

PTX was apparent as well. Consultation of patient's files showed that patient underwent left pneumonectomy (PMN) at the age of seven for extensive lung sequelae secondary to repeated respiratory infections.

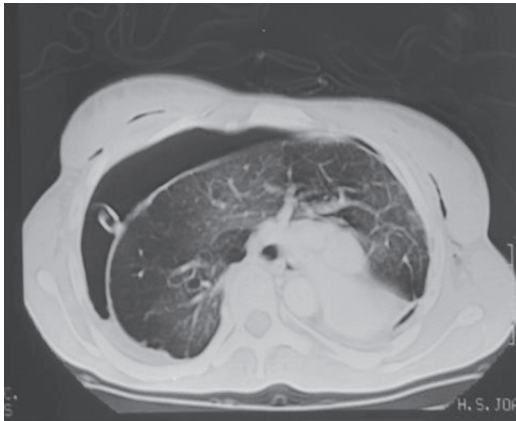


Fig. 2 – Thoracic CT scan demonstrating a single lung, herniated (“buffalo chest”)

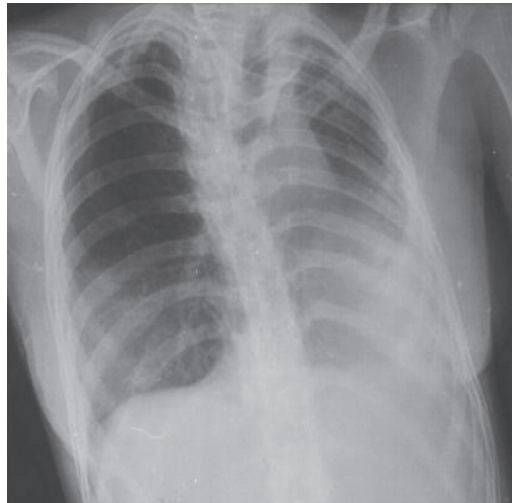


Fig. 3 – Chest x-ray after drains remotion

A CT scan confirmed a single lung, partially herniated to the contralateral side (“buffalo-chest”) with air in the pleural space on the left (Fig. 2).

On the eighth day of admission, a second chest tube was inserted because of sudden subcutaneous emphysema and pneumomediastinum, with good response, but the leak persisted, despite negative water suction through both thoracic drains. Surgical intervention was discussed, but was considered for critical deterioration alone, given the high risks of the procedure. One month later, despite complete lung expansion never having been achieved, pleurodesis with slurry talc was performed via one of the chest tubes, with sedation; we used 5 g of talc with reduced number of particles smaller than 10  $\mu\text{m}$  (“graded” talc). Six days later, the leak resolved, the lung expanded and the tubes were subsequently removed (Fig. 3).

The patient was discharged from the hospital forty-five days after admission and there was no recurrence of PTX during the follow-up period (2.5 years).

## Discussion

Contralateral PTX after PMN is a rare but potentially fatal complication. Few isolated case reports exist in the literature and almost all cases occur in the immediate post operative period.<sup>1</sup> Of the handful of cases reported, the overall mortality approaches 50%. Delayed diagnosis is the usual cause for the high mortality, therefore a high index of suspicion is required if mortality is to be reduced. If such a diagnosis is considered, the correct course of action is immediate decompression, even before radiological confirmation.<sup>2</sup>

A single pleural space is sometimes called “buffalo chest” because the similarity with some buffalo or bison of North America.<sup>3</sup> In this patient, the presence of a “buffalo chest” made the initial chest x-ray interpretation difficult, since the image was also compatible with previous left lobectomy.

In general, spontaneous PTX can be treated conservatively by expectant observation, aspiration, or chest drainage. In this patient,

recurrence may have serious consequences and a more definitive treatment should be attempted. Surgery for pleurodesis and/or bleb resection is complicated and dangerous in a patient with previous pneumonectomy.<sup>4</sup> Few isolated case reports exist in the literature<sup>5,6,7,8</sup>, where the most common management was insertion of a thoracostomy tube followed by surgery, because of maintained air leak. In general, patients with a PTX and air leak persisting beyond 4 days should be evaluated for surgery, to seal the leak and perform pleurodesis to prevent recurrence;<sup>4</sup> in this particular situation, surgical intervention was discussed and, given the high risks of the procedure, reserved for critical deterioration, although it can be argued that the surgical conditions of the patient could also deteriorate as time passed by. An episode of subcutaneous emphysema and pneumomediastinum was controlled with the insertion of a second drain, although some reports concerning the management of spontaneous PTX are not in favour of an additional chest tube when the air leak persists.<sup>4</sup> Later, the patient maintained haemodynamic and radiological stability, but the leak persisted and the lung didn't completely expand, so the intrapleural treatment with slurry talc was decided. After the procedure, the situation resolved in a few days.

There is conflicting evidence as to whether chemical pleurodesis with tetracycline is effective for the treatment of fully expanded PTX with persistent air leak;<sup>9-10</sup> talc is the preferred agent in managing pneumothorax with persistent air leaks, when patients are not operative candidates.<sup>4</sup> We believe that slurry talc contributed to the resolution of the bronco-pleural fistulae, despite complete lung expansion never having been achieved.

A too lengthy time was taken to perform the procedure, but it had been expected that the lung expanded completely, which is important for pleurodesis.

There is no standard treatment for this condition. Persistent air leak may imply surgical intervention<sup>4,6</sup>, which may carry important risks of morbidity and mortality. Indications and techniques continue to evolve - thoracoscopic procedures, with bleb resections and/or pleurodesis are now most frequently used and can be performed with the aid of cardiopulmonary bypass.<sup>4</sup>

## Conclusion

Pneumothorax in a single lung is fortunately a rare condition, but is a challenging situation in terms of diagnosis and therapy. Specific management guidelines do not exist yet, and a case by case evaluation is still needed.

## Bibliography

1. Bruce A. A Postpneumonectomy Patient With Iatrogenic Pneumothorax. *The Internet Journal of Emergency and Intensive Care Medicine* 2000; 5(1).
2. Watts BL, Howell MA. Tension pneumothorax: a difficult diagnosis. *Emerg Med J* 2001; 18: 319-20.
3. Kurt W, Grathwohl, Stephen Dardak. *Buffalo Chest*. *N Engl J Med* 2003; 349:1829.
4. Baumann MH, Strange C, Heffner JE, Light R, Kirby TJ, Klein J, Luketich JD, Panacek EA, Sahn SA. Management of spontaneous pneumothorax: an American College of Chest Physicians Delphi consensus statement. *Chest* 2001; 119:590-602.
5. Hubbard JH, Nkere UU, Bhatnagar NK. Spontaneous contralateral pneumothorax following pneumonectomy. *Postgraduate Med J* 1997; 73: 107-8.
6. Birdas TJ, Beckart DH, Keenan RJ. Contralateral spontaneous pneumothorax after pneumonectomy: thoracoscopic management with cardiopulmonary bypass.

## PNEUMOTÓRAX ESPONTÂNEO NUM PULMÃO VICARIANTE

Anabela Marinho, Beatriz Lima, Idalina Araújo, Pedro Bastos, J Agostinho Marques, Isabel Gomes

Interactive Cardiovascular and Thoracic Surgery 2005; 4:27-9.

7. Cesario A, Kawamukai K, Margaritora S, Granone P. Persistent post-pneumonectomy spontaneous pneumothorax: a challenging case. Interactive Cardiovascular and Thoracic Surgery 2003; 2: 477-9.

8. Ishikawa N, Sato H, Hiranuma C, Takizawa M. A surgical Intervention Using Percutaneous Cardiopulmonary Support for Contralateral Pneumothorax following Pneumonectomy. Ann Thorac Cardiovasc Surg 2001; 4: 235-6.

9. Macoviak JA, Stephenson LW, Ochs R, Edmunds LH. Tetracycline pleurodesis during active pulmonary-pleural air leak for prevention of recurrent pneumothorax. Chest 1982; 81:78-81.

Light RW, O'Hara VS, Moriz TE, McElhinney AJ, Butz R, Haakenson CM, Read RC, Sassoos CS, *et al.* Intrapleural tetracycline for the prevention of recurrent spontaneous pneumothorax: results of a Department of Veterans Affairs Cooperative Study. JAMA 1990; 264:2224-30.