


Contents lists available at [ScienceDirect](http://ScienceDirect.com)

Gynecologic Oncology Reports

journal homepage: www.elsevier.com/locate/gore

Primary osteosarcoma of the uterus with cardiac and pulmonary metastases



Cynthia Abraham^{a,*}, Roisin O'Cearbhaill^b, Robert Soslow^b

^a Jamaica Hospital, Dept of Obstetrics & Gynecology, 89-06 135th St, Suite 6S, Jamaica, NY 11418, USA

^b Memorial Sloan-Kettering Cancer Center, 1275 York Avenue, New York, NY 10065, USA

ARTICLE INFO

Article history:

Received 13 May 2014

Accepted 10 July 2014

Available online 1 October 2014

Keywords:

Uterine osteosarcoma

Cardiac metastasis

Pulmonary metastasis

Introduction

Uterine sarcomas are uncommon, comprising less than 1% of all gynecologic neoplasms and 3–7% of all uterine neoplasms. Clinical manifestations of uterine sarcoma typically consist of vaginal bleeding, pelvic pain or pressure and an enlarged uterus (D'Angelo and Prat, 2010). Uterine sarcomas can be classified as either homologous (consisting of components native to the uterus) or as heterologous (consisting of components foreign to the uterus such as cartilage and bone). The majority of uterine sarcomas are homologous (DiSaia and Creasman, 2012). Heterologous uterine osteosarcomas are distinctly rare with published references limited to case reports. To our knowledge, 18 cases of primary osteosarcoma arising from the uterus have been published. We present the first case of a 47 year old Asian female with primary uterine osteosarcoma that exhibited cardiac and pulmonary metastases.

Case

A 47 year old Asian female presented with a six month history of menometrorrhagia, abdominal pain and early satiety. She also reported a two month history of chronic cough. Six months prior to symptom onset, she was in good health. Magnetic resonance imaging of the abdomen and pelvis performed five months prior to initial office presentation showed a uterus measuring 12 × 9 × 9 cm with a heterogeneously

enhancing mass in the anterior aspect of the uterus measuring 8 × 8 × 7 cm. The ovaries appeared unremarkable. Endometrial biopsy performed three months prior to initial office presentation showed secretory endometrium. Pelvic ultrasound performed on the day of initial office presentation showed a uterus measuring 17 × 14 × 12 cm with multiple intramural leiomyomas and findings suggestive of adenomyosis. The patient was counseled on treatment options and elected for surgical management. Given the history of cough, the patient underwent a chest X-ray pre-operatively and was noted to have multiple scattered pulmonary nodules which were confirmed after CT of the chest with contrast was performed. CT of the abdomen and pelvis indicated no other metastases. Given the patient's worsening symptoms, it was decided to proceed with primary surgical management for pathological confirmation of malignancy and palliation of symptoms. Total abdominal hysterectomy and bilateral salpingo-oophorectomy (TAH/BSO) was performed.

The surgical specimen weighed 1827 g. The uterine corpus measured 17 × 16 × 16 cm. Approximately 90% of the uterus was displaced by a soft, friable necrotic tumor that was interspersed with viable tissue suggestive of smooth muscle and measuring 14 × 11 × 9 cm (Fig. 1). There was a rim of myometrium surrounding the tumor that measured 1.5 cm. The ovaries and fallopian tubes showed no pathological change. Calcifications were not grossly evident.

Initial pathologic diagnosis was leiomyosarcoma. However, on repeat pathologic evaluation, a diagnosis of primary uterine osteosarcoma based on the presence of multinucleated giant cells (Fig. 2a) and osteoid formation with ossification (Fig. 2b) was favored. It is possible that the tumor arose in the setting of a uterine leiomyosarcoma that underwent heterologous differentiation but there was no evidence of leiomyosarcoma seen in the pathology specimen. Initial staining showed that the tumor was positive for caldesmon with focal positivity to desmin and CD10 while it was negative for cam5.2, pax8, SMA, actin, CD34, CD117, ER and CA 125. Keratin staining did not support a diagnosis of carcinosarcoma. Neither cartilage formation nor carcinomatous elements were present.

On postoperative day 16, the patient presented with dyspnea to the office. CT of the chest showed two intracardiac masses which were ultimately felt to represent tumor; these masses were not present on the CT of the chest that was performed one month prior. It was elected to not proceed with cardiac surgery so as to not delay initiation of systemic chemotherapy. Given the osteosarcoma histology, chemotherapy in the form of doxorubicin and ifosfamide with mesna was initiated. The patient experienced a dramatic improvement in her symptoms within

* Corresponding author at: Staten Island University Hospital, Dept of OB/GYN, 475 Seaview Avenue, Staten Island, NY 10305, United States. Tel.: +1 917 330 1470.

E-mail address: cynthia.abraham08@gmail.com (C. Abraham).

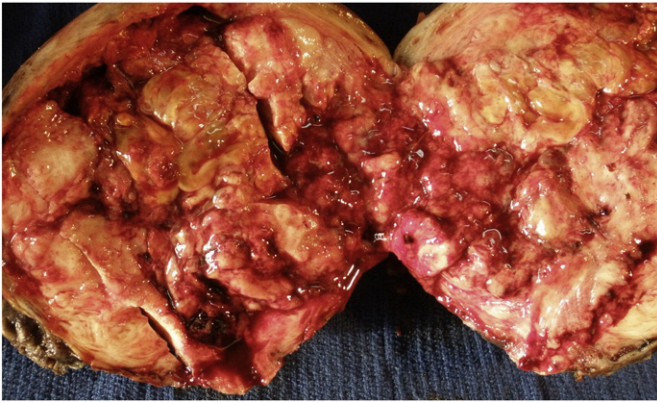


Fig. 1. Entire gross specimen bivalved.

one week after commencing chemotherapy. Following five cycles of doxorubicin and ifosfamide with mesna, CT of the chest, abdomen and pelvis showed an interval improvement in the size of the pulmonary metastases.

Imaging performed one month later however indicated an increase in the size of the pulmonary metastases. There was no change in the size of the intracardiac masses. She subsequently received one dose of gemcitabine and decided to enter hospice care. She died six months after surgery secondary to worsening symptoms associated with the pulmonary metastases.

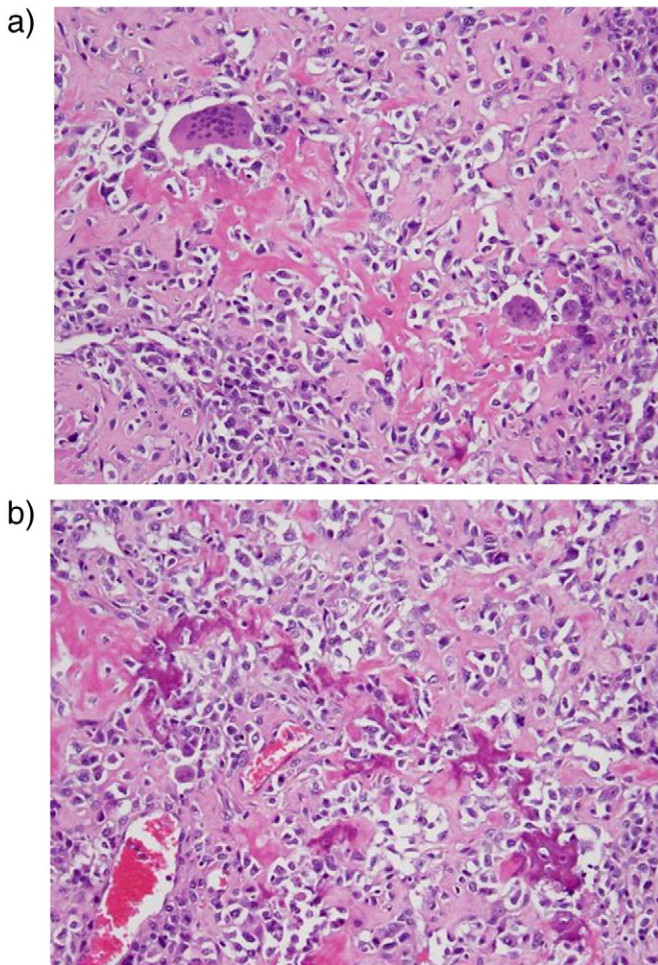


Fig. 2. a. Osteoclast-like giant cells and pleomorphic tumor cells are distributed within prominent eosinophilic matrix (osteoid). b. The osteoid is focally calcified, imparting the appearance of bone.

Discussion

Uterine leiomyosarcomas are very aggressive tumors and portend a poor prognosis. Making a diagnosis preoperatively based on endometrial biopsy is difficult as the tumor arises within the smooth muscle. Leiomyosarcomas have been reported to occur twice as often in African-American as in Caucasian women. Mean age at diagnosis is 60 years old (DiSaia and Creasman, 2012). Heterologous uterine osteosarcomas are unusually rare with instances limited to case reports. The histologic origin of uterine osteosarcomas may be secondary to either mesenchymal differentiation or a smooth muscle neoplasm with malignant osseous metaplasia. However, these theories are controversial (Kostopoulou et al., 2002). The ideal chemotherapy regimen for patients with primary uterine osteosarcoma is unknown given the rarity of these tumors. Therefore, chemotherapy recommendations are extrapolated from clinical trials of chemotherapy for uterine sarcomas and extraskeletal osteosarcomas. In uterine leiomyosarcoma, the combination of doxorubicin and ifosfamide is associated with reported response rates of 30–48% and that of gemcitabine and docetaxel with response rates of 27–40% (Hensley, 2010).

Based on a PubMed Search using the search words “uterus” and “osteosarcoma,” we found that the age range at time of diagnosis ranged from 41 to 82. Grossly, the size range of the tumors ranged from 4 to 40 cm. Of the eleven patients with metastatic uterine osteosarcoma, five had abdominal spread and one had metastasis to the skull. Five patients had pulmonary metastasis. Table 1 summarizes the findings associated with those previously reported patients with pulmonary metastasis and the findings associated with our case (Stier and Lyman, 1936; Carleton and Williamson, 1961; Jotkowitz and Valentine, 1985; Emoto et al., 1994; Pisciole et al., 1985; Su et al., 2002). None of the patients initially presented with pulmonary metastases at the time of diagnosis. None of the patients had cardiac metastasis.

In our case, the possibility of metastasis from a skeletal osteosarcoma was excluded based on the patient’s history, physical exam and preoperative imaging. Additionally, skeletal osteosarcomas primarily occur in the first two decades of life. Although the distinction between leiomyosarcoma with heterologous (osseous) elements and “osteosarcoma” has not been codified in the gynecologic pathology literature, the histologic features of the specimen in our case were distinctive enough to favor the diagnosis of osteosarcoma over leiomyosarcoma. The histologic findings were in accordance with the following three guidelines espoused by Pisciole et al. (1985): primary origin in bone was excluded, neoplastic osteoid was present, and an epithelial component and other specific homologous or heterologous elements were absent after confirming the presence of an adequate tissue sampling. Furthermore, desmin testing was positive which is consistent with myoblastic differentiation, a finding associated with osteosarcomas arising from soft tissue. Although desmin testing aided in supporting the diagnosis of osteosarcoma, the diagnosis of osteosarcoma is based on histology, not immunophenotype. Thus, immunohistochemical results were not used as primary diagnostic indices. The main tumor entity in our differential diagnosis was malignant mixed müllerian tumor (MMMT). This was ruled out based on negative keratin staining. Moreover, the tumor in our case was not described as polypoid and projecting into the uterine cavity as is the description associated with MMMT (Su et al., 2002).

This is the first case describing a female with primary uterine osteosarcoma that exhibited cardiac and pulmonary metastases. This patient’s course indicates that although extremely rare, uterine osteosarcomas, like leiomyosarcomas, do respond to doxorubicin and ifosfamide. However, this patient’s course serves to emphasize the aggressive nature and metastatic potential associated with uterine osteosarcoma given the location of the metastases and progression of the disease in spite of instituting a comprehensive regimen consisting of surgery and chemotherapy. The small number of published cases of uterine osteosarcoma does not allow for clear guidelines on the best

Table 1
Summary of findings associated with previously reported cases of primary uterine osteosarcoma with pulmonary metastasis and with the present case of osteosarcoma of the uterus.

Source	Age	Symptoms	Size of tumor (if noted), site of metastasis at initial presentation (if any)	Treatment	Clinical duration
Stier and Lyman (1936)	53	Abdominal pain	6 cm, omentum	SCH, BSO	2 months
Carleton and Williamson (1961)	82	Vaginal bleeding	Bladder; tumor filled pelvis	Intracavity radium	8 months
Jotkowitz and Valentine (1985)	51	Backache, abdominal pain, weight loss	Pelvis, omentum, peritoneum	None	20 days
Piscioli et al. (1985)	56	Vaginal bleeding	12 cm	TAH, BSO, CHT, RT	37 months
Emoto et al. (1994)	67	Abdominal pain	16 cm	TAH, BSO	4 months
Su et al. (2002)	62	Abdominal pain	15 cm	Biopsy of mass	4 months
Present case	47	Abdominal pain, vaginal bleeding, early satiety, chronic cough	14 cm, lungs	TAH, BSO, CHT	6 months

Abbreviations: SCH: supracervical hysterectomy, TAH: total abdominal hysterectomy, BSO: bilateral salpingo-oophorectomy, CHT: chemotherapy; RT, radiation therapy.

therapeutic approach for this disease entity. Further research is required to potentially identify “targetable” driver mutations.

Written informed consent was obtained from the patient for publication of this case report and accompanying images.

Conflict of interest statement

The authors have no conflicts of interest to declare.

References

- Carleton, C.C., Williamson, J.W., 1961. Osteogenic sarcoma of the uterus. *Arch. Pathol.* 72, 135–139.
- D'Angelo, E., Prat, J., 2010. Uterine sarcomas: a review. *Gynecol. Oncol.* 116 (1), 131–139 (Jan).
- DiSaia, Creasman, 2012. *Sarcoma of the Uterus in Clinical Gynecologic Oncology*, 8th ed. pp. 175–187.
- Emoto, M., Iwasaki, H., Kawarabayashi, T., Egami, D., Yoshitake, H., Kikuchi, M., Shirakawa, K., 1994. Primary osteosarcoma of the uterus: report of a case with immunohistochemical analysis. *Gynecol. Oncol.* 54 (3), 385–388 (Sep).
- Hensley, M.L., 2010. Update on gemcitabine and docetaxel combination therapy for primary and metastatic sarcomas. *Curr. Opin. Oncol.* 22 (4), 356–361 (Jul).
- Jotkowitz, M.W., Valentine, R.A., 1985. A rare pelvic mass: osteosarcoma of the body of the uterus. *Aust. N. Z. J. Obstet. Gynaecol.* 25, 132–136.
- Kostopoulou, E., Dragoumis, K., Zafarakas, M., Myronidou, Z., Agelidou, S., Bontis, I., 2002. Primary osteosarcoma of the uterus with immunohistochemical study. *Acta Obstet. Gynecol. Scand.* 81 (7), 678–680 (Jul).
- Piscioli, F., Govoni, E., Polla, E., Pusioli, T., Dalri, P., Antolini, M., 1985. Primary osteosarcoma of the uterine corpus. Report of a case and critical review of the literature. *Int. J. Gynecol. Obstet.* 23, 377–385.
- Stier, R.F.E., Lyman, J.C., 1936. Osteoblastic sarcoma of the uterus. *Am. J. Clin. Pathol.* 6, 562–567.
- Su, M., Tokairin, T., Nishikawa, Y., Yoshioka, T., Takahashi, O., Watanabe, H., Doi, Y., Omori, Y., Yoshioka, T., Sageshima, M., Tanaka, T., Enomoto, K., 2002. Primary osteosarcoma of the uterine corpus: case report and review of the literature. *Pathol. Int.* 52 (2), 158–163 (Feb).