




ELSEVIER

Contents lists available at [ScienceDirect](http://ScienceDirect)

## Urology Case Reports

journal homepage: [www.elsevier.com/locate/eucr](http://www.elsevier.com/locate/eucr)

Inflammation and Infection

## Fungal Fourniers Gangrene in an Immunocompromised Patient



Winston Crowell, Robyn Roberts\*, Susan Tarry

Department of Surgery, University of Texas Medical Branch, 301 University Blvd., Galveston, TX 77555, USA

## ARTICLE INFO

## Article history:

Received 8 September 2015

Accepted 29 September 2015

## Keywords:

Fournier gangrene

Fungal

Zygomycetes

Rhizopus

## ABSTRACT

Fournier's Gangrene is a rapidly progressive necrotizing fasciitis of the groin, perianal and perineal region that is often polymicrobial in nature, often averaging 3 species of bacteria per patient. The typical infection can be due to a host of microbes, including gram positive, gram negative and anaerobic species including. Many of the causative organisms are found in the normal microbial flora of the perineum. Therefore, Fournier's is an opportunistic infection most commonly affecting the immunosuppressed. The majority of Fournier's gangrene are bacterial; however there have been cases of fungal Fournier's gangrene reported in the literature.

© 2016 The Authors. Published by Elsevier Inc. This is an open access article under the CC BY-NC-ND license (<http://creativecommons.org/licenses/by-nc-nd/4.0/>).

## Introduction

Fournier's gangrene is often associated with polymicrobial infection of those that are immunosuppressed.<sup>1–3</sup> The following case demonstrates that, in addition to antibiotics, antifungals should be administered at the time of treatment.<sup>1</sup>

## Case report

A 54 year old male admitted to University of Texas Medical Branch for work up of newly diagnosed acute myeloid leukemia. The patient's past medical history was significant for prostate cancer, hepatitis C virus, non-insulin dependent diabetes mellitus, and hypertension. After initiation of chemotherapy the patient was diagnosed with neutropenic fevers and eventually developed pneumonia, respiratory distress requiring intubation, and septic shock. His blood cultures revealed *Serratia marcescens*. The patient was treated in the medical intensive care unit with vancomycin, and piperacillin-tazobactam. In addition, he was also on prophylactic acyclovir and fluconazole. During the patient's intensive care admission a condom catheter was placed for accurate output measurements.

The patient was eventually extubated and the condom catheter was removed. Upon removal of the condom catheter a penile pain was noted and a lesion was seen. Urology was consulted on day 22 for evaluation of the patient's genitals. Laboratory review at the time of consultation were significant for white blood cell count of

$<0.1 \times 10^3/\text{mL}$ , hemoglobin of 7.2 g/dL, platelet count of  $42 \times 10^3/\text{mL}$ , serum sodium levels of 130 mEq/L, glucose of 230 mg/dL, and creatinine of 0.52 ng/dL.

A genitourinary exam revealed a blackened scrotum and a penile shaft with crepitus and eschars consistent with Fournier's gangrene, however, there was no foul smell. The patient was immediately taken for genitourinary debridement. During this procedure the left testis was found to be grossly involved and necrotic appearing, therefore a left orchiectomy and left hemiscrotectomy was performed.

Post-operatively the patient was stable and afebrile, however his mental status was noted to be altered with episodes of confusion. Quantitative analysis returned on post-operative day four positive for the fungus zygomycetes, and patient was started on systemic liposomal Amphotericin B. The patient's wound was noted to be mottled with a paucity of granulation tissue, therefore, the patient was taken back to the operating room for a second debridement.

The second debridement included right orchiectomy, supra-pubic tube placement, penectomy as well as further groin debridement. The Burn team was consulted intra-operatively for more aggressive debridement. Post-operatively the patient received amphotericin soaked dressing changes, as well amphotericin bladder irrigation. He underwent a third debridement with the Burn team.

On post-operative day 16 the patient became hypotensive, tachycardic, febrile; and a green growth was noted on the groin so further debridement with the Burn team was scheduled. Before further debridement was possible the patient's condition worsened and the medical intensive care unit noted the patient's demise on post-operative day 18.

\* Corresponding author. Tel.: +1 5035228006.

E-mail addresses: [rlcrowel@utmb.edu](mailto:rlcrowel@utmb.edu), [robyncrowell@gmail.com](mailto:robyncrowell@gmail.com) (R. Roberts).

### Literature review

Zygomycetes is ubiquitous and its spores are found in outdoor and indoor air samples.<sup>1</sup>

Risk factors for hosting an infection include leukemia; neutropenia due to chemotherapy; broad-spectrum antibiotics disrupting normal flora; diabetes mellitus; and steroid use due to their ability to induce diabetes mellitus and decrease inflammatory response. Once diagnosed, amphotericin B is the preferred antifungal, but since it can impair renal function its use is sometimes halted prematurely.<sup>1</sup>

Zygomycosis can occur as a cutaneous, subcutaneous, rhinocerebral, pulmonary, or disseminated infection. The cutaneous form of the zygomycetes can occur either by primary infection at the site or by dissemination from another location in the host. Presentation of the primary infection include red lesions which may develop to black eschars and slough off to produce ulcers. The cutaneous form of infection can delve deeper into the fat and fascia to become necrotizing fasciitis. An infection that has progressed this far has a high mortality rate, but once it has disseminated hematogenously mortality rates can go even higher to between 94% and 100%.<sup>1,4</sup>

To further complicate the situation, *Rhizopus*, the genus responsible for 90% of cases of zygomycosis,<sup>1</sup> are characteristic for angioinvasion, thrombosis and necrosis.<sup>1</sup> This is particularly dangerous in cases of Fournier's gangrene due to the complicated lymphatic system of the genital region (Figs. 1–3).

### Discussion

Early recognition of fungal genitourinary infection is of paramount importance as zygomycosis can quickly become disseminated and carries a high mortality rate. Our patient was particularly susceptible to infection, possessing many of the risk factors associated with zygomycosis infection.

This patient's physical exam was unique for fungal Fournier's upon first encounter.

Firstly, the patient did not possess the fetid odor that usually occurs as part of bacterial Fournier's gangrene. Secondly, the patient had what appeared to be an infarcted testicle intra-operatively,

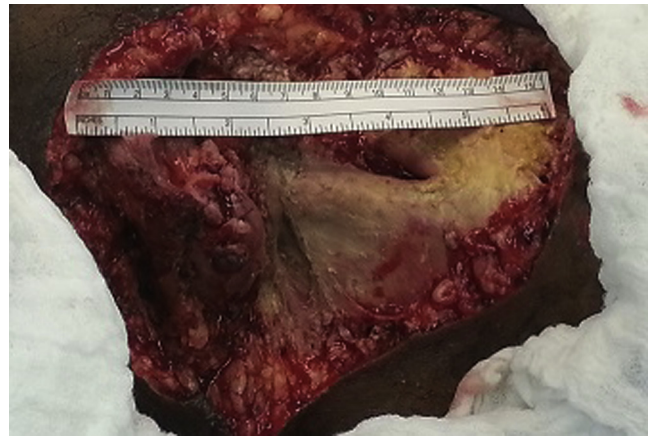

Figure 2. After second debridement.

which does not occur in the context of bacterial Fournier's gangrene. These unique findings should have raised suspicion for fungal infection. Thirdly, our patient was immunocompromised from receiving chemotherapy, recent bacteremia, and intubated due to respiratory distress secondary to pneumonia. We should be aware as clinicians that such patients are at high risk for fungal infections.

Once cultures returned positive for *Rhizopus* amphotericin B was administered, but 4 days had already passed since the initial

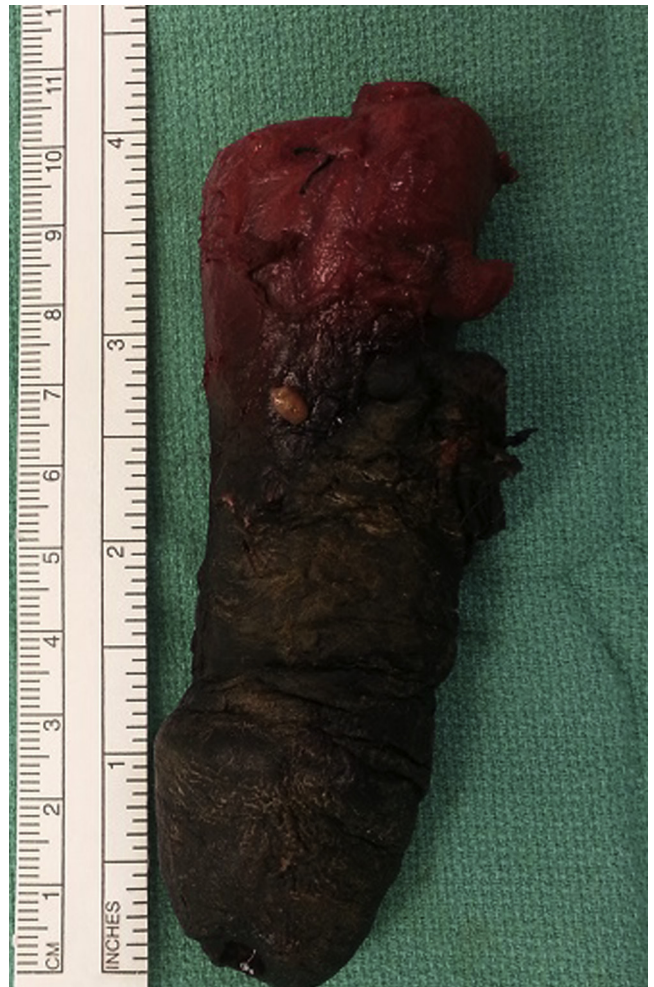

Figure 3. After second debridement – penectomy specimen.

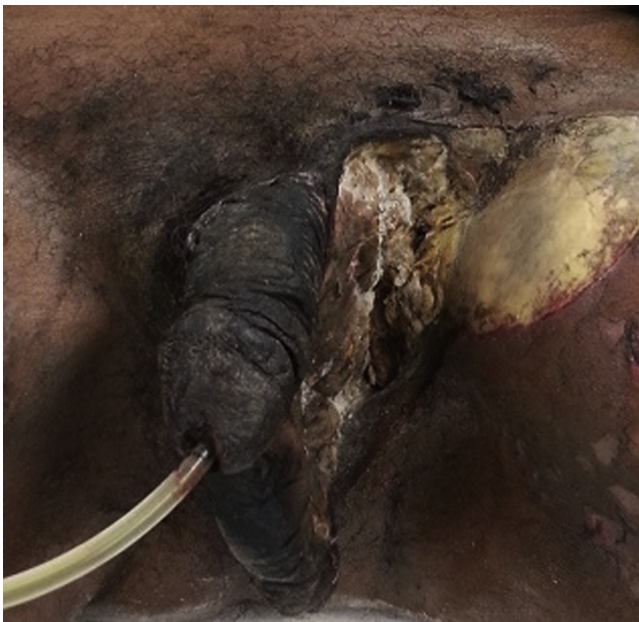

Figure 1. After first debridement.

debridement. Due to our patient's immunocompromised state and, disseminated zygomycosis at presentation there was very little possibility of rescuing the patient at onset. The aggressive nature of zygomycetes infection necessitates an equally aggressive treatment plan. Multiple debridements may be necessary with simultaneous antifungal therapy but even this may not be sufficient.

**Conflict of interest**

There is no conflict of interest.

**References**

1. Ribes JA, Vanover-Sams CL, Baker DJ. Zygomycetes in human disease. *Clin Microbiol Rev.* 2000 Apr;13(2):236–301. Review. PubMed PMID: 10756000; PubMed Central PMCID: PMC100153.
2. Eke N. Fournier's gangrene: a review of 1726 cases. *Br J Surg.* 2000 Jun;87(6):718–728. Review. PubMed PMID: 10848848.
3. Vick R, Carson 3rd CC. Fournier's disease. *Urol Clin North Am.* 1999 Nov;26(4):841–849. Review. PubMed PMID: 10584624.
4. Roden MM, Zaoutis TE, Buchanan WL, et al. Epidemiology and outcome of zygomycosis: a review of 929 reported cases. *Clin Infect Dis.* 2005 Sep 1;41(5):634–653. Epub 2005 Jul 29. Review. PubMed PMID: 16080086.