



# Journal of Coloproctology

[www.jcol.org.br](http://www.jcol.org.br)



## Case Report

# Endoanal pilonidal sinus: case report and literature review



Carolina Talini<sup>a</sup>, Geanine Baggio Fracaro<sup>a,b</sup>, Allan Cezar Faria Araújo<sup>a,c</sup>,  
Doryane Maria dos Reis Lima<sup>b,d</sup>, André Pereira Westphalen<sup>a,c,\*</sup>

<sup>a</sup> Hospital Universitário do Oeste do Paraná (HUOP), Cascavel, PR, Brazil

<sup>b</sup> Sociedade Brasileira de Coloproctologia, Rio de Janeiro, RJ, Brazil

<sup>c</sup> Universidade Estadual do Oeste do Paraná (UNIOESTE), Cascavel, PR, Brazil

<sup>d</sup> Faculdade Assis Gurgacz, Cascavel, PR, Brazil

### ARTICLE INFO

#### Article history:

Received 2 February 2015

Accepted 20 February 2015

Available online 29 April 2015

#### Keywords:

Pilonidal sinus

Rectal fistula

Transrectal ultrasound

#### Palavras-chave:

Cisto pilonidal

Fístula anal

Ultrassom endoanal

### ABSTRACT

Pilonidal sinus is a term first used by Hodges in 1880 to describe granulomatous lesions containing hairs in its interior. The presence of endoanal pilonidal sinus is rare and only nine cases have been reported in medical literature. This article describes a male, 42 years, initially submitted to fistulotomy with seton placement that four years later evolved with complaints of anal purulent discharge associated with painful anal groin. During the first evaluation a small endoanal tumor was found. It was located in posterolateral anus position and contained hair in its interior, without purulent discharge at that moment. Underwent surgery that confirmed the presence of endoanal pilonidal sinus. The sinus was opened and left to heal by secondary intention. The patient had good outcome with no signs of recurrence.

© 2015 Sociedade Brasileira de Coloproctologia. Published by Elsevier Editora Ltda. All rights reserved.

### Cisto pilonidal endoanal: relato de caso e revisão de literatura

#### R E S U M O

O termo cisto pilonidal foi descrito pela primeira vez por Hodges em 1880 para descrever lesões granulomatosas contendo pêlos em seu interior. A presença de cisto pilonidal endoanal é rara e existem apenas nove casos relatados na literatura médica. Descreve-se um caso masculino, 42 anos, em acompanhamento há 5 anos no serviço. Submetido inicialmente à fistulotomia em dois tempos com sedenho, evoluindo 4 anos depois com queixas de secreção purulenta intermitente por via anal associada a presença de tumoração dolorosa. No exame físico constatou-se presença de orifício contendo pêlos em seu interior, sem

\* Corresponding author.

E-mail: [andrewestphalen@terra.com.br](mailto:andrewestphalen@terra.com.br) (A.P. Westphalen).

<http://dx.doi.org/10.1016/j.jcol.2015.04.002>

2237-9363/© 2015 Sociedade Brasileira de Coloproctologia. Published by Elsevier Editora Ltda. All rights reserved.

secreção purulenta no momento do exame. Foi encaminhado para tratamento cirúrgico que confirmou diagnóstico de cisto pilonidal endoanal. No procedimento foi realizada abertura do cisto que foi deixado para cicatrizar por segunda intenção. O paciente apresentou boa evolução, sem sinais de recidiva local.

© 2015 Sociedade Brasileira de Coloproctologia. Publicado por Elsevier Editora Ltda.

Todos os direitos reservados.

## Introduction

Pilonidal sinus is a term first used by Hodges in 1880 to describe granulomatous lesions containing hairs in its interior.<sup>1</sup> Such lesions were first described by Warren in 1854 and called hairy cyst.<sup>2</sup> Is a common entity in young hairy man and most of them contain long hair with no follicles.<sup>1</sup>

Similar lesions are being described in other body parts such as abdominal wall, ears, hands, armpit, gluteal, interdigital region, nipple, occipital, perineum and umbilicus.<sup>1-3</sup> This diversity of topography is a factor that supports a theory, and in support of that theory, some authors suggest that pilonidal cysts are the result of lost hairs that are pushed into the skin.

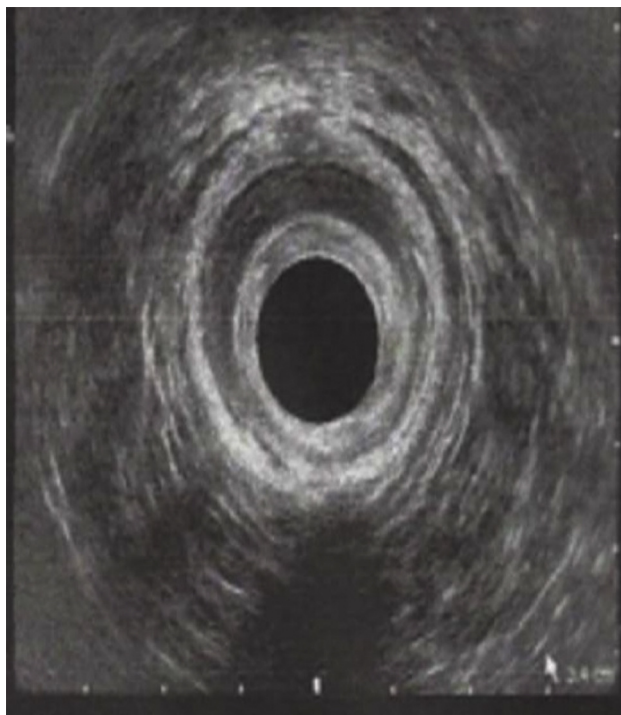
The presence of endoanal pilonidal sinus is rare<sup>4</sup> and only nine cases have been reported in medical literature.<sup>5</sup> There are several ways to explain the genesis of those sinus in the anal canal. One of them regards an extension of a sacro-coccygeal cyst to the perianal region and other less widespread theories are that the pilonidal cyst could be born through the entry of hairs into an open anal fissure or that hair can get into the anal canal region as they do elsewhere in the body.<sup>1,3,4</sup> Nowadays the most accepted theory concerns the acquired disease after performing anal fistulotomy or other surgical procedure in which hair may enter the subcutaneous tissue through the healing wound or through the newly formed scar and may serve as the cradle of a pilonidal sinus.<sup>1,4,5</sup>

The pilonidal sinus can often be confused with anal fistula. Usually the patient has multiple recurrences and underwent several surgical procedures but without symptoms improvement.<sup>6</sup>

This article aims to report an endoanal pilonidal sinus case that appeared after surgical treatment to correct an anal fistula.

## Clinical presentation

GF, male, 42 years, smoker, diagnosed with HIV 10 years ago (using Efavirenz, Lamivudine and Zidovudine), who first came to this Coloproctology service 5 years ago, complaining about a fast growing anal tumor, painful, which evolved to spontaneous drainage of pus. After first service admission an anal posterolateral fistula was diagnosed in association with grade I hemorrhoids and multiple perianal skin tags. The patient underwent surgical procedure with excision of skin tags (that pathological anatomy confirmed that it was squamous papilloma with hyperkeratosis associated with viral cytopathic default), fistulotomy with seton placement and cauterization of hemorrhoidal nipples.



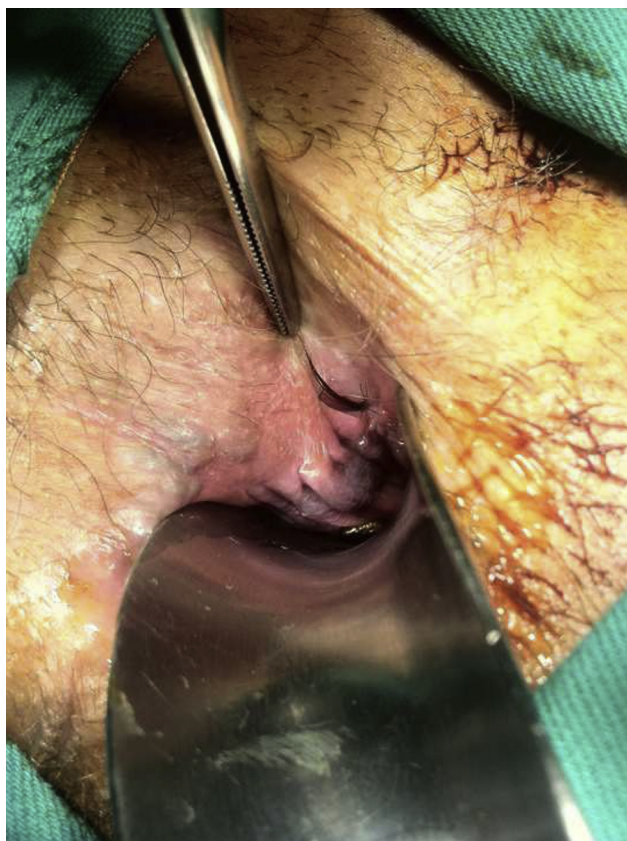**Fig. 1 – 3D endoanal ultrasound showing thinning of the anal canal, without any lesions.**

About a year ago started presenting anorectal complaints again. Related drainage of purulent and fetid secretion during this period and pain during evacuation without bleeding, denying increasing on the nodule size. During the first evaluation a small endoanal tumor was found. It was located in posterolateral anus position and contained hair in its interior, without purulent discharge at that moment.

Patient was submitted to 3D endoanal ultrasound that found no lesions despite the thinning of the left dorsolateral internal and external anal sphincter in the posterolateral quadrant of the middle anal canal (Fig. 1). It was clinically diagnosed as pilonidal sinus of the anal canal and the patient underwent surgery.

Surgery revealed left posterolateral sinus containing hair in its interior and after opening the sinus it was possible to visualize the presence of pus in small quantity (Fig. 2), and the surgeon decided to open the entire trajectory of the sinus.

In the immediate postoperative period the patient had good outcome, no pain complaints and no secretion drainage. The patient remains in ambulatory follow-up and had no recurrence or complications six months after the surgery.



**Fig. 2 – Transoperatory demonstrating posterolateral sinus containing hair in its interior.**

## Discussion

Different pilonidal sinus presentations are described in literature. Regarding those located in endoanal region, eight cases were reported in man and one of them in a woman.<sup>1-5</sup> When it comes to the age, those were all young patients – 23, 27, 29, 30, 42, 46, 55 and 58 years for the men and 42 years for the woman.

Four of them presented recurrent purulent discharge and were submitted to the most diverse surgical procedures without clinical improvement.<sup>1,3-5</sup> Two of them had no symptoms and were diagnosed during a surgical procedure to correct hemorrhoids<sup>4</sup> and three of them were symptomatic for the first time.<sup>2</sup> None of the evaluated patients had found hair in

endoanal region by themselves. As in the presented case, the sinus were unique in eight of the reported cases and one other patient presented two endoanal sinus.<sup>1</sup>

When it comes to the surgical procedure, in four cases the cyst trajectory was opened and left to heal by secondary intention<sup>1,4</sup> just like the case presented here and on the other four cases the lesion was completely removed.<sup>2-5</sup>

One of the reported cases<sup>5</sup> had a similar outcome as the one we present here. Both patients were initially surgically treated to correct an anal fistula with seton, evolved with symptoms recurrence and developed endoanal pilonidal sinus.

One of the previous case reports had a two years follow-up<sup>4</sup> and none of the five patients presented disease recurrence. Other author presented one year follow up with no recurrence.<sup>5</sup> All other case reports presented no information about the follow-up period.<sup>1-3</sup>

## Conclusion

Endoanal pilonidal sinus is a rare entity with very few reported cases in literature. In the related cases most patients are young men who are symptomatic for a long time until the true disease is diagnosed. Surgical treatment seems to be effective for healing with low recurrence rates.

## Conflicts of interest

The authors declare no conflicts of interest.

## REFERENCES

1. Wilson E, Failes DG, Killingback M. Pilonidal sinuses of the anal canal: report of case. *Dis Colon Rectum*. 1971;14(6):468-70.
2. Weston SD, Schlachter IS. Pilonidal cyst of the anal canal: case report. In: *Read at the meeting of the American Proctologic Society*. 1962.
3. Accarpio G, Davini MD, Fazio A, Senussi OH, Yakubovich A. Pilonidal sinus with an anal canal fistula: report of case. *Dis Colon Rectum*. 1988;31(12):965-7.
4. Ortiz H, Marti J, DeMiguel M, Carmona A, Cabañas IP. Hair-containing lesions within the anal canal. *Int J Colorectal Dis*. 1987;2:153-4.
5. Alrawashdeh W, Ajaz S, Hammond TM, Porrett TRC, Lunniss PJ. Primary anal pilonidal disease. *Colorectal Dis*. 2008;10:303.
6. Clothier PR, Haywood IR. The natural history of the post anal (pilonidal) sinus. *Ann R Coll Surg Engl*. 1984;66:201-3.