

Available online at
ScienceDirect
www.sciencedirect.comElsevier Masson France
EM|consulte
www.em-consulte.com/en

Original article – Works of SFHG

Is unicompartmental-to-unicompartmental revision knee arthroplasty a reliable option? Case-control study

J.A. Epinette^{a,*}, M. Leyder^b, D. Saragaglia^c, G. Pasquier^d, G. Deschamps^e,
the Société Française de la Hanche et du Genou (SFHG)^f^a Clinique Médico-Chirurgicale, 200, rue d'Auvergne, 62700 Bruay-Laboussière, France^b Centre Chirurgical Émile-Gallé, 49, rue Hermite, 54000 Nancy, France^c Clinique Universitaire de Chirurgie Orthopédique et de Traumatologie du Sport, Hôpital Sud, CHU de Grenoble, 38130 Échirolles, France^d Service d'Orthopédie D, hôpital Roger-Salengro, CHRU de Lille, rue Émile-Laine, 59037 Lille, France^e Centre Orthopédique Médico-Chirurgical, 71640 Dracy-le-Fort, France^f 52, rue Boissonnade, 75014 Paris, France

ARTICLE INFO

Article history:

Accepted 25 October 2013

Keywords:

Knee arthroplasty
Unicompartmental knee arthroplasty
Failure
Revision

ABSTRACT

Background: In selected patients with failed unicompartmental knee arthroplasty (UKA), revision UKA is a reliable option and may even provide lower morbidity rates and better functional outcomes compared to revision total knee arthroplasty.**Material and methods:** In a multicentre retrospective study of 425 knees requiring revision surgery after UKA, 36 knees were managed with revision UKA.**Results:** Of the 36 knees, 3 (8.33%) required iterative revision surgery, for aseptic loosening. After a mean follow-up of 8.3 years, the mean IKS knee and function scores were high (93.81/100 and 90.77/100, respectively).**Discussion:** In carefully selected patients, UKA-to-UKA revision performed according to a rigorous operative technique deserves a role in the surgical strategy for failed UKA.**Level of evidence:** III, multicentre retrospective case-control study.

© 2013 Published by Elsevier Masson SAS.

1. Introduction

Unicompartmental knee arthroplasty (UKA) has a number of specificities in terms not only of indications and operative technique, but also of the approach to and management of prosthetic failure. UKA is viewed by some authors as a temporary procedure, suggesting that revision surgery, when needed, may be best performed early, particularly as greater ease of revision would be expected with UKA than with total knee arthroplasty (TKA). Although UKA revision usually involves conversion to TKA [1–7], UKA-to-UKA revision may be an attractive option in patients with isolated prosthetic failure, moderate bone loss, intact ligaments, and no disease of the other knee compartments. The theoretical advantages of UKA-to-UKA revision include greater expected simplicity of the surgical procedure and improved functional outcomes, with the benefits related to preservation of the central pivot.

During the symposium on failed UKA organised in November 2011 by the French Hip and Knee Society (*Société Française de la Hanche et du Genou*, SFHG), data on UKA failures were analysed [8].

Here, our objective was to delineate the circumstances in which global or partial UKA-to-UKA revision can be considered, the characteristics of the surgical procedure, and the functional outcomes. Our working hypothesis was that, in carefully selected patients with failed UKA, revision UKA is a reliable option that may even produce lower morbidity rates and better functional outcomes compared to revision TKA.

2. Material and methods

Data on 425 UKA failures in 416 patients managed over the last 25 years were collected at the time of revision surgery at 23 centres and reported at the SFHG symposium [8]. Among these 425 cases, 36 were managed by UKA-to-UKA revision.

2.1. Case-series

The 36 UKA-to-UKA revisions were performed in 36 patients, 19 (52.8%) males and 17 females (47.2%), with a mean age at revision of 64.47 ± 11.19 years (range, 39–91 years) and a mean body mass index (BMI) of 28.59 ± 4.09 kg/m² (range, 21.48–37.46 kg/m²). The medial compartment was involved in 34 cases and the lateral compartment in 2 cases. The reason for initial UKA was osteoarthritis

* Corresponding author.

E-mail address: jae@orthowave.net (J.A. Epinette).

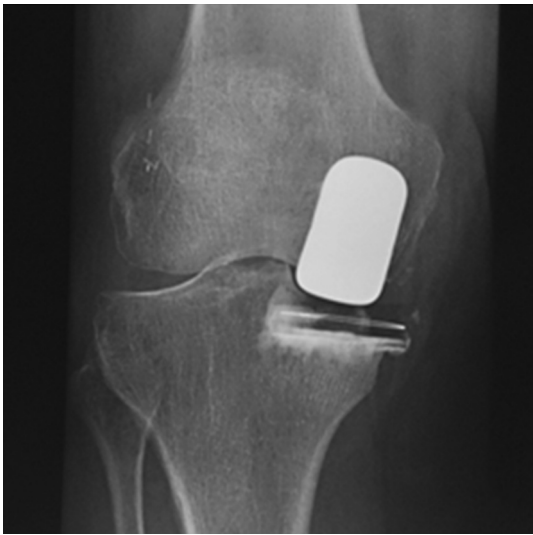

Fig. 1. Knee pain after unicompartmental arthroplasty (malposition): the femoral implant impinges on the spines and the tibial plateau is too wide.

in 29 (80.6%) patients, avascular necrosis in 6 (16.7%), and inflammatory joint disease in 1 (2.8%). At revision, both components were replaced in 8 (22.2%) knees, the femoral component only in 7 (19.4%) knees, the tibial component only in 19 (52.8%) knees, and the insert only in 2 (5.6%) knees.

Loosening was the main reason for UKA-to-UKA revision, with 23 (63.9%) knees, including 16 (44.4%) with tibial component loosening, 4 (11.1%) with femoral component loosening, and 3 (8.3%) with loosening of both components. In 3 (8.3%) cases, revision was required by wear, which was isolated in 2 cases and accompanied with metallosis in 1 case. In 2 (5.6%) cases, polyethylene wear of the metal-backed insert diagnosed based on severe and progressive narrowing of the interprosthetic joint space was managed by replacing only the insert. At revision, the surgeon identified technical errors responsible for prosthesis failure in 8 (22.2%) cases. In 3 of these cases (1 lateral and 2 medial replacements), marked peripheral overhang caused pain and required replacement of the tibial component only (Fig. 1). In 3 other knees, faulty positioning of the femoral component led to impingement on the tibial spines and required replacement of the femoral component only in 2 cases and of both components in 1 case. In 1 case of medial UKA, over-correction was managed by replacing the tibial component only, with a thinner tibial plateau. Finally, in 1 case, faulty insert clipping resulted in osteolysis under the plateau, which was treated by implantation of a cemented polyethylene plateau (Fig. 2). No cases of infection were recorded.

The time to revision varied widely. Revisions for technical errors were performed within the first 2 years and those for wear after the first 5 years. Revisions for loosening occurred up to 20 years after the initial UKA.

Bone loss was limited in these revisions. At the femur, the bone defects were grade 1 in 67% of cases and grade 2A in 33%. At the tibia, the grades were 1 in 69% of cases, 2A in 25%, and 2B in 6%. Grafting was rarely performed: cortical-cancellous bone was grafted on the femoral side in 9% of cases and under the tibial plateau in 14% of cases.

2.2. Methods

We collected the study data via the Internet using OrthoWave™ software (ARIA, Bruay Labuissière, France) to record all the features of the initial and revision procedures. Functional outcomes were

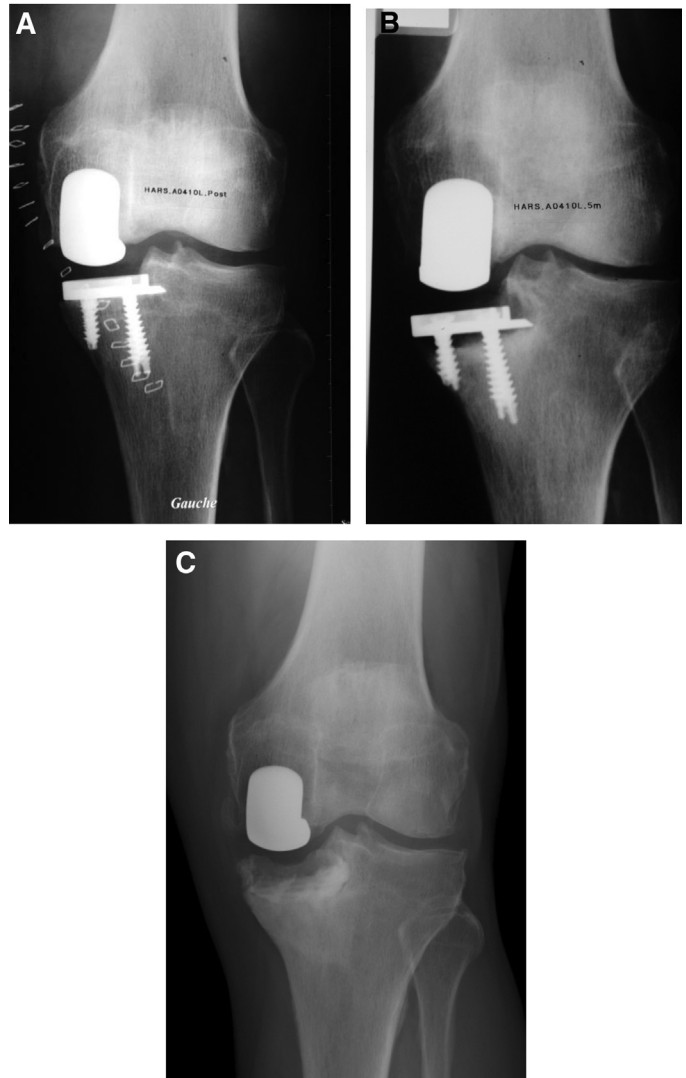

Fig. 2. Cementless metal-backed prosthesis: faulty clipping of the insert. A. Satisfactory appearance in the immediate post-operative period. B. Vast osteolytic defect under the tibial plateau 5 months later. C. Revision by implantation of a cemented polyethylene insert: excellent result 6 years after the revision (total IKS score, 200).

assessed using the International Knee Society (IKS) scores, and the degree of bone loss was evaluated.

Multivariable statistical analyses were performed, and groups were compared using the non-parametric Kruskal-Wallis test, Student's *t* test, and Pearson's χ^2 test. Values of $p \leq 0.05$ were considered significant. Kaplan-Meier survival curves were plotted using prosthesis failure as the endpoint; however, the sample size was too small to produce reliable curves beyond the first 3 years. Consequently, iterative revisions were assessed based on the frequency, circumstances, and subsequent outcome of failures.

Within the initial cohort of 425 UKA failures, we identified 38 cases of UKA-to-TKA revision matched to the 36 UKA-to-UKA revisions on age, BMI, sex distribution, degree of bone loss, and mean clinical follow-up time. We then compared outcomes between these two groups.

3. Results

At the time of the study, of 36 prostheses, 32 (88.9%) were still in place and 3 (8.3%) had failed and been removed; 1 (2.8%) patient had died of an unrelated cause.

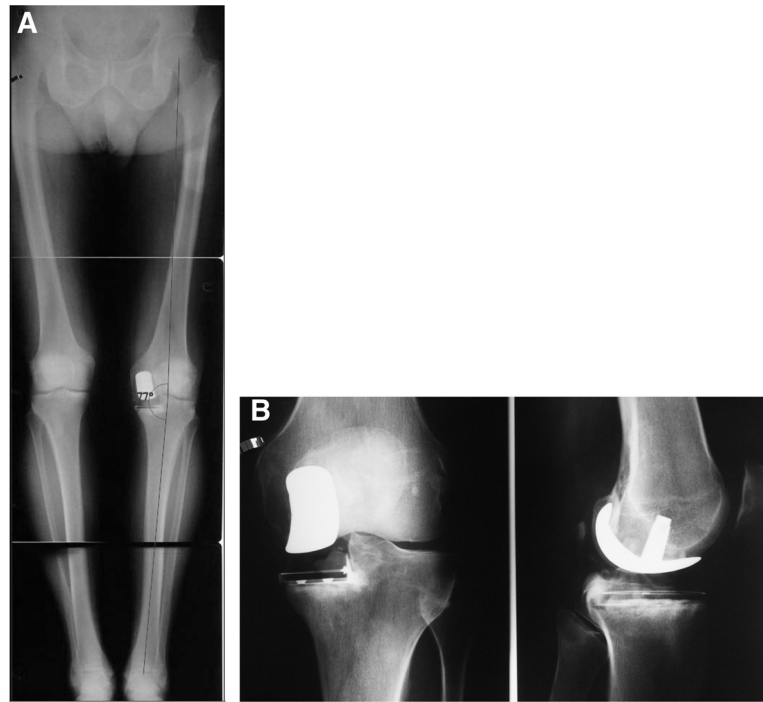


Fig. 3. Failed unicompartmental knee arthroplasty revision after 1 year, with aseptic loosening of the tibial component. Revision total knee arthroplasty with an excellent outcome. A. Full-length radiograph of both lower limbs before iterative revision. B. Lateral radiograph before iterative revision; obliquity of the condyle inducing peripheral loading of the plateau.

3.1. Complications

No intra-operative or early complications were recorded for any of the 36 UKA-to-UKA revisions. Failure requiring iterative revision occurred for 3 (8.3%) knees, after 8 months, 9 months, and 3 years, respectively. Aseptic loosening was the reason for failure in all 3 cases. The underlying mechanisms, however, differed across these 3 knees. A 63-year-old man who had cemented UKA performed because of inflammatory joint disease experienced loosening of both components within the first year. He subsequently required three revisions with TKA but finally achieved a satisfactory total IKS score (180 after 4 years). The other 2 failures involved the cemented tibial plateau. A 55-year-old man with a pre-operative hip-knee-ankle angle of 177° had marked condylar obliquity that clearly induced excessively peripheral loading of the tibia (Fig. 3A and B). TKA was performed and the outcome was favourable with a total IKS score of 195 after 4 years. The other case of aseptic tibial component loosening occurred after 3 years in a knee with a cemented metal-backed medial plateau, well-positioned implants, and no mechanical axis malalignment. Tibial component replacement was successful in producing a good outcome (Fig. 4).

3.2. Clinical outcomes

Mean clinical follow-up was 8.3 ± 6.74 years (range, 1–23 years); follow-up was longer than 5 years for 59.3% of knees and longer than 10 years for 29.6% of knees. For 9 knees, the functional outcome was satisfactory but disabilities due to other conditions precluded a quantitative assessment. The IKS knee and function scores were determined for the remaining 27 knees. At last follow-up, the mean IKS knee score on the 100-point scale was 93.81 ± 9.26 (range, 69–100) and 38.5% of knees had the maximal score of 100. The mean IKS function score, also on a 100-point scale, was 90.77 ± 15.41 (range, 45–100) with 65.4% of knees having a score of 100. Summing the two scores produced a total IKS score on 200 of 184.58 ± 23.11 (range, 122–200), with 38% of knees having the maximal score of

200. The clinical outcome was considered excellent for 80.8% of knees, good for 11.5% of knees, and fair for 7.7% of knees.

Loosening was the reason for revision for two-thirds of the 36 knees. Clinical outcomes did not differ significantly between the knees with loosening and those with other reasons for revision: the mean IKS knee score was 92.53 ± 10.44 (range, 69–100) in the group with loosening and 96.22 ± 6.34 (range, 82–100) in the group with other reasons ($p = 0.3437$, non-significant). The mean IKS functional scores were 90.59 ± 15.9 (range, 45–100) and 91.11 ± 15.37 (range, 60–100) ($p = 0.9363$, non-significant).

For 2 knees, only the insert was replaced. In 1 of these 2 cases, iterative wear required replacement of the insert 9 years later. Long-term outcomes were favourable in these 2 cases, with IKS knee scores of 100 and 90 and IKS function scores of 100 and 100 after 21 and 16 years, respectively.

Evaluation of the radiographs obtained at last follow-up showed no evidence of wear, progressive lucent lines, or obvious extension of the lesions to the adjacent knee compartments.

Compared with the UKA-to-UKA revision group, the matched group of 38 UKA-to-TKA revisions had similar bone loss (grades 1 and 2A) and clinical follow-up times (8.3 vs. 7.9 years). The mean IKS knee score was 87.11 ± 15.38 (range, 37–100), the mean IKS function score was 84.47 ± 16.01 (range, 55–100), and the mean total IKS score was 171.58 ± 27.33 (range, 97–200). Although for each of these three scores the values were higher in the UKA-to-UKA group than in the UKA-to-TKA group, the differences were not statistically significant ($p = 0.051$ for the knee score and $p = 0.122$ for the function score). In the UKA-to-TKA group, 1 (2.6%) prosthesis was removed because of deep-seated infection and 3 (7.9%) because of prosthesis failure. Thus, the failure rate was similar to that seen in the UKA-to-UKA group.

4. Discussion

This study collected a vast cohort of 425 revisions for failed UKA performed at 23 centres over more than two decades. Most of

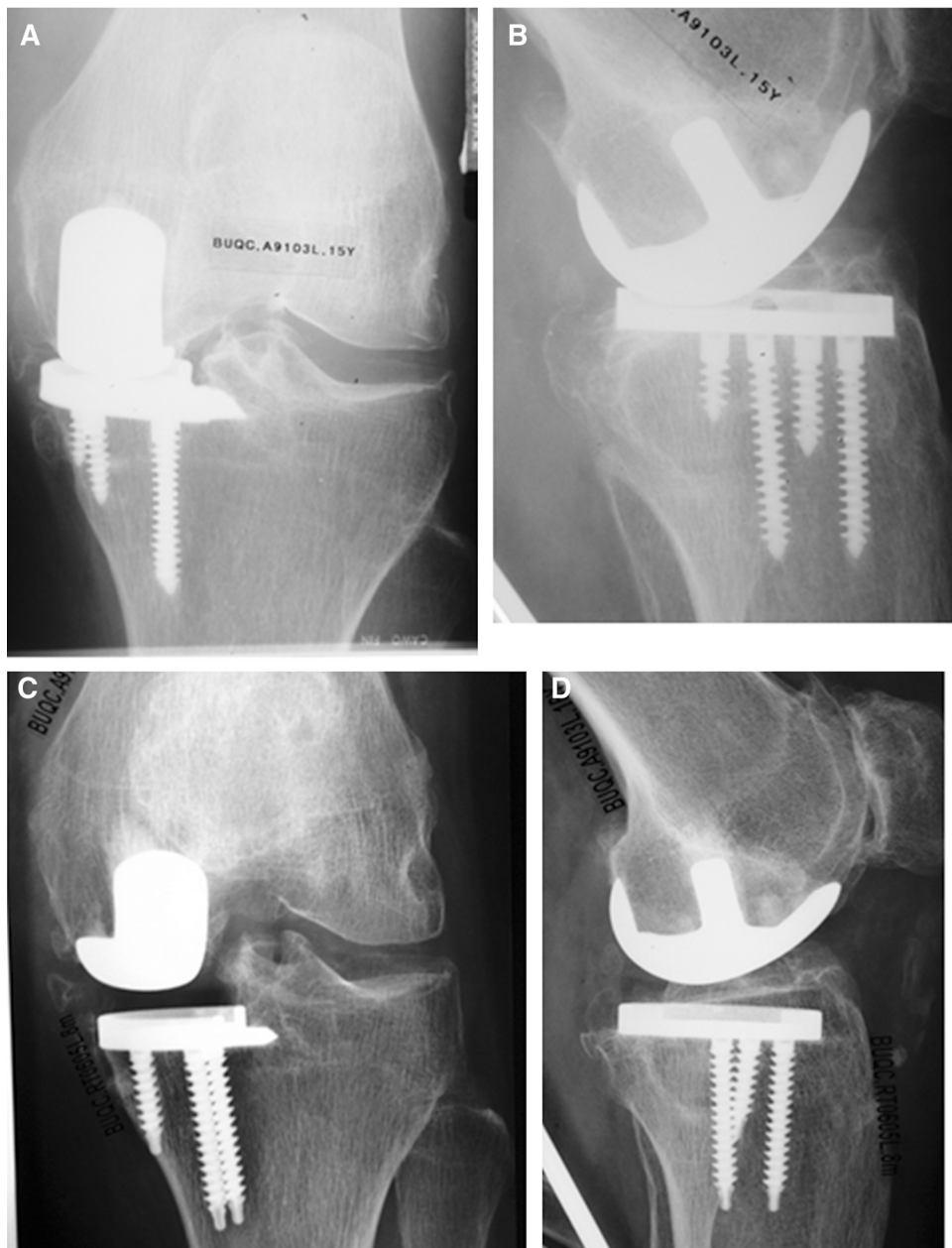


Fig. 4. Excellent result 7 years after replacement of the tibial component of a medial unicompartmental prosthesis that showed massive wear after 15 years. A and B Massive wear before revision. C and D. Excellent result 7 years after revision.

these revisions consisted in TKA. Here, we focussed on the cases of UKA-to-UKA revision involving the same compartment. The multicentre retrospective design and inclusion of a large number of knees affected the completeness of data collection, thereby limiting the statistical analysis and the development of definitive conclusions. In particular, over time the number of cases became too small for a meaningful survival curve analysis. Nevertheless, the comparison to the Australian and Swedish registries [9–11] in the article reporting the first part of the symposium results [8] supports the conclusions and representative nature of our SFHG case-series. Of the 425 cases of failed UKA, 36 were managed by UKA-to-UKA revision ($n = 36$, 8.5%; 32 medial, 2 lateral and 2 isolated medial insert replacements).

Few data on UKA-to-UKA revision have been published. Lustig et al. [1] reported that UKA was performed in only about 7% of revisions for failed UKA. Similarly, in the latest report on the Swedish registry published in 2012 [12], only 5.6% of revisions did not

consist in TKA. The 2012 report on the Australian registry indicated that total or partial UKA revision accounted for only 8% of 3359 UKA failures [13]. These data are consistent with the 8.5% UKA-to-UKA rate in the multicentre SFHG cohort.

Our working hypothesis was that, in carefully selected patients, UKA-to-UKA revision can be a reliable option and may even provide lower morbidity rates and better functional outcomes than UKA-to-TKA revision. Overall, the outcomes of UKA-to-UKA revision were favourable in our study. The failure rate was only 3/36 (8.3%), and all failures were due to repeated aseptic loosening. Our analysis of these failures confirms that, in the event of UKA-to-UKA revision, the fate of the new prosthesis depends on the same implantation rules as those relevant to primary UKA. Only patients with osteoarthritis or avascular necrosis and limited bone lesions are eligible for UKA-to-UKA revision, which is not appropriate in patients with inflammatory joint disease. The rules that govern component implantation and positioning must be followed

scrupulously, failing which complications are inevitable. Thus, based on the Swedish registry, Lewold et al. [14] concluded that UKA-to-TKA revision was mandatory and provided 3-fold greater survival times than UKA-to-UKA revision. However, this conclusion was based on nationwide data obtained from multiple surgeons, some of whom were insufficiently experienced. Although UKA is a challenging procedure, UKA-to-UKA revision is more challenging still and requires special training and considerable experience on the part of the surgeon. In the SFHG case-series, all revisions were performed by highly experienced surgeons.

The mean IKS knee and function score values of 93.8 and 90.8, respectively (mean total IKS score, 184.6) after a mean clinical follow-up of 8.3 years are consistent with those reported by Tinius et al. [15] in a study of 116 UKA-to-UKA revisions. The total IKS score in this previous study was 167.4 (range, 144–173) after a mean follow-up of 3.8 years, a value similar to that obtained by the authors after primary UKA. Furthermore, the results in the SFHG case-series are better overall than those recorded after UKA-to-TKA revision by Lustig et al. [1] (IKS knee score, 86; and IKS function score, 76) or by Saragaglia et al. [5] (86.3 and 80.4, respectively). It should be noted that the bone defects at revision in these two earlier studies were larger overall in the UKA-to-TKA revisions than in the UKA-to-UKA revisions. However, detailed data on the degree of bone loss at revision were not provided, precluding a formal comparison with our case-series. Nevertheless, our comparison of two matched cohorts taken from the overall SFHG cohort showed no significant differences between UKA-to-TKA and UKA-to-UKA revisions.

5. Conclusion

Our study of 36 UKA-to-UKA revisions confirmed our working hypothesis, at least in part. Thus, although UKA-to-TKA revision remains the most widely used strategy, it should not be adopted routinely for the management of failed UKA. UKA-to-UKA revision in patients with limited bone defects and no extension of the lesions can constitute a reliable option associated with both low morbidity rates and good clinical outcomes related to optimal preservation of the knee ligaments and kinesiology. Although only about 8% of UKA failures were managed by UKA revision in the various studies published to date, this strategy, when used in specific indications and in carefully selected patients by experienced surgeons who follow a rigorous operative technique, deserves a place among the surgical options for failed UKA.

Disclosure of interest

None of the authors declares any conflict of interest directly related to the article. In fact, JAE is a consultant for Stryker and received travel support for attending a scientific meeting (De Puy), GP is an educational consultant for Zimmer; GD receives royalties from Tornier; and DS received travel support for attending a scientific meeting. ML declares no conflicts of interest.

Acknowledgements

This multicentre study would have not been carried out without the sound involvement of the 23 Institutions, which agreed to feed the database of the symposium. We wish to express our best thanks and gratitude to the participating surgeons; Argenson Jean-Noël (Marseille); Bloch Anthony (Aix-en-Provence); Bonnin Michel (Lyon); Callas Philippe (Aix-en-Provence); Cartier Philippe (Paris); Cazenave Alain (Berck sur mer); Chambat Pierre (Lyon); Chatain Frédéric (Grenoble); Chol Christophe (Dracy-le-Fort); Dejour David (Lyon); Deschamps Gérard (Dracy-le-Fort); Épinette Jean-Alain (Bruay-Labuissière); Hernigou Philippe (Paris); Lerat Jean-Luc (Lyon); Mertl Patrice (Amiens); Migaud Henri (Lille); Mole Daniel (Nancy); Moyen Bernard (Lyon); Pasquier Gilles (Lille); Rouvillain Jean-Louis (Fort-de-France); Saragaglia Dominique (Grenoble); Tabutin Jacques (Cannes); Trojani Christophe (Nice).

References

- [1] Lustig S, Parratte S, Demey G. Reprises de prothèse unicompartmentale par prothèse totale de genou. In: Prothèses partielles de Genou, Cahiers d'Enseignement de la SoFCOT. Elsevier Masson; 2012. p. 128–37.
- [2] Chatain F, Richard A, Deschamps G, Chambat P, Neyret P. Revision total knee arthroplasty after unicompartmental femorotibial prosthesis. *Rev Chir Orthop Reparatrice Appar Mot* 2004;90:49–57.
- [3] Deschamps G, Cartier P. Revision of unicompartmental prosthesis. In: Cartier P, Epinette JA, Deschamps G, Hernigou P, editors. *Unicompartmental knee arthroplasty*, vol. 61. Paris: Elsevier Publisher; 1997. p. 152–5.
- [4] Levine WN, Ozuna RM, Scott RD, Thornhill TS. Conversion of failed modern unicompartmental arthroplasty to total knee arthroplasty. *J Arthroplasty* 1996;11:797–801.
- [5] Saragaglia D, Estour G, Nemer C, Colle PE. Revision of 33 unicompartmental knee prostheses using total knee arthroplasty: strategy and results. *Int Orthop* 2009;33:969–74.
- [6] McAuley JP, Engh GA, Ammeen DJ. Revision of failed unicompartmental knee arthroplasty. *Clin Orthop Relat Res* 2001;(392):279–82.
- [7] Springer BD, Scott RD, Thornhill TS. Conversion of failed unicompartmental knee arthroplasty to TKA. *Clin Orthop Relat Res* 2006;446:214–20.
- [8] Epinette JA, Brunschweiler B, Mertl P, Mole D, Cazenave A, French Society for Hip and Knee. Unicompartmental knee arthroplasty modes of failure: wear is not the main reason for failure. *Orthop Traumatol Surg Res* 2012;98(6 Suppl.): S124–30.
- [9] Sundberg M, Lidgren L, Dahl AW, Robertson O. The Swedish Knee Arthroplasty Register. Annual report; 2011 <http://www.knee.nko.se/english/online/thePages/contact.php>
- [10] Tomkins A. National Joint Replacement Registry. Annual report. Australian Orthopaedic Association; 2011 <http://www.surfacehippy.info/pdf/australian-nat-reg-2011.pdf>
- [11] Dahl AW, Robertsson O, Lidgren L, Miller L, Davidson D, Graves S. Unicompartmental knee arthroplasty in patients aged less than 65 - Combined data from the Australian and Swedish Knee Registries. *Acta Orthop* 2010;81: 90–4.
- [12] <http://www.knee.nko.se/english/online/thePages/publication.php>
- [13] <https://aoanjrr.dmac.adelaide.edu.au/annual-reports-2012>
- [14] Lewold S, Robertsson O, Knutson K, Lidgren L. Revision of unicompartmental knee arthroplasty: outcome in 1135 cases from the Swedish Knee Arthroplasty study. *Acta Orthop Scand* 1998;69:469–74.
- [15] Tinius M, Klima S, Marquass B, Tinius W, Josten C. Revision possibilities after failed unicompartmental knee arthroplasty: an analysis of 116 revisions. *Z Orthop Ihre Grenzgeb* 2006;144:367–72 [In German].