


Available online at
 ScienceDirect
www.sciencedirect.com

Elsevier Masson France
 EM|consulte
www.em-consulte.com/en

**Orthopaedics
& Traumatology**
 Surgery & Research

REVIEW ARTICLE

Chondral repair of the knee joint using mosaicplasty[☆]

H. Robert

Orthopaedic Department, Nord Mayenne Hospital, 229, boulevard Paul-Lintier, 53100 Mayenne, France

Accepted: 4 March 2011

KEYWORDS

Knee;
 Osteochondral graft;
 Osteochondritis;
 Osteochondral defect;
 Cartilage repair

Summary Mosaicplasty grafting is performed by transferring one or more cylindrical osteochondral autografts from a low weight-bearing area of the knee towards the defective site, usually the femoral condyle. Numerous biomechanical, histological, animal and clinical studies have evaluated the different technical aspects of this procedure. The preoperative work-up encompasses an evaluation of functional disturbances, alignment, knee stability and imaging (CT arthrography or MRI with cartilage sequences). The surgical procedure includes harvesting the grafts by mini-arthrotomy of the medial or lateral trochlea and a stage for arthroscopic graft insertion. The ICRS classification is used to describe the defect (area, depth, location) before and then after debridement. A few, large diameter grafts are harvested from the trochlea across from the defect. The graft plugs are transplanted by press-fit, flush with the cartilage, along a convergent plane in recipient sockets of exactly the same depth. Each stage, harvesting, drilling and insertion is repeated until all the full-thickness gap region has been covered. Postoperative movement is free but weight-bearing is delayed for 2 to 4 weeks. Mosaicplasty is indicated in young patients (under 50), with symptomatic chondral or osteochondral defects of less than 3 cm in the weight-bearing part of the femoral condyle. Pre-osteoarthritis is an absolute contraindication for this procedure. Any misalignment (of more than 5°) or sagittal instability is treated simultaneously. This is a difficult and demanding procedure.

© 2011 Elsevier Masson SAS. All rights reserved.

Articular cartilage has a very low potential for spontaneous repair [1,2]. Deep chondral defects in a weight-bearing area are at high risk of progressing to osteoarthritis [3,4]. The frequency of chondral defects is 63%, but only 5% of these are deep defects (ICRS grades III and IV) in patients under

40 [5]. Treatment of focal substance loss in the knee is still a difficult and controversial subject in 2011. In the past 50 years, numerous techniques have been attempted to repair focal defects in weight-bearing areas of the knee to obtain tissue called 'hyalin-like' that is as close as possible to hyalin cartilage. At the beginning of the 1960s, multiple holes were drilled into subchondral bone to try to stimulate stem cells and favor mainly fibrochondral regeneration. This technique was re-introduced by Steadman and called "Microfracture" [6]. Microfractures are only

[☆] This paper is from an instructional lecture presented by H. Robert during the 85th Sofcot Annual Meeting (November 2010).
 E-mail address: henri.robert@wanadoo.fr

indicated for small, recent substance loss in young subjects [7]. After 1983, autologous cultured chondrocytes were developed by Brittberg and Peterson [8]. The cell cultures obtained by transfer in a cell therapy laboratory were then injected under a periosteal flap. The results were satisfying but the technique is difficult and not completely satisfactory (harvesting and suturing of the flap is difficult, with irregular spatial distribution of the cells). At present, autologous chondrocytes or stem cells are transplanted into a matrix by arthroscopy. Numerous osteochondral grafts were developed in the 1990s, and are extensively used because they are easier and less expensive to perform. This technique can be applied to many different joints: knee, ankle, elbow, shoulder... but this update will be limited to the knee.

Historical background

Several authors have developed a procedure using large osteochondral grafts from the patella [9], the posterior femoral condyle [10], and the medial trochlea [11]. These techniques are invasive, do not provide a congruent graft, and can disturb articular biomechanics.

The use of several osteochondral cylinders can compensate for these disadvantages and the first case was published by Matsusue et al. in 1993 [12]. This was a 15 mm diameter chondral defect of the femoral condyle, associated with an anterior cruciate ligament tear. Bobic [13] published results in 1996 and Hangody developed the multiple graft technique called "Mosaicplasty" in 1992 and reported the results in 1997 [14].

Experimental studies in dogs [15] and horses have shown that at 4 weeks, there was osseous integration but that a gap remained in the cartilage between the donor and recipient site; at 8 weeks the connective tissue between the plugs was fibrocartilage; and at 1 year, the cartilage covered 60–70% of the graft area.

Biomechanical and histological background

There are several questions.

What is the minimum sized defect for an indication of chondral graft?

A biomechanical study of cadaveric knees shows a peak in pressure on the periphery of defects greater than 10 mm in diameter [16]. A smaller defect does not influence peripheral pressure. A threshold of 9 mm was defined by Convery et al. in a study of the horse [17]. A threshold of 10 mm has been adopted by numerous authors as an indication for chondral repair in a weight-bearing area [4,8].

What is the importance of the stress reduction provided by an osteochondral graft?

Loss of 16 mm of chondral substance (2 cm²) in a weight-bearing area of the human femoral condyle increases peripheral stress by 92%. If three 8 mm grafts are implanted, stress is only increased by 35% on the periphery of the

defect. Stress in the area of the graft remains less than 30% of intact femoral condyle stress [18].

What is the ideal site for harvesting?

Theoretically an area with low stress whose curve and thickness are similar to that of the recipient site.

Areas with low stress

Garretson et al. [19] studied contact pressure on the sides of the trochlea with electroresistant dynamic pressure sensors during flexion movements between 0 and 105°. Contact pressure was low on the medial trochlea and the lower lateral trochlea. Because of the different widths of these two areas, small grafts should be harvested from the medial trochlea and larger grafts from the low lateral trochlea.

Area with similar convexity

Restoring the curvature of the condyle is important to obtain good distribution of stresses. Any loss in curvature creates a risk of under- or over-stressing the graft. Two cadaveric studies have shown that the medial or lower lateral trochlea (above the intercondylar groove) provides the best curve for condyles because the upper section is more convex. The rim of the groove is flat and can be used to restore the trochlea [20,21].

Area with the best thickness

Cartilage thickness varies depending on the area of the knee and is proportional to stress. Several studies have measured cartilage thickness in different donor sites: medial and lateral trochlea, intercondylar notch by arthroscore [22] or in cadaveric knees [20]. For Thauat et al., the thickness of the donor site is a mean 1.8 mm (1.33–1.97 mm), and is therefore thinner than that of the condyle weight-bearing area, which is the usual recipient site, and which is 2.5 mm (2.41–2.69 mm). The thickness is greater on the sides of the trochlea compared to the intercondylar notch, especially the lateral side [22].

What is the most reliable harvesting technique?

The study by Keeling et al. [23] comparing harvesting by arthrotomy and arthroscopy showed that grafts (7 mm diameter) had an incongruence of less than 1 mm in 57% and 69% of the cases respectively. Although the arthroscopic technique may be more reliable, it is more difficult, in particular for the lateral side of the trochlea and there is a risk of marginal fractures. Surface incongruence increases graft diameter for the same angular defect.

What factors influence graft stability?

Vertical stability in relation to graft size

Different diameter (8 and 11 mm) and different length (10, 15 et 20 mm) grafts were tested in pig femurs with axial tears. Grafts of 11 mm in diameter and 15 and 20 mm long had the best resistance [24].

Vertical stability in relation to recipient socket depth

Kock et al. [25] compared stability during axial loading in a cadaveric study of grafts with perfect depth matching and in shorter grafts. Grafts which were adjusted for length were two to three times more stable.

Horizontal stability with press-fit

Two types of grafts were implanted into rabbit condyles: with or without a press-fit effect. In the first group without press-fit at 24 weeks, the cartilage was thicker, chondrocyte density was increased and there were numerous hypertrophic chondrocyte clusters. In the second group, with a press-fit effect, the cartilage was unchanged [26]. Slightly wider plugs are preferable to preserve the mature state of the cartilage [27].

What is the consequence of graft surface incongruence?

A study in sheep compared three types of graft surface: congruent, countersunk 1 mm, and countersunk 2 mm. If the graft is congruent or countersunk 1 mm, the hyalin is preserved and is hypertrophic, but above that necrosis occurs. A graft without stress seems to disappear [28].

What is the risk of graft insertion on cell viability?

A cadaveric study by Patil et al. [29] showed that the insertion force of 8 mm diameter grafts did not affect cell viability as long as it remained below a threshold of 400 N (force < 10 MPa) and that the graft and recipient site are the same length. If the graft plug is longer than the recipient site, insertion force is above 15 MPa, which damages chondrocytes [30]. Several low force insertions are less dangerous for chondrocytes than fewer high force insertions.

What is the outcome of transplanted grafts?

Lane et al. [31] transplanted two trochlear grafts on the condyle of six adult goats. At 3 months the surface of 10/12 grafts appeared normal, while two cases of surface fibrillation were noted. The bony interface of the plug was completely consolidated into the recipient site, but there was no healing of the cartilage surface. Ninety-five percent of the grafts were shown to be viable by confocal microscope, and were synthesizing glycoaminoglycans. Kock et al. [32] performed a histological analysis of one case of mosaicplasty of three grafts on the medial condyle in a 49-year-old man. Because of a clinical failure 3 years after surgery, the entire grafted condyle was removed for total knee arthroplasty and studied. Osseous integration was good, the surface hyaline cartilage was viable, the "tide mark" was continuous but a fissure remained between the plug and the adjacent cartilage of the recipient site.

What is the outcome of the donor site?

Normally, the donor site is left empty and secondary arthroscopic follow-up has shown surface depression and fibrous tissue in deeper areas [33]. Certain authors have tried to fill

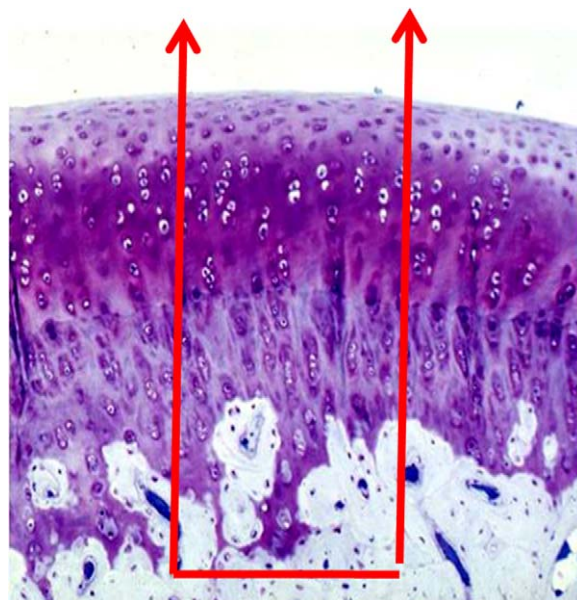


Figure 1 Harvesting of a functional graft of hyalin cartilage and subchondral bone.

this area with an osteoperiosteal plug from the tibia [34]; however these attempts have not resulted in quality bone filling.

In conclusion

Grafts from the medial and lateral femoral trochlea and the area above the sulcus terminalis successfully restore a condylar defect. Graft diameter should be large, should be as long as the recipient core sites and inserted by press-fit. The osteochondral graft remains viable, osseous integration occurs with the recipient site, while healing on the surface is less frequent.

Advantages and disadvantages of the autologous osteochondral grafts

Advantages

The osteochondral graft is a viable functioning unit, which provides hyaline cartilage on a bony support (Fig. 1). Graft size can be adapted within certain limits to the recipient site. This is a one-stage procedure that does not require a laboratory or cell therapy. Risk of infection is low and there is no risk of rejection.

Disadvantages

Harvesting and implantation with this technique must be very carefully performed to obtain maximum coverage ($\geq 80\%$) with stable and well-integrated grafts. Harvesting of several grafts may result in postoperative pain.

Preoperative evaluation

Clinical

Focal cartilage substance loss in the knee may occur after a direct trauma or osteochondritis. There are no specific clinical signs of chondral defects, but they are suggested by the association of pain when the knee is in certain positions, effusion, and locking. A clinical examination should investigate pain during condylar or patellar pressure, which may suggest the location of the defect. Sagittal or frontal laxity should also be searched for as well as frontal misalignment. Clinical evaluation of the patient should include the medical history, the level of sports activity and the body mass index (BMI).

Imaging

Imaging should include at least weight-bearing AP and lateral view X-rays to identify any tibiofemoral impingement, which would be a contraindication to repair, as well as to identify any existing osteochondritis dissecans. A 30° femoropatellar view shows centering of the patella and the thickness of the sides of the trochlea which may be the donor site. Analysis of surface and deep osteochondral substance loss is based on CT arthrography, MRI or arthro-MRI. Based on these imaging results, the depth of the defect can be classified according to the four ICRS grades. If necessary spiral CT arthrography can be used to obtain inframillimetric slices and reconstruction on all planes, but great care should be taken when reading these results. Defects of more than 50% of cartilage thickness and fissures are better identified with CT arthrography than with MRI [35] and with better specificity [22]. Classic MRI sequences (Spin echo T1, Gradient echo T1 or T2) identify at most 53% of chondral defects [7,35] but the results are highly specific. However superficial defects may be missed. In the absence of recent trauma, subchondral bone defects suggest deep chondral defects (grade 3 or 4). Specific cartilage sequences: 3D gradient echo T1 sequences with fat saturation provide 3–4-mm thick slices on three spatial planes and fast spin echo T2 (FSE) sequences

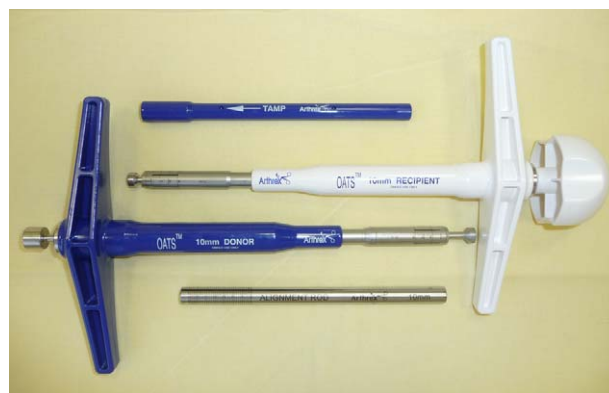

Figure 2 “Single use OATS®” instrumentation from the Arthrex Company.

with fat saturation improve these results [35]. Arthro-MRI is indicated to evaluate osteochondritis dissecans or recipient cancellous bone as well as to evaluate the surface of traumatic defects [36]. Indeed, these lesions may be crater-like, surrounded by unstable flaps and only the deep part can be identified and diagnosed by MRI alone, which often results in underestimation of the surface [37]. At present T2 mapping sequences provide further information about the organization of collagen matrix and the extent of the defects.

Mosaicplasty technique

We describe our step-by-step arthroscopic technique for defects of the femoral condyle with the system we usually use (Single use OATS®; Société Arthrex) (Fig. 2).

Installation

The patient is in the supine position. Flexion of up to 120° should be possible. A tourniquet is placed and can be inflated if necessary. The foot is placed in a knee bar to keep the knee flexed at an angle to obtain a perpendicular view of the defect. This angle is determined by a lateral view X-ray

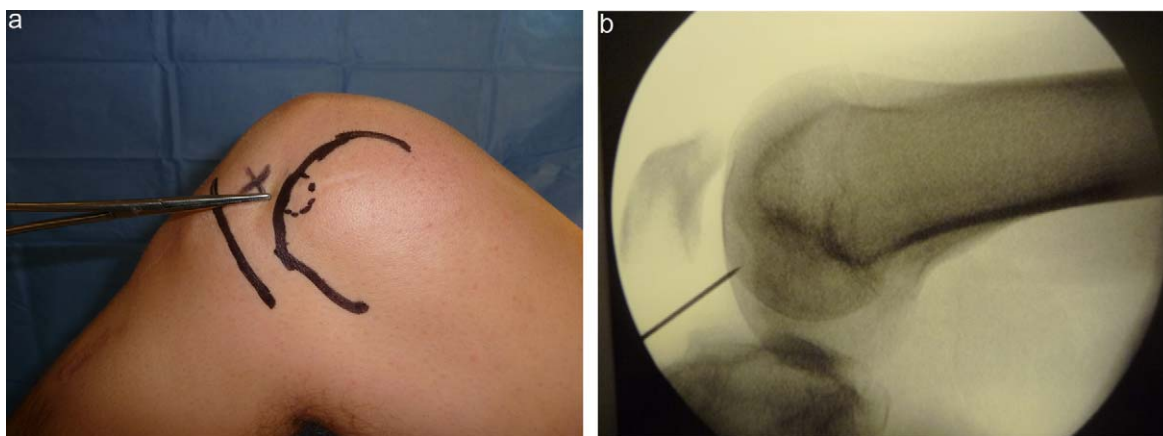


Figure 3 a: the patient is installed in the supine position on a knee bar; b: radioscopic control confirms that the degree of knee flexion is sufficient to have direct access to the graft site.

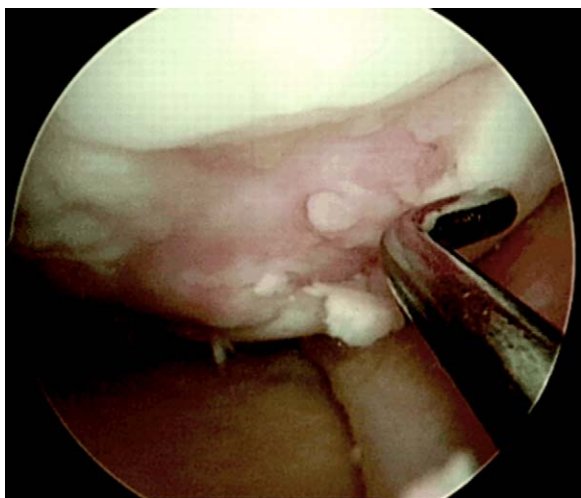


Figure 4 Arthroscopic measurement of the size of the defects with a short hook probe.

with a clamp aimed towards the defect which does not cross the tibia (Fig. 3a and b).

Surgical approach

The arthroscopic portal is inferior-medial or inferior-lateral while the instrumental portal is directly across from the defect. The instrumental portal is chosen by testing with a long intramuscular needle (18-G) so that it is directly perpendicular to the condylar defect.

Arthroscopic evaluation

The condylar defect is evaluated according to the ICRS classification in nine sectors for location, and four grades of depth (defects are usually grade 3 or 4) The height and width are measured then photographed with the probe for scale. The defect is excised and debrided to obtain healthy and clear edges, usually with a scalpel (blade 11) or a curette rather than a shaver. If poor quality edges remain, there is a risk of poor incorporation of the edges of the plugs. After debridement, the defect is precisely measured with a short probe (Fig. 4) whose length is known or with a long and tapered probe (Fig. 5) or by using the lesional arc technique [38]. The approach is determined by the location and surface of the defect: arthroscopic or mini-arthrotomy. If the defect is large and very posterior, arthroscopic access is difficult and arthrotomy will be used. In other cases, arthroscopy is possible if the surgeon has experience with this technique.

Planning

The number and diameter of grafts are chosen according to the size of the defect. Certain authors [7,30] prefer average sized grafts 5–7 mm, which requires more harvesting while others [13] harvest larger diameter grafts (10–11 mm). We prefer to harvest fewer, larger diameter grafts to improve stability, coverage and simplify the procedure. To simulate coverage of the defect, we use a flexible sizer/tamper with a known diameter, which is placed in the substance loss as

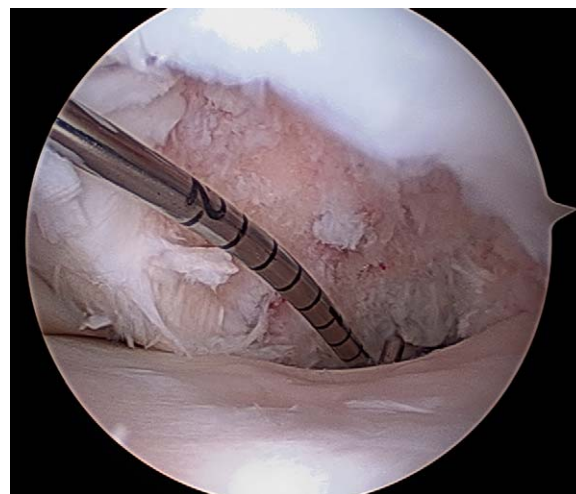

Figure 5 Measurement of the size of the defects with a long tapered hook probe.

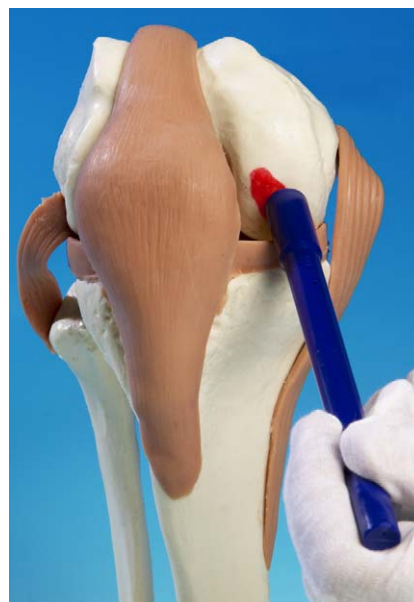


Figure 6 Estimation of the number of grafts needed with a cylindrical tamp that is the same size as the tubular harvesting chisel.

many times as is necessary (Fig. 6). Harvesting is limited to three large diameter grafts (10 or 11 mm) from the lateral trochlea above the sulcus terminalis, 8 or 9 mm grafts are harvested from the smaller medial trochlea; grafts from the intercondylar notch are limited to 6 mm. We only use one single-use autograft harvesting kit to reduce costs.

Harvesting the graft

Harvesting is usually performed by mini-parapatellar arthrotomy, 3 cm high, rather than by arthroscopy (Fig. 7a, b) beginning with the trochlea across from the femoral condyle defect. Thus to cover the medial condyle we harvest the lateral trochlea and vice versa. This allows us to differentiate donor site postoperative pain from that of the recipient site. If necessary we harvest around the intercondylar notch,

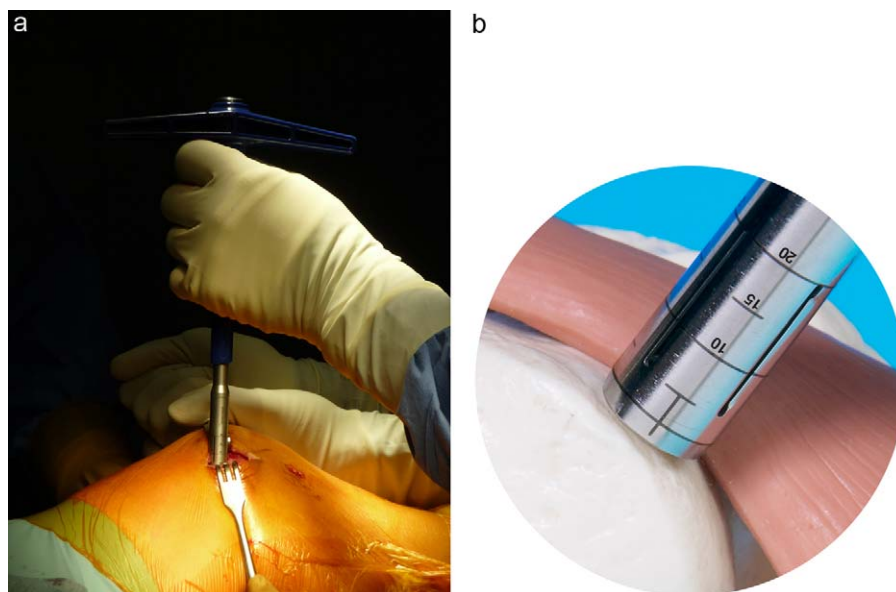


Figure 7 a et b: harvesting of three grafts by lateral arthrotomy from the trochlea. The tubular harvesting chisel should respect the dual perpendicularity of the trochlea and remain perpendicular to the cartilage surface.

under arthroscopy, because cartilage thickness and convexity is less good. Donor harvesting with the tubular chisel should be very careful and respect the dual perpendicular planes of the trochlea. Control is obtained with a laser marker, which should remain parallel to the surface throughout the procedure. A perfectly cylindrical graft is essential and can only be obtained if the tubular donor harvester remains absolutely perpendicular to the surface of the donor site but if 10° of misalignment occurs in the harvesting of a 10 mm graft, 1 mm of stepping will occur. The tubular donor harvester is impacted with a mallet (never a motor) to a depth of at least 15 mm, without rotating. The graft should be 15 mm long for a traumatic defect and 20 mm for osteochondritis dissecans. When the desired depth has been reached, the tubular donor harvester can be turned 180° several times and used as a lever to fracture the base of the plug. If rotation begins before reaching the fully desired depth, spiroid graft fracture will inevitably occur. The first graft is harvested just above the sulcus terminalis and the others above this. The length of the osteochondral donor graft is determined by the 'donor' harvester window (graduated alignment rod) to drill recipient sockets of exactly the same length. The graft is kept in its tube while the drilling is performed, and not in saline solution.

Graft implantation

The procedure is performed under arthroscopy. Drilling of recipient sockets is performed with a 1 mm diameter tubular chisel (recipient harvester) that is 1 mm smaller than the donor harvester to obtain a press-fit effect. The recipient harvester is positioned on the defect at the limit of debridement, in a perfectly perpendicular position, with the laser mark parallel to the healthy chondral surface. Impaction obtained with a mallet by arthroscopic control until a depth is reached that is the same as the harvested donor graft. The recipient chisel harvester can then be turned 180° sev-

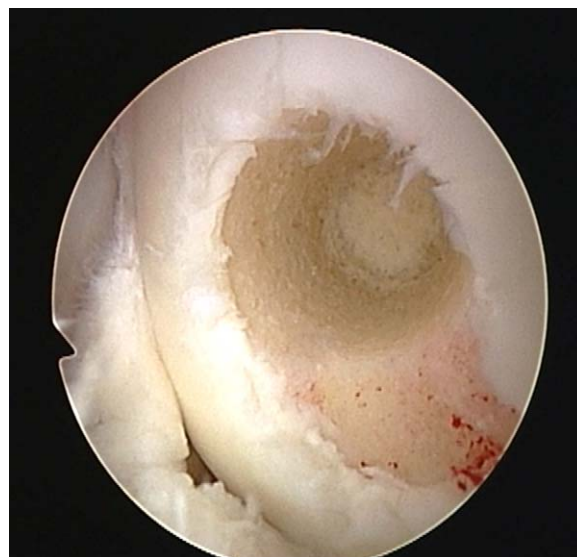

Figure 8 The first socket is drilled in the recipient site of the femoral condyle.

eral times and removed from the knee (Fig. 8). The length of the recipient sockets is confirmed with a flexible calibrated depth probe (Fig. 9). The graft removed from the recipient socket will be inserted into the donor site at the end of the procedure. The "donor" graft is placed opposite the condylar socket and gradually advanced by turning the graft delivery screw (Fig. 10a and b). When insertion is nearly complete, the instrument is removed and the graft is impacted with a flexible tamper. Ideally that should be positioned so that it is barely touching the healthy femoral condyle. When several grafts are necessary, the same procedure is repeated, harvest, drill and insert. The goal is to restore a convex surface so that each graft should be aimed towards the center of the condyle, which makes it

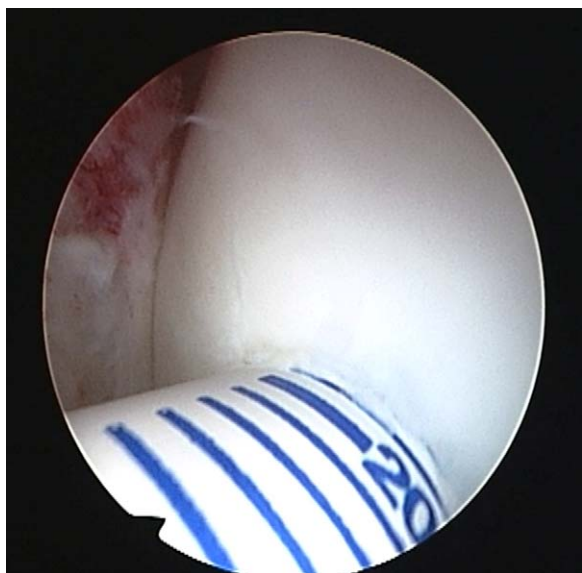

Figure 9 The length of the recipient socket is measured and should correspond to that of the graft.

necessary to 'touch' adjacent grafts while maintaining stability (Fig. 11a and b). This is only possible if each graft is firmly flushed with the base of the recipient socket. If graft convergence is not respected, the rebuilt surface will be flat, 'palissaded' and non-convex. The direction of each of the sockets should be radial and non-parallel (Fig. 12). The goal is to cover as much substance loss as possible with cartilage, at least 80%, and for grafts to fit as snugly as possible. If there is space between the sockets, they can be filled with a bone paste obtained by grinding a recipient graft. Once the grafts are in place, flexion-extension movements are made to make sure that the implant is perfectly stable (Fig. 13). The donor sockets are filled with plugs from the receiver sockets (Fig. 14). A redon drain is put in place and the incision is closed. There is no splint to limit mobility.

Mosaicplasty™ technique with the Smith & Nephew instrumentation

The steps are identical until drilling. The receiver socket is performed in two steps: drilling with a bit protected by a guide then dilation to the diameter of the graft. Insertion

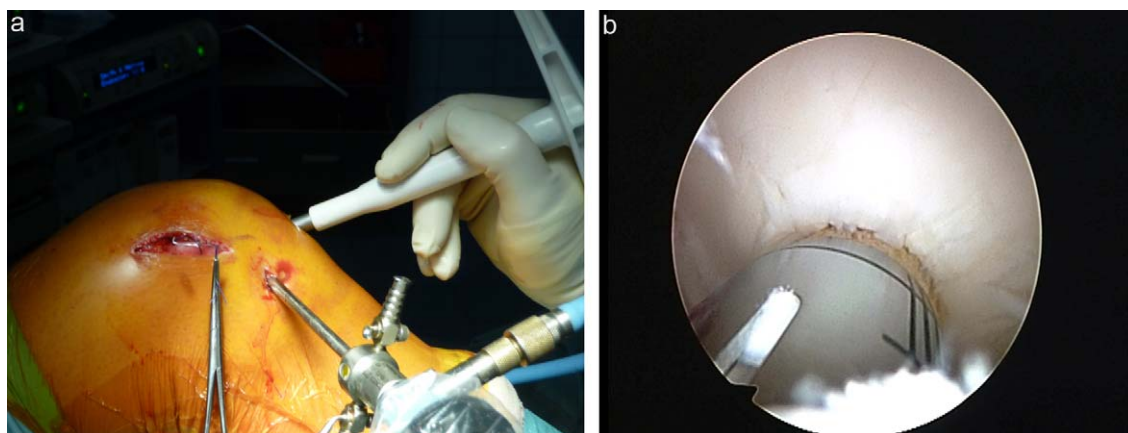


Figure 10 a et b: the graft is presented across from the socket and gradually inserted by tightening the screw.

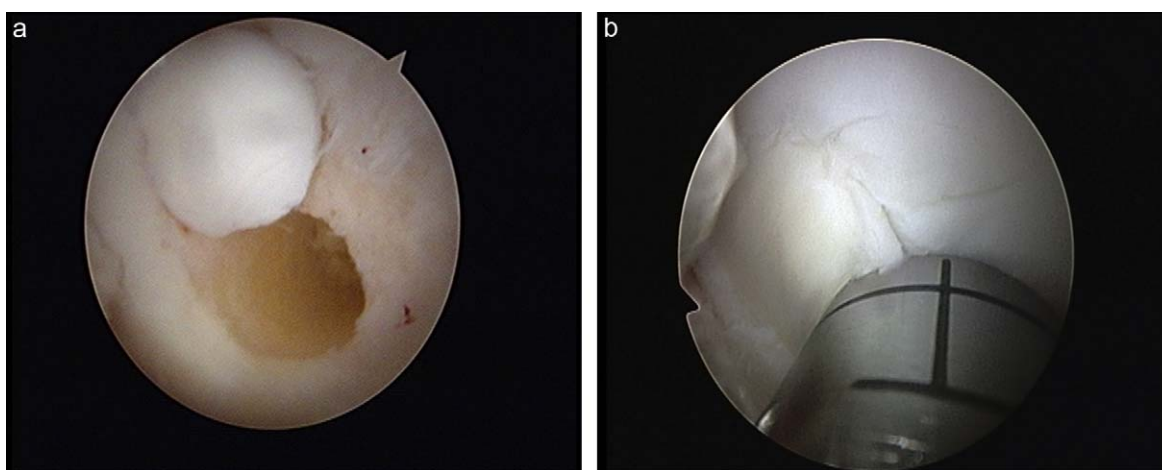


Figure 11 a et b: a second socket is drilled slightly touching the first graft to follow the convexity of the femoral condyle and obtain optimal filling. Insertion of the second graft.

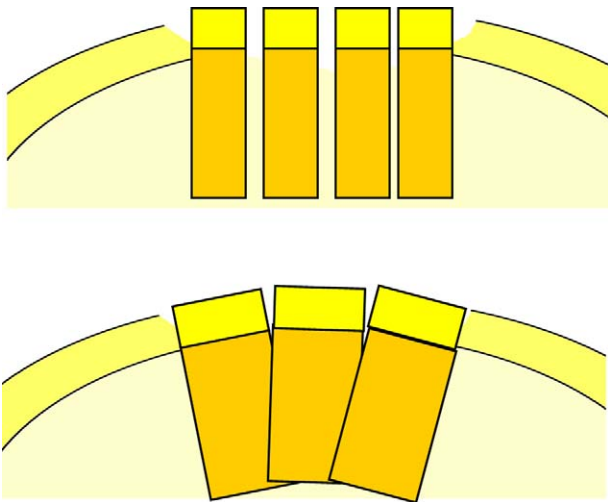


Figure 12 Parallel graft insertion restores a flat surface, radial insertion can restore convexity.

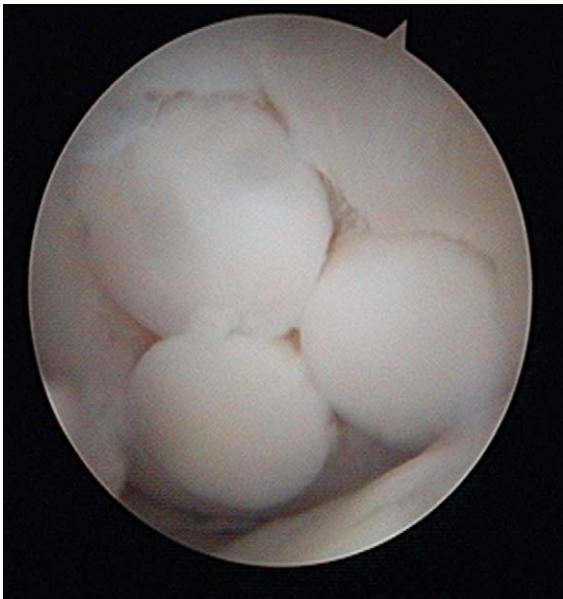

Figure 13 Arthroscopic view of three grafts.

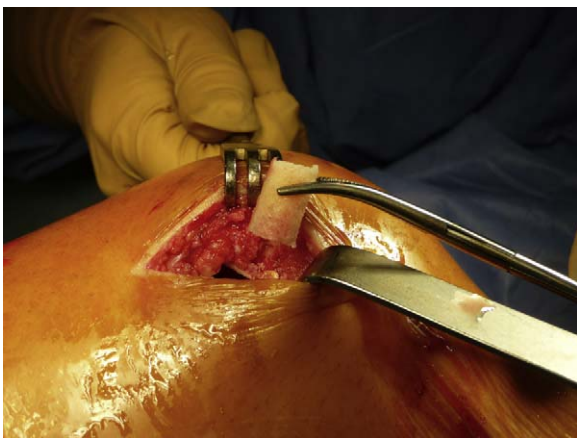

Figure 14 Filling of donor sockets with receiver plugs.

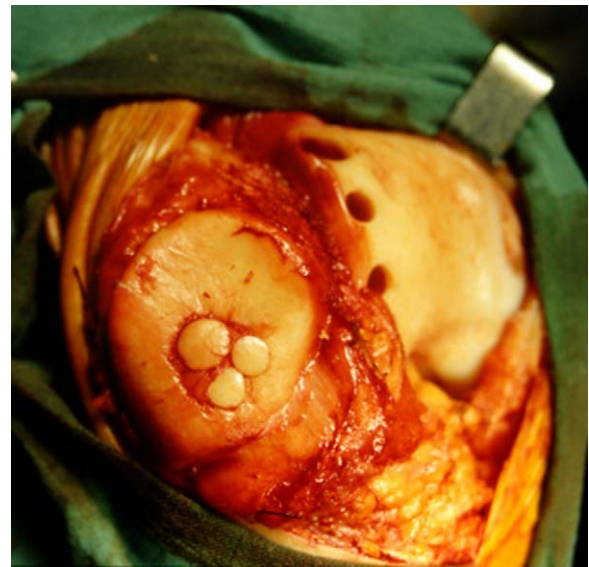

Figure 15 Patellar graft with three grafts after complete eversion.

and impaction of the graft is performed with the same guide. The diameter of the chisels is 2.7–8.5 mm.

Mosaicplasty of the patella

Arthrotomy is essential to obtain patellar eversion. The grafts are harvested on the rim of the intracondylar notch, which is flatter than on the trochlea and should be 12 mm deep. Drilling of receiver sockets should be slightly convergent to recreate the median ledge or parallel for a facet (Fig. 15).

Mosaicplasty of the tibia

The graft technique on a small surface of the tibial plateau is possible but difficult. To prepare the receiver socket an oblique view is necessary (20–30°) from a window in the tibial cortex, with the help of an ACL ligamentoplasty guide, which is positioned under arthroscopy. The graft is harvested from the medial or lateral trochlea with the same guide angle. The graft is inserted into the tibial socket taking care to maintain the desired oblique angle. When it reaches the peripheral cartilage, a bioresorbable interference screw blocks it in the socket. Specific instrumentation has been developed for this indication (Retrograde OATS® system, Arthrex).

Postoperative follow-up

Ice packs are applied to the knee for several weeks to avoid any hemarthrosis. The use of anticoagulants, the use of a tourniquet and when to apply weight depend upon the surgeon's preferences. If anticoagulants are used, an overdose includes the risk of hemarthrosis, which makes rehabilitation very difficult. Prophylactic antibiotics are recommended for 24 hours. Analgesics (morphine pump, crural

catheter) and non steroid anti-inflammatory drugs are essential to favor early movement without a splint.

Rehabilitation

Femoral condyle grafts

If there is a single stable graft, immediate weight-bearing is possible [13]. If there are several grafts, weight should not be applied for 2–3 weeks, then partial weight for 2–4 weeks [7,39]. Free and early movement of the knee is recommended for lubrication and chondral nutrition. It can be free or by arthromotor. Open kinetic chain exercises begin immediately, then after the third week closed kinetic chain exercises can begin. Running can begin 10 weeks after surgery, and pivot sports after 5 months.

Patellar grafts

Weight can be applied immediately but flexion should be limited to 20–30° for 3–4 weeks. Open kinetic chain exercises can begin after the third week.

Graft associated with a tibial osteotomy

The osteotomy determines the protocol; normally no weight is applied for 4 weeks then partial weight for 3–4 weeks. The rest of the protocol is followed.

Graft associated with an ACL ligamentoplasty

The osteochondral graft determines the protocol.

Graft follow-up

MRI is the best imaging technique for follow-up of grafts using specific sequences: T2-Fast Spin Echo (FSE) sequences with proton density images with and without fat saturation and T1 gradient echo sequences with fat saturation [35]. For the first few months, the deep part of the graft consolidates while the surface heals. The imaging signal of the trabecular donor graft is identical to that of trabecular receiver site, however the low intensity signal of the interface becomes less and less visible. On the surface, the hypointense signal of the cartilage remains thick and becomes continuous with the receiver cartilage. MRI identifies graft anomalies, poor integration, surface degeneration, bone edemas and synovial effusion. A persistent hyperintense signal at the interface or in the deep part of the graft suggests poor graft integration.

Specific cases

Multiple osteochondral grafts for osteochondritis dissecans

In 1999, Berlet et al. proposed implanting several plugs 4.5 mm in diameter to obtain integration of osteochondritis dissecans [40]. The principle is to provide a biological tutor for healing of the fragment (Fig. 16).

Graft and screw fixation for osteochondritis dissecans

In case of ICRS stage 3 OCD, fixation of the pedicled fragment alone is not always enough to obtain satisfactory union in an adult [41]. A combination of screw fixation and implantation of

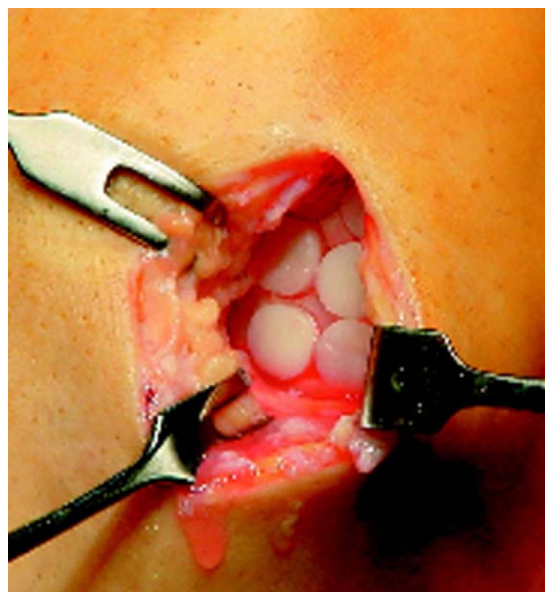


Figure 16 Multiple osteochondral grafts on a large osteochondritis dissecans according to the Berlet procedure.

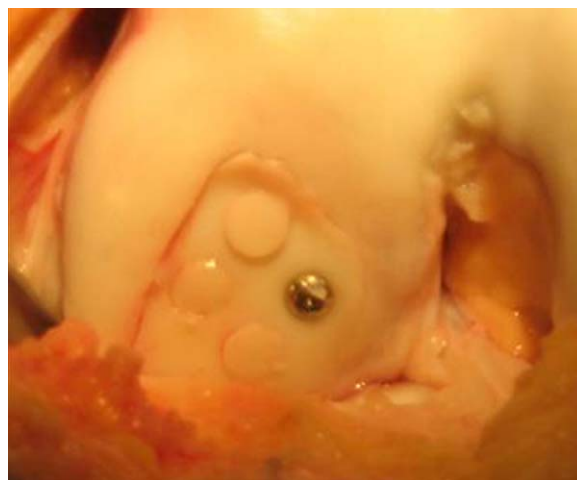

Figure 17 Screw fixation and a graft for osteochondritis dissecans by the “Fixation+” technique (courtesy of P. Beaufilets).

one or more small diameter plugs (4.5 mm), called “Fixation plus” improves the chances of healing (Fig. 17) [42].

Mega-OATS

In case of very large defects of the femoral condyle (more than 2 cm in diameter), the posterior femoral condyle can be harvested and a graft can be fashioned and inserted by press-fit. The harvested femoral condyle restores itself, but there is a risk of degeneration in this compartment. This is a salvage technique [43].

Complications

Fracture of the graft during harvesting

If it is less than 10 mm long the graft will be unstable once it is transplanted. It is better to obtain a graft that is at least 15 mm long.

Graft inserted too deeply

The graft will be ineffective. The socket for the second graft should be prepared and the too deeply inserted graft should be pulled up with a crochet hook then temporarily stabilized with a small pin during insertion of the second graft.

Postoperative hemarthrosis

Severe bleeding is rare but requires arthroscopic needle aspiration or lavage. Hemorrhage usually occurs in the harvest sites, especially if there are several and they are not filled with the trabecular bone from the receiver sockets.

Femoropatellar pain

The donor site can remain painful for several months, but rarely more than 3 months. Two cases of painful and fibrocartilage hypertrophy of the donor site have been described requiring arthroscopic debriding [44]. Filling with fibrocartilaginous tissue will be unsatisfactory if the grafts are more than 8 mm in diameter [45]. There may be a long-term risk of lateral femoropatellar osteoarthritis (2.3%) [7].

Necrosis of graft cartilage

Usually the patient is in pain, and MRI shows a lack of restored continuity of the chondral surface. Arthroscopy can be used to transfer a larger graft, after debriding.

Pseudarthrosis of the graft

The diagnosis is based on persistent pain in the graft area lasting more than 3 or 4 months. MRI shows a hypersignal around the graft. A new larger graft is necessary in the same recipient sockets.

Results

Laszlo Hangody et al. [7] recently published a series of 789 femoral condyle defects, 31 tibial defects and 147 femoropatellar defects including 81% with an associated procedure (meniscal, ligamental or bone). At a maximum of 15 years of follow-up, the following results were observed: 92% of good or very good results for the femoral condyle, 87% for the tibia and 74% for the femoropatella. Out of 83 biopsies, the authors found hyalin cartilage in 83% of the cases (type II collagen and glycoaminoglycans) and especially perfect integration of the cartilage matrices. Numerous authors have published their results on femoral condyle defects, with 84% of good and very good results at 4 years of follow-up for Chow et al., 88% at 2 years of follow-up for Jacob et al., and 87% at one year of follow-up for the *Société française d'arthroscopie* [30,45,46].

All of these authors emphasize the advantages of mosaicplasty: the simplicity of a one-stage surgical procedure, the transfer of living autologous cartilage, the low cost and morbidity, but frequency of associated surgical procedures was 45 [7] to 85% [30].

Solheim et al. reported deterioration of initially satisfying outcomes (Lysholm and pain scale) between one and seven years after surgery, without clearly explaining these results [47].

Two teams performed randomized studies comparing mosaicplasty and first and second generation chondrocyte grafts with at least one year of follow-up. For Horas

et al. [48], the clinical results were better and more rapid with mosaicplasty, and histological results were better with mosaicplasty despite a gap in the chondral edges of the plugs. For Bentley et al. [49], there was clinical improvement with both techniques but the lack of peripheral integration is a disadvantage of mosaicplasty. The histology of chondrocyte grafts is more frequently hyalin or fibrohyalin.

Contraindications

Mosaicplasty is not indicated in the following cases: pre-osteoarthritis dissecans or osteoarthritis dissecans, inflammatory arthropathies, a history of knee infections, tumors, patients over 50. The relative contraindications are: overweight patients, severe tobacco addiction, and poor treatment compliance [7].

Indications

Repair of symptomatic cartilage defects of the knee is a difficult decision because of the technical complexity and risks of this procedure. It should only be considered in patients whose functional incapacity, sports activity and the extent of the defect have been sufficiently evaluated to make a decision. We believe that the patient should self-evaluate pain, daily difficulties with mobility and functional difficulties (walking, using stairs, sitting, squatting, driving, running, pivoting, sports...), and the effect on daily personal, family and professional life. The Knee and Osteoarthritis Outcome Score (KOOS) or the International Cartilage Repair Society (ICRS) score can be used and compared for focal knee defects. This is the first step when making a therapeutic decision. Then MRI, arthro-MRI and CT arthrography imaging can be used to locate and measure the surface and depth of the defect. Only defects that remain painful after at least 3 months of observation should be treated, except for specific cases.

There are several available options for an isolated symptomatic defect of the femoral condyle whose size has been determined by imaging. Chondral repair techniques should only be proposed in cases of deep, limited local substance loss (grades III and IV), which are symptomatic (subjective ICRS score < 55/100) in young subjects (younger than 50). Associated injuries (meniscal, ligament) should be treated simultaneously or prior to chondral repair. Any misalignment of the knee above 5° requires simultaneous or prior osteotomy. Schematically [50], no repair is necessary for defects less than 1 cm²; if the surface is between 1–3 cm² after debridement, microfractures, osteochondral autografts or chondrocyte grafts are possible, with the choice being based on the quality of subchondral bone. Above 3 cm² (or 2 cm in diameter), an osteochondral graft or a chondrocyte graft are both possible. The chondrocyte graft should be proposed after other procedures have failed. Osteochondritis dissecans is often a deep lesion, which requires an osteochondral or chondrocyte graft. The indications vary and there is a risk with complex defects, such as severe associated osteoarticular and ligament injuries, or in knees that have undergone many operations ("Salvage procedure" de T. Minas) [51].

Conclusion

Mosaicplasty graft is an effective but difficult technique. Preparation of the recipient site should leave the edges of the defect clean. A few large sized grafts should be harvested on the medial or lateral trochlea across from the recipient femoral condyle, by mini-arthrotomy. Graft transfer by arthroscopy or arthrotomy should be flush, radial and not aggressive to chondral cells. Maximum coverage and stability (press-fit) should be obtained. Any misalignment (above 5°) or instability should be treated simultaneously or prior to chondral repair. This technique should be limited to substance loss whose surface is a maximum of 3 cm².

Disclosure of interest

The author declares that he has no conflicts of interest concerning this article.

References

- [1] Buckwalter JA, Mankin HJ. Articular cartilage degeneration and osteoarthritis, repair, regeneration and transplantation. *Instr Course Lect* 1998;47:487–504.
- [2] Hueter W. On the structure and disease of articular cartilage. *Philos Trans R Soc London* 1743;42:514–21.
- [3] Linden B. Osteochondritis dissecans of the femoral condyles: a long-term follow-up study. *J Bone Joint Surg* 1977;59-A:769–76.
- [4] Messner K, Maletius W. The long-term prognosis for severe damage to weight bearing cartilage in the knee: a 14-year clinical and radiographic follow-up in 28 young athletes. *Acta Orthop Scand* 1996;67:165–8.
- [5] Curl W, Krome J, Gordon ES, Rusching J, Smith BP, Poehling GG. Cartilage injuries: a review of 31,516 knee arthroscopies. *Arthroscopy* 1997;13:456–60.
- [6] Steadman JR, Rodkey WG, Singleton SB, Briggs KK. Microfracture technique for full thickness chondral defects: technique and clinical results. *Oper Tech Orthop* 1997;7:300–4.
- [7] Hangody L, Vasarhelyi G, Hangody LR, Sukosd Z, Tibay G, Bartha L, et al. Autologous osteochondral grafting, technique and long-term results. *Injury* 2008;39S1:532–9.
- [8] Brittberg M, Lindahl A, Nilsson A, Peterson L. Treatment of deep cartilage defects in the knee with autologous chondrocyte implantation. *N Engl J Med* 1994;331:889–95.
- [9] Outerbridge KK, Outerbridge AR, Outerbridge RE. The use of a lateral patellar autologous graft for the repair of a large osteochondral defect of the knee. *J Bone Joint Surg* 1995;77:65–72.
- [10] Müller W. Osteochondritis dissecans. In: *Progress in orthopaedic surgery*. Hastings DE, editor. Vol. 3. Springer-Verlag; 1978. p. 135–6.
- [11] Yamashita F, Sakakida K, Suzu F, Takai S. The transplantation of an autogeneic osteochondral fragment for osteochondritis dissecans of the knee. *Clin Orthop* 1985;201:43–50.
- [12] Matsusue Y, Yamamuro T, Hama H. Arthroscopic multiple osteochondral transplantation to the chondral defect in the knee associated with ACL disruption. *Arthroscopy* 1993;9(3):318–21.
- [13] Bobic V. Arthroscopic osteochondral autograft transplantation in ACL reconstruction: a preliminary clinical study. *Knee Surg Sports Traumatol Arthrosc* 1996;3:262–4.
- [14] Hangody L, Kish G, Karpati Z. Arthroscopic autogenous osteochondral mosaicplasty for the treatment of femoral condylar articular defect. *Knee Surg Sports Traumatol Arthrosc* 1997;5:262–7.
- [15] Hangody L, Kish G, Karpati Z. Autogenous osteochondral graft technique for replacing knee cartilage defects in dogs. *Orthop Int* 1997;19(5):175–81.
- [16] Guettler JH, Demetropoulos CK, Yang KH, Jurist KA. Osteochondral defect in human knee. Influence of defect size on cartilage rim and load distribution to surrounding cartilage. *Am J Sports Med* 2004;32:1451–8.
- [17] Convery FR, Akeson WH, Keown GH. The repair of large osteochondral defects. An experimental study in horses. *Clin Orthop* 1972;82:253–62.
- [18] Kock NB, Smolders JMH, Van Susante JLC, Buma P, Van Kampen A, Verdonschot N. A cadaveric analysis of contact stress restoration after osteochondral transplantation of a cylindrical cartilage defect. *Knee Surg Sports Traumatol Arthrosc* 2008;16:461–8.
- [19] Garretson RB, Katolic LI, Beck PR, Bach BR, Cole BJ. Contact pressure at osteochondral donor sites in the patellofemoral joint. *Am J Sports Med* 2004;32:967–74.
- [20] Ahmad CS, Cohen ZA, Levine WN, Ateshian GA, Mow VC. Biomechanical and topographic considerations for autologous osteochondral grafting in the knee. *Am J Sports Med* 2001;29(2):201–6.
- [21] Bartz RL, Kamaric E, Noble PC, Lintner D, Bocell J. Topographic matching of selected donor and recipient sites for osteochondral grafting of the articular surface of the femoral condyle. *Am J Sports Med* 2001;29:207–12.
- [22] Thauat M, Couchon S, Lunn J, Charrois O, Fallet L, Beaufilet P. Cartilage thickness matching of selected donor and recipient sites for osteochondral autografting of the medial condyle. *Knee Surg Sports Traumatol Arthrosc* 2007;15:381–6.
- [23] Keeling JJ, Gwinn DE, McGuigan FX. A comparison of open versus arthroscopic harvesting of osteochondral autografts. *Knee* 2009;16:458–62.
- [24] Duchow J, Hess T, Kohn D. Primary stability of press-fit implanted osteochondral grafts. *Am J Sports Med* 2000;28:24–7.
- [25] Kock NB, Van Susante J, Buma P, Van Kampen A, Verdonschot N. Press-fit stability of an osteochondral autograft: influence of different plug length and perfect depth alignment. *Acta Orthop* 2006;77:422–8.
- [26] Makino T, Fujioka H, Terukina M, Yoshiya S, Matsui N, Kurosaka M. The effect of graft sizing on osteochondral transplantation. *Arthroscopy* 2004;20:837–40.
- [27] Pearce SG, Hurtig MB, Clarnette R, Kalra M, Cowan B, Miniaci A. An investigation of 2 techniques for optimizing joint surface congruency using multiple osteochondral autografts. *Arthroscopy* 2001;17:50–5.
- [28] Huang FS, Simonean PT, Norman AG, Clark JM. Effects of small incongruities in a sheep model of osteochondral grafting. *Am J Sports Med* 2004;32:1842–8.
- [29] Patil S, Butcher W, D'Lima DD, Steklov N, Bugbee WD, Hoeneche HR. Effect of osteochondral graft insertion forces on chondrocyte viability. *Am J Sports Med* 2008;36:1726–32.
- [30] Jacob R, Franz T, Gautier E, Mainil Varlet P. Autologous osteochondral grafting in the knee: indications results and reflections. *Clin Orthop* 2002;401:170–84.
- [31] Lane JG, Tontz Jr WL, Ball ST, Massie JB, Chen AC, Bae WC, et al. A morphologic, biochemical, and biomechanical assessment of short-term effects of osteochondral autograft plug transfer in an animal model. *Arthroscopy* 2001;17(8):856–63.
- [32] Kock NB, Van Susante JLC, Wymenga AB, Buma P. Histological evaluation of a mosaicplasty of the femoral condyle, retrieval specimens obtained after TKA. *Acta Orthop Scand* 2004;75:505–8.
- [33] Ahmad C, Guiney WB, Drinkwater CJ. Evaluation of site intrinsic healing response in autologous osteochondral grafting of the knee. *Arthroscopy* 2002;18:95–8.

- [34] Van Suzante JLC, Wymega AT, Buma P. Potential healing benefit of an osteoperiosteal bone plug from the proximal tibia on a mosaicplasty donor-site defect in the knee. *Arch Orthop Trauma Surg* 2003;123:466–70.
- [35] Brittberg M, Winalski C. Evaluation of cartilage injuries and repair. *J Bone Joint Surg* 2003;85-A:58–69.
- [36] Blum A, Loeuille D, Lochum S, Kohlman R, Grignon B, Coudane H. L'arthro-IRM: principes et applications. *J Radiol* 2003;84:639–57.
- [37] Robert H. Évaluation arthroscopique des lésions chondrales du genou. *Maitrise Orthopedique* 2007;162:12–7.
- [38] Robert H, Lambotte JC, Flicoteaux R. Arthroscopic measurements of cartilage lesions of the knee condyle. Principles and experimental validation of a new method. *Cartilage* 2011 [In press].
- [39] Robert H. Les techniques de réparation chondrale et ostéochondrale du genou. Incidences sur la rééducation. *Ann Readaptation Med Phys* 2002;45:62–8.
- [40] Berlet GC, Mascia A, Miniaci A. Treatment of unstable osteochondritis dissecans lesions of the knee using autogenous osteochondral grafts (mosaicplasty). *Arthroscopy* 1999;15:312–6.
- [41] Lefort G, Moyen B, Beaufile P, De Billy B, Breda R, Cadilhac C, et al. Osteochondritis dissecans of the femoral condyles: report of 892 cases. *Rev Chir Orthop Reparatrice Appar Mot* 2006;92:2S97–141.
- [42] Lintz F, Pujol N, Pandeirada C, Boisrenoult P, Beaufile P. Hybrid fixation: evaluation of a novel technique in adult osteochondritis dissecans of the knee. *Knee Surg Sports Traumatol Arthrosc* 2011;19:568–71.
- [43] Braun S, Minzlaff P, Hollweck R, Wortler K, Imhoff AB. The 5,5 years results of mega OATS autologous transfer of the posterior femoral condyle: a case-series study. *Arthritis Res Ther* 2008;10(3):R68.
- [44] LaPrade RF, Botker JC. Donor-site morbidity after osteochondral transfer procedures. *Arthroscopy* 2004;7:E15.
- [45] Chow JCY, Hantes ME, Houle JB, Zalavras CG. Arthroscopic autogenous osteochondral transplantation for treating knee cartilage defect: a 2-to-5-year follow-up study. *Arthroscopy* 2004;7:681–90.
- [46] Robert H, Boyer T. Symposium « Réparation cartilagineuse ». Montpellier: Annales de la Société française d'arthroscopie, Sauramps Medical; 2000. p. 155–271.
- [47] Solheim E, Hegna J, Oyen J, Austgulen OK, Harlem T, Strand T. Osteochondral autografting in articular cartilage defects in the knee: results at 5 to 9 years. *Knee* 2010;17:84–7.
- [48] Horas U, Pelinkovic D, Herr G, Aigner T, Schnettler R. Autologous chondrocyte implantation and osteochondral cylinder transplantation in cartilage repair of the knee joint. *J Bone Joint Surg Am* 2003;85:185–92.
- [49] Bentley G, Briant LC, Carrington WJ, Akmal M, Goldberg A, Williams AM, et al. A prospective randomised comparison of autologous chondrocyte implantation versus mosaicplasty for osteochondral defects in the knee. *J Bone Joint Surg* 2003;85-B:223–30.
- [50] Haute Autorité de santé (HAS). Évaluation de la greffe chondrocytaire du genou. Rapport d'étape. 2005. <http://www.has.sante.fr/>.
- [51] Minas T. Autologous chondrocyte implantation for focal defects of the knee. *Clin Orthop* 2001;391S:349–61.