CORE
Metadata, citation and similar papers at core.ac.uk
Provided by Elsevier - Publisher Connector

No one is dead until warm and dead

Anand Iyer, MCh, Vincent Rajkumar, Bsc, CCP, Dinesh Sadasivan, MCh, Jaye Bruce, FRACP, and Ian Gilfillan, FRACS, Fremantle, Australia

Drs Iyer, Gilfillan, Rajkumar, Sadasavian, and Bruce (*left to right*)

Deep hypothermia causes circulatory and neurologic disturbances.[1] The mortality rates are high, even with institution of immediate treatment.[2] It has been shown that prolongation of submersion over 5 to 10 minutes worsens the prognosis considerably.[3] The discovery of a hypothermic patient with no signs of life poses the question of whether the patient got cold after death or is just cold but potentially salvageable. This becomes more difficult when the ambient temperature is not near freezing because the cooling process is much slower with greater risk of neurologic damage. We report one such case of a patient with hypothermia caused by drowning, with no signs of life, who was successfully resuscitated with femorofemoral bypass.

Clinical Summary

A 28-year-old man went diving to collect mussels underwater wearing a wet suit. He was missing for almost 30 minutes when rescuers spotted him. The paramedics found him to be cold, asystolic, and unresponsive to stimulus. They gave adrenaline and commenced cardiopulmonary resuscitation. On arrival at the emergency department, he had a core temperature of 24°C, was in ventricular fibrillation with no spontaneous respiratory effort, had fixed and dilated pupils, and was unresponsive to painful stimulus.

We found later that he had a history of intravenous drug abuse and was on medications for depression. DC shocks were given multiple times, and warming was commenced by giving warm fluids and performing warm lavage. With these steps, his temperature increased only by 2.5°C, and there were frequent periods of asystole. A decision was made to establish femorofemoral bypass for warming. Rewarming with bypass commenced almost 3 hours after drowning. A coated extracorporeal membrane oxygenator was used. Partial bypass with flow rates of between 2.5 and 3.5 L/min, an approximate index of 2.0 $L \cdot min^{-1} \cdot m^{-2}$, and a mean arterial pressure of 50 to 60 mm of Hg was maintained.

The first arterial blood gas measurement showed severe acidosis and hyperkalemia (Figure 1). These parameters gradually improved, and rewarming was continued at the rate of 8°C/h. At 31.7°C, cardiac electrical activity was detected. A couple of DC shocks resulted in recommencement of sinus rhythm. Attempts to wean from cardiopulmonary bypass after rewarming failed initially. There was a decrease in saturation, and arrhythmia's started occurring. As a result, extracorporeal support was continued. The following morning, he was weaned of extracorporeal membrane oxygenation with high doses of inotropes.

The complication that followed was right limb ischemia. A fasciotomy did not help, and after repeated debridements and conservative amputations, he finally required hindquarter amputation. A defunctioning ileostomy was done before amputation to prevent contamination of the wound. Other complications were renal failure requiring dialysis for 5 weeks and prolonged ventilation for 7 weeks. After 11 weeks, he was transferred to the rehabilitation unit with normal neurological function. He was subsequently discharged.

Discussion

Hypothermia is a well-recognized cause of cardiorespiratory arrest. With cardiopulmonary bypass, full recovery is possible, but mortality is high at 53% to 80%.[3] In the report by Hauty and colleagues,[2] no patients with absence of signs of life survived. Only 2 patients with hypothermia treated successfully with cardiopulmonary bypass have been reported from the United Kingdom, both of whom were initially responsive to stimuli but later went into cardiorespiratory arrest. The first recovered, and the second died of cerebrovascular accident.[4,5]

Our patient had no signs of life on discovery. This case challenged the team with the dilemma of whether to continue resuscitation or cease active management. Considering the patient's prolonged period of circulatory arrest and cardiopulmonary resuscitation, we were concerned with the low likelihood of recovery and intact neurological outcome. The final decision to commence bypass for rewarming was made on the basis of the adage that "no one is dead until warm and dead."

To our astonishment, the patient made a good recovery. One important step would have been to use femoral perfusion with a graft cannula in this case involving prolonged femoral bypass cannulation. This could have maintained the vascularity of his limb to some extent.

The temperature of water that day was 17°C, and he was wearing a wet suit, which maintains the temperature of the body for 60 minutes, even when the water temperature is 8°C. He was therefore in moderate hypothermia. Deep hypothermia increases the tolerance of the brain to ischemia by slowing the metabolic process. Despite the long period of moderate hypothermia, there were no residual neurological deficits.

This patient might be an exception, but in hypothermic patients with some evidence of cardiac electrical activity or even with no signs of life, rewarming with cardiopulmonary bypass is something worth considering.

From the Department of Cardiothoracic Surgery, Fremantle Hospital, Alma St, Fremantle WA, Australia.

Received for publication April 4, 2007; accepted for publication May 11, 2007.

Address for reprints: Anand Iyer, MCh, Department of Cardiothoracic Surgery, Fremantle Hospital, Alma St, Fremantle WA, Australia (E-mail: anandcvts@hotmail.com).

J Thorac Cardiovasc Surg 2007;134:1042-3

0022-5223/$32.00

Copyright © 2007 by The American Association for Thoracic Surgery

doi:10.1016/j.jtcvs.2007.05.028

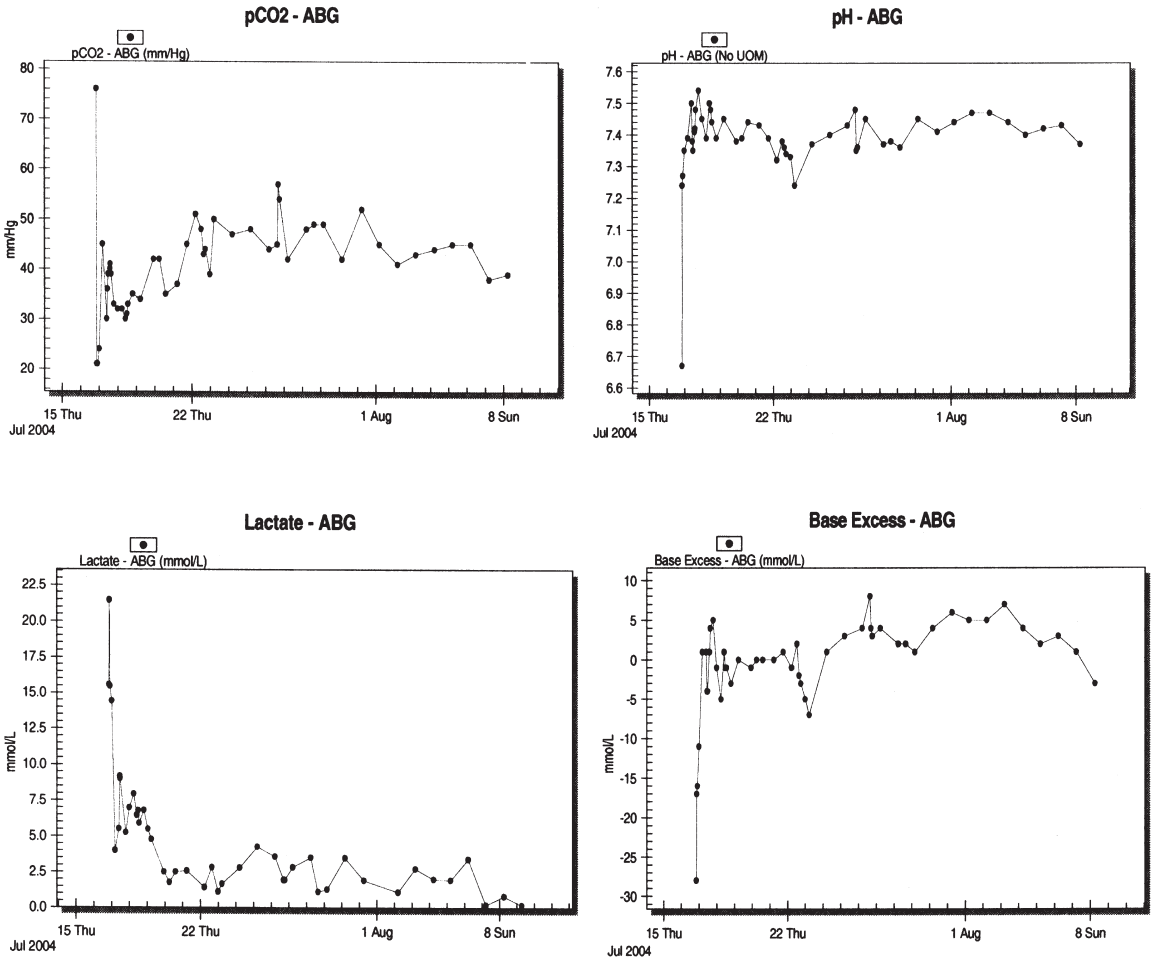

Figure 1. Graphs showing the levels of pCO2, pH, lactate, and base excess on arrival of the patient in the Emergency Room and their subsequent improvement after institution of bypass for rewarming.

References

1. Herity B, Daly L, Bourke GJ, Horgan JM. Hypothermia and mortality and morbidity: an epidemiological analysis. *J Epidemiol Community Health*. 1991;45:19-23.
2. Hauty MG, Esrig BC, Hill JG, Long WB. Prognostic factors in severe accidental hypothermia: experience from the Mt. Hood tragedy. *J Trauma*. 1987;27:1107-12.
3. Walpoth BH, Walpoth-Aslan BN, Mattle HP, Bogdan PR. Outcome of survivors of accidental deep hypothermia and circulatory arrest treated with extracorporeal blood warming. *N Engl J Med*. 1997;337:1500-5
4. Jones AI, Swann U. Prolonged resuscitation in accidental hypothermia: use of mechanical cardiopulmonary resuscitation and partial cardiopulmonary bypass. *Eur J Emerg Med*. 1994;1:34-6.
5. Steedman DJ, Rainer T, Campanella C. Cardiopulmonary resuscitation following profound immersion hypothermia. *J Accid Emerg Med*. 1997; 14:170-2.