

## General Thoracic Surgery

# Tracheal cartilage regeneration by slow release of basic fibroblast growth factor from a gelatin sponge

Hitoshi Igai, MD,<sup>a</sup> Yasumichi Yamamoto, MD,<sup>a</sup> Sung Soo Chang, MD,<sup>a</sup> Masaya Yamamoto, MD,<sup>b</sup> Yasuhiko Tabata, MD,<sup>b</sup> and Hiroyasu Yokomise, MD<sup>a</sup>

**Objective:** We investigated whether implantation of a gelatin sponge, releasing basic fibroblast growth factor slowly (b-FGF) into a tracheal cartilage defect, would induce regeneration of autologous tracheal cartilage.

**Methods:** We created a 1-cm defect in the midventral portion of each of 10 consecutive cervical tracheal cartilage rings in 12 experimental dogs. In the control group (n = 4), the resulting defects were left untreated. In the gelatin group (n = 4), empty gelatin sponges were implanted in the defects. In the basic fibroblast growth factor group (n = 4), gelatin sponges incorporating 100  $\mu$ g of b-FGF solution were implanted in the defects. We killed the 4 dogs in each group at 1, 3, 6, and 12 months after implantation, respectively, and examined the implant sites macro- and microscopically.

**Results:** In the control and gelatin groups, no regenerated cartilage was observed in the tracheal cartilage defects, and the width of the gap between the host cartilage stumps had shrunk. In the b-FGF group, regenerated cartilage was observed in all dogs. The proportion of the defect in the host cartilage occupied by regenerated cartilage was 13%, 84%, 75%, and 69% at 1, 3, 6, and 12 months, respectively. The regenerated cartilage was fibrous cartilage covered with perichondrium, which grew from the host perichondrium and showed continuity with the host cartilage stumps.

**Conclusions:** Implantation of a gelatin sponge slowly releasing basic fibroblast growth factor induces tracheal cartilage regeneration, which subsequently fills a large proportion of experimentally created tracheal cartilage defects within 12 months after implantation.

From the Second Department of Surgery,<sup>a</sup> Kagawa University, Kagawa, Japan; and Institute for Frontier Medical Sciences,<sup>b</sup> Kyoto University, Kyoto, Japan.

Received for publication Nov 23, 2006; accepted for publication Feb 12, 2007.

Address for reprints: Hitoshi Igai, Second Department of Surgery, Faculty of Medicine, Kagawa University, 1750-1 Ikenobe, Miki-cho, Kita-gun, Kagawa 761-0793, Japan (E-mail: [igai@med.kagawa-u.ac.jp](mailto:igai@med.kagawa-u.ac.jp)).

J Thorac Cardiovasc Surg 2007;134:170-5  
0022-5223/\$32.00

Copyright © 2007 by The American Association for Thoracic Surgery

doi:10.1016/j.jtcvs.2007.02.022

The surgical management of tracheal reconstruction is one of the most difficult problems associated with extensive tracheal resection in patients with malignant or benign disease. Several approaches have been attempted, including tracheal transplantation<sup>1-3</sup> and use of prosthetic materials,<sup>4,5</sup> but success has been limited because of graft ischemia and immune rejection, leading to anastomotic dehiscence and stenosis.

We have been investigating the use of artificial organs made of bioabsorbable materials to induce regeneration of defective or missing host tissues.<sup>6-8</sup> In a previous study, we focused on inducing regeneration of the trachea to produce an artificial prosthesis.<sup>9</sup>

### Abbreviations and Acronyms

AB	= alcian blue
b-FGF	= basic fibroblast growth factor
BMP	= bone morphogenetic protein
HE	= hematoxylin and eosin


The normal canine trachea, as is the case in humans, is composed of a mucosal layer, a submucosal layer, tracheal glands, a smooth muscle layer, and tracheal cartilage rings. The chief function of tracheal cartilage is to maintain the integrity of the tracheal lumen. Therefore, we have investigated the possibility of tracheal cartilage regeneration using biodegradable materials as a first step in attempting to produce an artificial trachea.

Bone morphogenetic protein (BMP)-2 or basic fibroblast growth factor (b-FGF) promotes the regeneration of chondrocytes in articular cartilage defects in vivo.<sup>10-15</sup> However, to our knowledge, few reports have indicated that these growth factors induce cartilage regeneration in tracheal cartilage defects. We have reported previously that implantation of gelatin sponge releasing BMP-2 or b-FGF slowly induces regeneration of tracheal cartilage.<sup>16-18</sup> However, implantation of a gelatin sponge incorporating BMP-2 did not achieve a sufficient result because regenerated cartilage was observed only at the ends of the host cartilage stumps.<sup>17</sup> On the other hand, implantation of a gelatin sponge incorporating b-FGF resulted in regeneration of cartilage that occupied 84% of cartilage defects created experimentally, although the results were based on short-term observations made over 3 months.<sup>18</sup> In the present study, we investigated the long-term results in dogs receiving b-FGF implantation for repair of tracheal defects and whether the regenerated cartilage would be absorbed as a result of foreign body reaction.

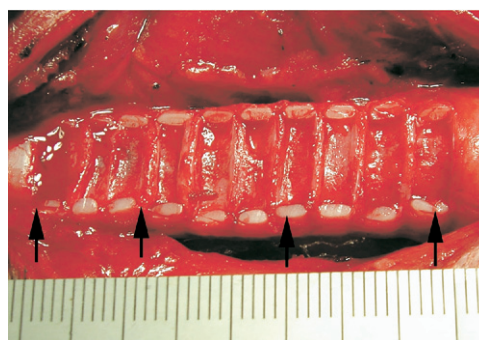## Materials and Methods

### Preparation of Gelatin Sponge Incorporating b-FGF

Gelatin as a 5 wt% aqueous solution with an isoelectric point of 5.0 (Nitta Gelatin Co, Osaka, Japan) containing 0.05 wt% glutaralde-



**Figure 1.** Macroscopic appearance of the gelatin sponge. The material was hard when in a dry state but was converted to a gel form when soaked with b-FGF solution.

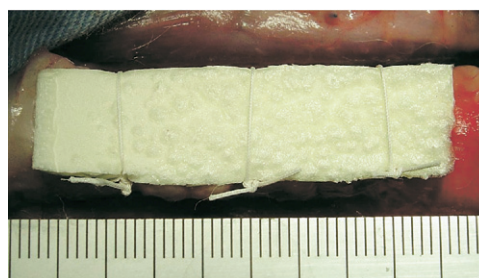


**Figure 2.** Operative appearance of a 1-cm gap made in the mid-ventral portion of each of 10 consecutive cervical tracheal cartilages from rings 4 to 13, extending for a total length of about 5 cm. The tracheal mucosa was carefully preserved. (Arrows show the tracheal cartilage defect.)

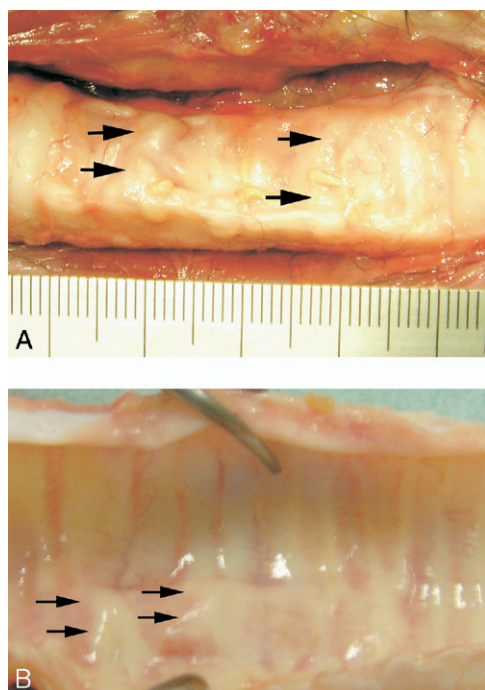
hyde (Wako Pure Chemical Industries, Osaka, Japan) was cast into a Teflon mold, then stored at 4°C for 12 hours to allow complete chemical cross-linking. The resulting material was immersed in an aqueous solution of glycine (Nakarai Tesque Inc, Kyoto, Japan) at 37°C for 1 hour to block any residual glutaraldehyde, rinsed in distilled water, freeze-dried, and finally sterilized by exposure to ethylene oxide gas. The prepared gelatin sponge was trimmed into pieces measuring approximately 10 × 50 × 2 mm<sup>3</sup> (Figure 1). Just before implantation, 100 μg of aqueous b-FGF solution was dissolved in 0.3 mL of saline solution, and the resulting solution was applied dropwise to the empty gelatin sponge. The sponge was then left to stand for 15 minutes to allow the b-FGF solution to soak in completely. B-FGF ionically immobilized on the gelatin sponge is released slowly for about 2 weeks as it degrades.<sup>19</sup>

### Operative Procedures

Twelve hybrid beagle dogs aged 2 to 3 years and weighing between 10 and 13 kg were anesthetized by intramuscular administration of 10 mg/kg ketamine (Sankyo Co, Tokyo, Japan) and 5 mg/kg xylazine (Bayer Japan, Tokyo, Japan), with 2 μg/kg atropine sulfate (Tanabe Seiyaku Co, Osaka, Japan) added to control secretions. All dogs were intubated via the trachea and ventilated

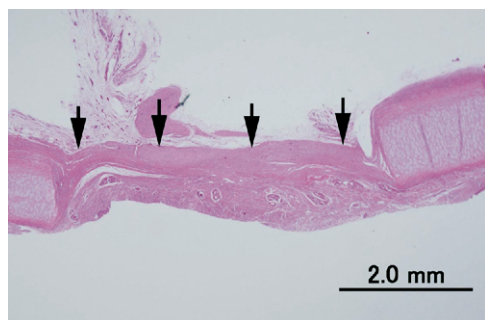


**Figure 3.** Operative appearance of the gelatin sponge, containing 100 μg of b-FGF solution, implanted in the tracheal cartilage defect. The gelatin sponge was fixed by 1-0 silk sutures to prevent dislodgment.



**Figure 4. Macroscopic appearance of the implant sites in the trachea in the b-FGF group. When the implant site was observed from both outside (A) and inside (B), regenerated cartilage (arrows) connected the stumps of each cartilage ring and filled the defect between them.**

mechanically with a mixture of nitrous oxide, halothane, and oxygen. We created a 1-cm gap in the midventral portion of 10 consecutive cervical tracheal cartilage rings (4th to 13th), taking care to preserve the tracheal mucosal layer (Figure 2). The gelatin sponge was fitted exactly into each gap. In the 4 dogs defined as the control group, the gaps were left unfilled. In the 4 dogs defined



**Figure 5. Microscopic appearance of the implant site in the control group. No regenerated cartilage was observed in the cartilage defect. The mucosal layer in the defect was thicker than that in the normal portion, and the submucosal layer was occupied by dense collagen bundles (arrows) and fibroblasts (HE stain  $\times 12.5$ ).**

as the gelatin group, empty gelatin sponges were implanted in the gaps. In the 4 remaining dogs defined as the b-FGF group, gelatin sponges incorporating 100  $\mu\text{g}$  b-FGF were implanted in the gap. The implanted gelatin sponges were fixed with 1-0 silk sutures to prevent dislodgment (Figure 3).

**Follow-up Studies**

We killed the 4 dogs in each group by bolus injection of a fatal dose of pentobarbital at 1, 3, 6, and 12 months after implantation, respectively. The cervical trachea including the implant sites was resected for macro- and microscopic examination. Initially, we observed the resected trachea grossly, then made cross sections through the middle portions of the implant sites to observe the internal lumen of the trachea. Then we prepared thinly sliced sections and stained them with hematoxylin and eosin (HE) or alcian blue (AB) for light microscopic examination. The shortest straight line distance between host cartilage stumps (defined as “H-distance”) or regenerated cartilage stumps (defined as “R-distance”) and the thickest straight line distance of the mucosal layer in host cartilage defect were measured. The ratio of the defect of the host cartilage occupied by regenerated cartilage was defined as:  $(1 - \text{R-distance}/\text{H-distance}) \times 100 (\%)$ .

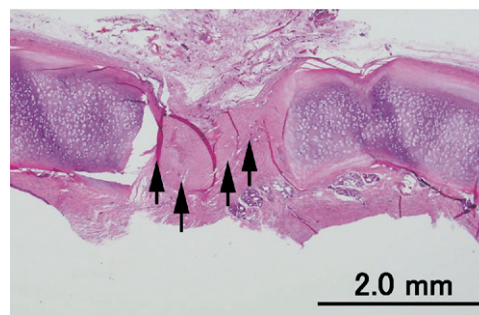
This experiment was performed in accordance with the “Guide for the Care and Use of Laboratory Animals” prepared by the Institute of Laboratory Animal Resources, National Research Council (published by the National Academy Press, revised 1996) and “Guide for the Care and Use of Experimental Animals” prepared by Kagawa University (1999).

**Results**

All 12 dogs survived without complications until they were killed as planned.

**Macroscopic Findings**

In the control and gelatin groups, each tracheal cartilage defect was filled with soft granulation tissue. Tracheal cartilage regeneration was not evident in the cartilage defect.



**Figure 6. Microscopic appearance of the implant site in the gelatin sponge group. No regenerated cartilage was observed in the cartilage defect. The mucosal layer in the defect was thicker than that in the normal portion, and the submucosal layer was occupied by dense collagen bundles (arrows) and fibroblasts. The distance between the host cartilage stumps had decreased markedly (HE stain  $\times 12.5$ ).**

**TABLE 1. Microscopic characteristics of the experimental dogs**

Group and dog (n)	Survival period (mo)	Ratio of the H.C. defect occupied by R.C. (%)	Gap length between H.C. stumps (mm)	Gap length between R.C. stumps (mm)
Control				
1	1	None	5.0	None
2	3	None	3.0	None
3	6	None	6.0	None
4	12	None	10	None
Gelatin				
1	1	None	0.7	None
2	3	None	2.5	None
3	6	None	3.7	None
4	12	None	3.7	None
b-FGF				
1	1	13	7.0	6.1
2	3	84	9.0	1.4
3	6	75	6.8	1.7
4	12	69	8.4	2.6

R.C., Regenerated cartilage; H.C., host cartilage.

Similarly, at 1 month in the b-FGF group, tracheal cartilage regeneration was also not evident in the defect, although the defect was filled with elastic hard tissue that connected each of the stumps of the host cartilage ring. In contrast, at 3, 6, and 12 months in the b-FGF group, tracheal cartilage regeneration was evident (Figure 4, A and B). The cartilage defect was filled with regenerated cartilage, which connected each of the stumps of the host cartilage ring.

### Microscopic Findings

In the control group, tracheal cartilage regeneration was not observed in the host cartilage defect (Table 1) (Figure 5). H-distances were 5.0, 3.0, 6.0, and 10 mm at 1, 3, 6, and 12 months, respectively, and the mean value was 6.0 mm. H-distance had shrunk in comparison with the original 10-mm length. The submucosal layer was occupied by dense collagen bundles and fibroblasts in the defect. The thickness of the mucosal layer was 0.88, 0.65, 0.45, 0.29 mm at 1, 3, 6, and 12 months, respectively, and the mean value was 0.57 mm. The mucosal layer in the defect was thicker than that in the normal portion.

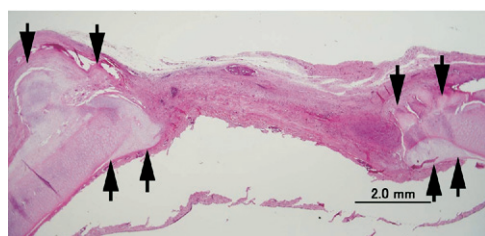
In the gelatin group, tracheal cartilage regeneration was also not observed in the host cartilage defect (Figure 6). H-distances were 0.7, 2.5, 3.7, and 3.7 mm at 1, 3, 6, and 12 months, respectively, and the mean value was 2.7 mm. Moreover, the submucosal layer was occupied by dense collagen bundles and fibroblasts in the defect. The thickness of the mucosal layer, which was thicker than that in the normal portion, was 1.6, 0.62, 1.0, and 0.90 mm at 1, 3, 6, and 12 months, respectively, and the mean value was 1.0 mm.

In the b-FGF group, cartilage regeneration was observed in all dogs. H-distances were 7.0, 9.0, 6.8, and 8.4 mm at 1, 3, 6, and 12 months, respectively, and the mean value was

7.8 mm. R-distances were 6.1, 1.4, 1.7, and 2.6 mm at 1, 3, 6, and 12 months, respectively. At 1 month, regenerated cartilage was observed only at the both ends of the host cartilage stumps (Figure 7). The ratio of the defect in the host cartilage occupied by regenerated cartilage was 13%. In contrast, at 3, 6, 12 months, the ratio was 84%, 75%, and 69%, respectively (Figure 8, A and B). The gap between the regenerated cartilage stumps, which represented the remaining cartilage defect, was occupied by granulation tissue. The regenerated cartilage was fibrous cartilage, which contained abundant collagen fibers in a hyaluronic acid-positive matrix, differentiating from native hyaline cartilage (Figure 9, A). The presence of hyaluronic acid in the matrix was proved by positive staining with alcian blue (Figure 9, B). Moreover, the regenerated cartilage was covered with perichondrium that had grown from the perichondrium of the host cartilage and showed continuity with the host cartilage stumps (Figure 10).

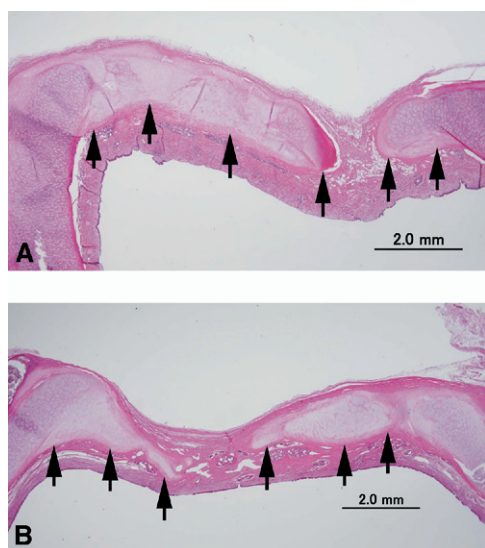
### Discussion

Mature cartilage tissue has limited capacity for regeneration, because of its avascular nature and relatively low cell density. In the present study, cartilage regeneration was not observed in control dogs with untreated tracheal defects or in dogs whose tracheal defects had been filled with plain gelatin. This result suggested that cartilage regeneration does not occur if the defect is left untreated and also that implantation of empty gelatin sponge does not induce cartilage regeneration. On the other hand, cartilage regeneration was observed in all dogs treated with slow-release b-FGF. Therefore, we concluded that implantation of a gelatin sponge slowly releasing b-FGF induced tracheal cartilage regeneration, which filled 69% to 84% of the

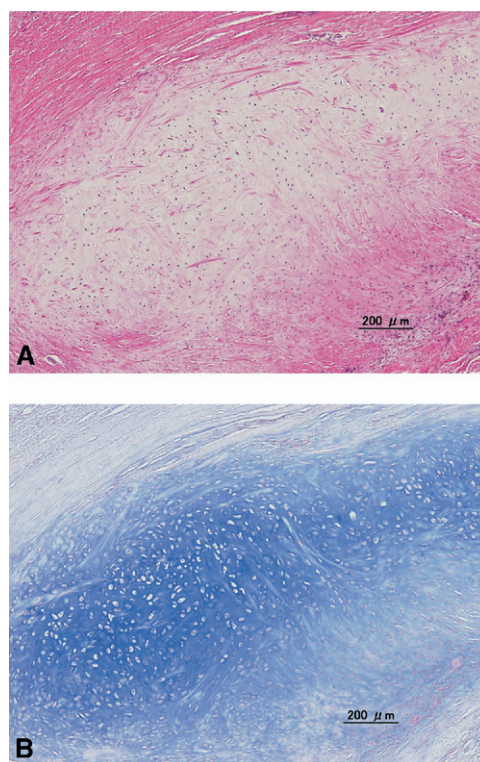


**Figure 7. Microscopic appearance of the implant site at 1 month in the b-FGF group. Regenerated cartilage (arrows) was observed only at the both ends of the host cartilage stumps with a concentric pattern (HE stain  $\times 12.5$ ).**

experimentally created tracheal cartilage defects, and had connected the stumps of the host cartilage with granulation tissue at 3, 6, and 12 months after implantation. It has been reported that various growth factors induce cartilage regeneration.<sup>20,21</sup> However, the mechanism by which cartilage regenerates in vivo, involving complex biologic interactions, has been unclear. In the present study, regenerated cartilage was covered with perichondrium that had grown from the perichondrium of the host cartilage, and showed continuity with the host cartilage stumps. Perichondrium is known to have chondrogenic potential<sup>22</sup> and to be a possible source of regenerated cartilage at sites of defects in adults.<sup>23</sup> A number of experimental studies have demonstrated cartilage regeneration by using perichondrial grafts.<sup>24,25</sup> Duynstee and colleagues<sup>22</sup> reported that perichondrium consisted of an inner cambium layer, which was the source of new

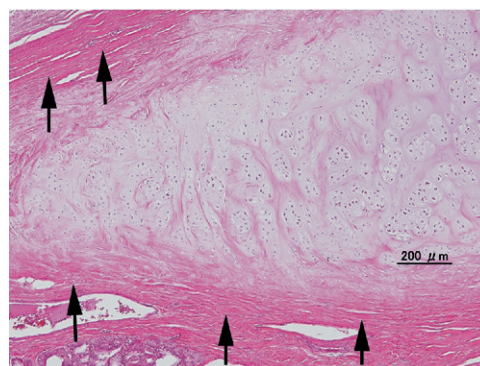


**Figure 8. Microscopic appearance of the implant site at 6 (A) and 12 (B) months in the b-FGF group. Regenerated cartilage (arrows) filled the defect completely and bridged the host cartilage stumps with granulation tissue (HE stain  $\times 12.5$ ).**



**Figure 9. Regenerated cartilage in the b-FGF group contained abundant collagen fibers in a hyaluronic acid-positive matrix (A). Hyaluronic acid in the matrix was positively stained with alcian blue (B) (A: HE stain  $\times 100$ , B: AB stain  $\times 100$ ).**

cartilage, and an outer fibrous layer, which was a fibrous supportive tissue, and that b-FGF was expressed during the process of cartilage regeneration in vitro. Therefore, we speculated that the regenerated cartilage observed in our study originated from perichondrium, as a result of stimulation by slow release of b-FGF from the gelatin sponge.



**Figure 10. Regenerated cartilage was covered with perichondrium (arrows), which had grown from the perichondrium of the host cartilage (HE stain  $\times 100$ ).**

We used a biodegradable gelatin sponge to allow b-FGF to be released slowly. Because of the short half-life of b-FGF in the body, it cannot be expected to efficiently induce tracheal cartilage regeneration if administered as a solution. The distances between the host cartilage stumps were markedly reduced in the plain gelatin group compared with the control group. This suggested that implantation of the gelatin sponge alone had induced a foreign body reaction and accelerated the process of gap shrinkage. Additionally, inflammation caused thickening of the mucosal layer in the gelatin group. In contrast, in the b-FGF group, H-distance was relatively well maintained compared with the gelatin group, despite the implantation of the gelatin sponge. We speculated that this maintenance of the H-distance in the b-FGF group was due to the fact that regenerated cartilage, rather than collagen bundles, had occupied the defect, unlike the situation in the control and gelatin groups. Regenerated cartilage prevented shrinkage of the distance between the stumps.

The regenerated cartilage was fibrous cartilage consisting of chondrocytes and a small amount of their territorial matrix in combination with dense collagen fibers. Because native tracheal cartilage is hyaline cartilage, regeneration of hyaline cartilage is more ideal. However, regeneration of fibrous cartilage is sufficient for maintaining the integrity of the tracheal lumen. In fact, in the present study, regenerated cartilage maintained the integrity of the tracheal lumen without resorption during the 12-month observation period, and the experimental dogs survived without problems such as tracheal collapse. We speculated that the regenerated cartilage was not absorbed because it was covered with perichondrium.

We have therefore demonstrated that slow release of b-FGF from a bioabsorbable gelatin sponge induces cartilage regeneration in the trachea. This regenerated cartilage repaired the host tracheal cartilage defect and maintained the integrity of the tracheal lumen.

## References

- Yokomise H, Inui k, Wada H, et al. High-dose irradiation prevents rejection of canine tracheal allografts. *J Thorac Cardiovasc Surg.* 1994;107:1391-7.
- Yokomise H, Inui K, Wada H, et al. Long-term cryopreservation can prevent rejection of canine tracheal allografts with preservation of graft viability. *J Thorac Cardiovasc Surg.* 1996;111:930-4.
- Yokomise H, Inui K, Wada H, et al. Split transplantation of the trachea: a new operative procedure for extended tracheal resection. *J Thorac Cardiovasc Surg.* 1996;112:314-8.
- Neville WE. Reconstruction of the trachea and stem bronchi with Neville prosthesis. *Int Surg.* 1982;67:229-34.
- Okumura N, Nakamura T, Takimoto Y, Kiyotani T, Lee YH, Shimizu Y, et al. The repair of tracheal defects using bioabsorbable mesh. *ASAIO J.* 1992;38:M555-9.
- Yamamoto Y, Nakamura T, Shimizu Y, et al. Intrathoracic esophageal replacement in the dog with the use of an artificial esophagus composed of a collagen sponge with a double-layered silicone tube. *J Thorac Cardiovasc Surg.* 1999;118:276-86.
- Yamamoto Y, Nakamura T, Shimizu Y, et al. Experimental replacement of the thoracic esophagus with a bioabsorbable collagen sponge scaffold supported by a silicone stent in dogs. *ASAIO J.* 1999;45:311-6.
- Yamamoto Y, Nakamura T, Shimizu Y, et al. Intrathoracic esophageal replacement with a collagen sponge-silicone double layer tube: evaluation of omental-pedicle wrapping and prolonged placement of an inner stent. *ASAIO J.* 2000;46:734-9.
- Yamamoto Y, Okamoto T, Goto M, Yokomise H, Yamamoto M, Tabata Y. Experimental study of bone morphogenetic proteins-2 slow release from an artificial trachea made of biodegradable materials: evaluation of stenting time. *ASAIO J.* 2003;51:533-6.
- Cuevas P, Burgos J, Baird A. Basic fibroblast growth factor (FGF) promotes cartilage repair in vivo. *Biochem Biophys Res Commun.* 1988;156:611-8.
- Yamamoto T, Wakitani S, Imoto K, et al. Fibroblast growth factor-2 promotes the repair of partial thickness defects of articular cartilage in immature rabbits but not in mature rabbits. *Osteoarthritis Cartilage.* 2004;12:636-41.
- Fujimoto E, Ochi M, Kato Y, Mochizuki Y, Sumen Y, Ikuta Y. Beneficial effect of basic fibroblast growth factor on the repair of full-thickness defects in rabbit articular cartilage. *Arch Orthop Trauma Surg.* 1999;119:139-45.
- Otsuka Y, Mizuta H, Takagi K, et al. Requirement of fibroblast growth factor signaling for regeneration of epiphyseal morphology in rabbit full thickness defects of articular cartilage. *Dev Growth Differ.* 1997;39:143-56.
- Suzuki T, Bessho K, Fujimura K, Okubo Y, Segami N, Izuka T. Regeneration of defects in articular cartilage in rabbit temporomandibular joints by bone morphogenetic protein-2. *Dev Growth Differ.* 1997;39:143-56.
- Sellers RS, Zhang R, Glasson SS. Repair of articular cartilage defects one year after treatment with recombinant human bone morphogenetic protein-2 (rhBMP-2). *J Bone Joint Surg Am.* 2000;82:151-60.
- Okamoto T, Yamamoto Y, Goto M, et al. Slow release of bone morphogenetic protein 2 from a gelatin sponge to promote regeneration of tracheal cartilage in a canine model. *J Thorac Cardiovasc Surg.* 2004;127:329-34.
- Okamoto T, Yamamoto Y, Goto M, et al. Cartilage regeneration using slow release of bone morphogenetic protein-2 from a gelatin sponge to treat experimental canine tracheomalacia: a preliminary report. *ASAIO J.* 2003;49:63-9.
- Igai H, Chang S, Gotoh M, Yamamoto Y, Misaki N, Okamoto T, et al. Regeneration of canine tracheal cartilage by slow release of basic fibroblast growth factor (b-FGF) from gelatin sponge. *ASAIO J.* 2006;52:86-91.
- Yamamoto M, Ikada Y, Tabata Y. Controlled release of growth factors based on biodegradation of gelatin hydrogel. *J Biomater Sci Polym Ed.* 2001;12:77-88.
- Schmidt MB, Chen EH, Lynch SE. A review of the effects of insulin-like growth factor and platelet derived growth factor on in vivo cartilage healing and repair. *Osteoarthritis Cartilage.* 2006;14:403-12.
- Song SU, Hong YJ, Oh IS, Yi Y, Choi KB, Lee JW, et al. Regeneration of hyaline articular cartilage with irradiated transforming growth factor beta1-producing fibroblasts. *Tissue Eng.* 2004;10:665-72.
- Duynstee MLG, Verwoerd-Verhoef HL, Verwoerd CDA, Osch G. The dual role of perichondrium in cartilage wound healing. *Plast Reconstr Surg.* 2002;15:1073-9.
- Ozbek S, Kahveci R, Karveci Z, Filiz G, Ozcan M, Sirmali S. Effect of lyophilized heterologous collagen on new cartilage formation from perichondrial flaps in rabbits: an experimental study. *Ann Plast Surg.* 2003;50:528-34.
- Ulutas K, Menderes A, Karaca C, Ozkal S. Repair of cartilage defects with periosteal grafts. *Br J Plast Surg.* 2005;58:65-72.
- Ozgenel GY, Filiz G, Ozcan M. Effect of human amniotic fluid on cartilage regeneration from free perichondrial grafts in rabbits. *Br J Plast Surg.* 2004;57:423-8.