

A Rare Cause of Sudden Ptosis: Posterior Communicating Artery Aneurysm

Merve Fatma BOZKURT,¹ Erdem DINC,¹ Emis EKEN,² Seyran BOZKURT,³ Cem SUNDU¹

¹Department of Ophthalmology, Mersin University, Mersin

²Clinic of Neurology, Silifke State Hospital, Mersin

³Department of Emergency, Mersin University, Mersin, all in Turkey

SUMMARY

A forty-seven-year-old female patient was admitted to our clinic with sudden ptosis and diplopia without pain. She had no trauma or systemic disease history. Ptosis and mydriasis were observed in her left eye. Eye movement was restricted all directions without lateral. Isolated oculomotor nerve paralysis was diagnosed based on clinical findings, and posterior communicating artery aneurysm was observed in magnetic resonance angiography.

Key words: Aneurysm; isolated oculomotor nerve paralysis; posterior communicating artery.

Introduction

Diabetes mellitus, hypertension, multiple sclerosis, trauma, and compressive lesions such as neoplasms and aneurysms can cause oculomotor nerve paralysis (ONP).^[1] Nerve paralysis may also be associated with various neurological syndromes. Clinical findings of ONP show differences according to the affected nerve segment. Also, systemic findings can be seen with nerve paralysis.^[2] Isolated ONP associated with aneurysm or compressive lesions is characterized by sudden onset, pain, and pupilla involvement.^[2] We report a case admitted the emergency clinic with sudden ptosis in her left eye that was diagnosed as isolated ONP related to a posterior communicating artery aneurysm.

Case Report

A forty-seven-year-old female patient was admitted to the clinic with sudden ptosis and diplopia without pain. Her complaints had begun three days prior. She had no trauma

or systemic disease history. Best-corrected visual acuity was 10/10 in her right eye and 7/10 in her left eye. Total ptosis and mydriasis were seen in her left eye (Figure 1). While direct and indirect light reflex was normal in her right eye, light reflex could not be observed in her left eye. Also, eye movement was restricted to all directions without lateral (Figure 1). Approximately 30 prism diopters exotropia was seen in the primary position. Anterior and posterior segment examination was normal in both eyes. Computer tomography (CT) and diffusion magnetic resonance imaging (MRI) was observed as normal. However, a posterior communicating artery aneurysm was seen in enhanced MRI and MRI angiography (Figure 2). Isolated ONP was diagnosed based on clinical and radiological findings and endovascular treatment was planned.

Discussion

The oculomotor nerve supplies the motor innervation of levator palpebrae superior, rectus superior, rectus inferior, oblique inferior musculi and parasympathic innervation of the

Submitted: May 22, 2014 **Accepted:** June 23, 2014 **Published online:** June 15, 2015

Correspondence: Merve Fatma BOZKURT, M.D. Faculty of Medicine, Department of Ophthalmology, Ciftlikkoy Campus, Mersin University, 33110 Mersin, Turkey.

e-mail: fmerveb@gmail.com



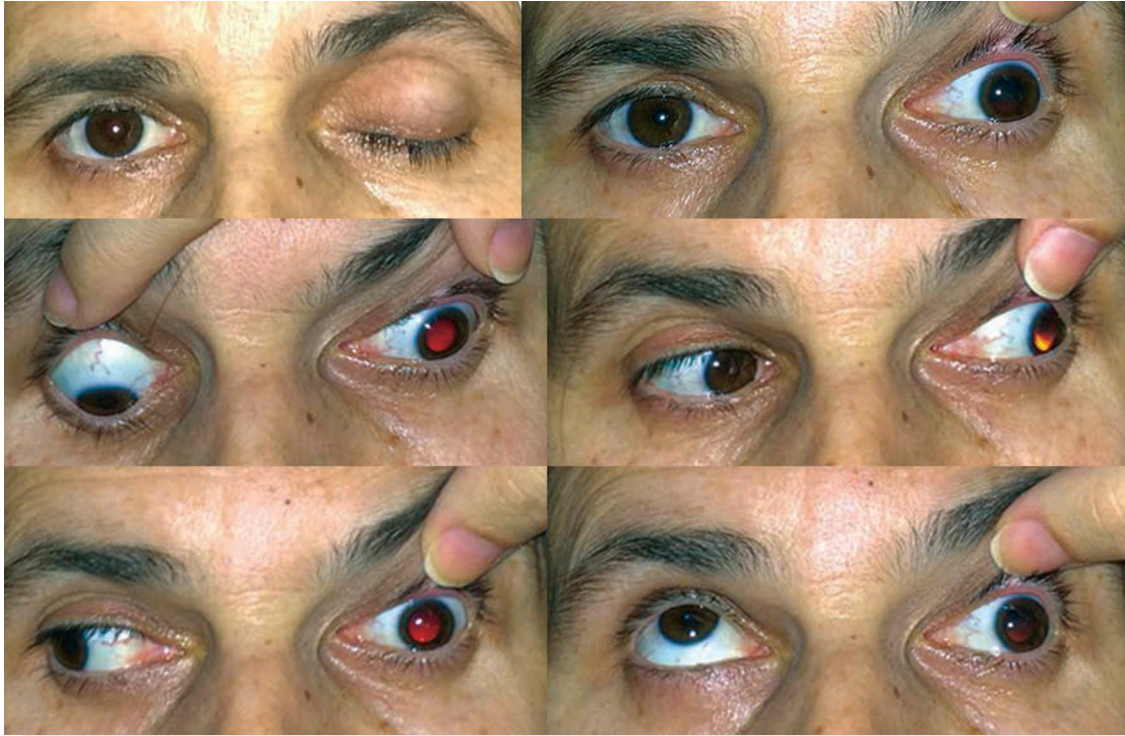


Figure 1. Total ptosis and mydriasis were seen in her left eye. Eye movement was restricted to all directions except lateral. Also, exotropia was observed at the primary position.

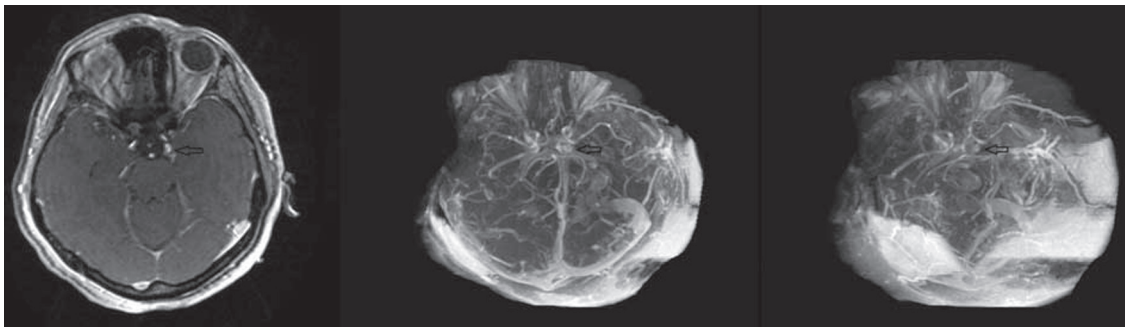


Figure 2. Posterior communicating artery aneurysm, which is the millimetric nodular gadolinium enhancement, was seen in enhanced MRI (T2 sequence) and MRI angiography (arrows).

iris and ciliary body.^[3] The basilar section of the nerve passes between the posterior cerebral and superior cerebellar arteries laterally parallel to posterior communicating artery. Intracranial aneurysms in this area are the primary cause of the insulating ONP that is determined in approximately 20-30% of the cases as underlying etiologic factor.^[4] The primary location of the aneurysms that cause the nerve paralysis is the posterior communicating artery; we presented a case reporting an aneurysm in a similar region. As is known, hypertension or trauma are important risk factors for aneurysm, but in our case study there was no systemic disease or trauma history.^[6]

Insulting ONP that is caused by aneurysm or mass effect is usually characterized by acute pain and pupillary involve-

ment.^[2] In our case study, nerve paralysis emerged acutely at the same time as pupillary involvement was detected. But as there was no pain history in our case, it does not suit the classical clinical picture, but similar cases have been reported.^[7] However pupillary involvement may not be detected in 8-15% of patients with aneurysm caused ONP but pupillary involvement may occur by following patients.^[8] The existence of pupillary involvement may give an idea about the underlying etiologic factor. If there is pupillary involvement, aneurysms or mass-like lesions that occupy an area should be considered, but if there is no pupillary involvement, vascular pathologies lead by diabetes mellitus should be thought of. This situation occurs because of the position of the fibers that lie in the nerve. While the infact caused by the

vascular pathologies such as diabetes mellitus affects the center of the nerve, mechanical causes affect the fibers that are close to the area.^[9] As the parasympathetic fibers of the nerve lie superficially, pupillary involvement is detected in these cases because of the impression. At the same time, other than the lateral rectus and superior oblique muscoli, extraocular motor innervation is damaged so that ptosis and scantiness of eye movements except the exterior view are detected.^[2] Also, as we presented in our case, study patients develop diplopia and the affected eye slides to the exterior.

Clinically insulting ONP-like cases should be examined for trauma and systemic vascular disease. In that case, differential diagnosis about the underlying etiologic factor can be done. Intracranial visualization should be performed. As occurred in the case we presented, normal intracranial visualization should not eliminate the clinical diagnosis of aneurysm, and angiography should be performed urgently. As treatment of cases with unruptured aneurysms endovascular techniques has recently become more popular, it is also planned in our case study.^[10]

Consequently similar clinical patients consulting to emergency service should be diagnosed differentially for intracranial aneurysms. Otherwise rupture of the aneurysm resulting in subarachnoid bleeding with subsequent high mortality and morbidity and the clinical situation of the patient may become worse.

Conflict of Interest

The authors declare that there is no potential conflicts of interest.

References

1. Kissel JT, Burde RM, Klingele TG, Zeiger HE. Pupil-sparing oculomotor palsies with internal carotid-posterior communicating artery aneurysms. *Ann Neurol* 1983;13:149–54. [CrossRef](#)
2. Kanski JJ. Third nerve. In: Kanski JJ, ed. *Clinical ophthalmology: a systematic approach*. 5th ed. New York: Butterworth Heinemann; 2006. p. 631–5.
3. Bruce BB, Biousse V, Newman NJ. Third nerve palsies. *Semin Neurol* 2007;27:257–68. [CrossRef](#)
4. Motoyama Y, Nonaka J, Hironaka Y, Park YS, Nakase H. Pupil-sparing oculomotor nerve palsy caused by upward compression of a large posterior communicating artery aneurysm. Case report. *Neurol Med Chir (Tokyo)* 2012;52:202–5. [CrossRef](#)
5. Chang SI, Tsai MD, Wei CP. Posterior communicating aneurysm with oculomotor nerve palsy: clinical outcome after aneurysm clipping. *Turk Neurosurg* 2014;24:170–3.
6. Evliyaoğlu Ç. Pathophysiology and genetics of intracranial aneurysms. *Turkish Neurosurgery* 2012;22:189–96.
7. Alim S, Demir AK, Hamzaoğlu V. Isolated oculomotor nerve palsy due to compression by a large intracranial aneurysm after blunt head trauma. *Journal of Contemporary Medicine* 2013;3:203–6.
8. Atilla H. Paralitik şaşılık ve supranükleer göz hareketleri. In: O'Dwyer PA, Akova YA, editör. *Temel göz hastalıkları*. 2. basım. Ankara: Güneş Tıp Kitabevleri; 2011. s. 817–826.
9. Fukushima Y, Imai H, Yoshino M. Ptosis as partial oculomotor nerve palsy due to compression by infundibular dilatation of posterior communicating artery, visualized with three-dimensional computer graphics: case report. *Neurol Med Chir* 2014;54:214–8. [CrossRef](#)
10. Yavuz K, Geyik S, Saatci I, et al. Endovascular treatment of cerebral aneurysms. *Türkiye Klinikleri J Radiol-Special Topics* 2012;5:84–90.