



ORIGINAL ARTICLE

# Anterior alveolar dimensions among different classifications of sagittal jaw relationship in Saudi subjects

Adel AlHadlaq

College of Dentistry, King Saud University, Department of Pediatric Dentistry and Orthodontics, P.O. Box 60169, Riyadh 11545, Saudi Arabia

Received 26 September 2009; revised 12 October 2009; accepted 23 December 2009  
Available online 6 February 2010

## KEYWORDS

Anterior alveolus;  
Class I occlusion;  
Class II malocclusion;  
Class III malocclusion;  
Saudi sample

**Abstract** Sound orthodontic movement of anterior teeth is delineated by the biological dimensions of the anterior alveolus.

*Objective:* To establish and compare the anterior alveolar dimensions among normal and abnormal sagittal maxillomandibular relationships in a Saudi sample.

*Materials and methods:* The lateral cephalometric radiographs of 81 Saudi subjects (42 males and 39 females) were used to determine the anteroposterior and vertical dimensions of the anterior alveolus in Class I ( $N = 30$ ), Class II ( $N = 24$ ), and Class III ( $N = 27$ ) cases. The anterior alveolar dimensions were then compared among males and females belonging to the same sagittal classification and between the different sagittal classifications of the same gender.

*Results:* Significant differences ( $P < 0.05$ ) in the anterior alveolar dimensions between males and females were demonstrated for the same sagittal jaw classification. Also, significant differences ( $P < 0.05$ ) were detected between the anterior alveolar dimensions among the different sagittal maxillomandibular classifications of the same gender.

*Conclusion:* Both the gender and the sagittal maxillomandibular relationship can affect the anteroposterior and vertical dimensions of the anterior alveolus.

© 2010 King Saud University. All rights reserved.

## 1. Introduction

Increased facial convexity is a major indication for extraction therapy to allow for retraction of anterior teeth during orthodontic treatment. Optimal stability and esthetics are normally achieved when the upper and lower incisors are positioned upright relative to their apical bony bases (Bills et al., 2005). Camouflage treatment of Class II and Class III malocclusion is often feasible with anteroposterior repositioning of upper and/or lower incisors to restore normal sagittal relationship (Costa Pinho et al., 2004; Demir et al., 2005). Positioning of the incisors in the middle of the alveolar process between the

E-mail address: aalhadlaq@hotmail.com

1013-9052 © 2010 King Saud University. All rights reserved. Peer-review under responsibility of King Saud University.  
doi:10.1016/j.sdentj.2010.02.004



Production and hosting by Elsevier

labial and lingual/palatal cortical plates improves the support around the roots and leads to enhanced periodontal conditions (Handelman, 1996; Horiuchi et al., 1998).

The width of the alveolar base is usually accomplished upon complete eruption of the permanent teeth (Sergl et al., 1996). Normal biological architecture with ideal bony support is established when the roots are situated in the medullary portion of the alveolar bone with adequate alveolar bone thickness surrounding the roots (Mirabella and Artun, 1995). Therefore, sound orthodontic tooth movement usually takes place within the alveolar bone without biological encounter between the roots and the cortical plates to avoid any possible iatrogenic risks, such as bone loss or root resorption (Lupi et al., 1996). Excessive lingual retraction or labial protraction of incisors is a common reason for inadvertent periodontal consequences due to resorption of the cortical bone and root exposure (Sarıkaya et al., 2002; Demir et al., 2005). In general, approximating the lingual or facial cortical plates increases the risk for producing undesirable effects (Horiuchi et al., 1998).

Remodeling capability of the alveolar bone has been demonstrated to be tapering from the height of the alveolar process in the direction of the root apex (Vardimon et al., 1998). This biological limitation to orthodontic tooth movement, especially at the level of root apex, has focused the attention of orthodontic literature on the relationship between different orthodontic tooth movements of upper and lower incisors in the labiolingual direction and the thickness of the anterior alveolus (Wainwright, 1973; Mulie and Hoeve, 1976; Handelman, 1996; Vardimon et al., 1998). Also, the correlation between anterior alveolar dimensions and different skeletal jaw relationships has been studied (Edwards, 1976; Wonglamsam et al., 2003; Bills et al., 2005). The height and width of the anterior alveolus in normal Class I Saudi individuals has been already established (Al-Barakati and Alhadlaq, 2007). In order to achieve a sound anteroposterior orthodontic tooth movement of upper and lower incisors in patients with abnormal sagittal jaw relationship, knowledge of the sagittal width of the upper and lower anterior alveolus is essential. The purpose of the present study was to establish and compare the anterior alveolar dimensions as measured relative to the root apex of the maxillary and mandibular central incisors among different sagittal maxillomandibular classifications in Saudi male and female subjects.

## 2. Materials and methods

The lateral cephalometric radiographs of 81 Saudi subjects (42 males and 39 females) obtained from the orthodontic records at the orthodontic clinic, King Saud University, were utilized in this study. All individuals of the sample were healthy with no congenital or acquired medical disorders, no previous orthodontic treatment or growth modification therapy, and

no history of trauma to the head/neck region. All subjects were adults with an age range between 16–24 years of age for the males and 17–29 years for the females. The male and female groups were subdivided into a total of six study groups based on the sagittal classification of the maxillomandibular relationship as reflected by the ANB angle. The ANB angle value ranged from 0° to 4° for the Class I subjects, from 5° to 13° for the Class II subjects and from -1° to -10° for the Class III subjects. The average age and ANB angle of the sample among different study groups are presented in Table 1.

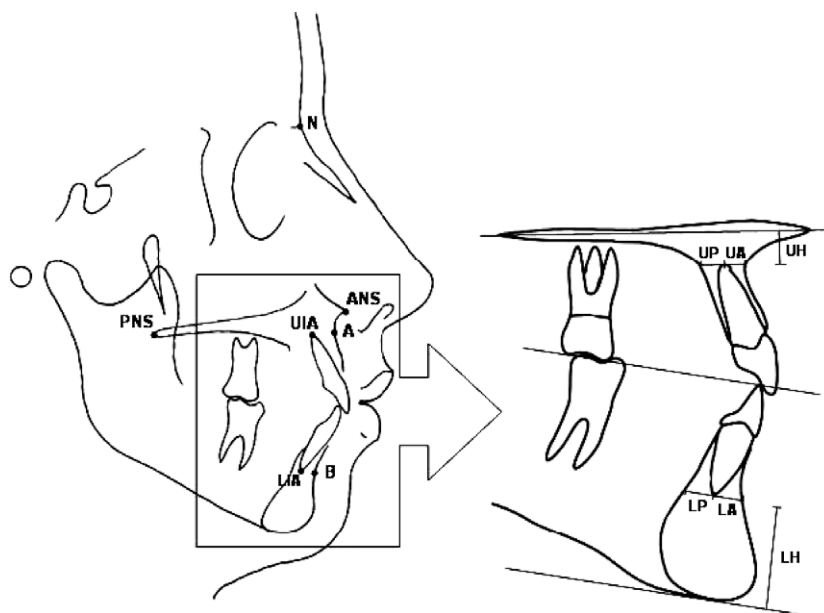
All lateral cephalometric radiographs were traced over an illuminated viewing box in a darkened room using a sharp 3H pencil on an acetate tracing paper. The landmarks identified on each cephalometric tracing were: nasion (N), anterior nasal spine (ANS), posterior nasal spine (PNS), point A (A), point B (B), upper incisal apex (UIA), and lower incisal apex (LIA) (Fig. 1). The method described by Handelman (1996) of measuring the dimensions of the maxillary and mandibular anterior alveolus was followed (Fig. 1). The following variables were measured on each cephalometric tracing for comparison in this study:

- Upper posterior alveolus width (UP): the distance from the apex of the maxillary central incisor to the limit of the palatal cortex along a line drawn through the apex parallel to the palatal plane (ANS–PNS).
- Upper anterior alveolus width (UA): the distance from the apex of the maxillary central incisor to the limit of the labial cortex along a line drawn through the apex parallel to the palatal plane.
- Upper anterior alveolus height (UH): the shortest distance between the maxillary central incisor apex and the palatal plane.
- Lower posterior alveolus width (LP): the distance from the apex of the mandibular central incisor to the limit of the lingual cortex along a line drawn through the apex parallel to the occlusal plane.
- Lower anterior alveolus width (LA): the distance from the apex of the mandibular central incisor to the limit of the labial cortex along a line drawn through the apex parallel to the occlusal plane.
- Lower anterior alveolus height (LH): the shortest distance from the apex of mandibular central incisor apex to the lowest point on the mandibular symphysis that is transected by a line parallel to the occlusal plane.

The measurements were performed manually with a standard ruler and protractor to the nearest 0.5 mm or 0.5° value. All linear measurements were corrected for magnification and presented as true values after subtraction of the correction factor from each measured value. Magnification correction factor was established by measuring a known value (10 mm) on a

**Table 1** Average age and ANB angle value among subjects of various study groups.

	Average ± SD					
	Female group (N = 39)			Male group (N = 42)		
	Class I (n = 15)	Class II (n = 11)	Class III (n = 13)	Class I (n = 15)	Class II (n = 13)	Class III (n = 14)
Age (years)	21.6 ± 1.64	22.55 ± 3.56	22.15 ± 3.26	20.87 ± 2.83	19 ± 2.58	20.43 ± 2.17
ANB (°)	2.53 ± 1.14	8.95 ± 2.52	-5.19 ± 2.73	2.63 ± 0.88	9.73 ± 1.99	-6.25 ± 2.75



**Figure 1** Identified cephalometric landmarks and measurements of the maxillary and mandibular anterior alveolus. N: nasion; ANS: anterior nasal spine; PNS: posterior nasal spine; A: point A; B: point B; UIA: upper incisal apex; LIA: lower incisal apex; UH: height of the upper alveolus; UA: width of the upper anterior alveolus; UP: width of the upper posterior alveolus; LH: height of the lower alveolus; LA: width of the lower anterior alveolus; LP: width of the lower posterior alveolus.

ruler fixed near the subject's head during radiographic acquisition. To assess reliability of the study method, the identification of landmarks and tracing measurements of 10 randomly selected cephalometric radiographs were repeated two weeks later and the correlation coefficient values between the two repeated measurements were established. The arithmetic mean and standard deviation (SD) for all the variables were calculated and analysis of variance (ANOVA) followed by Scheffe's test was performed to detect differences between means of corresponding variables among different study groups at 0.05 significance level. All statistical tests were performed using SPSS software package (ver. 12, SPSS Inc., Chicago, IL, USA).

### 3. Results

The tracing and measurement method employed in this study proved to be reliable as reflected by the high correlation coef-

ficient value between the LP repeated measurements of all variables ( $r^2$  value ranges from 0.928 to 0.987).

The mean  $\pm$  SD of all variables among the various study groups are presented in Table 2. Significant differences ( $P < 0.05$ ) were found between males and females Class I subjects for all alveolus dimensions except for the width of the alveolus posterior to the lower incisor (Table 2). However, no significant differences ( $P < 0.05$ ) were detected between males and females Class II subjects for all variables except for the upper posterior alveolus width and the lower anterior alveolus height (Table 2). When the anterior alveolar dimensions in Class III subjects were compared between males and females, significant differences ( $P < 0.05$ ) were demonstrated between the means of upper anterior alveolus width, upper anterior alveolus height, and the lower anterior alveolus height (Table 2).

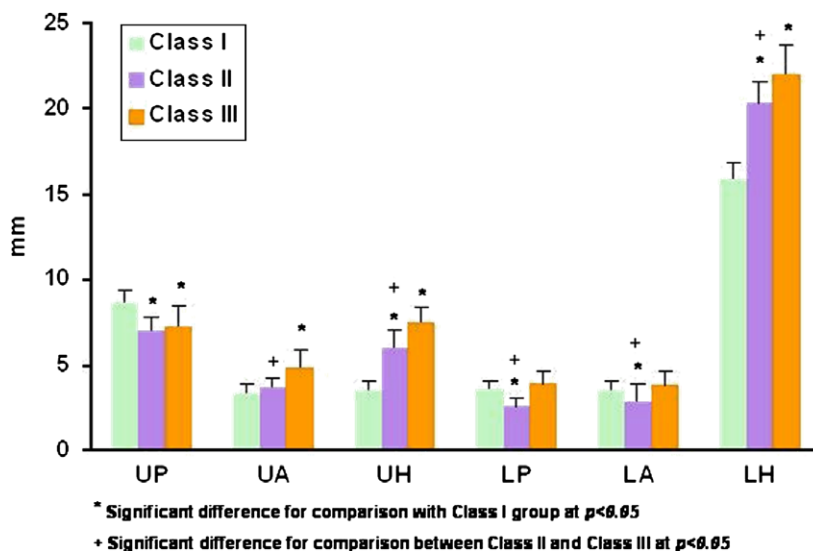
In general, both Class II male and female subjects differ significantly ( $P < 0.05$ ) from their Class I counterparts in all

**Table 2** Width and height of the anterior alveolus among the different study groups.

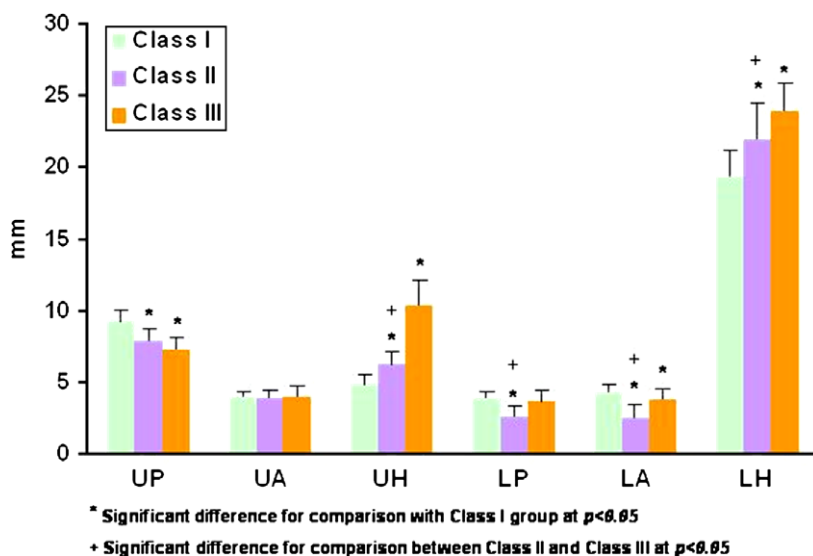
Variable	Mean $\pm$ SD (mm)					
	Female groups ( $N = 39$ )			Male groups ( $N = 42$ )		
	Class I ( $n = 15$ )	Class II ( $n = 11$ )	Class III ( $n = 13$ )	Class I ( $n = 15$ )	Class II ( $n = 13$ )	Class III ( $n = 14$ )
UP	8.65 $\pm$ 0.77*	7.02 $\pm$ 0.78*	7.27 $\pm$ 1.15	9.27 $\pm$ 0.68	7.87 $\pm$ 0.90	7.34 $\pm$ 0.84
UA	3.37 $\pm$ 0.51*	3.73 $\pm$ 0.55	4.87 $\pm$ 0.97*	4.02 $\pm$ 0.37	3.88 $\pm$ 0.55	4.07 $\pm$ 0.76
UH	3.53 $\pm$ 0.52*	6.05 $\pm$ 0.91	7.58 $\pm$ 0.78*	4.85 $\pm$ 0.65	6.29 $\pm$ 0.88	10.43 $\pm$ 1.73
LP	3.67 $\pm$ 0.45	2.55 $\pm$ 0.58	3.88 $\pm$ 0.77	3.9 $\pm$ 0.46	2.71 $\pm$ 0.73	3.77 $\pm$ 0.71
LA	3.55 $\pm$ 0.52*	2.80 $\pm$ 1.07	3.85 $\pm$ 0.77	4.38 $\pm$ 0.50	2.60 $\pm$ 0.93	3.84 $\pm$ 0.73
LH	15.83 $\pm$ 1.01*	20.32 $\pm$ 1.23*	21.94 $\pm$ 1.76*	19.35 $\pm$ 1.85	21.88 $\pm$ 2.54	23.96 $\pm$ 1.92

UP: upper posterior alveolar width, UA: upper anterior alveolar width, LP: lower posterior alveolar width, LA: lower anterior alveolar width, UH: upper alveolar height, LH: lower alveolar height.

\* Significant difference when comparing males and females for the same classification at  $P < 0.05$ .



**Figure 2** Means and standard deviations of the anterior alveolar dimensions among different classifications of sagittal maxillomandibular relationship in the female group.

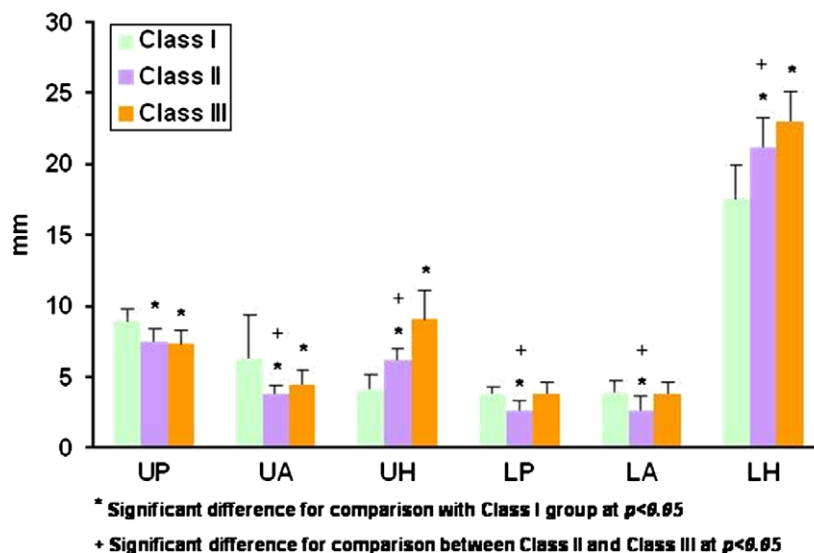


**Figure 3** Means and standard deviations of the anterior alveolar dimensions among different classifications of sagittal maxillomandibular relationship in the male group.

anterior alveolar dimensions except for the width of the upper alveolus anterior to the upper incisors (Figs. 2 and 3). When the anterior alveolar dimensions were compared between Class III and Class I female subjects, significant differences ( $P < 0.05$ ) were demonstrated between all the variables except for the anteroposterior width of the lower anterior alveolus (Fig. 2). However, Class III male subjects differed significantly ( $P < 0.05$ ) from their Class I counterparts in all anterior alveolar dimensions except at the width of the alveolus anterior to the upper incisors and posterior to the lower incisors (Fig. 3). Also, both male and female Class II subjects showed closely related pattern of significant differences of variables relative to their Class III counterparts. Female Class II and Class III subjects demonstrated significant differences ( $P < 0.05$ ) between means of all the variables except for the width of the alveolus

posterior to the upper incisors, while male Class II and Class III subjects showed significant differences ( $P < 0.05$ ) in all the variables except for the width of the alveolus both posterior and anterior to the upper incisors (Figs. 2 and 3).

Finally, when the male and female subjects were pooled together, the variables between the different maxillomandibular sagittal classifications showed significant differences (Fig. 4). Subjects with Class II skeletal pattern ( $n = 24$ ) demonstrated significant differences ( $P < 0.05$ ) for all the variables when compared to their Class I counterparts ( $n = 30$ ) (Fig. 4). Also, Class III subjects ( $n = 27$ ) showed significant differences ( $P < 0.05$ ) for all the variables when compared to Class I subjects except for the anteroposterior width of the lower anterior alveolus (Fig. 4). In addition, Class II and Class III subjects differed significantly ( $P < 0.05$ ) among all the variables except



**Figure 4** Means and standard deviations of the anterior alveolar dimensions among different classifications of sagittal maxillomandibular relationship in the pooled sample of male and female subjects.

for the width of the anterior alveolus posterior to the upper incisors (Fig. 4).

#### 4. Discussion

In this study, the anteroposterior and vertical dimensions of the anterior alveolus were compared among a sample of Saudi individuals segregated based on their gender and the sagittal skeletal jaw relationship. The anterior alveolar dimensions in Class I normal Saudi subjects have been already established (Al-Barakati and Alhadlaq, 2007). However, because of the limited remodeling ability of the anterior alveolus associated with orthodontic movement (Sarikaya et al., 2002), it remains of high clinical value to establish the dimensions of the anterior alveolus in cases of skeletal maxillomandibular malrelationship where significant orthodontic tooth movement of upper and lower incisors is expected to take place in order to compensate for the skeletal malrelationship. The rationale for selecting individuals with significant skeletal jaw discrepancy in this study ( $ANB > 5^\circ$  for Class II and  $ANB < -1^\circ$  for Class III) is to reveal any significant differences between anterior alveolar dimensions in Class I normal subjects and true Class II and Class III cases. Border line cases of mild skeletal discrepancy may not require significant anteroposterior movement of upper and lower incisors and may be a subject of controversy in classification. In addition, since significant differences between anterior alveolar dimensions were demonstrated among male and female groups in Class I normal Saudi subjects (Al-Barakati and Alhadlaq, 2007), the sample was distributed according to the gender in the present study as well to detect if similar differences do exist in cases of skeletal jaw malrelationship. However, comparison between alveolar width variables was also performed between the different sagittal maxillomandibular classifications when the male and female subjects were pooled for each variable group. This was performed to detect any significant differences when the sample size is increased within each group and for the purpose of comparison with other studies which did not account for the gender classification between groups (Handelman, 1996).

When male and female groups were compared, significant difference ( $P < 0.05$ ) was found between all dimensions the anterior alveolus except for the alveolar width posterior to the lower incisor. This finding is similar to the finding of the previous study (Al-Barakati and Alhadlaq, 2007) that majority of the anterior alveolar dimensions showed significant difference between males and females in Class I normal subjects. However, in the previous study (Al-Barakati and Alhadlaq, 2007), the width of the alveolus anterior to the upper incisors was not significantly different among males and females. This minor discrepancy in findings between the two studies, however, can be related to differences in the sample size and/or different dentoalveolar characteristics of the two samples. In the present study, fewer differences between males and females were detected for the anterior alveolar dimensions in Class II and Class III subjects than in Class I cases. Previous investigation (Handelman, 1996) which compared the anterior alveolar dimensions among different skeletal jaw relationships did not segregate the sample based on the gender, and thus comparison with the present study on this regard could not be performed. In general, for all sagittal jaw classifications, male individuals showed greater values of anterior alveolar dimensions than their female counterparts from the same classification. This finding is in accordance with the previous studies that have established cephalometric norms for Saudi male and female individuals (Shalhoub et al., 1987; Al-Jasser, 2005; Hassan, 2006; Al-Barakati and Alhadlaq, 2007).

Class II subjects showed similar pattern of differences of the anterior alveolar dimensions when compared to the corresponding dimensions in the Class I group for both genders. All dimensions of the anterior alveolus in Class II subjects for both males and females showed significant difference from those in Class I subjects except for the width of the alveolus anterior to the upper incisors. In contrast, no significant difference was detected between any of the anterior alveolar dimensions in Class II and Class I normal subjects as reported by Handelman (1996). This difference in finding can be related to multiple factors including differences in sample population, sample size, selection criteria, and/or pooling of the male and

female subjects in one group in the other study (Handelman, 1996). Nonetheless, the pattern of differences between the corresponding variables in Class II and Class I subjects is similar among the two studies. For example, the height of both upper and lower anterior alveolus is greater in Class II subjects than in Class I subjects as demonstrated by both studies. This consistency between the two studies in this finding reflects the general tendency for the Class II individuals to possess a greater height of the upper and lower anterior alveolus than Class I individuals.

In the present study, differences between the corresponding anterior alveolar dimensions in Class III and Class I normal subjects varied between males and females. Female Class III sample differed significantly from female Class I sample in all anterior alveolar dimensions except for the anterior and posterior width of the lower anterior alveolus, while Class III male subjects differed significantly from Class I male subjects in all anterior alveolar dimensions except for the anterior width of the upper alveolus and the posterior width of the lower alveolus. Similar previous study (Handelman, 1996) that had investigated for the correlation between anterior alveolar dimensions and sagittal jaw relationship, however, did not account for the gender upon segregation of the study sample to allow for comparison with the present study on this finding. In contrast to Class II subjects, Handelman<sup>4</sup> reported significant differences between Class III subjects and Class I normal subjects in the width of the alveolus posterior to the lower incisors and the height of the upper and lower anterior alveolus. Similarly, the present study has found significant differences in the height of the upper and lower anterior alveolus among Class III and Class I subjects of both male and female groups. This consistency in finding between the two studies may demonstrate part of the dentoalveolar compensation in Class III individuals with an increased anterior alveolar height due to overeruption of upper and lower incisors to conquer for the typical lack of anterior occlusion in such cases.

When the anterior alveolar dimensions in Class II and Class III subjects were compared, most dimensions showed significant differences in both male and female groups. This finding is in contrast to the finding of Handelman (1996) who demonstrated only one significant difference between the anterior alveolar dimensions in Class II and Class III Caucasian subjects related to the width of the alveolus posterior to the lower incisors. Also, most anterior alveolar dimensions were found to be of greater value in Class III subjects than in Class II subjects within each gender's group in the present study. Such observation, on the contrary, was demonstrated only for the height of the upper and lower anterior alveolus by Handelman (1996). In general, variability in the sample background and study methods can account for these inconsistencies among the two studies.

Comparison of the findings of the present study when the male and the female subjects were pooled together for each variable group with a related study (Handelman, 1996) which has been performed on Caucasian population showed marked distinctions between the two studies. For example, in contrast to the study of Handelman (1996) where no significant differences were demonstrated between Class I and Class II subjects in all the variables, the present study demonstrated significant differences between all the variables among the two groups. Also, while Class III subjects differed significantly from their average counterparts in the posterior width of the lower ante-

rior alveolus and the height of both upper and lower anterior alveolus in the Caucasians, the Saudi Class III subjects in the present study showed significant differences among all the variables except for the anterior and posterior width of the lower anterior alveolus. Lastly, while the present study demonstrated significant differences among all the variables between Class II and Class III subjects except for the posterior width of the upper anterior alveolus, Handelman (1996) failed to demonstrate any significant difference between the two groups except for the posterior width of the lower anterior alveolus. Once more, variability of racial background and sample selection criteria between the two studies may account for such differences in findings.

Further studies to investigate the relationship between the dimensions of the anterior alveolus and other skeletal jaw malrelationships in the vertical and transverse dimensions are recommended.

## 5. Conclusion

The present study established the dimensions of the anterior alveolus as measured from the lateral cephalometric radiograph for a selected group of Saudi individuals with normal and abnormal sagittal skeletal jaw relationship. Significant differences of the anterior alveolar dimensions were found between males and females with Class I, Class II, and Class III skeletal maxillomandibular classification. When controlling for the gender, significant differences of the anterior alveolar dimensions were detected between individuals with Class I normal jaw relationship and individuals with Class II or Class III jaw relationship. In addition, Class II jaw relationship subjects were demonstrated to have multiple significantly different anterior alveolar dimensions when compared to subjects with Class III jaw relationship.

## References

- Al-Barakati, S., Alhadlaq, A., 2007. Anterior alveolar dimensions in Class I Saudi subjects. *J. Pak. Dent. Ass.* 16, 95–102.
- Al-Jasser, N.M., 2005. Cephalometric evaluation for Saudi population using the Downs and Steiner analysis. *J. Contemp. Dent. Pract.* 6, 52–63.
- Bills, D.A., Handelman, C.S., BeGole, E.A., 2005. Bimaxillary dentoalveolar protrusion: traits and orthodontic correction. *Angle Orthod.* 75, 333–339.
- Costa Pinho, T.M., Ustrell Torrent, J.M., Correia Pinto, J.G., 2004. Orthodontic camouflage in the case of a skeletal class III malocclusion. *World J. Orthod.* 5, 213–223.
- Demir, A., Uysal, T., Sari, Z., Basciftci, F.A., 2005. Effects of camouflage treatment on dentofacial structures in Class II division I mandibular retrognathic patients. *Eur. J. Orthod.* 27, 524–531.
- Edwards, J.G., 1976. A study of the anterior portion of the palate as it relates to orthodontic therapy. *Am. J. Orthod.* 69, 249–273.
- Handelman, C.S., 1996. The anterior alveolus: its importance in limiting orthodontic treatment and its influence on the occurrence of iatrogenic sequelae. *Angle Orthod.* 66, 95–109.
- Hassan, A.H., 2006. Cephalometric norms for Saudi adults living in the western region of Saudi Arabia. *Angle Orthod.* 76, 109–113.
- Horiuchi, A., Hotokezaka, H., Kobayashi, K., 1998. Correlation between cortical plate proximity and apical root resorption. *Am. J. Orthod. Dentofac. Orthop.* 114, 311–318.
- Lupi, J.E., Handelman, C.S., Sadowsky, C., 1996. Prevalence and severity of apical root resorption and alveolar bone loss in

- orthodontically treated adults. *Am. J. Orthod. Dentofac. Orthop.* 109, 28–37.
- Mirabella, A.D., Artun, J., 1995. Risk factors for apical root resorption of maxillary anterior teeth in adult orthodontic patients. *Am. J. Orthod. Dentofac. Orthop.* 108, 48–55.
- Mulie, R.M., Hoeve, A.T., 1976. The limitations of tooth movement within the symphysis, studied with laminagraphy and standardized occlusal films. *J. Clin. Orthod.* 10, 882–893.
- Sarikaya, S., Haydar, B., Cığır, S., Ariyürek, M., 2002. Changes in alveolar bone thickness due to retraction of anterior teeth. *Am. J. Orthod. Dentofac. Orthop.* 122, 15–26.
- Sergl, H.G., Kerr, W.J., McColl, J.H., 1996. A method of measuring the apical base. *Eur. J. Orthod.* 18, 479–483.
- Shalhoub, S.Y., Sarhan, O.A., Shaikh, H.S., 1987. Adult cephalometric norms for Saudi Arabians with a comparison of values for Saudi and North American Caucasians. *Brit. J. Orthod.* 14, 273–279.
- Vardimon, A.D., Oren, E., Ben-Bassat, Y., 1998. Cortical bone remodeling/tooth movement ratio during maxillary incisor retraction with tip versus torque movements. *Am. J. Orthod. Dentofac. Orthop.* 114, 520–529.
- Wainwright, W.M., 1973. Faciolingual tooth movement: its influence on the root and cortical plate. *Am. J. Orthod.* 64, 278–302.
- Wonglamsam, P., Manosudprasit, M., Godfrey, K., 2003. Facio-lingual width of the alveolar base. *Aust. Orthod. J.* 19, 1–11.