

Dissociated pulmonary vein potentials: Expression of the cardiac autonomic nervous system following pulmonary vein isolation?



Andreas Kyriacou, MRCP, PhD,[†] Sajad Hayat, MRCP, MD,[†] Norman Qureshi, MA, MRCP,^{*†} Nicholas S. Peters, FRCP, PhD, FHRS,^{*†} Prapa Kanagaratnam, FRCP, PhD,^{*†} Phang Boon Lim, MRCP, PhD^{*†}

From the ^{*}National Heart and Lung Institute, Imperial College London, London, United Kingdom, and [†]Imperial College Healthcare NHS Trust, London, United Kingdom.

Introduction

In the electrically nonisolated pulmonary veins, the cardiac autonomic system has been shown to play an important role in initiating pulmonary vein (PV) ectopy and triggering atrial fibrillation (AF).^{1–3} However, the effects of the cardiac autonomic system on the isolated PV are not currently known. We present the observations from a case where opportunistic stimulation of the autonomic system was performed in the presence of dissociated pulmonary vein potentials (PVPd).

Case report

A 56-year-old man with lone paroxysmal AF had 3 PV isolation procedures over 2 years. Following each intervention he experienced recurrence of palpitations within a few weeks, clearly documented as paroxysms of AF despite antiarrhythmic therapy. He was offered a fourth ablation, as he continued to be highly symptomatic on a weekly basis.

Following an uncomplicated transeptal puncture and creation of a 3-dimensional left atrial geometry, the pulmonary veins were mapped with a circumferential mapping catheter. All pulmonary veins, except for the left inferior pulmonary vein (LIPV), were not only isolated but also electrically silent. However, the LIPV exhibited PVPd with a longer cycle length compared to sinus rhythm, which did not

conduct to the atria. Isolation of this vein was confirmed by demonstrating exit block; pacing from within the PV led to capture of the local sleeve with no propagation of conduction to the atrial tissue (Figure 1). Administration of adenosine did not reveal any left atrial–PV conduction in any vein, and did not affect the PVPd within the LIPV.

As all PVs were electrically isolated, a decision was made to explore the role of the intrinsic cardiac autonomic nervous system in potentially triggering PV tachycardia within the LIPV, as we have previously demonstrated using the technique of synchronized high-frequency stimulation (HFS).¹ HFS was delivered at the described anatomic location of the ganglionated plexus close to the LIPV antra. This led to accelerated PV firing within the vein, but with exit block still maintained (Figure 2). When synchronized HFS was stopped, the dissociated potentials decelerated to the baseline rate.

We elected to perform radiofrequency ablation at this ganglionated plexus site, owing to the increased PV firing that was triggered by the autonomic stimulation. Within 1 second of radiofrequency application, PV firing accelerated once again, but on this occasion also conducted into the atria, which led to AF initiation, with the appearance of fixed conduction timing between the PV electrograms and the coronary sinus (CS) atrial electrograms for the first 2 beats (black arrows in Figure 3A) before onset of AF. This rapid PV ectopy continued until the end of ablation delivery, following which the pulmonary ectopy slowed to baseline cycle length, but with AF continuing (Figure 3A and B).

In view of this unique observation, a cluster of radiofrequency ablation lesions were delivered at this presumed ganglionated plexus site, which eventually led to the elimination of the PVPd arising from this vein.

Following this, AF spontaneously terminated within 5 minutes, and no further PV firing was inducible by further attempts at synchronized HFS or by administration of adenosine. No further ablation was performed and the procedure was stopped after this.

KEYWORDS Cardiac autonomic nervous system; Dissociated pulmonary vein potentials

ABBREVIATIONS AF = atrial fibrillation; AV = atrioventricular; HFS = high-frequency stimulation; LIPV = left inferior pulmonary vein; PV = pulmonary vein; PVPd = dissociated pulmonary vein potentials (Heart Rhythm Case Reports 2015;1:401–405)

Disclosure: The autonomic group at Imperial are supported by the National Institute of Health Research Biomedical Research Scheme, and Dr Lim is supported by the British Heart Foundation grant FS/06/089.

Address reprint requests and correspondence: Phang Boon Lim, Imperial College Healthcare NHS Trust, Hammersmith Hospital, Cardiology Department, 2nd Floor B Block, Du Cane Rd, London W12 0HS, United Kingdom. E-mail address: p.b.lim@imperial.ac.uk.

KEY TEACHING POINTS

- The cardiac autonomic nervous system (ANS) may be implicated in the expression of dissociated pulmonary vein potentials.
- From our observation, it appears that sufficient stimulation of the cardiac ANS may also promote pulmonary vein–left atrial electrical reconnection.
- The opportunistic (if not routine) examination of the cardiac ANS may be of value in successfully treating recurrent paroxysmal atrial fibrillation.

The patient has remained symptom free 6 months following the procedure, and is not taking any antiarrhythmic therapy.

Discussion

The role of the autonomic nervous system in promoting dissociated pulmonary vein activity

The cardiac autonomic system has been implicated in the initiation of PV ectopy and AF.^{2,3} PVPd are often seen, and have been considered to be a marker of PV isolation and an adequate endpoint for an AF ablation procedure.⁴ However, more recently investigators have suggested that PVPd may be predictive of acute reconnection in isolated pulmonary veins.⁵ Another group has investigated the response of PVPd following administration of adenosine.⁶ They found a mixed response to adenosine: in most patients there was an increase in the rate of PVPd and in others a reduction in the rate of PVPd, and in very few both effects were observed. The long-term implications of PVPd are currently unknown. However,

it has been suggested that the presence of the PVPd may not be useful in predicting AF recurrence in the long term.⁷

We have previously demonstrated that synchronized HFS was able to trigger PV ectopy and PV tachycardia, leading to initiation of AF.¹ However, in this group of patients with paroxysmal AF, HFS was performed in patients prior to the PV isolation procedure. Ablation around presumed sites of ganglionated plexi abolished these PV ectopic responses, as did conventional PV isolation using the cryoballoon, which did not specifically target the autonomic ganglia.⁸ These findings indicate that endocardial ablation may be able to abolish ectopic PV triggers of AF, which may explain successful outcomes, even in the presence of high PV reconnection rates.⁹

The unique observation from this case appears to indicate that autonomic stimulation of the ganglionated plexus located outside the PV is able to induce electrophysiologic changes within the PV, *across* a line of previous electrical isolation. This observation is supported by anatomic studies showing the course of neurons traversing the PV–atrial junction transmurally, but also *epicardially*, which could be one explanation of continued “neuronal conduction” on the epicardial surface in the presence of electrical (myocardial) disconnection.¹⁰ Adenosine, which mimics acetylcholine signaling¹¹ and activates the autonomic nervous system, has been shown to increase PVPd frequency or induce spontaneous PVPd in previously silent PVs,⁶ which may be a further indication of persistent neuronal connection post PV isolation.

Autonomic influences in paroxysmal atrial fibrillation

PV ectopy has been shown to trigger AF in humans,¹² with specific variations in autonomic tone seen to precede onset of

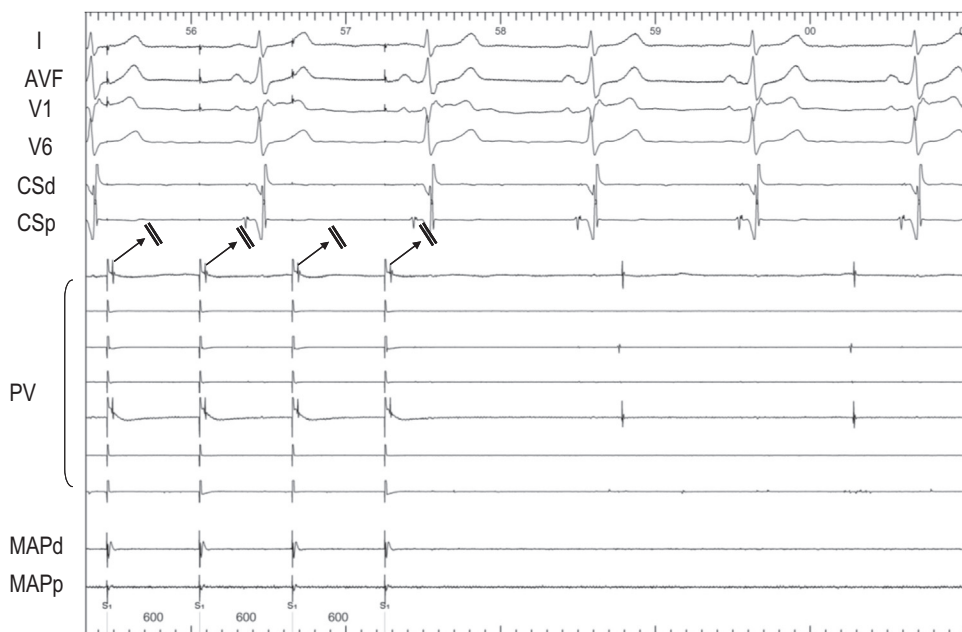


Figure 1 Demonstration of exit block from the pulmonary vein. The pulmonary vein is paced using the circumferential mapping catheter with capture of a local sleeve but failure to conduct to the atrial tissue, as shown by the arrows. With cessation of pacing the atrial rate remains unchanged, with evidence of dissociated pulmonary potentials.

PV ectopy that triggers AF.^{13,14} Using a combination of optical mapping and intracellular microelectrodes, Po et al¹⁵ showed in superfused canine PV preparations that sustained PV tachycardias could only be induced in the presence of acetylcholine and re-entry was shown to be the mechanism of these tachycardias. The authors surmised that the structural and functional nonuniformity of the PV, in the presence of autonomic modulation, could provide a fertile substrate for re-entry.

On this basis, several studies have been performed that aim to target ganglionated plexi, typically as adjunctive ablation to PV isolation, but with varying success rates.^{16–18} This variation may be due to the differing techniques used to identify and ablate the autonomic nervous system, including pure anatomic localization based on the presumed locations of plexi sites¹⁹ (2012 HRS consensus document), or with attempts at producing a functional response (atrioventricular [AV] block) using HFS to locate

these sites.¹⁶ However, we demonstrated in previous human studies that synchronized HFS produced PV ectopic responses in the PV adjacent to the stimulated ganglionated plexus, but with continuous HFS applied to the same site, no consistent AV nodal responses could be observed. This observation suggests that using an AV nodal functional response to continuous HFS to locate ganglionated plexi may not be sufficient to locate the ectopic-triggering ganglionated plexi sites, highlighting the complexity of the intrinsic cardiac autonomic neural network, both in its distribution and in its functional response.^{1,8}

Given the significant challenges in maintaining long-lasting PV isolation, it may be time to revisit a mechanistically guided strategy targeting the upstream triggers of PV ectopy and tachycardia. The autonomic nervous system appears to be a promising target, and more studies are needed to explore the role of ablative treatment of these ectopy-inducing ganglionated plexi in treatment of paroxysmal AF.

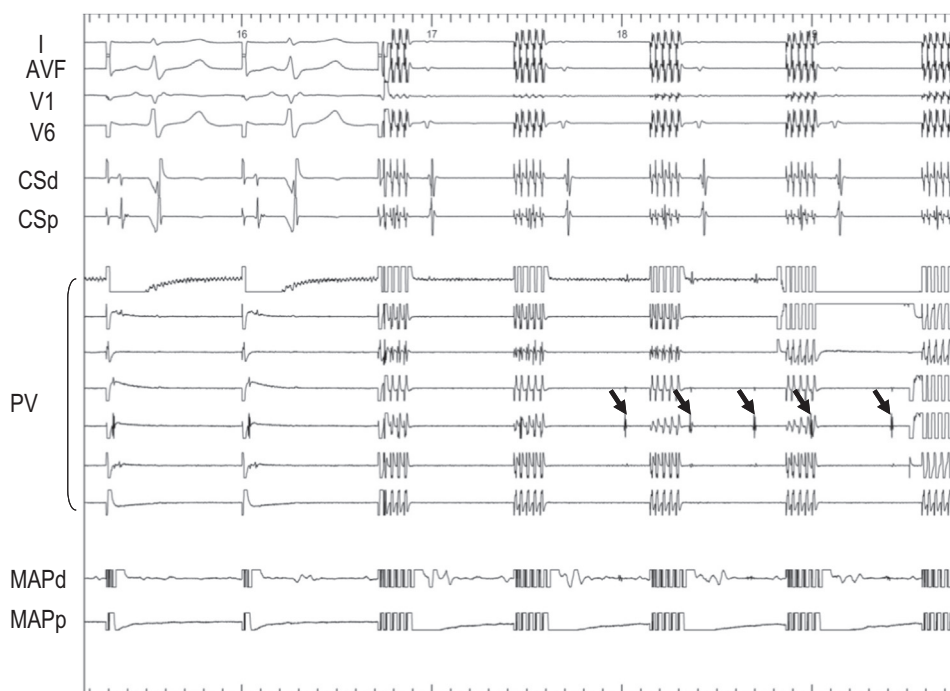


Figure 2 High-frequency stimulation (HFS) of the ganglionic plexus. HFS was delivered at the antrum of the left inferior pulmonary vein at a presumed ganglionated plexus site. Shortly after the onset of the HFS delivery there was initiation of rapid pulmonary vein firing, as shown by the arrows, but with exit block to the atrium still maintained.

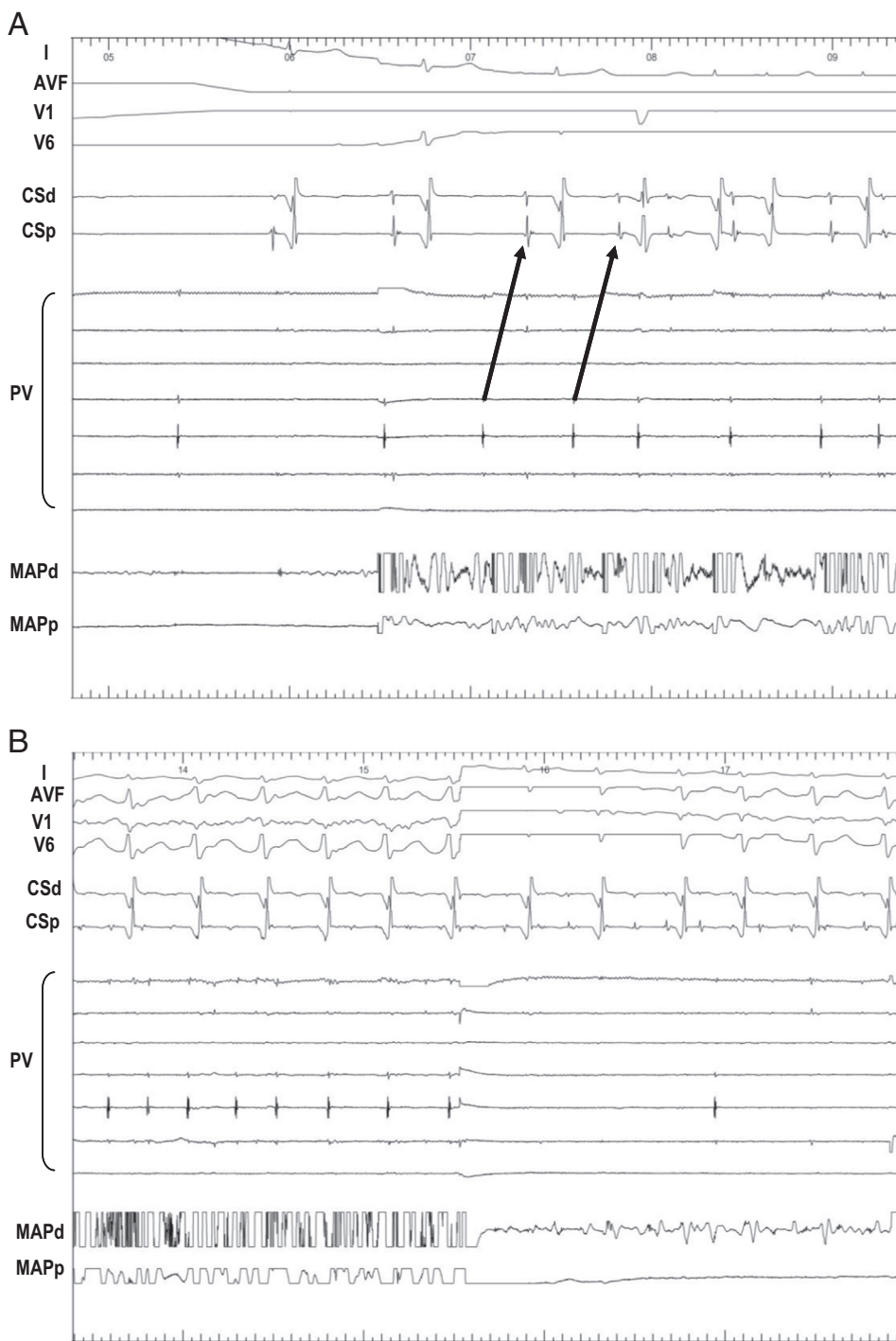


Figure 3 Radiofrequency ablation at the ganglionic plexus. **A:** Radiofrequency application at the site of the ganglionic plexus not only accelerated pulmonary vein (PV) firing but on this occasion there was conduction into the atrium (*arrows*), which led to atrial fibrillation. **B:** Following the end of the ablation delivery, the frequency of the PV firing returned to baseline, with eventual cessation of PV ectopy after a cluster of ablation lesions at the ganglionic plexus site.

References

1. Lim PB, Malcolm-Lawes LC, Stuber T, Wright I, Francis DP, Davies DW, Peters NS, Kanagaratnam P. Intrinsic cardiac autonomic stimulation induces pulmonary vein ectopy and triggers atrial fibrillation in humans. *J Cardiovasc Electrophysiol* 2011;22:638–646.
2. Schauerte P, Scherlag BJ, Patterson E, et al. Focal atrial fibrillation: experimental evidence for a pathophysiological role of the autonomic nervous system. *J Cardiovasc Electrophysiol* 2001;12(5): 592–599.
3. Scherlag BJ, Yamanashi WS, Patel U, et al. Autonomically induced conversion of pulmonary vein focal firing into atrial fibrillation. *J Am Coll Cardiol* 2005;45(11): 1878–1886.
4. Duytschaever M, De Meyer G, Acena M, El-Haddad M, De Greef Y, Van Heuverswyn F, Vandekerckhove Y, Tavernier R, Lee G, Kistler P. Lessons from dissociated pulmonary vein potentials: entry block implies exit block. *Europace* 2013;15(6):805–812.
5. Jiang CY, Fu JW, Matsuo S, Nault I, He H, Jiang RH, Liu Q, Fan YQ, Sheng X, Zhang ZW, Fu GS. Dissociated pulmonary vein rhythm may predict the acute

- pulmonary vein connection post-isolation in patients with paroxysmal atrial fibrillation. *Europace* 2011;13(7):949–954.
6. Cheung JW, Ip JE, Chung JH, Markowitz SM, Liu CF, Thomas G, Lee JM, Lessner SJ, Lerman BB. Differential effects of adenosine on pulmonary vein ectopy after pulmonary vein isolation: implications for arrhythmogenesis. *Circ Arrhythm Electrophysiol* 2012;5(4):659–666.
 7. Lee G, Kalman JM, Vohra JK, Teh A, Medi C, Ling LH, Kistler PM. Dissociated pulmonary vein potentials following antral pulmonary vein isolation for atrial fibrillation: impact on long-term outcome. *Heart* 2011;97(7):579–584.
 8. Malcolme-Lawes LC, Lim PB, Wright I, Kojodjojo P, Koa-Wing M, Jamil-Copley S, Dehbi HM, Francis DP, Davies DW, Peters NS, Kanagaratnam P. Characterization of the left atrial neural network and its impact on autonomic modification procedures. *Circ Arrhythm Electrophysiol* 2013;6(3):632–640.
 9. Cappato R, Negroni S, Pecora D, Bentivegna S, Lupo PP, Carolei A, Esposito C, Furlanello F, De Ambroggi L. Prospective assessment of late conduction recurrence across radiofrequency lesions producing electrical disconnection at the pulmonary vein ostium in patients with atrial fibrillation. *Circulation* 2003;108(13):1599–1604.
 10. Vaitkevicius R, Saburkina I, Rysevaite K, Vaitkeviciene I, Pauziene N, Zaliunas R, Schauerte P, Jalife J, Pauza DH. Nerve supply of the human pulmonary veins: an anatomical study. *Heart Rhythm* 2009;6(2):221–228.
 11. Belardinelli L, Giles WR, West A. Ionic mechanisms of adenosine actions in pacemaker cells from rabbit heart. *J Physiol* 1988;405:615–633.
 12. Haïssaguerre M, Jais P, Shah DC, Takahashi A, Hocini M, Quiniou G, Garrigue S, Le Mouroux A, Le Métayer P, Clémenty J. Spontaneous initiation of atrial fibrillation by ectopic beats originating in the pulmonary veins. *N Engl J Med* 1998;339(10):659–666.
 13. Zimmermann M, Kalusche D. Fluctuation in autonomic tone is a major determinant of sustained atrial arrhythmias in patients with focal ectopy originating from the pulmonary veins. *J Cardiovasc Electrophysiol* 2001;12(3):285–291.
 14. Bettoni M, Zimmermann M. Autonomic tone variations before the onset of paroxysmal atrial fibrillation. *Circulation* 2002;105(23):2753–2759.
 15. Po SS, Li Y, Tang D, Liu H, Geng N, Jackman WM, Scherlag B, Lazzara R, Patterson E. Rapid and stable re-entry within the pulmonary vein as a mechanism initiating paroxysmal atrial fibrillation. *J Am Coll Cardiol* 2005;45(11):1871–1877.
 16. Scherlag BJ, Nakagawa H, Jackman WM, Yamanashi WS, Patterson E, Po S, Lazzara R. Electrical stimulation to identify neural elements on the heart: their role in atrial fibrillation. *J Interv Card Electrophysiol* 2005;13(Suppl 1):37–42.
 17. Pokushalov E, Romanov A, Katritsis DG, Artyomenko S, Shirokova N, Karaskov A, Mittal S, Steinberg JS. Ganglionated plexus ablation vs linear ablation in patients undergoing pulmonary vein isolation for persistent/long-standing persistent atrial fibrillation: a randomized comparison. *Heart Rhythm* 2013;10(9):1280–1286.
 18. Katritsis DG, Giazitoglou E, Zografos T, Pokushalov E, Po SS, Camm AJ. Rapid pulmonary vein isolation combined with autonomic ganglia modification: a randomized study. *Heart Rhythm* 2011;8(5):672–678.
 19. Calkins H, Kuck KH, Cappato R, et al. Heart Rhythm Society Task Force on Catheter and Surgical Ablation of Atrial Fibrillation. 2012 HRS/EHRA/ECAS expert consensus statement on catheter and surgical ablation of atrial fibrillation: recommendations for patient selection, procedural techniques, patient management and follow-up, definitions, endpoints, and research trial design: a report of the Heart Rhythm Society (HRS) Task Force on Catheter and Surgical Ablation of Atrial Fibrillation. Developed in partnership with the European Heart Rhythm Association (EHRA), a registered branch of the European Society of Cardiology (ESC) and the European Cardiac Arrhythmia Society (ECAS); and in collaboration with the American College of Cardiology (ACC), American Heart Association (AHA), the Asia Pacific Heart Rhythm Society (APHRS), and the Society of Thoracic Surgeons (STS). Endorsed by the governing bodies of the American College of Cardiology Foundation, the American Heart Association, the European Cardiac Arrhythmia Society, the European Heart Rhythm Association, the Society of Thoracic Surgeons, the Asia Pacific Heart Rhythm Society, and the Heart Rhythm Society. *Heart Rhythm* 2012;9(4):632–696.