Hellenic Journal of Cardiology (2016) xx, 1–2

Available online at www.sciencedirect.com

ScienceDirect

journal homepage: http://www.journals.elsevier.com/hellenic-journal-of-cardiology/

LETTER TO THE EDITOR

Evolution of the electrocardiogram in a patient with arrhythmogenic right ventricular cardiomyopathy

A 35-year-old male patient had been diagnosed with arrhythmogenic right ventricular cardiomyopathy (ARVC) presenting with two minor and one major among the then actual criteria,[1] namely sustained monomorphic ventricular tachycardia with left bundle branch block superior axis configuration recurring under amiodarone treatment, negative T-waves in leads V1-V4 in sinus rhythm and manifest RV dilation on computed tomography (Figure 1A) 11 years ago. Endocardial linear catheter ablation of the ventricular tachycardia was done 5 years later and no recurrences were recorded since. At the time of this first admission epsilon waves were lacking on the standard 12-lead ECG and on Fontaine leads. At that time the patient had also paroxysmal atrial fibrillation for which he continued to receive 100 mg of amiodarone daily. Due to amiodarone-induced thyroid toxicity and in line with the results of recently published study showing decreased total mortality with rhythm control strategy[2] he was recently admitted for pulmonary vein isolation. The procedure was uneventful. The His-ventricular interval measured during the ablation was 67 milliseconds. The computed tomography (Figure 1B) done before the procedure showed evolved RV dilation and multiple low density areas in the RV, the interventricular septum and the left ventricular apex corresponding to fatty infiltration. The ECG showed QRS morphology fulfilling the criteria for complete right bundle branch block (RBBB)[3] and clearly discernible epsilon waves in many leads (Figure 1B) that were not present 6 years ago. These waves represent delayed excitation of the areas of RV myocardium involved by fibro-fatty replacement, are usually present in leads V1-V3, and are a major diagnostic criterion for ARVC.[1,4] The extensive distribution of the epsilon waves in this patient was most probably due to the advanced RV dilation causing extensive adjacency to the area of the recording electrodes and to the involvement of the interventricular septum and left ventricular apex by the disease. In a recent study by Protonotarios et al. among 86 patients with ARVC epsilon waves were present in 25 (29%). Epsilon waves beyond chest lead V3 were found in 9 of those 25 patients and were associated with increased RV outflow tract diameter and wall motion abnormalities. Besides, epsilon waves in the inferior leads were present in 7 of the same 25 subjects.[5] In another study by Peters et al. only 6% (22 of 374) of the patients with ARVC had complete RBBB and most of them developed the conduction disorder during follow-up.[6] The presence of RBBB with a manifest terminal delay in leads I and V6 in our case precludes the use of signal-averaged ECG in the quest for additional diagnostic criteria.[4,7] Besides, positive SAECG belongs to the group of the depolarization criteria together with the epsilon waves and as such would not be of further value. Of note however, in a recent paper by Efremidis the presence of a very late potential, beyond the end of the QRS complex (at the end of the ST segment/beginning of the T wave), was found in a patient with Naxos disease and locally widened QRS complex during electrophysiologic study.[8]

In the case presented the ECG evolution over 6-years time-span started with a minor diagnostic criterion and ended up with a major one plus a conduction disorder thus reflecting the evolving myocardial disease.

Peer review under responsibility of Hellenic Cardiological Society.

http://dx.doi.org/10.1016/j.hjc.2016.09.001

Please cite this article in press as: Shalganov TN, Stoyanov MK, Evolution of the electrocardiogram in a patient with arrhythmogenic right ventricular cardiomyopathy, Hellenic Journal of Cardiology (2016), http://dx.doi.org/10.1016/j.hjc.2016.09.001

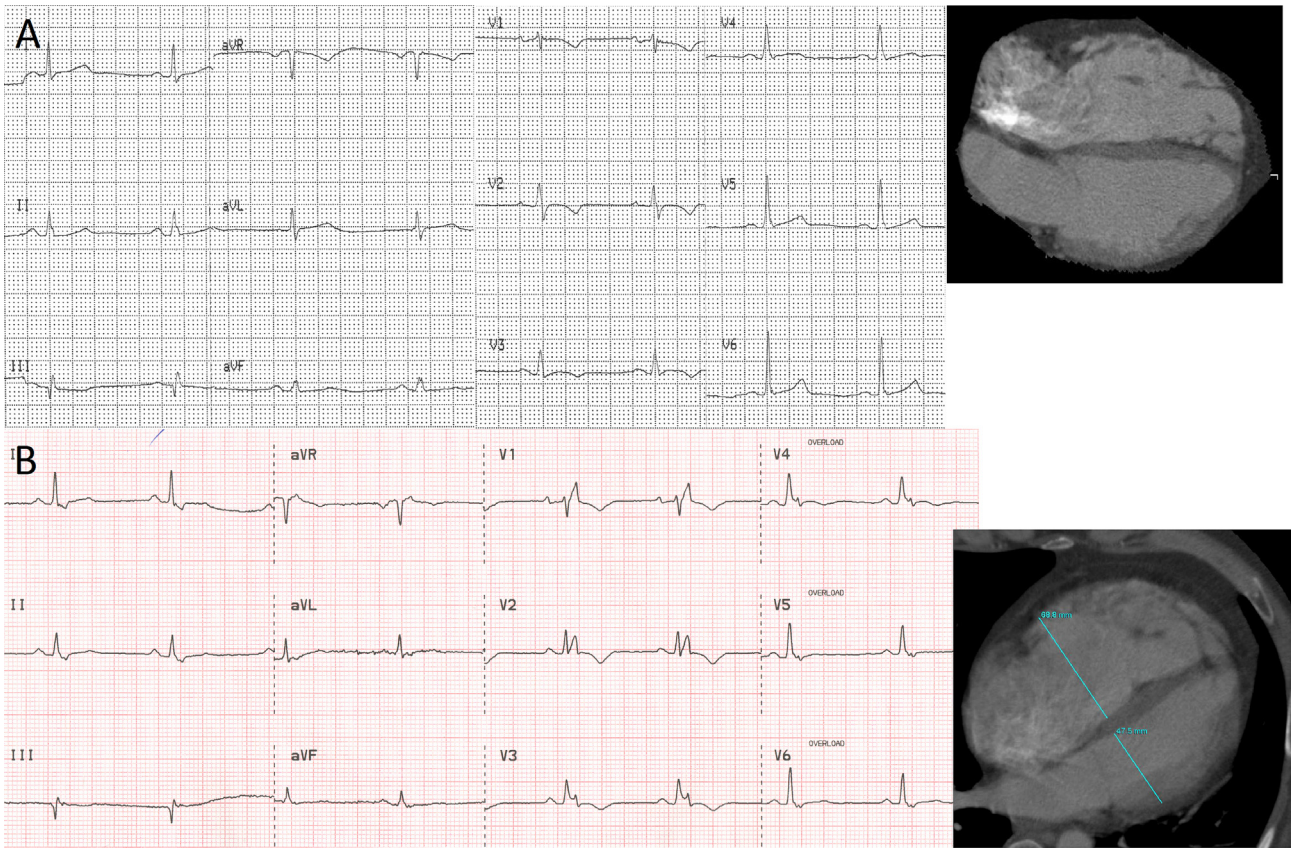

Figure 1 **A** — Standard 12-lead ECG obtained 6 years ago showing only negative T-waves in leads V1-V4; **B** — Standard 12-lead ECG obtained during the current presentation — the epsilon waves are clearly distinctive and superimposed over the right bundle branch block pattern. The inserts in both panels show the corresponding computed tomographic images.

Conflicts of interest

None

Funding sources

None

References

1. McKenna WJ, Thiene G, Nava A, et al. Diagnosis of arrhythmogenic right ventricular dysplasia/cardiomyopathy. *Br Heart J*. 1994;71:215—218.
2. Vardas P, Andrikopoulos G, Baroutsou B. A Greek prospective observational study of cardiovascular morbidity and mortality in patients with atrial fibrillation. *Hellenic J Cardiol*. 2015;56:475—494.
3. Surawicz B, Childers R, Deal BJ, Gettes LS. AHA/ACCF/HRS Recommendations for the standardization and interpretation of the electrocardiogram. Part III: intraventricular conduction disturbances. *Circulation*. 2009;119:e235—e240.
4. Marcus FI, McKenna WJ, Sherrill D, et al. Diagnosis of arrhythmogenic right ventricular cardiomyopathy/dysplasia: proposed modification of the Task Force Criteria. *Eur Heart J*. 2010;31:806—814.
5. Protonotarios A, Anastasakis A, Tsatsopoulo A, et al. Clinical significance of epsilon waves in arrhythmogenic cardiomyopathy. *J Cardiovasc Electrophysiol*. 2015;26:1204—1210.
6. Peters S, Trümmel M, Koehler B. Special features of right bundle branch block in patients with arrhythmogenic right ventricular cardiomyopathy/dysplasia. *Int J Cardiol*. 2012;157:102—103.
7. Gatzoulis KA, Carlson MD, Biblo LA, et al. Time domain analysis of the signal averaged electrocardiogram in patients with a conduction defect or a bundle branch block. *Eur Heart J*. 1995;16:1912—1919.
8. Efremidis M, Prappa E, Charalampous C, et al. Endocardial late potentials during sinus rhythm define the re-entry circuit of ventricular tachycardia in arrhythmogenic right ventricular cardiomyopathy. *Hellenic J Cardiol*. 2013;54:394—396.

Tchavdar N. Shalganov, M.D., Ph.D. *
Milko K. Stoyanov, M.D.
Cardiology Department, National Heart Hospital, Sofia, Bulgaria

*Corresponding author: Assoc. prof. Tchavdar N. Shalganov, MD, PhD, Cardiology Department, National Heart Hospital, 65, Koniovitsa str., 1309 Sofia, Bulgaria.
Tel./fax: +359 2 9211 402.
E-mail address: tchavdar.shalganov@gmail.com (T.N. Shalganov)

24 June 2016