


Contents lists available at [ScienceDirect](http://www.sciencedirect.com)

## Acta Orthopaedica et Traumatologica Turcica

journal homepage: <https://www.elsevier.com/locate/aott>

## An anatomic study of the lateral patellofemoral ligament

Sercan Capkin <sup>a,\*</sup>, Gulsah Zeybek <sup>b</sup>, Ipek Ergur <sup>b</sup>, Can Kosay <sup>c</sup>, Amac Kiray <sup>b</sup><sup>a</sup> Hınıs Sağlık Yuvuz Yurekseven State Hospital, Department of Orthopaedics and Traumatology, Erzurum, Turkey<sup>b</sup> Dokuz Eylül University School of Medicine, Department of Anatomy, Izmir, Turkey<sup>c</sup> Dokuz Eylül University School of Medicine, Department of Orthopaedics and Traumatology, Izmir, Turkey

## ARTICLE INFO

## Article history:

Received 23 February 2016

Received in revised form

15 May 2016

Accepted 24 July 2016

Available online 8 August 2016

## Keywords:

Anatomic study

Lateral patellofemoral ligament

Lateral condyle of the femur

## ABSTRACT

**Objective:** The lateral patellofemoral ligament (LPFL) is part of the lateral retinaculum cut during arthroscopic or open release. We investigated its anatomic and morphometric characteristics.**Materials and methods:** We identified the LPFL insertion point on the condyle in vertical and sagittal planes in 32 adult cadaveric knees. We measured its length and width at the insertion point. We located the midpoint of this point and measured from it to the distal and posterior condylar ends. We measured anterior-posterior and proximal-distal lateral condylar lengths. We evaluated the insertion point shape on the lateral femoral condyle. Degree of relationship between variables was assessed using Pearson's correlation coefficient.  $p < 0.05$  was considered statistically significant.**Results:** The LPFL mean length was 23.2 mm, and mean width at the insertion point was 15.6 mm. Regarding its insertion into the lateral condyle, central insertions were more frequent (vertical plane: 53.1% central and sagittal plane: 75% central). A significant positive correlation was evident between the LPFL length and width at the insertion point ( $p = 0.05$ ). Thus, the LPFL length was proportional to its width at the insertion point. A significant positive correlation was found between the anterior-posterior condylar length and width of the LPFL at the insertion point ( $p = 0.017$ ). Therefore, greater anterior-posterior condylar length equates to a larger area of insertion on the condyle.**Conclusion:** Greater width of the LPFL at the insertion point corresponds to greater LPFL and anterior-posterior lateral condylar lengths.© 2016 Turkish Association of Orthopaedics and Traumatology. Publishing services by Elsevier B.V. This is an open access article under the CC BY-NC-ND license (<http://creativecommons.org/licenses/by-nc-nd/4.0/>).

## Introduction

An appreciation of the anatomy of the knee extensor mechanism, medial and lateral retinacular patellofemoral ligaments are necessary to understand patellofemoral joint stability.<sup>1</sup> Retinacular patellofemoral ligaments, particularly the medial patellofemoral ligament (MPFL), play an important role in stabilization of the patella.<sup>2–6</sup> The anatomic and biomechanical properties of the MPFL are described in detail in the literature.<sup>7–10</sup> However, the structural features and the margins of the lateral patellofemoral ligament (LPFL) remain poorly defined.<sup>11</sup>

The lateral retinaculum consists of the superficial oblique and deep transverse layers.<sup>12</sup> The LPFL and lateral patellotibial ligament in the deep transverse layer are the two main lateral retinacular structures that stabilize the patella.<sup>13</sup> Kaplan<sup>14</sup> first described the *lateral epicondylapatellar ligament* as a palpable thickening of the joint capsule. Reider and colleagues<sup>15</sup> later renamed this structure as the LPFL in an anatomic study involving 21 fresh cadaveric knees. They observed that it is a palpable thickening of the joint capsule and connects the patella to the femoral epicondyle. They described its width as ranging from 3 to 10 mm. A correlation was also reported between morphometric properties of the LPFL and patella. Merician and colleagues<sup>11</sup> found that joint capsule was thickened laterally to form the lateral patellofemoral ligament. This capsular thickening was variable from knee to knee and the margins were difficult to define exactly. The lateral patellofemoral ligament was attached to the lateral patella at its widest part and anchored to the lateral femoral epicondyle. Vieira and colleagues<sup>16</sup> resected the LPFL in 10 fresh cadaveric knees. They observed that, after

\* Corresponding author.

E-mail addresses: [sercancapkn@gmail.com](mailto:sercancapkn@gmail.com) (S. Capkin), [gulsah.zeybek@deu.edu.tr](mailto:gulsah.zeybek@deu.edu.tr) (G. Zeybek), [ipek-ergur@hotmail.com](mailto:ipek-ergur@hotmail.com) (I. Ergur), [kosaycan@gmail.com](mailto:kosaycan@gmail.com) (C. Kosay), [amac.kiray@deu.edu.tr](mailto:amac.kiray@deu.edu.tr) (A. Kiray).

Peer review under responsibility of Turkish Association of Orthopaedics and Traumatology.

resection, the patella spontaneously luxated medially, demonstrating the role of this ligament in patellar stability.

Medial subluxation of the patella is a described complication after lateral retinacular and particularly LPFL release.<sup>17,18</sup> Of the 154 cases of medial patellar subluxation reported in the literature, 144 (94%) occurred in patients who had undergone a previous lateral retinacular release procedure<sup>17–25</sup> or a lateral release and tibial tubercle transfer.<sup>26–28</sup> Performing a limited lateral release avoids this complication.<sup>11</sup> However, when lateral release procedures are examined, it is clear that both layers of the retinaculum are cut.<sup>29</sup> Different techniques have been described for the repair or reconstruction of lateral patellar stabilizers.<sup>17,30</sup>

The purpose of this study was to elucidate the morphometric characteristics of the LPFL at its insertion in the femoral condyle and to evaluate the correlation between the LPFL and lateral femoral condyle measurements, which may be helpful in better describing the lateral release or reconstruction afterwards to decrease complications.

## Materials and methods

We dissected 32 adult cadaveric knees fixed in formaldehyde at the Department of Anatomy, Dokuz Eylul University. The bilateral knees of eight female and eight male cadavers were examined. A longitudinal midline incision was made from 5 cm above the superior pole of the patella to the tibial tubercle. Then, the patella was turned down to a lateral position using the medial parapatellar approach. Subsequently, the LPFL was exposed by careful dissection (Fig. 1). We recorded measurements in two categories: measurements of the lateral condyle of the femur and LPFL. A caliper ruler with millimeter graduations was used to take these measurements.

All measurements were made with the knee at 30° of flexion. First, the anterior–posterior (A–B) and proximal–distal (C–D) lengths of the lateral condyle were measured. Then, the midpoint of the insertion point of the LPFL on the condyle (E) was identified, and we measured from this point to the distal (E–D) and posterior (E–B) ends of the condyle (Fig. 2). Next, we measured the length and width (at the insertion point on condyle) of the LPFL (Fig. 3). In addition, the lateral condyle of the femur was divided into three equal parts (superior–middle–inferior) in the vertical plane and into three equal parts (anterior–middle–posterior) in the sagittal plane. Subsequently, the areas of the insertion points of the LPFL on the condyle were identified in the sagittal and vertical planes (Fig. 4).

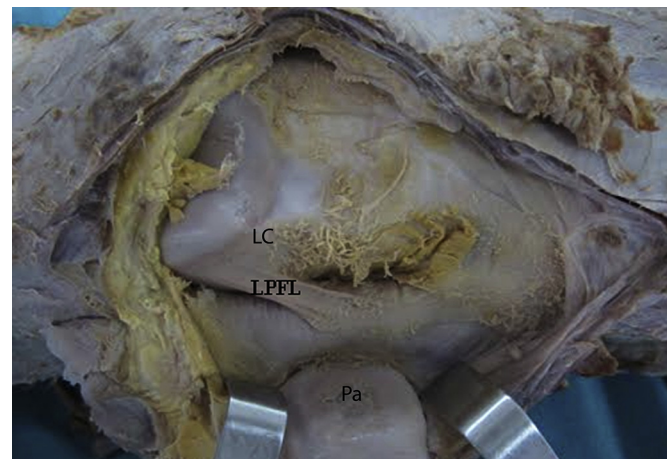


Fig. 1. Photograph of the anterolateral aspect of the left knee (LPFL: lateral patellofemoral ligament, Pa: patella, LC: lateral condyle of the femur).

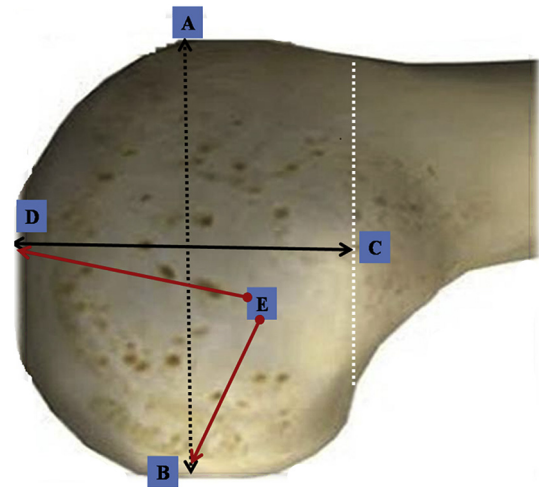


Fig. 2. Schematic representation of the measurements of the lateral condyle (A–B: anterior–posterior length of the condyle; C–D: proximal–distal length of the condyle; E–B: distance between the midpoint of the LPFL insertion point on the condyle and the posterior end of the condyle; and E–D: distance between the midpoint of the LPFL insertion point on the condyle and the distal end of the condyle).



Fig. 3. Photograph of the measurement of the LPFL (L: length, W: width, Pa: patella, LC: lateral condyle of the femur).

## Statistical analysis

All statistical analyses were performed using SPSS 18.0 (version 18.0; SPSS Inc., Chicago, IL, USA). The degree of relationship between variables was assessed using Pearson's correlation coefficient. Statistical significance was defined as  $p < 0.05$ .

## Results

In all knees, we observed that the LPFL was located in the deep retinacular layer and underwent insertion into both the patella and femur with fan-like expansions. No scar over the skin indicating an operation or no degenerative changes was observed in patella. The lateral femoral condyle and LPFL measurements are presented in Table 1.

The relationship between the width (LPFL\_W) and length (LPFL\_L) of the LPFL was analyzed, and the relationship between the LPFL\_W and measurements of the lateral condyle (LCAP\_L, LCPD\_L) was evaluated using Pearson's correlation coefficient. The relationship between the width (at the insertion point on the

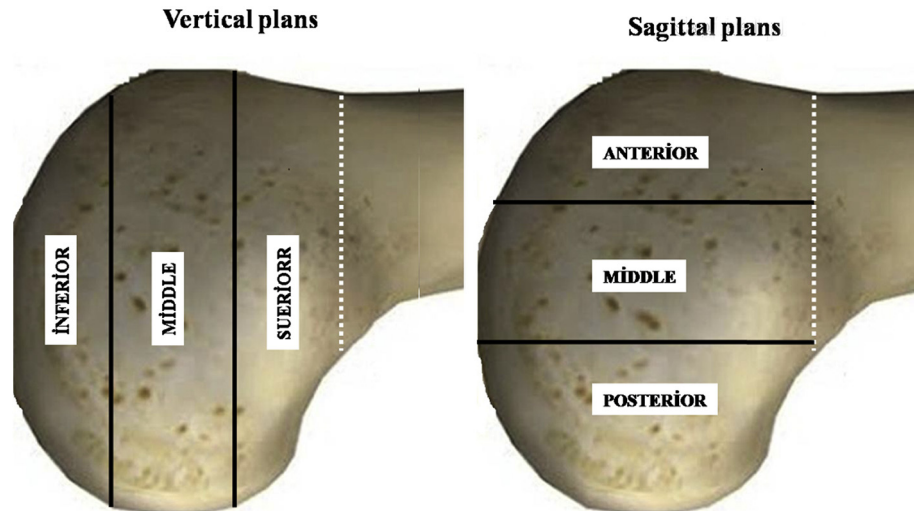


Fig. 4. Schematic representation of the lateral femoral condyle divided into three equal parts in the vertical and sagittal planes.

**Table 1**  
Measurements of the lateral condyle and lateral patellofemoral ligament.

	Min (mm)	Max (mm)	Mean (mm)	SD (mm)
LPFL_L	12.4	40	23.2	7.03
LPFL_W	9.7	33.9	15.6	5.03
LCAP_L	40.7	70.2	57.9	7.94
LCPD_L	31.1	69.2	48.9	7.97
E–B_L	9.8	29.3	19.7	5.26
E–D_L	5.1	31.2	16.5	5.94

E–B\_L: distance between the midpoint of the LPFL insertion point on the condyle and the posterior end of the condyle; E–D\_L: distance between the midpoint of the LPFL insertion point on the condyle and the distal end of the condyle; LCAP\_L, anterior–posterior length of the lateral condyle; LCPD\_L, proximal–distal length of the lateral condyle; LPFL\_L, length of the lateral patellofemoral ligament; LPFL\_W, width of the LPFL (at the insertion point on the condyle); min, minimum; max, maximum; mm, millimeter; SD, standard deviation.

condyle) and length of the LPFL was statistically significant ( $p = 0.05$ ). Also, the relationship between the width of the LPFL (at the insertion point on the condyle) and anterior–posterior length of the lateral condyle was statistically significant ( $p = 0.017$ ). Conversely, the relationship between the width of the LPFL (at the insertion point on the condyle) and proximal–distal length of the lateral condyle was not statistically significant ( $p = 0.214$ ; Table 2).

The frequencies of the positions of the insertion point of the LPFL on the lateral femoral condyle were evaluated in the vertical and sagittal planes. The insertion point of the LPFL on the condyle was superior in 37.5%, middle in 53.1%, and inferior in 9.4% in the vertical plane. The insertion point of the LPFL on the condyle was anterior in 21.9%, middle in 75%, and posterior in 3.1% in the sagittal plane (Table 3).

**Table 2**  
Degree of relationship between the pairs of variables calculated using Pearson's correlation coefficient.

Pair of variables	<i>n</i>	Correlation coefficient	<i>p</i> value
LPFL_W × LPFL_L	32	+0.335	0.05*
LPFL_W × LCAP_L	32	+0.425	0.017*
LPFL_W × LCPD_L	32	+0.229	0.214

*n*, number of knees; LPFL\_W, width of the lateral patellofemoral ligament (at the insertion point on the condyle); LPFL\_L, length of the LPFL; LCAP\_L, anterior–posterior length of the lateral condyle; LCPD\_L, proximal–distal length of the lateral condyle. \* Statistically significant  $p < 0.05$ .

## Discussion

In this study, 32 cadaveric knees were dissected to elucidate in detail the morphometric characteristics of LPFL, which are reported difficult to be defined exactly and are important in reconstructive procedures.<sup>11,15,25,31,32</sup>

We found that the mean length of the LPFL is 23.2 mm and its mean width at the insertion point on the condyle is 15.6 mm. These measurements were not in accordance with the findings of Navarro and colleagues' study in which mean length of 42.1 mm, and mean width of 16.1 mm was reported.<sup>31</sup> The difference between the studies may result from ethnic differences and the preparation of samples as their specimens were prepared fresh and not formalized.

The insertion of the LPFL into the lateral condyle was found to be more frequently in the central area (vertical plane: 53.1% middle and sagittal plane: 75% middle) in our study. These findings are also different from the study of Navarro and colleagues<sup>31</sup> in which they observed that its femoral insertion at the lateral epicondyle, which features a fan-like expansion of the fibers, is predominantly located in the posterior region, proximal to the lateral epicondyle. The patellar insertion was found in the posterior half and upper lateral aspect, also with expanded fibers in their study. They observed a significant correlation between the length of the LPFL and width of the lateral patellar facet. Hence, the shorter the LPFL, the wider the lateral patellar facet.

In our study, a significant positive correlation was evident between the length and width of the LPFL at the insertion point on the condyle ( $p = 0.05$ ). In other words, when the length of the LPFL increases, its width at the insertion point on the condyle also increases. We also observed a significant positive correlation between the anterior–posterior length of the condyle and width of the LPFL at the insertion point on the condyle ( $p = 0.017$ ). Thus,

**Table 3**  
Frequencies of the positions of the insertion point of the lateral patellofemoral ligament on the condyle in the vertical and sagittal planes.

	Vertical			Sagittal		
	Superior	Middle	Inferior	Anterior	Middle	Posterior
Number of knees	12	17	3	7	24	1
Frequency	37.5%	53.1%	9.4%	21.9%	75%	3.1%

when the anterior–posterior length of the condyle increases, the LPFL has a larger area of insertion on the condyle.

In our study, all measurements were made with the knee at 30° of flexion. Fulkerson and Gossling demonstrated that the patella presents the first articular contact with the trochlea in the first 10° of knee flexion. From 20° to 30° of flexion the patella is better adapted in the femoral trochlea and from 30° it stabilizes in the trochlear fovea.<sup>13</sup> Merican and colleagues examined the biomechanical properties of the LPFL and lateral patellofemoral ligament in eight fresh-frozen cadaveric knees. At 30° of flexion, the transverse fibers of the midsection of the lateral retinaculum were found to be the main contributor to the lateral restraint of the patella.<sup>11</sup>

Waligora and colleagues<sup>33</sup> studied the clinical anatomy of the extensor apparatus of the knee and quadriceps femoris. After dissection, they were able to describe the MPFL easily in all knees, but they were only able to describe the LPFL in one knee. They did not perform morphometric measurements. In our study, the LPFL was easily identified in all knees.

Medial dislocation or subluxation of the patella is a serious complication that can occur after an isolated arthroscopic or open lateral release.<sup>18,23</sup> One of the main causes of patellofemoral instability is extreme tension in the lateral retinaculum. This tension can cause lateral subluxation or dislocation of the patella. The LPFL, which participates in the lateral retinaculum, may be responsible for patellofemoral instability.<sup>32</sup> Teitke and Torga<sup>25</sup> described the LPFL reconstruction for medial patellar dislocation that develops after failed lateral release. They described an LPFL reconstruction technique. The 60 patients' outcomes were excellent with respect to patellar stability, and there were no cases of recurrent subluxation. Recently, successful results of the LPFL reconstruction for the treatment of medial patellar subluxation were published in another study. When nonsurgical measures fail, LPFL reconstruction can provide patellofemoral stability and excellent functional outcomes.<sup>17</sup> Our findings may be helpful in better describing the morphometric characteristics of the LPFL and the lateral release or reconstruction afterwards to decrease complications.

There are some limitations of our study. One limitation of our study is that we did not measure the width of the LPFL in the lateral patellar facet. Measurements of the of the LPFL in the lateral patellar facet would be helpful to better compare the results with the study of Navarro and colleagues.<sup>31</sup> Another limitation our specimens were prepared formalized not fresh.

In conclusion, this study showed that the LPFL is most often inserted into the middle section of the lateral condyle, and there is a significant positive correlation between its length and width at the insertion point on the condyle. In addition, we observed a significant positive correlation between the anterior–posterior length of the lateral condyle and width of the LPFL at the insertion point on the condyle. That is, greater width of the LPFL at the insertion point corresponds to greater LPFL and anterior–posterior lateral condylar lengths. The results of this study may improve current understanding of the anatomy of the femoral insertion of the LPFL and may assist surgeons in performing anatomical reconstruction.

## References

1. Andrikoula S, Tokis A, Vasiliadis HS, Georgoulis A. The extensor mechanism of the knee joint: an anatomical study. *Knee Surg Sports Traumatol Arthrosc.* 2006;14:214–220.

2. Conlan T, Garth WP, Lemons JE. Evaluation of the medial soft-tissue restraints of the extensor mechanism of the knee. *J Bone Jt Surg Am.* 1993;75:682–693.
3. Desio SM, Burks RT, Bachus KN. Soft tissue restraints to lateral patellar translation in the human knee. *Am J Sports Med.* 1998;26:59–65.
4. Hautamaa PV, Fithian DC, Kaufman KR, Daniel DM, Pohlmeier AM. Medial soft tissue restraints in lateral patellar instability and repair. *Clin Orthop.* 1998;349:174–182.
5. Nomura E, Horiuchi Y, Kihara M. Medial patellofemoral ligament restraint in lateral patellar translation and reconstruction. *Knee.* 2000;7:121–127.
6. Fithian DC, Nomura E, Arendt E. Anatomy of patellar dislocation. *Oper Tech Sports Med.* 2001;9:102–111.
7. Panagiotopoulos E, Strzelczyk P, Herrmann M, Scuderi G. Cadaveric study on static medial patellar stabilizers: the dynamizing role of the vastus medialis obliquus on medial patellofemoral ligament. *Knee Surg Sports Traumatol Arthrosc.* 2006;14:7–12.
8. Ostermeier S, Holst M, Bohnsack M, Hurschler C, Stukenborg-Colsman C, Wirth CJ. In vitro measurement of patellar kinematics following reconstruction of the medial patellofemoral ligament. *Knee Surg Sports Traumatol Arthrosc.* 2007;15:276–285.
9. Nomura E, Inoue M, Osada N. Anatomical analysis of the medial patellofemoral ligament of the knee, especially the femoral attachment. *Knee Surg Sports Traumatol Arthrosc.* 2005;13:510–515.
10. Mountney J, Senavongse W, Amis AA, Thomas NP. Tensile strength of the medial patellofemoral ligament before and after repair or reconstruction. *J Bone Jt Surg Br.* 2005;87(1):36–40.
11. Merican AM, Sanghavi S, Iranpour F, Amis AA. The structural properties of the lateral retinaculum and capsular complex of the knee. *J Biomech.* 2009;42(14):2323–2329.
12. Fulkerson JP. Normal anatomy. In: *Disorders of the Patellofemoral Joint.* 4th ed. Philadelphia: Lippincott Williams & Wilkins; 2004:1–23. p.
13. Fulkerson JP, Gossling HR. Anatomy of the knee joint lateral retinaculum. *Clin Orthop Relat Res.* 1980;153:183–188.
14. Kaplan E. Some aspects of functional anatomy of the human knee joint. *Clin Orthop Relat Res.* 1962;23:18–29.
15. Reider B, Marshall J, Koslin B, Ring B, Girsig F. The anterior aspect of the knee joint. *J Bone Jt Surg Am.* 1981;63(3):351–356.
16. Vieira EL, Vieira EA, da Silva RT, Berfein PA, Abdalla RJ, Cohen M. An anatomic study of the iliotibial tract. *Arthroscopy.* 2007;23:269–274.
17. Saper MG, Sheiner DA. Medial patellar subluxation: diagnosis and treatment. *Am J Orthop (Belle Mead NJ).* 2015;44(11):499–504.
18. Biedert RM, Friederich NF. Failed lateral retinacular release: clinical outcome. *J Sports Traumatol.* 1994;16:162–173.
19. Shannon BD, Keene JS. Results of arthroscopic medial retinacular release for treatment of medial subluxation of the patella. *Am J Sports Med.* 2007;35(7):1180–1187.
20. Hughston JC, Deese M. Medial subluxation of the patella as a complication of lateral retinacular release. *Am J Sports Med.* 1988;16(4):383–388.
21. Kolowich PA, Paulos LE, Rosenberg TD, Farnsworth S. Lateral release of the patella: indications and contraindications. *Am J Sports Med.* 1990;18:359–365.
22. Metcalf RW. An arthroscopic method for lateral release of the subluxating or dislocating patella. *Clin Orthop Relat Res.* 1982;167:9–18.
23. Nonweiler DE, DeLee JC. The diagnosis and treatment of medial subluxation of the patella after lateral retinacular release. *Am J Sports Med.* 1994;22:680–686.
24. Shellock FG, Mink JH, Deutsch AL, Fox JM, Ferkel RD. Evaluation of patients with persistent symptoms after lateral retinacular release by kinematic magnetic resonance imaging of the patellofemoral joint. *Arthroscopy.* 1990;6:226–234.
25. Teitge RA, Torga Spak R. Lateral patellofemoral ligament reconstruction. *Arthroscopy.* 2004;20:998–1002.
26. Abhaykumar S, Craig DM. Fascia lata sling reconstruction for recurrent medial dislocation of the patella. *Knee.* 1999;6:55–57.
27. Eppley RA. Medial patellar subluxation. In: Fox JM, Del Pizzo W, eds. *The Patellofemoral Joint.* New York, NY: McGraw-Hill; 1993:149–156.
28. Southwick WO, Becker GE, Albright A. Dovetail patellar tendon transfer for recurrent dislocating patella. *J Am Med Assoc.* 1968;204(8):665–669.
29. Gasser SI, Cucchetti BA. Arthroscopic lateral release of the patella with radiofrequency ablation. In: Jackson DW, ed. *Master Techniques in Orthopedic Surgery.* 3rd ed. Philadelphia: Lippincott Williams & Wilkins; 2008:1–11.
30. McCarthy MA, Bollier MJ. Medial patella subluxation: diagnosis and treatment. *Iowa Orthop J.* 2015;35:26–33.
31. Navarro MS, Beltrani Filho CA, Akita Junior J, Navarro RD, Cohen M. Relationship between the lateral patellofemoral ligament and the width of the lateral patellar facet. *Acta Ortop Bras.* 2010;18(1):19–22.
32. Luo ZP, Sakai N, Rand JA, An KN. Tensile stress of the lateral patellofemoral ligament during knee motion. *Am J Knee Surg.* 1997;10(3):139–144.
33. Waligora AC, Johanson NA, Hirsch BE. Clinical anatomy of the quadriceps femoris and extensor apparatus of the knee. *Clin Orthop Relat Res.* 2009;467(12):3297–3306.