



CLINICAL CASE

Visceral Angioedema Induced by Angiotensin Converting Enzyme Inhibitor: Case Report



Beatriz Frutuoso^{a,*}, Joana Esteves^b, Mafalda Silva^a, Pedro Gil^a,
Ana Cristina Carneiro^a, Sílvio Vale^b

^a Internal Medicine Department, Centro Hospitalar Vila Nova de Gaia/Espinho, Vila Nova de Gaia, Portugal

^b General Surgery Department, Centro Hospitalar Vila Nova de Gaia/Espinho, Vila Nova de Gaia, Portugal

Received 8 August 2015; accepted 6 October 2015

Available online 2 December 2015

KEYWORDS

Angioedema;
Angiotensin-
Converting Enzyme
Inhibitors/adverse
effects;
Intestinal Diseases

Abstract

Introduction: Intestinal angioedema is a rare adverse effect of angiotensin converting enzyme inhibitors.

Clinical case: A 42-year old woman presented to the Emergency Department complaining of diffuse abdominal pain, predominantly in the right quadrants, with no other associated symptoms.

She had been started on perindopril plus indapamide 72 h before the admission for arterial hypertension. There was no other relevant background.

Physical examination suggested peritoneal irritation on the lower quadrants of the abdomen and right flank.

Laboratory tests were relevant for mild leukocytosis. Abdomen ultrasound and contrast-enhanced computed tomography scan showed moderate amount of fluid in the pelvic excavation and small intestine wall thickening. She was admitted for observation. Once the hypothesis of intestinal angioedema was admitted, angiotensin converting enzyme inhibitor was withheld and no other-directed therapy was instituted. Within 24 h she showed clinical, analytic and imaging improvement, thus supporting this diagnosis.

Conclusion: The diagnosis of intestinal angioedema induced by angiotensin converting enzyme inhibitor can be challenging and time consuming due to its rarity and nonspecific symptoms, which may lead to underdiagnosis of this entity.

© 2015 Sociedade Portuguesa de Gastreenterologia. Published by Elsevier España, S.L.U. This is an open access article under the CC BY-NC-ND license (<http://creativecommons.org/licenses/by-nc-nd/4.0/>).

* Corresponding author.

E-mail address: beatriz.frutuoso@chvng.min-saude.pt (B. Frutuoso).

PALAVRAS-CHAVE

Angioedema;
Inibidor da Enzima de
Conversão da
Angiotensina/efeitos
adversos;
Doenças Intestinais

Angioedema Visceral Induzido por Inibidor da Enzima de Conversão da Angiotensina: Caso Clínico**Resumo**

Introdução: O angioedema intestinal é um efeito adverso raro dos inibidores da enzima de conversão da angiotensina.

Caso clínico: Sexo feminino, 42 anos, recorreu ao Serviço de Urgência por dor abdominal difusa predominante nos quadrantes direitos, sem outra sintomatologia. Tinha iniciado perindopril e indapamida 72 horas antes por hipertensão arterial. Sem outros antecedentes de relevo. Ao exame objetivo salientava-se apenas sinais de irritação peritoneal à palpação da fossa ilíaca e flanco direitos. Analiticamente evidenciava discreta leucocitose, sem outras alterações. A ecografia e tomografia computadorizada contrastada abdominal revelaram líquido moderado na escavação pélvica e espessamento das paredes do delgado. Foi internada para vigilância. Admitindo-se angioedema intestinal, o inibidor da enzima de conversão da angiotensina foi suspenso e não foi instituída qualquer outra terapêutica dirigida. Em 24 horas, verificou-se melhora clínica, analítica e imagiológica, corroborando a hipótese de diagnóstico.

Conclusão: O diagnóstico de angioedema intestinal por inibidor da enzima de conversão da angiotensina é, por vezes, difícil e moroso pela sua raridade e inespecificidade dos sintomas, podendo conduzir ao subdiagnóstico desta entidade.

© 2015 Sociedade Portuguesa de Gastrenterologia. Publicado por Elsevier España, S.L.U. Este é um artigo Open Access sob a licença de CC BY-NC-ND (<http://creativecommons.org/licenses/by-nc-nd/4.0/>).

1. Introduction

Angiotensin converting enzyme (ACE) inhibitors are widely used in clinical practice. Angioedema is a rare adverse reaction, occurring in approximately 0.1–0.7% of patients.¹ Although the risk to an individual is relatively low, the large number of people taking these medications, calculated in more than 40 million patients in the United States, means the absolute number of ACE inhibitor induced angioedema is, in fact, significant.¹ Most of the cases described in literature refer to angioedema of the lips, tongue, face, or airway.¹ More rarely, visceral involvement may occur, especially in the jejunum.^{1–3} The exact incidence of visceral angioedema induced by ACE inhibitor is unknown and this condition is probably underdiagnosed.^{1,4–7} In a literature review from 1980 to 2010, Korniyenko et al reported 27 published cases.³

The authors present a case of intestinal angioedema induced by ACE inhibitor.

2. Clinical case

A 42-year old caucasian woman presented to the Emergency Department complaining of diffuse abdominal pain, predominantly in the right quadrants, for the last 10h. She was previously asymptomatic and, at admission, did not have any other symptoms, including nausea, vomiting, diarrhea or any other gastrointestinal symptom, breathing difficulty, cough, rash or pruritus.

She had been started on perindopril plus indapamide 72 h before the admission for arterial hypertension, with no other relevant background.

At admission, significant findings on physical exam included an arterial pressure of 112/72 mmHg, pulse of

61 per minute, peripheral oxygen saturation of 100% on room air and tympanic temperature of 37 °C. There was no swelling of the face, oral cavity or tongue, dyspnea or stridor. Abdominal examination showed signs of peritoneal irritation on lower quadrants of the abdomen and right flank.

Laboratory tests were relevant for mild leukocytosis with high neutrophil count (12.910 leukocyte/ μ L, 79.2% of neutrophil). The remaining analysis, including liver enzymes were within the normal range – aminotransferase aspartate: 22 U/L, aminotransferase alanine: 22 U/L (normal 4–33/4–50, respectively), pancreatic amylase: 28 U/L (normal 13–53), lipase: 24 U/L (normal 13–60) or C-reactive protein: 0.35 mg/dL (normal <0.5). Abdominal ultrasound revealed thickening of intestinal wall associated with abdominal fluid. A contrast-enhanced abdominal computed tomography (CT) was done for further characterization (Fig. 1), showing a moderate amount of liquid in the pelvic excavation and wall thickening of small intestine, cecum and ascending colon.

She was admitted for observation. Once the hypothesis of intestinal angioedema was admitted, ACE inhibitor was withheld. The patient was started on intravenous fluids and analgesics and kept on nothing by mouth status. Within 24h she showed clinical, analytic and imaging improvement, with ultrasound still revealing moderate free fluid, but less expressive wall thickening of the small intestine loops.

The clear improvement in 24h without other treatment besides perindopril withholding, in the scenario of no symptoms or history suggestive of any alternative diagnosis strongly supported ACE inhibitor induced angioedema.

The patient was discharged home, advised not to resume any ACE inhibitors. One year later she remained asymptomatic.

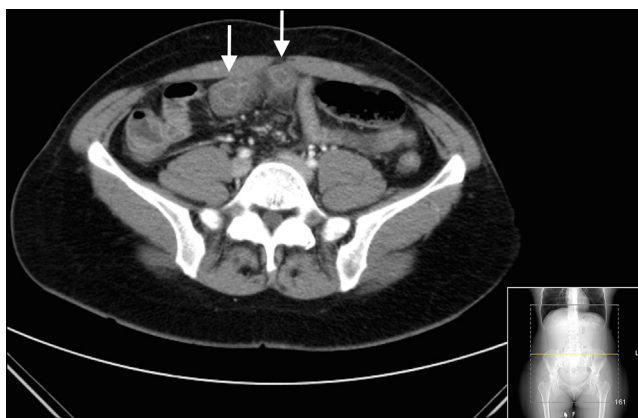


Figure 1 Contrast-enhanced computed tomography demonstrating circumferential transmural thickening of ileum walls, producing a target-like lesion (arrows) that is typical of edema.

3. Discussion

Visceral angioedema induced by ACE inhibitor is a rare, but well-established entity, described in some publications.³

Studies suggest that elevated levels of bradykinin, a vasodilator peptide degraded by angiotensin converting enzyme, result in vasodilation and increased vascular permeability causing the edema.^{1,3,4,8,9}

Female sex appears to have a major predisposition to it and its incidence is five times greater in black people.^{1,4,10}

Jejunum is most often affected followed by ileum and duodenum.¹⁻³ There are reports of gastric involvement.^{3,11}

ACE inhibitor induced angioedema is characterized by the absence of pruriginous rash.^{1,5}

It presents as diffuse abdominal pain, diarrhea, vomiting and anorexia.^{1-3,12} Symptoms usually begin 72 h after starting ACE inhibitor,^{8,13-15} but there are reports of angioedema that developed after weeks^{10,16} or years of therapy.^{2,10,17,18} Typically symptoms resolve 48 h after ACE inhibitor suspension.^{3,4}

The laboratory evaluation is often normal or it may exhibit mild leukocytosis.^{2,3}

Radiologic studies show small intestine wall thickening, mesenteric edema and ascites^{2,3,7,10,13,19-22} that may simulate ischemia or inflammatory bowel disease.^{2,4,19,21,22} Typically, there are target-like images on contrast-enhanced radiologic studies specific of intestinal wall edema, no matter the cause of the edema.^{2,3,19,22}

Oudit et al,⁴ proposed four diagnostic criteria based on the use of ACE inhibitor (regardless of dose and duration of use), nonspecific abdominal complaints in the presence of visceral edema (with or without ascites), resolution of symptoms and radiological changes following discontinuation of ACE inhibitor and lack of alternative diagnoses.

In this report, opposite to other publications, the only complain was abdominal pain, with no additional gastrointestinal symptoms. However, presentation within 72 h after starting perindopril, unspecific laboratory findings, as well as characteristic imaging were suggestive and facilitated the diagnosis of ACE inhibitor angioedema. Furthermore, as there is not a single, definitive diagnostic test it is crucial to rule out other possible diagnoses. In this case, the

clinical history and complementary methods of diagnosis allowed the exclusion of acute hepatitis or pancreatitis, mesenteric ischemia, intestinal obstruction, appendicitis, acute cholecystitis or lymphoproliferative disease. Acute gastroenteritis was very unlikely, given the lack of other symptoms beyond abdominal pain. There was no personal or family history that led into the hypothesis of hereditary C1 esterase inhibitor deficiency, vasculitis or inflammatory bowel disease. Global improvement after suspension of the drug, with no other-directed therapy, supported this hypothesis.

4. Conclusion

Visceral angioedema is a rare, but well-described adverse effect of ACE inhibitor therapy. The diagnosis is often challenging and time consuming, requiring careful evaluation of the patient's medication and their side effects.

Ethical disclosures

Protection of human and animal subjects. The authors declare that no experiments were performed on humans or animals for this study.

Confidentiality of data. The authors declare that they have followed the protocols of their work center on the publication of patient data

Right to privacy and informed consent. The authors have obtained the written informed consent of the patients or subjects mentioned in the article. The corresponding author is in possession of this document.

Funding

The author(s) received no financial support for the research and/or authorship of this article.

Conflicts of interest

The authors declared no conflict of interest with respect to the authorship and/or publication of this article.

References

1. Guyer AC, Banerji A. ACE inhibitor-induced angioedema. UpToDate. 2015.
2. Scheirey CD, Scholz FJ, Shortsleeve MJ, Katz DS. Angiotensin-converting enzyme inhibitor-induced small-bowel angioedema: clinical and imaging findings in 20 patients. *Am J Roentgenol.* 2011;197:393-8.
3. Korniyenko A, Alviar CL, Cordova JP, Messerli FH. Visceral angioedema due to angiotensin-converting enzyme inhibitor therapy. *Cleveland Clin J Med.* 2011;78:297-304.
4. Oudit G, Girgrah N, Allard J. ACE inhibitor-induced angioedema of the intestine: case report, incidence, pathophysiology, diagnosis and management. *Can J Gastroenterol.* 2001;15:827-32.
5. Campbell T, Peckler B, Hackstadt RD, Payor A. ACE inhibitor-induced angioedema of the bowel. *Case Rep Med.* 2010;2010:690-5.

6. Augenstein VA, Heniford BT, Sing RF. Intestinal angioedema induced by angiotensin-converting enzyme inhibitors: an under-recognized cause of abdominal pain? *J Am Osteopat Assoc.* 2013;113:221–3.
7. Marmery H, Mirvis SE. Angiotensin-converting enzyme inhibitor-induced visceral angioedema. *Clin Radiol.* 2006;61:979–82.
8. De Graaf LC, vans Essen M, Schipper EM, Boom H, Duschek EJ. Unnecessary surgery for acute abdomen secondary to angiotensin-converting enzyme inhibitor to angiotensin-converting enzyme inhibitor use. *Am J Emerg Med.* 2012;30:1607–12.
9. Thalanayar PM, Ghobrial I, Lubin F, Karnik R, Bhasin R. Drug-induced visceral angioedema. *J Commun Hosp Intern Med Perspect.* 2014;4:25260.
10. Benson BC, Smith C, Laczek JT. Angiotensin converting enzyme inhibitor-induced gastrointestinal angioedema: a case series and literature review. *J Clin Gastroenterol.* 2013;47:844–9.
11. Shahzad G, Korsten MA, Blatt C, Motwani P. Angiotensin-converting enzyme (ACE) inhibitor-associated angioedema of the stomach and small intestine: a case report. *Mt Sinai J Med.* 2006;73:1123–5.
12. Chase MP, Fiarman GS, Scholz FJ, MacDermott RP. Angioedema of the small bowel due to an angiotensin-converting enzyme inhibitor. *J Clin Gastroenterol.* 2000;31:254–7.
13. Gonçalves BM, Caetano AC, Ferreira A. A rare cause of abdominal pain. *Gastroenterology.* 2013;145:e11–2.
14. Shahani L. ACE inhibitor-induced intestinal angio-oedema: rare adverse effect of a common drug. *BMJ Case Rep.* 2013;2013, pii:bcr2013200171.
15. Byrne TJ, Douglas DD, Landis ME, Heppell JP. Isolated visceral angioedema: an underdiagnosed complication of ACE inhibitors? *Mayo Clin Proc.* 2000;75:1201–4.
16. Spahn TW, Grosse-Thie W, Mueller MK. Endoscopic visualization of angiotensin-converting enzyme inhibitor-induced small bowel angioedema as a cause of relapsing abdominal pain using double-balloon enteroscopy. *Dig Dis Sci.* 2008;53:1257–60.
17. Chuah H, O'Donnell D. Angiotensin-converting enzyme inhibitor and visceral angio-oedema. *Emerg Med Australas.* 2012;24:207–8.
18. Haines EC, Wall GC. Possible angiotensin-converting enzyme inhibitor (ACEI)-induced small bowel angioedema. *J Pharm Pract.* 2011;24:564–7.
19. Coelho ML, Amaral R, Curvo-Semedo L, Caseiro-Alves F. Small bowel angioedema induced by angiotensin converting enzyme (ACE) inhibitor: US and CT findings. *JBR-BTR.* 2014;97:239–41.
20. Hachem CY, Balci NC, Desai D. Recurrent nausea: vomiting, and abdominal pain. *Gastroenterology.* 2010;138:e1–2.
21. Aggarwal A, Mehta N, Shah SN. Small bowel angioedema associated with angiotensin converting enzyme inhibitor use. *J Gen Intern Med.* 2010;26:446–7.
22. Vallurupalli K, Coakley KJ. MDCT features of angiotensin-converting enzyme inhibitor-induced visceral angioedema. *Am J Roentgenol.* 2011;196:w405–11.