

# SUBACUTE THYROIDITIS FOLLOWING INFLUENZA VACCINE (VAXIGRIP<sup>®</sup>) IN A YOUNG FEMALE

Jeng-Yueh Hsiao, Shih-Chieh Hsin, Ming-Chia Hsieh, Pi-Jung Hsia, and Shyi-Jang Shin

Department of Endocrinology and Metabolism, Kaohsiung Medical University Chung-Ho Memorial Hospital, Kaohsiung Medical University, Kaohsiung, Taiwan.

Subacute thyroiditis (SAT), also called de Quervain thyroiditis or granulomatous thyroiditis, is a self-limiting, possibly viral, and inflammatory thyroid disorder that is usually associated with thyroid pain and systemic symptoms. This report details a case of SAT possibly associated with influenza vaccine (Vaxigrip<sup>®</sup>) in a young female. The diagnosis, therapeutic management and outcome are discussed.

**Key Words:** subacute thyroiditis, de Quervain thyroiditis, influenza vaccine  
(*Kaohsiung J Med Sci* 2006;22:297–300)

Subacute thyroiditis (SAT) is a self-limiting thyroid disease associated with a triphasic clinical course of hyperthyroidism, hypothyroidism, and return to normal thyroid function. The well-known clinical features of SAT include thyroid pain with symptoms of hyperthyroidism, suppressed level of thyroid-stimulating hormone (TSH), low thyroid uptake of radioactive iodine, and elevated erythrocyte sedimentation rate [1,2]. Diagnosis is based on clinical and laboratory data, and tissue diagnosis is rarely required [1,3,4]. We present the case of a 25-year-old female with sudden onset of neck pain on the left side and swelling 2 days after she received an influenza vaccine injection of Vaxigrip<sup>®</sup>. Tracing back her history, she had experienced the same symptoms when she was 12 years old and recovered spontaneously. Therefore, we strongly suspected that SAT was possibly associated with influenza vaccine (Vaxigrip<sup>®</sup>) in this case.

## CASE REPORT

A 25-year-old female suffering from fever, left neck swelling, and tender bulging mass for 3 days visited our clinic. Her body temperature ranged from 37 to 39°C. There were no chills, sore throat, cough, shortness of breath or chest pain, and no genitourinary symptoms. Two days before this episode of fever and subsequent development of a small, tender bulging neck mass, which progressively enlarged, she had received influenza vaccine (Vaxigrip<sup>®</sup>). Tracing back her history, at 12 years of age, she had experienced a similar episode from which she recovered spontaneously, but she had not received any vaccination at that time.

On physical examination, her body temperature was 38°C, pulse rate was 90 bpm, respiratory rate was 15 breaths/min, and blood pressure was 110/70 mmHg. Her sclera was anicteric, pharynx was noninjected, and neck was supple. There was no cervical lymphadenopathy. Heart sounds were regular without murmurs, rubs or gallops. Her breathing sounds were clear. There was no skin rash and neurologic examination results were normal. A chest radiograph showed normal results.

Routine laboratory tests were unremarkable except for an erythrocyte sedimentation rate of 53 mm/hour (normal, 0–10 mm/hour). The leukocyte count was 9,790/ $\mu$ L (normal,

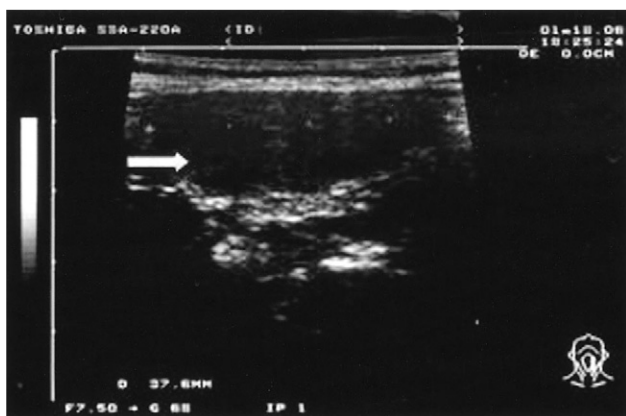
Received: August 10, 2005

Accepted: February 9, 2006

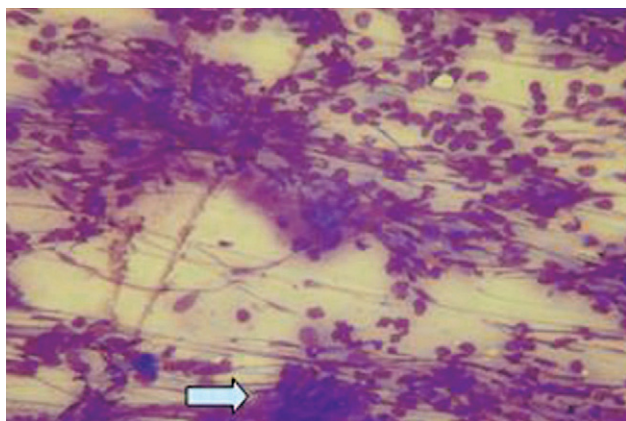
Address correspondence and reprint requests to: Dr Shyi-Jang Shin, Department of Endocrinology and Metabolism, Kaohsiung Medical University Chung-Ho Memorial Hospital, 100 Tzyou 1<sup>st</sup> Road, Kaohsiung 807, Taiwan.

E-mail: sjshin@kmu.edu.tw

4,000–11,000/ $\mu\text{L}$ ) and C-reactive protein level was 14  $\mu\text{g}/\text{mL}$  (normal, < 5  $\mu\text{g}/\text{mL}$ ). Urinalysis showed normal results. Blood culture results were negative. Thyroid function test results were normal (total T4, 8.2  $\mu\text{g}/\text{dL}$ ; total T3, 85 ng/dL; TSH, 1.0  $\mu\text{U}/\text{mL}$ ). Microsomal and thyroglobulin antibody test results were negative. Thyroid echocardiography showed a hypoechoic area over the left lobe (Figure 1). Multinuclear giant cell granulomas were observed in a fine-needle aspiration biopsy of the thyroid (Figure 2). The patient became afebrile during the next week, while receiving nonsteroidal anti-inflammatory drugs and steroids and recovered 2 weeks later. The tender neck mass also disappeared. According to the clinical manifestations, SAT was diagnosed. Since there was no viral infection prior to this episode and fever had occurred just after influenza vaccination, we suspected that this episode of SAT was associated with the administration of influenza vaccine.



**Figure 1.** Thyroid ultrasonography showed a hypoechoic area over the left lobe of the thyroid gland (arrow).



**Figure 2.** Subacute thyroiditis: multinuclear giant cell granulomas were observed in a fine-needle aspiration biopsy of the thyroid (arrow) (Liu stain, 100 $\times$ ).

## DISCUSSION

SAT has been termed granulomatous giant cell or de Quervain's thyroiditis. It is characterized by a generally self-limiting, usually painful inflammatory lesion of the thyroid gland, most probably of viral origin [5]. Many viruses have been implicated, including mumps, Coxsackie, influenza, adenoviruses, and echoviruses [6–8]. All current evidence indicate that SAT is not an autoimmune disease. The peak incidence occurs at 30–50 years of age, and women are affected thrice more frequently than men [3,9].

SAT begins with a prodrome of generalized myalgias, pharyngitis, low-grade fever and fatigue. Patients then present with fever and severe neck pain, swelling, or both. Painful SAT, which is a self-limiting inflammatory disorder, is the most common cause of thyroid pain [10]. A viral cause of SAT has, therefore, been proposed, but clear evidence is still lacking [7].

The hallmark of painful SAT is a markedly elevated erythrocyte sedimentation rate. C-reactive protein concentration is similarly elevated [11]. Color-flow Doppler ultrasonography may also help to make this distinction; in patients with Graves' disease, the thyroid gland is hypervascular, whereas in patients with painful SAT, the gland is hypoechoic and has low-to-normal vascularity [12]. The treatment for painful SAT is to provide symptomatic relief only. Nonsteroidal medications or salicylates are adequate to control mild thyroid pain; high doses of glucocorticoids (e.g. 40 mg/day prednisone) provide immediate relief. The doses of steroid should be tapered over a period of 4–6 weeks [13].

SAT, which is considered to be a viral disease [6–8], rarely recurs after a complete recovery, possibly because of immunity to the offending virus. However, late recurrence after several years has been reported [14–17]. The recurrent episodes were similar to the first episode of SAT. The titers of various viral antibodies were not increased during the clinical course of recurrence [17].

If vaccination is performed with heterologous antigens that are sufficiently different to permit an immunologic response, but are sufficiently similar to react with autologous antigens, then the vaccinated antigen may induce various immune response and systemic symptoms such as fever and myalgia. We report in this case that SAT occurred just after influenza vaccination and without a recent episode of viral infection before SAT. The patient had experienced a similar episode of fever and tender neck mass at 12 years of age, so SAT could be a possible diagnosis for that episode.

The recurrent episode is thought possibly to have been induced by the influenza vaccine injection due to delayed hypersensitivity reactions with sensitized lymphoid cells.

The side effects of and adverse reactions to influenza vaccine (Vaxigrip®) [18,19] that occurred during clinical trials were erythema, redness, swelling, pain, ecchymosis and induration. The most frequent side effect of vaccination is soreness at the vaccination site (affecting 10–64% patients) that lasts < 2 days. Systemic reactions included fever, malaise, myalgia, headache, shivering, sweating, muscular pain and joint pain. These reactions begin 6–12 hours after vaccination and can persist for 1–2 days. No clinical case report to date has demonstrated an association between SAT and influenza vaccination.

In the Minnesota cohort study [20], the inclusion criteria for diagnosis of SAT were any one of the following: (1) painful thyroid and either suppressed uptake of <sup>131</sup>I or elevated erythrocyte sedimentation rate, or both; (2) unilateral thyroid pain with abnormally low uptake of <sup>131</sup>I and elevated erythrocyte sedimentation rate; and (3) pathologic diagnosis (surgical specimen or biopsy). In our case, the patient presented with fever, left neck swelling, and tender bulging mass. In addition, markedly elevated erythrocyte sedimentation rate was observed. These findings were consistent with a diagnosis of SAT. As there was no evidence of recent bacterial or viral infection prior to this episode and because fever had occurred just after influenza vaccination, we highly suspected this episode of SAT to be directly associated with the influenza vaccine or that the recurrence was aggravated by influenza vaccination, but more precise methods are required to determine this possibility.

This case was a rare clinical case. Other researchers [21, 22] compiled and analyzed safety data on the inactivated split influenza vaccine, Vaxigrip®, from 28 clinical trials (total: 4,599 subjects aged 6 months to 99 years) to provide a robust estimate of the reactogenicity profile. The most frequent solicited reactions were nonsevere injection site pain and erythema in children, adults and the elderly. Mild or moderate fever was the most frequent reaction among 6- to 36-month-old individuals; few systemic reactions were reported in older groups. Reactogenicity was comparable in healthy and high-risk children. The long-term experience with the world's most widely used influenza vaccine, Vaxigrip®, confirms its excellent tolerability, and its continued use in clinical practice worldwide is supported.

## REFERENCES

- Intenzo CM, Park CH, Kim SM, et al. Clinical laboratory and scintigraphic manifestation of subacute and chronic thyroiditis. *Clin Nucl Med* 1993;18:302–6.
- Singer PA. Thyroiditis: acute, subacute, and chronic. *Med Clin North Am* 1991;75:61–77.
- Volpe R. Subacute thyroiditis. *Prog Clin Biol Res* 1981;74:115–34.
- Slatosky J, Shipton B, Wahba H. Thyroiditis: differential diagnosis and management. *Am Fam Physician* 2000;61:1047–52, 1054.
- Burke A, Marjorie T. Fever of unknown origin: subacute thyroiditis versus typhoid fever. *Heart Lung* 2005;34:147–51.
- Brouqui P, Raoult D, Conte-Devolx B. Coxsackie thyroiditis. *Ann Intern Med* 1991;114:1063–4.
- Volpe R, Row VV, Ezrin C. Circulating viral and thyroid antibodies in subacute thyroiditis. *J Clin Endocrinol Metab* 1967;27:1275–84.
- Sato M. Virus-like particles in the follicular epithelium of the thyroid from a patient with subacute thyroiditis. *Acta Pathol Jpn* 1975;25:499–501.
- Pearce EN, Farwell AP, Braverman LE. Thyroiditis. *N Engl J Med* 2003;348:2646–55.
- Greene JN. Subacute thyroiditis. *Am J Med* 1971;51:97–108.
- Pearce EN, Martino E, Bogazzi F. The prevalence of elevated serum C-reactive protein levels in inflammatory and noninflammatory thyroid disease. *Thyroid* 2003;13:643–8.
- Hiromatsu Y, Ishibashi M, Miyake I. Color Doppler ultrasonography in patients with subacute thyroiditis. *Thyroid* 1999;9:1189–93.
- Mizukoshi T, Noguchi S, Murakami T, et al. Evaluation of recurrence in 36 subacute thyroiditis patients managed with prednisolone. *Intern Med* 2001;40:292–5.
- Tauveron I, Thieblot P, Marcheix JC. Recurrence after 12 years of de Quervain–Crile subacute thyroiditis. *Rev Med Interne* 1991;12:396. [In French]
- Bauman A, Friedman A. Recurrence subacute thyroiditis: a report of three cases. *NY State J Med* 1983;83:987–8.
- Iitaka M, Momotani N, Ishii J, et al. Incidence of subacute thyroiditis recurrences after a prolonged latency: 24-year survey. *J Clin Endocrinol Metab* 1996;81:466–9.
- Yamamoto M, Saito S, Sakurada T, et al. Recurrence of subacute thyroiditis over 10 years after the first attack in three cases. *Endocrinol Jpn* 1988;35:833–9.
- Odelin MF, Pozzetto B. Tolerance of influenza vaccination in the aged and the nursing staff in a geriatric hospital. *Therapie* 1994;49:447–50.
- Proctor GD. “Vaxigrip” influenza vaccine. *Med J Aust* 1984; 141:136.
- Vahab F. Clinical features and outcome of subacute thyroiditis in an incidence cohort: Olmsted County, Minnesota, Study. *J Clin Endocrinol Metab* 2003;188:2100–5.
- Spila-Alegiani S, Salmaso S, Rota MC, et al. Reactogenicity in the elderly of nine commercial influenza vaccines: results from the Italian SVEVA study. Study for the evaluation of adverse events of influenza vaccination. *Vaccine* 1999;17(15–16):1898–904.
- Delore V, Salamand C, Marsh G, Arnoux S, Pepin S, Saliou P. Long-term clinical trial safety experience with the inactivated split influenza vaccine, Vaxigrip. *Vaccine* 2006;24:1586–92.

# 接種流行性感冒疫苗之後引發 亞急性甲狀腺炎的一位成人病例報告

蕭政岳 辛世杰 謝明家 蕭璧容 辛錫璋

高雄醫學大學附設中和紀念醫院 內分泌暨新陳代謝內科

亞急性甲狀腺炎（又稱為 *de Quervain* 甲狀腺炎或肉芽性甲狀腺炎）是一種會自癒的病毒性或發炎性甲狀腺疾病，通常會以甲狀腺疼痛和全身性症狀來表現。這病例報告是描述一位年輕女性的亞急性甲狀腺炎可能與注射流行性感冒疫苗有關，這病例的診斷，治療處理和結果將被討論。

**關鍵詞：**亞急性甲狀腺炎，*de Quervain* 甲狀腺炎，流行性感冒疫苗  
(高雄醫誌 2006;22:297-300)

---

收文日期：94 年 8 月 10 日

接受刊載：95 年 2 月 9 日

通訊作者：辛錫璋教授

高雄醫學大學附設中和紀念醫院內分泌暨新陳代謝內科

高雄市自由一路 100 號