

## EDITORIAL COMMENT

## Stiff by Stress

### Operant LV Diastolic Stiffness Assessed With Pre-Load Stress Echocardiography\*

Michael Böhm, MD, Jan-Christian Reil, MD

In this issue of *JACC*, Yamada et al. (1) echocardiographically assessed pre-load stress induced by leg-positive pressure (LPP) to improve risk stratification in 202 consecutive patients with mild heart failure. Patients were classified in groups on the basis of their left ventricular (LV) diastolic dysfunction as characterized by transmitral flow velocity. The authors focused on patients with impaired relaxation (IR) at rest and under LPP (stable IR) and those with IR at rest and pseudonormal flow pattern under LPP (unstable IR). On the basis of pre-load stress, Yamada et al. (1) could identify different operant LV stiffness in both patient groups, but associated with a poor prognosis in patients with unstable IR.

SEE PAGE 641

Diastolic myocardial function consists of 2 main components: active LV relaxation and passive LV chamber stiffness. The gold standard for analyzing myocardial diastolic function is invasive pressure-volume analysis performed by conductance catheter techniques. This approach can accurately assess the end-diastolic pressure-volume relationship (EDPVR) that mainly reflects passive myocardial properties in health and disease (Fig. 1). The measured curve is inherently nonlinear, and the slope of each of its pressure-volume points ( $\Delta$ pressure/ $\Delta$ volume) represents myocardial chamber stiffness (2-4). Chamber stiffness varies with respect to end-diastolic pressure and volume. When acting on the flat part of the curve, a small increase in the left ventricular filling pressure

occurs in response to a significant increase in end-diastolic volume (low operant stiffness) (4). In contrast, when working on the right part of the curve, the LV operates in the steep zone of EDPVR, indicating that small changes in volume are associated with a marked increase in filling pressures (high operant stiffness) (4). When exposed to excessive volume overload, even healthy hearts may have to work on the steep part of EDPVR, thereby developing increased chamber stiffness with reduced pre-load reserve. Consequently, “diastolic impairment” can be induced by volume overload even in the absence of diastolic dysfunction in healthy subjects. Pressure-volume analysis can also distinguish diastolic properties of different heart failure syndromes (Fig. 1A). Patients with heart failure with preserved ejection fraction often show diastolic dysfunction characterized by a leftward shift of EDPVR (low LV capacity: at a given filling pressure, end-diastolic volume is smaller than in control subjects). Patients with heart failure and a reduced ejection fraction usually show a rightward shift in the pressure-volume diagram due to eccentric remodeling (high LV capacity: at a given filling pressure, end-diastolic volume is increased). Patients with heart failure and reduced ejection fraction often also show diastolic dysfunction, especially when working on the stiffer part of EDPVR (2-4). In summary, pathologic hemodynamic features can be analyzed and interpreted in the pressure-volume relation on the basis of LV filling pressure and volume (Fig. 1A).

Because pressure-volume analysis by conductance catheter is too complicated for daily clinical routine, assessment of LV diastolic stiffness remains challenging in clinical practice. The technique of choice is Doppler echocardiography because of its general availability and easy use. The filling index  $E/E'$  correlates well with left ventricular filling pressure (5) but without giving any information on concomitant end-diastolic volume. The same is true for transmitral

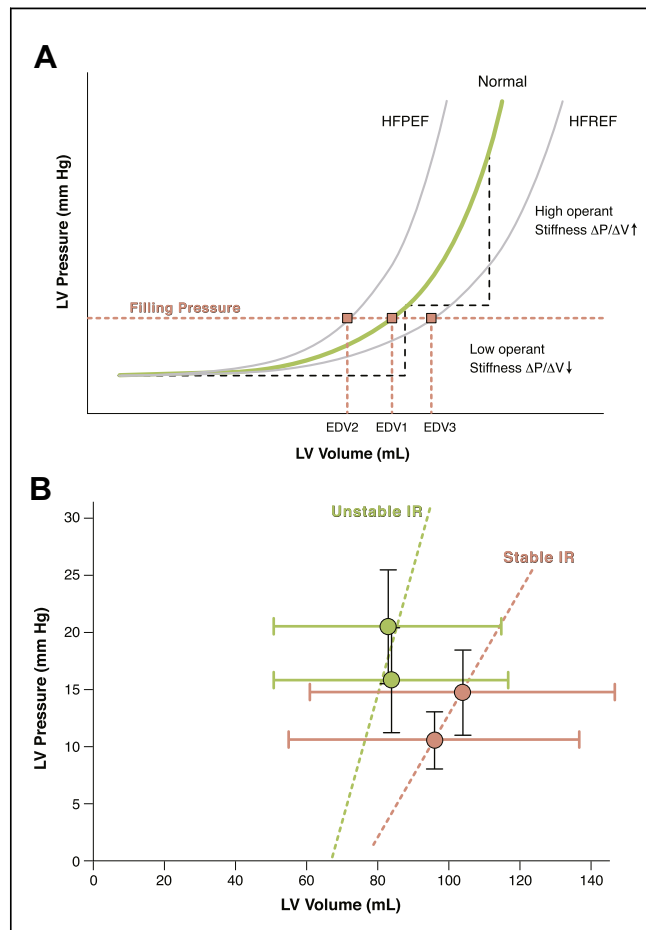
\*Editorials published in *JACC: Cardiovascular Imaging* reflect the views of the authors and do not necessarily represent the views of *JACC: Cardiovascular Imaging* or the American College of Cardiology.

From the Klinik für Innere Medizin III, Kardiologie, Angiologie und Internistische Intensivmedizin, Universitätsklinikum des Saarlandes, Homburg/Saar, Germany. Both authors have reported that they have no relationships relevant to the contents of this paper to disclose.

inflow profile measured by pulsed wave Doppler. Transmittal inflow reflects only the pressure gradient between the left atrium and LV during diastole, thereby characterizing LV filling pressures and LV relaxation (6). With prolonged relaxation, early diastolic filling is decreased, so that ventricular filling is compensated by increased atrial contraction ( $E < A$ , stage I of diastolic dysfunction). With progression of diastolic dysfunction and reduced LV compliance, filling pressure increases with a resultant increase in E-wave ( $E/A > 1$  stage II; pseudonormalization and stage III  $E/A > 2$ ) (2,4). In contrast to pressure-volume analysis, the measured echocardiographic filling parameters without an indication of the corresponding filling volume can neither define the relative position of EDPVR in comparison to that of control nor determine their relative position on EDPVR (Fig. 1A, pink dotted line). Therefore, these described indexes should be considered together with echocardiographic measurements of end-diastolic volume or ventricular size.

Patients with heart failure and Doppler-derived higher grades of diastolic dysfunction (stages II to III) have a poor prognosis (7). However, the relevance of IR transmitral flow pattern ( $E < A$ ) is unclear. The flow pattern can be associated with normal diastolic function in the elderly, showing low left ventricular filling pressure in the absence of heart failure. On the other hand, this flow pattern may indicate clinical diastolic dysfunction leading to an increase in LV filling pressure and heart failure (8). Thus, in elderly patients, an IR transmitral flow pattern has to be evaluated. Therefore, it is important to calculate the operant stiffness of the LV to distinguish both groups, thereby assessing the prognostic value of mild diastolic dysfunction ( $E < A$ ) in patients with heart disease.

To address this problem, pre-load stress echocardiography was performed by Yamada et al. (1) to determine operant stiffness of patients with mild heart failure with reduced or preserved ejection fraction and an  $E/A$  ratio  $< 1$ . A total of 202 patients were included and were divided into patients with  $E < A$  and those with pseudonormal or restrictive filling pattern ( $E > A$ ). The group with an  $E/A$  ratio  $< 1$  was exposed to a pre-load stress test. Pre-load increase was caused by a positive leg pressure (+90 mm Hg) performed by a special leg massage technique. The physical intervention augments venous return with concomitant increase in pre-load, resulting in a rightward shift of LV filling volume on a given EDPVR (Fig. 1A). Patients with low operant stiffness did not show marked changes in Doppler profile after pre-load intervention (stable IR,  $n = 121$ ).



**FIGURE 1** LV Operant Stiffness in Health and Heart Failure

(A) Schematic end-diastolic pressure-volume relationship (EDPVR) of a healthy subject (green curve); patients with heart failure and preserved ejection fraction (HFPEF) usually show a leftward shift in the pressure-volume (PV) diagram, whereas patients with heart failure and reduced ejection fraction (HFREF) display a rightward shift (gray curves). Diastolic stiffness ( $\Delta P/\Delta V$ ) depends on the specific position on EDPVR (low or high operant stiffness). End-diastolic volume (EDV) (pink squares) at a defined filling pressure determines left ventricular (LV) capacity. These parameters (EDV1 to EDV3) characterize different EDPVRs at identical filling pressures (leftward or rightward shift in PV diagram). (B) Reconstruction of LV end-diastolic filling pressure and echocardiography-based end-diastolic volume after pre-load stress test (based on Table 2 in Yamada et al. [1]). Patients with unstable impaired relaxation (IR) ( $n = 6$ ) show a leftward shift in PV diagram with high operant stiffness (low LV capacity, green points), whereas patients with stable IR ( $n = 16$ , pink points) have higher LV capacity with lower operant stiffness. The dotted lines imitate the slope of the corresponding operant LV stiffness in both groups of patients.

These patients work on the flat portion of the EDPVR (low operant stiffness) (Fig. 1A). Patients with high operating stiffness, however, had a changed transmitral flow profile showing pseudonormalization (unstable IR;  $n = 54$ ; high operant stiffness). On the basis of the pre-load stress, the authors could

elegantly identify patients with stable and unstable IR and could additionally demonstrate prediction of different prognostic values after clinical follow-up.

In a small subgroup of patients with stable and unstable IR, invasively assessed filling pressure and echocardiography-based volume measurements were performed to illustrate the hemodynamic changes after pre-load stress (Fig. 1B, reconstructed from Table 2 in Yamada et al. [1]). Patients with unstable IR showed a marked increase of filling pressure with minimal changes in filling volume, indicating high operant stiffness close to pre-load reserve (green points in Fig. 1B). Patients with stable IR, however, showed an appropriate increase in end-diastolic volume and pressure (low operant stiffness) (pink points in Fig. 1B). Single measurements of E/E' would have shown filling pressures in a diagnostic “gray zone” without separating the corresponding patients into 2 distinct prognostic groups (Table 2 in Yamada et al. [1]).

As reported by Yamada et al. (1), patients with stable IR have a better prognosis compared with patients with unstable IR. The latter have a prognosis similar to those patients with a higher degree of diastolic dysfunction. So, it is the merit of the authors (1) to introduce a dynamic pre-load stress test to gain echocardiography-based results of LV filling pressure and volume that may help to unmask patients with mild heart failure and a poorer prognosis. Further studies with more patients—preferably divided into those with heart failure with reduced or preserved ejection fraction—are needed to confirm these promising results.

---

**REPRINT REQUESTS AND CORRESPONDENCE:** Dr. Med. Jan-Christian Reil, Klinik für Innere Medizin III (Kardiologie, Angiologie, Internistische Intensivmedizin), Universitätsklinikum des Saarlandes, Kirrberger Straße, D 66421 Homburg/Saar, Germany. E-mail: [Jan.Reil@uniklinikum-saarland.de](mailto:Jan.Reil@uniklinikum-saarland.de).

---

## REFERENCES

1. Yamada H, Kusunose K, Nishio S, et al. Pre-load stress echocardiography for predicting the prognosis in mild heart failure. *J Am Coll Cardiol Img* 2014;7:641-9.
2. Maurer MS, Spevack D, Burkhoff D, Kronzon I. Diastolic dysfunction. Can it be diagnosed by Doppler echocardiography? *J Am Coll Cardiol* 2004;44:1543-9.
3. Kindermann M, Reil J-C, Pieske B, van Veldhuisen DJ, Böhm M. Heart failure with normal left ventricular ejection fraction: what is the evidence? *Trends Cardiovasc Med* 2008;18:280-92.
4. Borlaug BA. Chapter 92: heart failure with preserved ejection fraction. In: *Mayo Clinic Cardiology Concise Textbook*. 4th edition. New York, NY: Oxford University Press, 2013:850-7.
5. Nagueh SF, Middleton KJ, Kopelen HA, Zoghbi WA, Quiñones MA. Doppler tissue imaging: a noninvasive technique for evaluation of left ventricular relaxation and estimation of filling pressures. *J Am Coll Cardiol* 1997;30:1527-33.
6. Oh JK, Hatle L, Tajik AJ, Little WC. Diastolic heart failure can be diagnosed by comprehensive two-dimensional and Doppler echocardiography. *J Am Coll Cardiol* 2006;47:500-6.
7. Xie GY, Berk MR, Smith MD, Gurley JC, DeMaria AN. Prognostic value of Doppler transmitral flow patterns in patients with congestive heart failure. *J Am Coll Cardiol* 1994;24:132-9.
8. Penicka M, Vanderheyden M, Bartunek J. Diagnosis of heart failure with preserved ejection fraction: role of clinical Doppler echocardiography. *Heart* 2014;100:68-76.

---

**KEY WORDS** Doppler echocardiography, heart failure, leg-positive pressure, stress echocardiography, survival