

iFORUM

DEBATES IN IMAGING

Optimal Imaging for Guiding TAVR: Transesophageal or Transthoracic Echocardiography, or Just Fluoroscopy?



Itzhak Kronzon, MD, Vladimir Jelnin, MD, Carlos E. Ruiz, MD, PhD, Muhamed Saric, MD, PhD, Mathew Russell Williams, MD, Albert M. Kasel, MD, Anupama Shivaraju, MD, Antonio Colombo, MD, Adnan Kastrati, MD
Section Editor: Partho P. Sengupta, MD

THE FOLLOWING iFORUM DEBATE FEATURES 3 VIEWPOINTS related to the most practical and effective imaging strategy for guiding transcatheter aortic valve replacement (TAVR). Kronzon, et al. provide evidence that enhanced analysis of aortic valve anatomy and improved appreciation of complications mandate the use of transesophageal echocardiography as front-line imaging modality for ALL patients undergoing TAVR. On the other hand, Saric and colleagues compare and contrast the approach of performing TAVR under transthoracic guidance. Lastly, Kasel and co-workers provide preliminary evidence that TAVR could be performed under fluoroscopic guidance without the need for additional imaging technique. Although the use of less-intensive sedation or anesthesia might reduce the procedural time, we need more randomized data to establish the most cost-effective approach in guiding TAVR.

TEE for TAVR Guidance

Itzhak Kronzon, MD, Vladimir Jelnin, MD,
Carlos E. Ruiz, MD, PhD

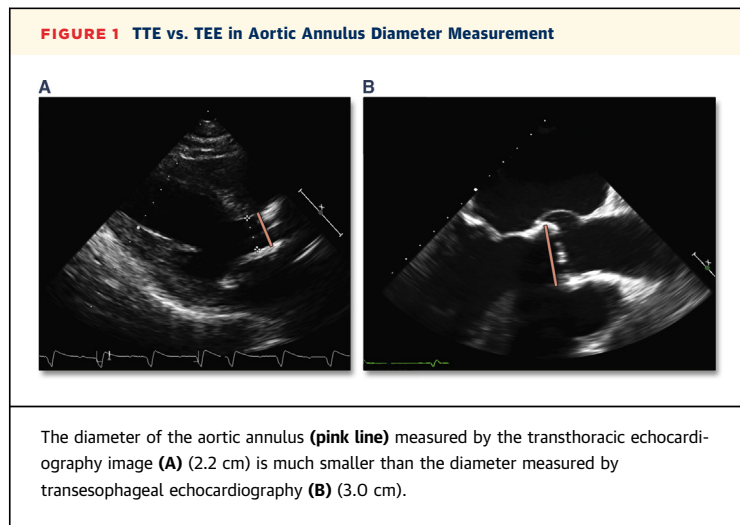
Surgical aortic valve replacement (SAVR) is considered the treatment of choice in symptomatic patients with severe aortic stenosis. However, one-third of these patients are denied surgery because of advanced age, frailty, comorbidities, and conditions known to increase the risk of this major cardiac surgery.

Transcatheter aortic valve replacement (TAVR) offers many of these patients another less traumatic option that does not require thoracotomy and cardiopulmonary bypass. When surgery is considered contraindicated, the outcome of patients who had undergone TAVR was better than in patients who

were treated medically (without valve replacement). In addition, high-risk patients randomized to TAVR had outcomes similar to those of high-risk patients randomized to SAVR (1).

TAVR is usually performed with the support of various cardiac imaging modalities. Fluoroscopy is almost always used and is frequently used along with coronary angiography and aortography. Pre-procedural transthoracic Doppler echocardiography is almost always used to establish the diagnosis of severe aortic stenosis. It is also used sometimes to assess, guide, and monitor the TAVR procedure.

Other modalities frequently used include transesophageal echocardiography (TEE), and multi-detector computed tomography. Transthoracic echocardiography (TTE) is suboptimal in many patients. It is especially difficult in patients in the supine



position (as is the case during TAVR) and in patients with emphysema, chest wall incisions, and deformities.

In many laboratories, TEE is considered the “bread and butter” modality of imaging during TAVR. The higher spatial resolution produces image quality that is far superior to that of images obtained by TTE. This includes improved analysis of aortic valve anatomy such as the bicuspid valve and better identification of intracardiac masses (2).

Aortic plaques can be seen on TEE (and only rarely on TTE). Their identification is important because large, mobile aortic debris may be a contraindication to catheter manipulation at their site.

With surgical findings as the gold standard, measurements obtained by TEE are significantly more accurate than those obtained by TTE (3). This accuracy is extremely important in the definition of the aortic annulus dimensions. Inaccurate evaluation of the annulus size may lead to serious complications. Oversizing of the annulus may result in the selection of valves of larger dimensions and may lead to annulus rupture. Undersizing may lead to device migration, paravalvular leak, and valve embolization (Figure 1) (4).

After TAVR is performed, it is important to evaluate the presence of aortic regurgitation because residual aortic regurgitation (especially more than 1+) is associated with a worse outcome (5). In addition to the severity, it is also important to determine whether the aortic regurgitation is a paravalvular leak or through the prosthetic valve leaflets. These 2 conditions may be handled differently. The site and details of aortic insufficiency cannot be accurately identified by fluoroscopy with contrast injection or

by TTE. Aortic insufficiency can be much better assessed by TEE.

TEE is also useful in the evaluation of post-procedure complications. Such complications include wall motion abnormalities due to coronary occlusion, cardiac tamponade due to right ventricular laceration by the pacing wire, aortic laceration, dissection, or intramural hematoma, some of which cannot be seen with TTE.

Although 3-dimensional (3D) TTE is feasible and available, its images are suboptimal. Accurate assessment of the cumbersome 3D shape of the left ventricular outflow tract-aortic root-aortic valve complex is frequently not of diagnostic quality. On the other hand, 3D TEE, now available with most modern echocardiographic equipment, enables the imager to reconstruct all the aortic valve components, with accurate measurement of the aortic annulus that is as accurate as that with contrast multidetector computed tomography, now considered by many to be the gold standard for determining annulus size (Figure 2). 3D TEE is also useful in the evaluation of the distance between the aortic annulus and the coronary ostia (especially the ostium of the left main coronary artery). The short distance between the annulus and the ostium or a long, bulky left coronary cusp may result in ostial occlusion and acute left ventricular ischemic insult (6).

3D TEE is also capable of showing the location of the catheter tip and of the longer intracardiac portion of the catheter (7).

3D TEE is now a part of the new, now commercially available, image fusion software and hardware. This equipment (Echonavigator, Philips Healthcare, Best, the Netherlands) is capable of superimposing the real-time 2-dimensional or 3D transesophageal echocardiographic images on real-time fluoroscopic images (Figures 3 and 4).

After registration, scale adjustment, and landmark positioning, this fusion technology allows better understanding of the anatomy (such as the location of the aortic annulus on the fluoroscopy screen, guiding catheters and devices, and post-deployment evaluation. This field is rapidly developing, improving, and constantly changing (8). It appears that fusion imaging may lead to shorter and safer transcatheter procedures, including TAVR.

In conclusion, TEE is the guiding technique of choice for TAVR. Although still requiring sedation or even general anesthesia, it provides real-time high-quality images and accurate measurements that result in better pre-procedural assessment, procedural guidance, and post-procedural monitoring of procedure results and possible complications.

Transthoracic Echocardiography for TAVR

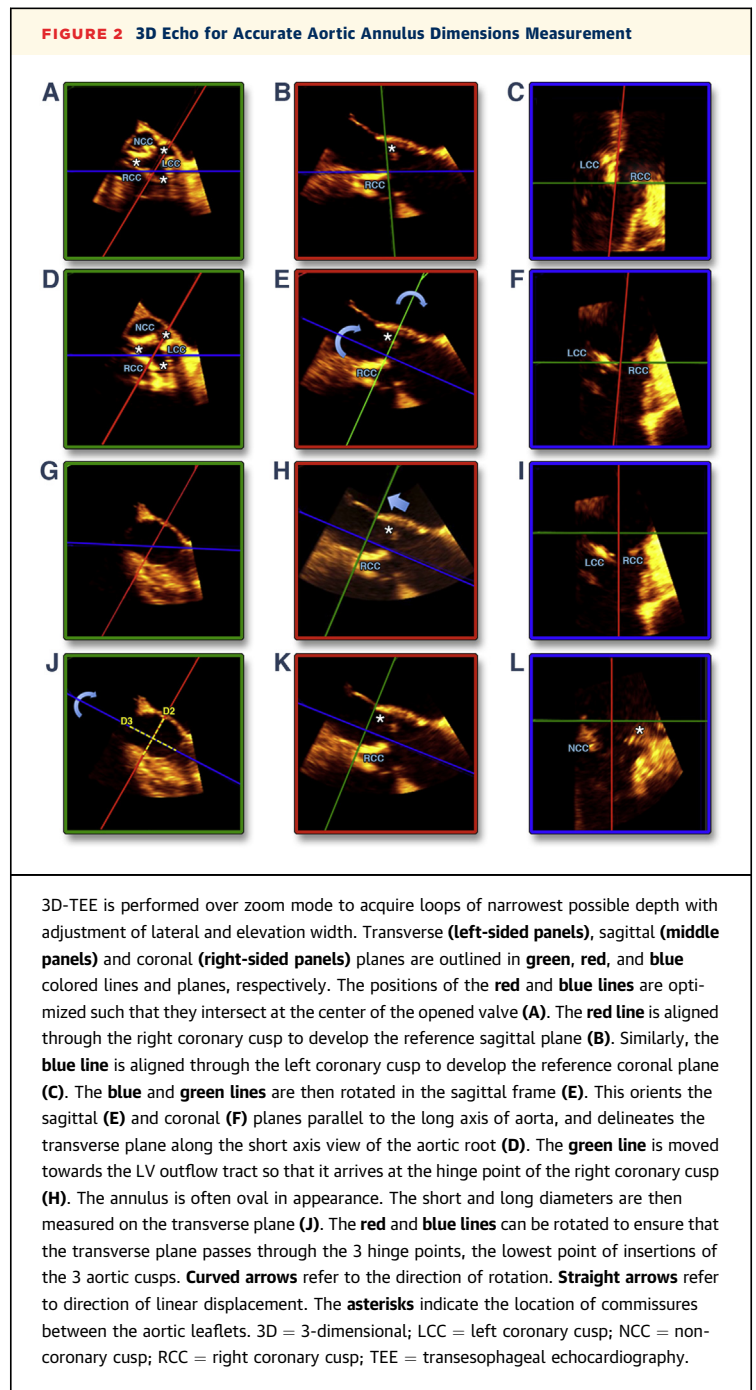
Muhammed Saric, MD, PhD, Mathew Russell Williams, MD

Transcatheter aortic valve replacement (TAVR) procedure requires the coordinated effort and expertise of the entire TAVR team, including interventionalists, anesthesiologists, and imaging specialists. At any TAVR stage, the choice of a periprocedural imaging technique (transthoracic vs. transesophageal echocardiography, fluoroscopy, computed tomography, and so on) should not be governed by the technique's inherent imaging strengths alone, but rather whether such an imaging technique provides a proper balance of diagnostic utility and safety in the larger context of a TAVR procedure.

Since the first human TAVR in France by Alain Cribier and colleagues (9) in 2002, echocardiography has played 3 important roles: 1) identification of appropriate candidates for TAVR; 2) intraprocedural guidance; and 3) assessment of post-procedural success. In the initial TAVR experience, a dichotomous pattern of echocardiographic evaluation was developed: a pre-procedural use of transthoracic echocardiography (TTE), and an intraprocedural use transesophageal echocardiography (TEE) in conjunction with general anesthesia (GA).

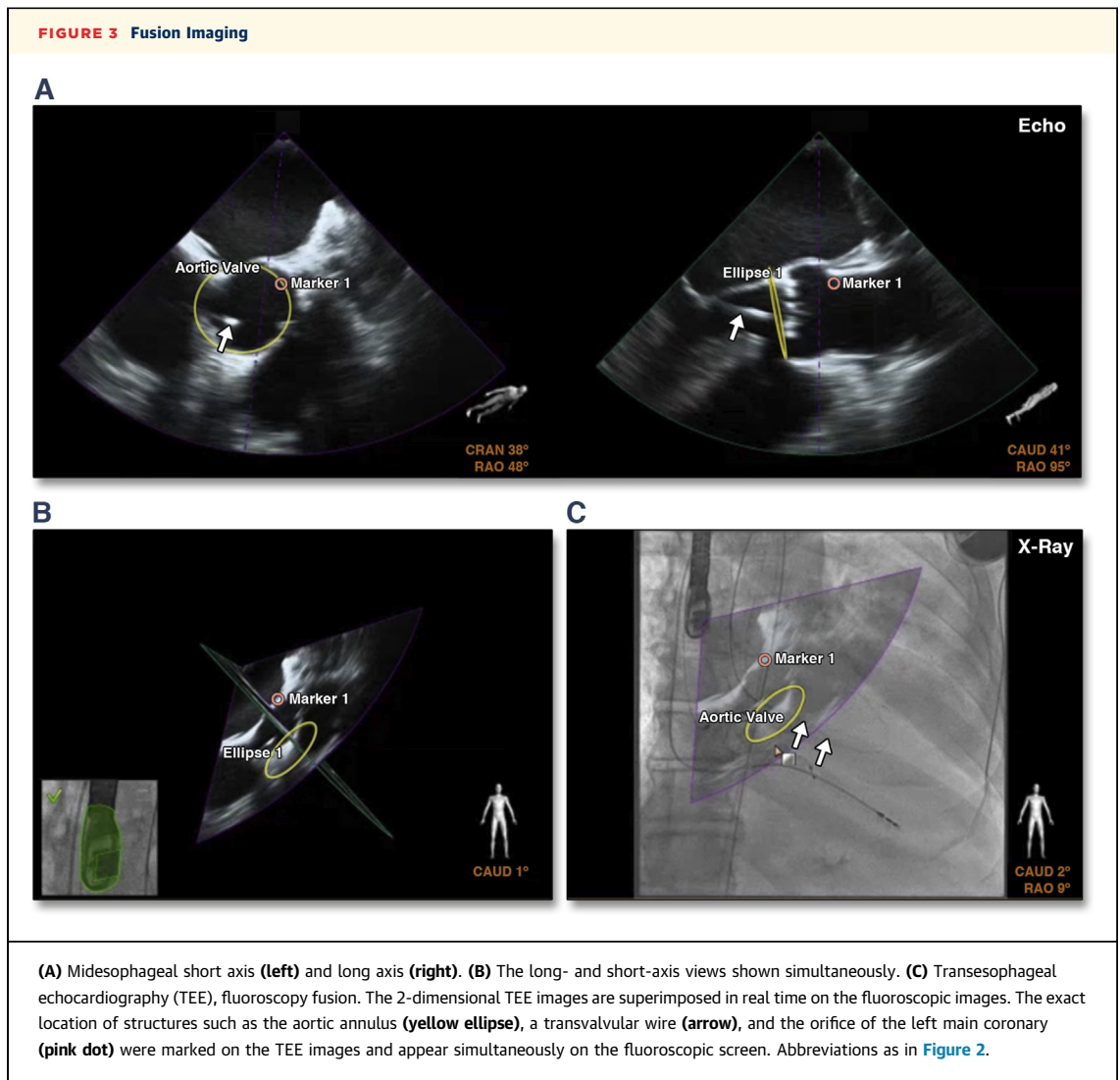
More recently, GA is being replaced with less invasive forms of anesthesia—collectively referred to as monitored anesthesia care (MOC)—which typically consists of intravenous injection of propofol or dexmedetomidine for sedation, and opioids for analgesia. MOC has been shown, for instance, in a meta-analysis of 1,542 TAVR patients enrolled in nonrandomized trials to provide anesthesia care that is noninferior to GA and may be associated with reduced procedural time and shorter hospital stay (10). Because MOC typically precludes TEE, the question arises whether TTE can replace TEE for intraprocedural guidance of TAVR. In this review, we argue that TTE in appropriate patients can provide diagnostic echocardiographic imaging before, during, and after TAVR. Relative advantages and disadvantages of TTE versus TEE in TAVR guidance are summarized in Table 1.

TTE FOR PRE-PROCEDURAL TAVR PLANNING. Pre-procedural evaluation includes establishing the diagnosis of severe aortic stenosis; characterization of the left ventricular outflow tract (LVOT) and aortic root anatomy; and assessment of all other cardiac parameters that might impact TAVR, such as left ventricular function, concomitant valvular lesions, and intracardiac pressures. All recent guidelines



stipulate that 2-dimensional (2D) and Doppler TTE are the principle means of establishing the presence, severity, and etiology of aortic stenosis, assessing its impact on cardiac anatomy and function, and determining prognosis and timing of valve intervention (11).

TTE can also provide important information on LVOT and aortic root anatomy relevant to TAVR. Concomitant LVOT obstruction that is due to



hypertrophy of the basal interventricular septum may be a contraindication for TAVR because it may prevent proper valve deployment. TTE can also determine the number of aortic valve cusps, which is important in TAVR planning because bicuspid aortic valve stenosis may be considered a contraindication for TAVR. TTE may also provide aortic root measurements relevant to choosing the size and type of a TAVR prosthesis, such as the annular diameter and the measurements of the sinuses of Valsalva, sinotubular junction, and the ascending aorta.

In the initial TAVR experience, the valve size was often chosen based on the sagittal (anteroposterior) annular diameter measured typically by 2D TTE or TEE. However, shortcomings of any such 2D imaging approach soon became evident because the aortic annulus is typically ovoid in shape; its sagittal diameter is generally smaller than its

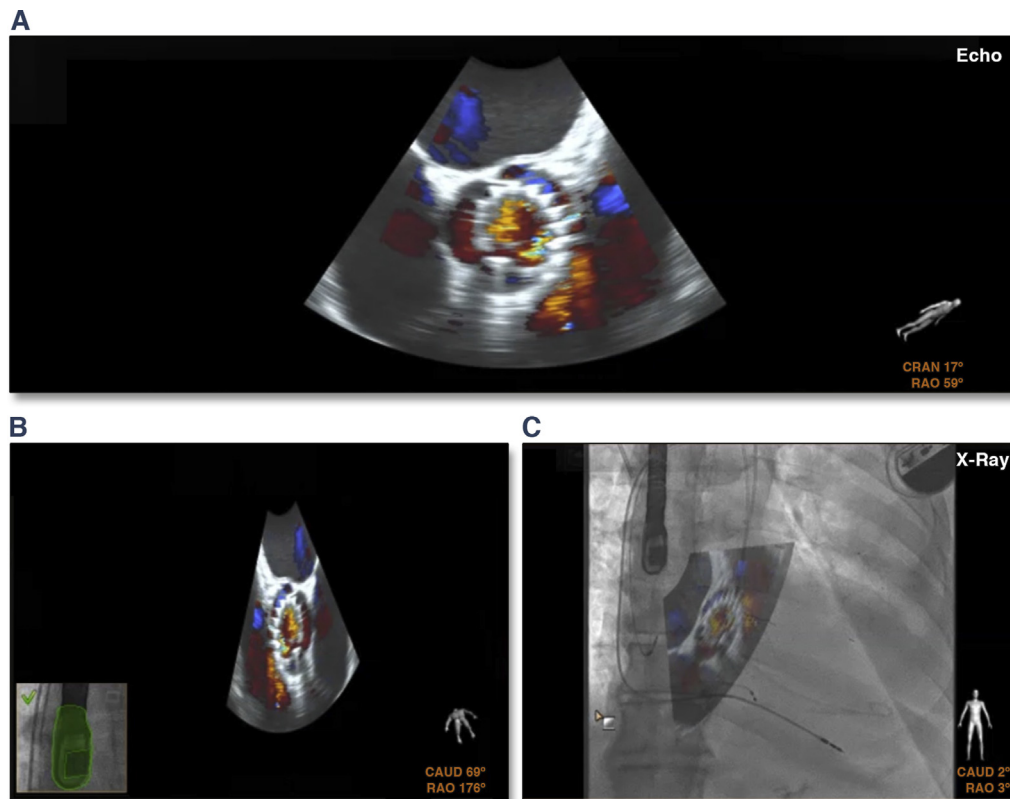
coronal (left-to-right) diameter, which cannot be reliably measured by any 2D technique, including echocardiography.

Although valve sizing based on 2D TTE may be adequate in many cases and may be improved by using 2D and 3D TEE, contrast-enhanced multislice computed tomography has become the gold standard for TAVR-specific aortic root assessment. A CT-derived annular perimeter or annular area rather than an annular diameter has become the primary means of valve sizing before TAVR in many centers.

TTE FOR INTRAPROCEDURAL TAVR GUIDANCE.

Although fluoroscopy remains the principle imaging tool for proper placement of percutaneous valves, echocardiography—either TTE or TEE—plays an important ancillary role in procedural guidance.

FIGURE 4 Fusion Imaging



After transaortic valve replacement with CorValve (Medtronic, Minneapolis, Minnesota), transesophageal echocardiography color flow Doppler (A and B) images are fused in real time with the fluoroscopy images (C). Abbreviations as in Figure 2.

Although TTE has only recently started to replace TEE in guiding TAVR, TTE already has an established role in guiding another aortic valve procedure, namely balloon aortic valvuloplasty (12). During TAVR, in properly selected patients with good imaging windows, TTE can demonstrate the exact location and performance of the prosthesis within the aortic root, its impact on the mitral valve and surrounding cardiac structures, and the potential need for repositioning of the aortic prosthesis.

2D TTE can demonstrate whether a deployed prosthesis assumed its proper circular shape in the short axis and whether the ventricular end of the prosthesis is too high or too low relative to the LVOT in the long axis. Standard TTE semiquantitative color and spectral Doppler techniques can then be used to assess TAVR function, including prosthetic gradients and presence or absence of transvalvular and perivalvular aortic regurgitation (PAR). When assessing PAR by TTE, one should bear in mind that on parasternal long-axis views, posteriorly located

PARs may be shadowed by the prosthesis; alternative (especially short-axis) views should be employed for surveillance of posterior PARs.

TTE FOR SURVEILLANCE OF POSSIBLE TAVR COMPLICATIONS.

Intraprocedural TTE can provide immediate information on all major TAVR complications, such as prosthetic malposition and malfunction, new mitral regurgitation (due to TAVR-related impingement of the anterior mitral leaflet or secondary to mitral valve disruption by TAVR deployment hardware), new right or left ventricular wall motion abnormalities, pericardial effusion with or without tamponade, and new cardiac shunt (such as ventricular septal defect or aortic annular rupture). Using standard echocardiography techniques, TTE may also be used to guide pericardiocentesis should tamponade develop during TAVR (13). TTE is also the primary imaging tool for follow-up evaluation of TAVR in a manner similar to follow-up of surgically implanted prostheses.

TABLE 1 TTE Versus TEE in TAVR Guidance

	TTE	TEE
Procedure invasiveness	<ul style="list-style-type: none"> • Noninvasive 	<ul style="list-style-type: none"> • Semi-invasive
Sedation requirement during TAVR	<ul style="list-style-type: none"> • Moderate sedation 	<ul style="list-style-type: none"> • General anesthesia
Imaging advantages	<ul style="list-style-type: none"> • 2D & Doppler TTE is the primary means for quantitative and qualitative assessment of aortic stenosis and its impact on cardiac anatomy and function • Provides diagnostic, TAVR-relevant information with a potentially better safety profile compared with TEE 	<ul style="list-style-type: none"> • Provides higher image resolution than TTE • 3D TTE has significant incremental value
Imaging disadvantages	<ul style="list-style-type: none"> • Quality of imaging determined by availability and location of imaging windows • Imaging may be limited by obesity, hyperinflation of lungs, chest deformity, and supine position • 3D TTE typically has limited incremental value • Shadowing of posterior PARs by TAVR prosthesis may occur 	<ul style="list-style-type: none"> • TEE imaging may lead to injuries of oropharynx, esophagus, and the stomach
Potential for disruption of surgical field sterility	<ul style="list-style-type: none"> • Present but can be minimized with the use of sterile TTE probe covers 	<ul style="list-style-type: none"> • Minimal
Impact of TAVR vascular access point to echocardiographic imaging	<ul style="list-style-type: none"> • Best suited for percutaneous transfemoral TAVR approach 	<ul style="list-style-type: none"> • Can be provided with any TAVR access point

2D = 2-dimensional; 3D = 3-dimensional; PAR = perivalvular aortic regurgitation; TAVR = transcatheter aortic valve replacement; TEE = transesophageal echocardiography; TTE = transthoracic echocardiography.

What is the proof that TTE can effectively replace TEE in TAVR guidance? In this issue of *iJACC*, Sengupta et al. (14) provide initial evidence from a retrospective study that TTE coupled with MOC allows for shorter procedure time while being noninferior with respect to procedural success, degree of paravalvular regurgitation, need for valve replacement, or complication rates compared with TEE under GA.

CHALLENGES IN SUBSTITUTING TTE FOR TEE IN TAVR GUIDANCE. There is no doubt that in most instances, TEE may provide higher quality images than TTE, given the higher frequency of TEE versus TTE probes and given the potential for a larger incremental value of 3D TEE compared with 3D TTE imaging in the context of TAVR (15). However, TEE remains a semi-invasive procedure and carries a small, but real, risk of serious oropharyngeal and gastroesophageal complications that can be particularly devastating in TAVR patients, who are typically very elderly with multiple comorbidities.

Challenges in replacing TEE with TTE for TAVR monitoring include image quality, potential impact on sterility of the operative field, and potential lack of physician expertise in performing TTE imaging.

Limitations to TTE imaging are well known and include obesity, hyperinflated lungs, and chest deformities. Proper selection of patients with good imaging windows before TAVR is essential for a successful periprocedural use of TTE. Because virtually all TAVR candidates have already had a TTE done pre-procedurally to assess eligibility, such TTEs should be reviewed by an echocardiographer

planning to use TTE periprocedurally for adequacy of transthoracic imaging windows.

Additionally, one should bear in mind that standard TTE imaging (as performed, for instance, for pre-procedural TAVR planning) is done in the left lateral decubitus position. By contrast, during TAVR, the patient is in a supine position; to find the optimum location of parasternal and apical windows the TTE probe often needs to be placed more laterally in supine patients compared with those imaged in the left lateral decubitus position.

The location of the vascular access for TAVR may limit available TTE imaging windows either directly through space competition or indirectly via the size of the sterile field necessary for TAVR performance. Of all approaches, percutaneous transfemoral approach—which is the most commonly used TAVR access site—has least interference with TTE imaging windows and is thus the preferred setting for using TTE in guiding TAVR. Surgical femoral cutdowns require larger sterile fields compared with transcatheter femoral approaches, which then may limit the amount of TTE imaging windows. At the other extreme is the transapical TAVR approach, which essentially precludes TTE guidance. Similarly, direct transaortic or trans-subclavian may severely limit the number of TTE imaging windows.

Echocardiographers must take every precaution to prevent contamination of the sterile field in the operating suite. Whenever there is a potential for field contamination, a commercially available sterile plastic cover for TTE probe should be used. The

emerging technology of robotic TTE (16) may provide imaging that minimizes interference with other members of the TAVR team while maintaining sterility of the surgical field.

A special challenge may be faced by physician echocardiographers in the United States, where TTEs are typically done by sonographers rather than physicians. The need for immediate and accurate interpretation of TTE images during TAVR typically requires the presence of a physician echocardiographer in a TAVR suite. If TTE images are acquired by such physicians, they need to have proper training and experience in performing TTEs.

CONCLUSIONS. The type of anesthesia during TAVR plays an important role in the overall choice of periprocedural imaging technique. It runs the gamut from moderate sedation guided with TAVR guided by fluoroscopy and angiography alone without any echocardiography at one extreme to GA with endotracheal intubation enabling 2D/3D TEE-guided TAVR on the other extreme. With the overall movement in many TAVR centers away from GA, intraprocedural TTE is well suited for a middle-ground approach of noninvasive TTE imaging using moderate sedation (17). Such an approach may minimize complications in TAVR patients, who are typically very elderly and frail with multiple comorbidities.

Fluoroscopy-Guided TAVR

Albert M. Kasel, MD, Anupama Shivaraju, MD,
Antonio Colombo, MD, Adnan Kastrati, MD

Since its first use in 2002, transcatheter aortic valve replacement (TAVR) as a treatment modality for severe, symptomatic aortic valve (AV) stenosis has undergone numerous modifications. At present, there are many percutaneous valves in clinical application and many more under investigation. The advancement in technology and innovative implantation techniques have allowed an increasing number of patients to benefit from transcatheter heart valves (THV). The purpose of this work is to describe how to perform a transfemoral TAVR under fluoroscopic guidance with a minimalistic approach using mainly the third-generation Edwards Sapien 3 valve (Edwards Lifesciences, Irvine, California) as an example.

OVERVIEW ON PATIENT SELECTION AND SCREENING.

All patients get an electrocardiogram, transthoracic echocardiogram, a coronary angiogram, and at least a 64-slice, multidetector computed tomography angiogram (CTA) of the heart, thoracic/abdominal

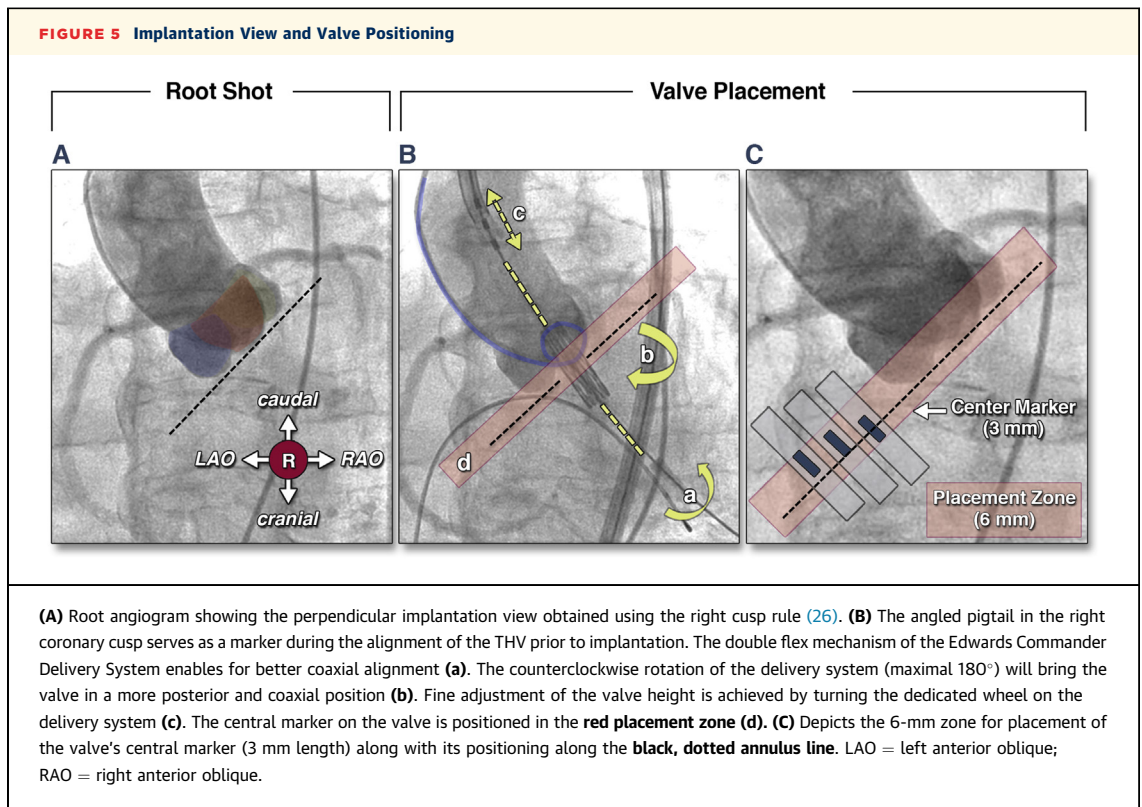
aorta, and bilateral lower extremity arterial vasculature before the TAVR procedure. The CTA is used to assess the feasibility of the TAVR based on the valve and vascular anatomy and to measure the aortic annulus size using the technique described by Kasel et al. (18).

GENERAL ANESTHESIA AND CONSCIOUS SEDATION VERSUS LOCAL AND CENTRAL ANALGESICS.

Many studies have shown that TAVR can be safely and effectively performed with the use of local anesthesia with conscious sedation (19-23). The advantages of performing TAVR under local anesthesia with conscious sedation when compared with general anesthesia include the following: ability to perform TAVR on patients with extensive pulmonary disease, better hemodynamic control and assessment, prompt assessment and treatment of stroke and myocardial infarction, early patient mobility, reduction in procedure time, decreased labor cost, and decreased hospital stay (22-25). However, a disadvantage to deep conscious sedation is that the patient can get disoriented, become restless, and move during the procedure leading to potential complications. On the other hand, Kasel et al. (21) showed that TAVR performed using only local and central analgesics is safe and feasible; full consciousness allows for better communication with the patient and less movement during the procedure.

KEY STEPS OF FLUOROSCOPIC-GUIDED TAVR.

1. Place an angled pigtail catheter in the right coronary cusp via the contralateral access site. Obtain the perpendicular implantation view under fluoroscopy using the "right cusp rule" (26) (A. Shivaraju, unpublished data, February 2015) (Figure 5A). The pigtail serves as a marker in the right coronary cusp until the valve is deployed; this reduces the use of contrast. When available, use the CTA-predicted implantation angle, which may often need to be adjusted under fluoroscopy guidance.
2. The vascular access site for the THV sheath is determined after reviewing the CTA images. Select a spot on the artery, without calcification, to puncture. The femoral head can be used as an anatomical marker. Access to the common femoral artery can be performed under fluoroscopy to ensure the needle is entering the artery above the bifurcation and below the inguinal ligament, in most cases at the middle portion of the femoral head. Percutaneous closure of the puncture site can be safely done using 2 Perclose ProGlide sutures (Abbott Vascular, Abbott Park, Illinois); the sutures are placed parallel to the course of the vessel (21).

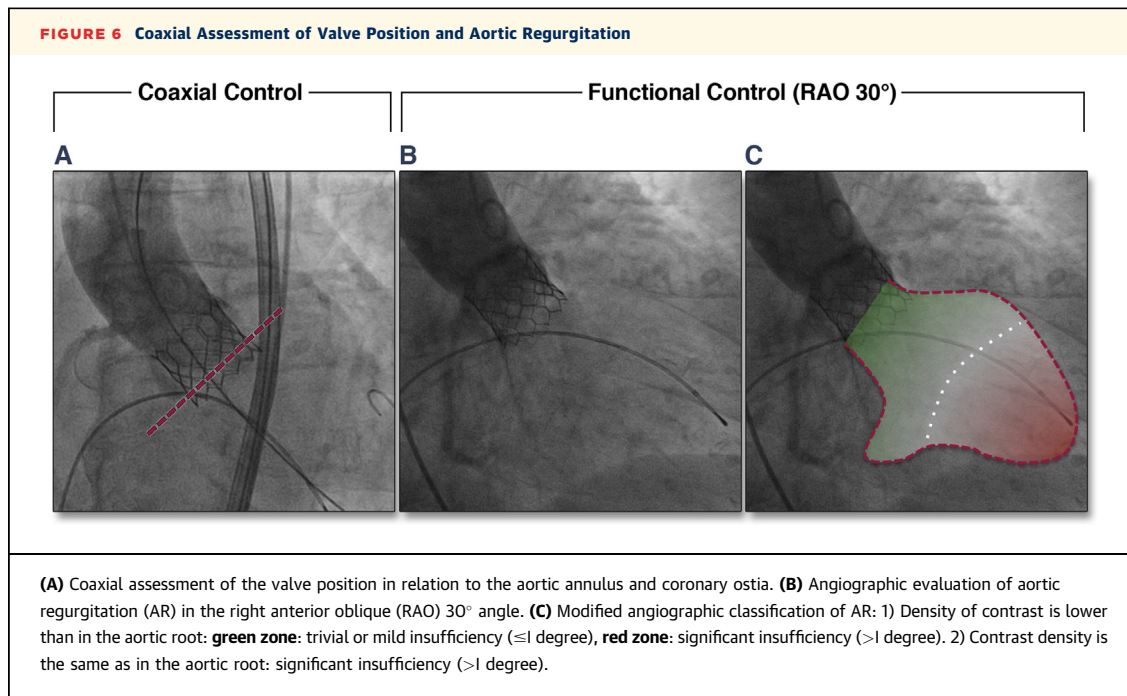


- To cross the stenotic AV, use the implantation view, direct the Amplatz-1 catheter toward the posteriorly located noncoronary cusp. Subsequently, move the straight-tip wire toward the middle of the AV via slow rotation of the catheter clockwise until the wire crosses the AV and drops into the left ventricle (27).
- In cases with minimal calcification on the AV, directly crossing the valve with the THV without previous balloon aortic valvuloplasty is feasible (28,29). In cases with a severely calcified AV, a small balloon could be used for AV pre-dilation as an alternative to the traditional balloon aortic valvuloplasty to ensure easy passage of the THV (A. Shivaraju, unpublished data, February 2015).
- Prior to implantation, align the THV using the pigtail catheter as a marker. The double flex mechanism of the Edwards Commander Delivery System (Edwards Lifesciences) will enable better coaxial alignment and positioning of the THV at the aortic annulus. In addition, the implantation height of the THV could be fine-tuned using the dedicated wheel at the grip of the commander catheter system (Figures 5B and 5C).
- After valve deployment, in the coaxial view, assess the position of the valve in relation to the aortic annulus and coronary ostia, and perform a root

angiogram with 10 ml of contrast volume with a flow rate of 10 ml/s (Figure 6A). Then, rotate the C-arm to a right anterior oblique 30° angle and perform another root angiogram with 30 ml of contrast volume at a flow rate of 20 ml/s (Figure 6B). Check for paravalvular aortic regurgitation using the simplified angiographic classification described first by Sandler et al. (30) (Figure 6C). In case of significant paravalvular regurgitation, post-dilation of the THV should be considered. Use the aortic regurgitation index (31) or a transthoracic echocardiogram for further assessment of the aortic insufficiency.

A detailed, stepwise instruction for transfemoral TAVR under fluoroscopy guidance for the Sapien XT (Edwards Lifesciences) device has previously been described by Kasel et al. (21).

FLUOROSCOPY-GUIDED TAVR USING THE MEDTRONIC CORE VALVE. Outlined here are some of the differences in the implantation of the self-expanding Medtronic Core Valve (MCV) system (Medtronic, Minneapolis, Minnesota). First, the deployment of the MCV begins at the noncoronary side, therefore, the pigtail catheter should be placed in the noncoronary cusp for guidance. Next, in most cases, direct crossing of the AV with the MCV is possible



without previous balloon aortic valvuloplasty. Nevertheless, to ensure a complete expansion of the MCV, a pre-dilation of the stenotic AV is recommended. Finally, deployment of the MCV can be done without rapid pacing. However, slow or rapid pacing will be beneficial and should be used in circumstances where there is increased valve movement during placement of this THV.

LIMITATIONS OF THE MINIMALISTIC APPROACH.

First, there is no transesophageal echocardiography guidance during the procedure to assess for intra-procedural or immediate post-procedural complications including pericardial effusion/tamponade, aortic regurgitation, and injury to the mitral apparatus. However, both fluoroscopy/angiography and transthoracic echocardiogram may resolve many of these diagnostic issues. Second, if the patient goes into respiratory distress, then they will need to be intubated during the procedure. Third, impaired renal function can limit the use of contrast, although TAVR under fluoroscopy guidance can generally be performed with < 100 ml of contrast use. Fourth, the procedure will need to be done in a timely manner as the patient will not tolerate lying flat on the table for long periods of time. Finally, rapid pacing will have to be done in short intervals to avoid the patient losing consciousness and to avoid myocardial stunning.

CONCLUSIONS. The minimalistic, fluoroscopic approach for TAVR allows for the procedure to be safely and effectively performed in the cardiac

catheterization laboratory setting. In addition, this approach reduces the procedure time, length of stay in the intensive care unit and hospital, as well as total cost. Further device developments in the field will additionally promote the use of the minimalistic, fluoroscopic approach as the standard TAVR approach.

AUTHOR DISCLOSURES Drs. Kronzon and Jelnin are consultants for Phillips Medical. Dr. Ruiz is a consultant for and has received an educational grant from Phillips Medical. Dr. Williams has been a consultant for and received research funding from Medtronic. Dr. Kasel is a medical consultant and proctor for and receives research support from Edwards Lifesciences. All other authors have reported that they have no relationships relevant to the contents of this paper to disclose.

REPRINT REQUESTS AND CORRESPONDENCE: Dr. Itzhak Kronzon, North Shore/LIJ Lenox Hill Hospital, 100 East 77th Street, New York, New York 10075. E-mail: iKronzon@nshs.edu OR Dr. Muhamed Saric, Leon H. Charney Division of Cardiology, New York University Langone Medical Center, 560 First Avenue, New York, New York 10016. E-mail: Muhamed.Saric@nyumc.org OR Dr. Albert Markus Kasel, Department of Cardiovascular Disease, Deutsches Herzzentrum München, Lazarettstrasse 36, 80636 Munich, Germany. E-mail: amkasel1@gmail.com.

REFERENCES

1. Leon MB, Smith CR, Mack M, et al., PARTNER Trial Investigators. Transcatheter aortic valve implantation for aortic stenosis. *N Engl J Med* 2010; 363:1597-607.
2. Takeda H, Muto T, Saito T, et al. Diagnostic accuracy of transthoracic and transesophageal echocardiography for the diagnosis of bicuspid aortic valve: comparison with operative findings. *Osaka City Med J* 2013;59:69-78.
3. Abraham TP, Kon ND, Nomeir AM, et al. Accuracy of transesophageal echocardiography in preoperative determination of aortic annular size during valve replacement. *J Am Soc Echocardiogr* 1997;149:149-54.
4. Kenny G, Monaghan M. How to assess aortic annulus size before transcatheter aortic valve implantation the role of echocardiography compared with other imaging modalities. *Heart* 2010;10: 1936-47.
5. Gatzmann M, Kozen M, Bojara W, et al. Long term outcome of patients with moderate and severe prosthetic aortic regurgitation after TAVR. *Am J Cardiol* 2012;110:1500-6.
6. Tamboreini G, Fusini L, Gzipari P, et al. Feasibility and accuracy of 3D TEE versus CT for the evaluation of aortic valve annulus to left main ostium distance before TAVI. *J Am Coll Cardiol Img* 2012;5:579-88.
7. Perk G, Lang RM, Garcia-Fernandez MA. Use of real time 3D transesophageal echocardiography in intracardiac catheter based interventions. *J Am Soc Echocardiogr* 2009;22:865-82.
8. Kaiser M, John M, Heilman T, et al. 2D/3D registration of TEE probe from two nonorthogonal C-arm directions. *Med Image Comput Comput Assist Interv* 2014;17:283-90.
9. Cribier A, Eltchaninoff H, Bash A, et al. Percutaneous transcatheter implantation of an aortic valve prosthesis for calcific aortic stenosis: first human case description. *Circulation* 2002;106: 3006-8.
10. Fröhlich GM, Lansky AJ, Webb J, et al. Local versus general anesthesia for transcatheter aortic valve implantation (TAVR)—systematic review and meta-analysis. *BMC Med* 2014;12:41.
11. Nishimura RA, Otto CM, Bonow RO, et al. 2014 AHA/ACC guideline for the management of patients with valvular heart disease: executive summary: a report of the American College of Cardiology/American Heart Association Task Force on Practice Guidelines. *J Am Coll Cardiol* 2014;63: 2438-88.
12. Bourgault C, Rodés-Cabau J, Côté JM, et al. Usefulness of Doppler echocardiography guidance during balloon aortic valvuloplasty for the treatment of congenital aortic stenosis. *Int J Cardiol* 2008;128:30-7.
13. Silvestry FE, Kerber RE, Brook MM, et al. Echocardiography-guided interventions. *J Am Soc Echocardiogr* 2009;22:213-31.
14. Sengupta P, Wiley B, Basnet S, et al. Transthoracic echocardiography guidance for TAVR under monitored anesthesia care. *J Am Coll Cardiol Img* 2015;8:379-80.
15. Zamorano JL, Badano LP, Bruce C, et al. EAE/ASE recommendations for the use of echocardiography in new transcatheter interventions for valvular heart disease. *J Am Soc Echocardiogr* 2011;24:937-65.
16. Boman K, Olofsson M, Berggren P, et al. Robot-assisted remote echocardiographic examination and teleconsultation. *J Am Coll Cardiol Img* 2014;7:799-803.
17. Holmes DR Jr., Mack MJ, Kaul S, et al. 2012 ACCF/AATS/SCAI/STS expert consensus document on transcatheter aortic valve replacement. *J Am Coll Cardiol* 2012;59:1200-54.
18. Kasel AM, Cassese S, Bleiziffer S, et al. Standardized imaging for aortic annular sizing: implications for transcatheter valve selection. *J Am Coll Cardiol Img* 2013;6:249-62.
19. Durand E, Borz B, Godin M, et al. Transfemoral aortic valve replacement with the Edwards SAPIEN and Edwards SAPIEN XT prosthesis using exclusively local anesthesia and fluoroscopic guidance: feasibility and 30-day outcomes. *J Am Coll Cardiol Intv* 2012;5:461-7.
20. Greif M, Lange P, Nabauer M, et al. Transcatheter aortic valve replacement with the Edwards SAPIEN XT and Medtronic CoreValve prosthesis under fluoroscopic guidance and local anaesthesia only. *Heart* 2014;100: 691-5.
21. Kasel AM, Shivaraju A, Schneider S, et al. Standardized methodology for transfemoral transcatheter aortic valve replacement with the Edwards Sapien XT valve under fluoroscopy guidance. *J Invasive Cardiol* 2014;26:451-61.
22. Motloch LJ, Rottlaender D, Reda S, et al. Local versus general anesthesia for transfemoral aortic valve implantation. *Clin Res Cardiol* 2012;101: 45-53.
23. Yamamoto M, Meguro K, Mouillet G, et al. Effect of local anesthetic management with conscious sedation in patients undergoing transcatheter aortic valve implantation. *Am J Cardiol* 2013;111:94-9.
24. Babaliaros V, Devireddy C, Lerakis S, et al. Comparison of transfemoral transcatheter aortic valve replacement performed in the catheterization laboratory (minimalist approach) versus hybrid operating room (standard approach): outcomes and cost analysis. *J Am Coll Cardiol Intv* 2014;7:898-904.
25. Ruggeri L, Gerli C, Franco A, et al. Anesthetic management for percutaneous aortic valve implantation: an overview of worldwide experiences. *HSR Proc Intensive Care Cardiovasc Anesth* 2012; 4:40-6.
26. Kasel AM, Cassese S, Leber AW, von Scheidt W, Kastrati A. Fluoroscopy-guided aortic root imaging for TAVR: "follow the right cusp" rule. *J Am Coll Cardiol Img* 2013;6:274-5.
27. Kasel AM, Shivaraju A, von Scheidt W, Kastrati A, Thilo C. Anatomic guided crossing of a stenotic aortic valve under fluoroscopy: "right cusp rule, part III". *J Am Coll Cardiol Intv* 2015; 8(1 Pt A):119-20.
28. Garcia E, Martin P, Hernandez R, et al. Feasibility and safety of transfemoral implantation of Edwards SAPIEN XT prosthesis without balloon valvuloplasty in severe stenosis of native aortic valve. *Catheter Cardiovasc Interv* 2014;83:791-5.
29. Mollmann H, Kim WK, Kempfert J, et al. Transfemoral aortic valve implantation of Edwards SAPIEN XT without predilatation is feasible. *Clin Cardiol* 2014;37:667-71.
30. Sandler H, Dodge HT, Hay RE, Rackley CE. Quantitation of valvular insufficiency in man by angiocardiography. *Am Heart J* 1963;65:501-13.
31. Sinning JM, Hammerstingl C, Vasa-Nicotera M, et al. Aortic regurgitation index defines severity of peri-prosthetic regurgitation and predicts outcome in patients after transcatheter aortic valve implantation. *J Am Coll Cardiol* 2012;59:1134-41.

KEY WORDS fluoroscopy, transcatheter aortic valve replacement, transesophageal echocardiography, transthoracic echocardiography