



REVISTA BRASILEIRA DE ANESTESIOLOGIA

Official Publication of the Brazilian Society of Anesthesiology
www.sba.com.br



SCIENTIFIC ARTICLE

Effectiveness of sub-Tenon's block in pediatric strabismus surgery

Kasim Tuzcu^{a,*}, Mesut Coskun^b, Esra Ayhan Tuzcu^b, Murat Karcioğlu^a,
Isil Davarci^a, Sedat Hakimoglu^a, Suzan Aydın^a, Selim Turhanoglu^a

^a Department of Anesthesiology and Reanimation, Medical Faculty of the Mustafa Kemal University, Hatay, Turkey

^b Department of Ophthalmology, Medical Faculty of the Mustafa Kemal University, Hatay, Turkey

Received 27 November 2013; accepted 5 February 2014

Available online 11 March 2014

KEYWORDS

Sub-Tenon's block;
Pediatric strabismus
surgery;
Anesthesia

Abstract

Background and objectives: Strabismus surgery is a frequently performed pediatric ocular procedure. A frequently occurring major problem in patients receiving this treatment involves the oculocardiac reflex. This reflex is associated with an increased incidence of postoperative nausea, vomiting, and pain. The aim of this study was to investigate the effects of a sub-Tenon's block on the oculocardiac reflex, pain, and postoperative nausea and vomiting.

Methods: Forty patients aged 5–16 years with American Society of Anesthesiologists status I–II undergoing elective strabismus surgery were included in this study. Patients included were randomly assigned into two groups by using a sealed envelope method. In group 1 ($n=20$), patients did not receive sub-Tenon's anesthesia. In group 2 ($n=20$), following intubation, sub-Tenon's anesthesia was performed with the eye undergoing surgery. Atropine use, pain scores, oculocardiac reflex, and postoperative nausea and vomiting incidences were compared between groups.

Results: There were no significant differences between groups with regard to oculocardiac reflex and atropine use ($p > 0.05$). Pain scores 30 min post-surgery were significantly lower in group 2 than in group 1 ($p < 0.05$). Additional analgesic needed during the postoperative period was significantly lower in group 2 compared to group 1 ($p < 0.05$).

Conclusions: In conclusion, we think that a sub-Tenon's block, combined with general anesthesia, is not effective and reliable in decreasing oculocardiac reflex and postoperative nausea and vomiting. However, this method is safe for reducing postoperative pain and decreasing additional analgesia required in pediatric strabismus surgery.

© 2014 Sociedade Brasileira de Anestesiologia. Published by Elsevier Editora Ltda. All rights reserved.

* Corresponding author.

E-mail: tuzcu01@gmail.com (K. Tuzcu).

PALAVRAS-CHAVE

Bloqueio subtenoniano;
 Cirurgia de estrabismo pediátrico;
 Anestesia

Eficácia do bloqueio subtenoniano em cirurgia de estrabismo pediátrico**Resumo**

Justificativa e objetivo: A cirurgia de estrabismo é um procedimento oftalmológico comum em pediatria. Um grande problema que ocorre com frequência em pacientes submetidos a esse tratamento envolve o reflexo oculocardíaco. Esse reflexo está associado ao aumento da incidência de náusea, vômito e dor. O objetivo deste estudo foi investigar os efeitos do bloqueio subtenoniano sobre o reflexo oculocardíaco, a dor, a náusea e o vômito no período pós-operatório.

Métodos: Foram incluídos no estudo 40 pacientes entre 5-16 anos, estado físico ASA I-II, submetidos à cirurgia eletiva de estrabismo. Foram randomicamente alocados em dois grupos, com o método de envelope lacrado. No Grupo 1 (n=20), pacientes não receberam bloqueio subtenoniano. No Grupo 2 (n=20), após a intubação, o bloqueio subtenoniano foi feito no olho submetido à cirurgia. Uso de atropina, escores de dor, reflexo oculocardíaco e incidência de náusea e vômito foram comparados.

Resultados: Não houve diferença significativa entre os grupos em relação ao reflexo oculocardíaco e ao uso de atropina ($p > 0,05$). Os escores de dor em 30 minutos de pós-operatório foram significativamente menores no Grupo 2 do que no Grupo 1 ($p < 0,05$). A necessidade de analgésico adicional durante o período pós-operatório foi significativamente menor no Grupo 2 do que no Grupo 1 ($p < 0,05$).

Conclusões: O bloqueio subtenoniano, em combinação com anestesia geral, não é eficaz e confiável para diminuir o reflexo oculocardíaco, bem como náusea e vômito pós-operatórios (NVPO). Porém, esse método é seguro para diminuir a dor no período pós-operatório e reduzir a analgesia adicional necessária em cirurgia de estrabismo pediátrico.

© 2014 Sociedade Brasileira de Anestesiologia. Publicado por Elsevier Editora Ltda. Todos os direitos reservados.

Introduction

Strabismus surgery is one of the most frequently performed pediatric ocular operations.¹ However, it can cause unfavorable side effects during intraoperative and postoperative periods. Typically, the major problems associated with strabismus surgeries include increased risk of the oculocardiac reflex (32–90%). This reflex may occur in response to a retraction of the extra-ocular muscles and is associated with an increased postoperative nausea and vomiting (PONV) incidence (46–85%) resulting from the oculometric reflex.^{2–4}

In the pediatric population, another important problem is postoperative pain management. Because of potential side effects, opiates and non-steroidal anti-inflammatory drugs should be used cautiously in these cases, particularly in outpatient surgeries. In recent years, regional anesthesia techniques have been recommended in conjunction with general anesthesia.^{5–8} Sub-Tenon's block is one of the regional anesthetic techniques used in ocular surgery. This technique involves local anesthetics being injected posterior to Tenon's capsule.

In this study, we aimed to investigate the effects of a sub-Tenon's block on the oculocardiac reflex (OCR), pain, and postoperative nausea and vomiting (PONV).

Methods

Forty patients aged 5–16 years with American Society of Anesthesiologists (ASA) physical status I–II undergoing elective strabismus surgery were included in this study. All

the parents were informed and gave their written consent. Ethical approval for this study was provided by the local Ethics Committee. Patients with an ocular pathology other than strabismus, patients allergic to the anesthetic agent, and children without communication abilities were excluded. During the preanesthesia evaluation, children were encouraged to report postoperative pain, if present. For premedication, 0.5 mg/kg midazolam in a particle-free fruit juice was orally given to all patients 1 h before surgery. Anesthesia induction was achieved by 2.5 mg/kg propofol, 1 µg/kg fentanyl, and 0.6 mg/kg rocuronium. Patients were intubated to secure their airway. Anesthesia was maintained by 2–3% sevoflurane in a 50%:50% (v/v) O₂ to air mixture. No additional fentanyl dose was used. Sevoflurane concentration was increased by 0.5% when an increase higher than 20%, compared to baseline values, occurred in heart rate and mean arterial pressure (MAP). End-tidal CO₂ pressure was maintained between 30 and 35 mmHg during surgery.

The patients were randomly assigned into two groups by using a sealed envelope method. In group 1 (n=20), patients did not receive sub-Tenon's anesthesia. In group 2 (n=20), following intubation, sub-Tenon's anesthesia was performed with the eye undergoing surgery. Sub-Tenon's anesthesia was performed with 5% bupivacaine (0.08 ml/kg). Under sterile conditions, a 19-gauge curved, blunt metallic cannula (25 mm) was inserted into sub-Tenon's space and the local anesthetic was injected. Surgery began 5 min after the sub-Tenon's injection.

All patients were monitored for heart rate, blood pressure, peripheral oxygen saturation (SpO₂), and end-tidal CO₂. These variables were recorded at intervals of every

Table 1 Demographic data of the patients.

	Group 1	Group 2	<i>p</i>
Age (years)	9 (5–16)	11 (5–16)	0.743
Weight (kg)	33.5 (14–65)	38.5 (17–65)	0.597
Gender (M/F)	8/12	10/10	0.525
Total muscles (1/2/3)	2/15/3	2/16/2	0.739
Operation times	75 (30–150)	67.5 (60–135)	0.735

5 min. OCR was considered an acute increase, higher than 20%, in heart rate or an acute decrease in heart rate below 60 beats/min. In the case of OCR in this study, the surgical stimulus was withdrawn. If a patient did not respond, atropine was given. Intraoperative follow-up was performed by an anesthesiologist blinded to study groups. Paracetamol (15 mg/kg, i.v.) was given to all patients 15 min before completion of the operation. When the operations were completed, patients were extubated by an antagonizing neuromuscular block with neostigmin and atropine. Pain, nausea, and vomiting were assessed at 30 min and at 1, 2, 4, and 6 h after surgery.

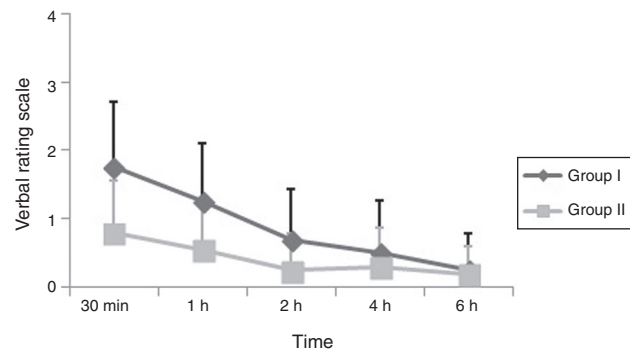
Postoperative follow-up was performed by clinicians blinded to study groups. Postoperative pain was assessed by using a verbal pain scale (0=no pain; 1=mild pain; 2=moderate pain; 3=severe pain; 4=very severe pain). Additional analgesic doses (ibuprofen, 10 mg/kg, p.o.) were given to patients with pain at a moderate or higher level. Numeric scoring was used for PONV (0=no nausea; 1=nausea is present, but no vomiting; 3=vomiting once within 30 min; 4=vomiting two or more times within 30 min). Ondansetron (0.1 mg/kg, i.v.) was given in cases of vomiting.

SPSS for Windows, version 15.0, was used for statistical analysis. Both descriptive and analytical statistics were used. Chi-square/Fischer's tests were used for comparisons between categorical variables. Normal distributions of continuous variables were tested with a Kolmogorov–Smirnov test. Mann-Whitney *U* tests were used to compare median values between groups. Statistical significance was considered as $p < 0.05$ for all statistical analysis.

Results

In this study, 40 patients were assigned to one of two groups with 20 patients per group. There were no significant differences between groups regarding age, gender, weight, number of muscles operated on, and operation times ($p > 0.05$). Demographic data are shown in Table 1.

Although the OCR developed in fewer patients in group 2 ($n = 7$) compared to group 1 ($n = 10$), there was no significant

**Figure 1** Postoperative verbal rating scale.

difference between groups ($p > 0.05$). There was also no significant difference in atropine use due to the OCR between groups ($p > 0.05$; Table 2).

Although PONV was observed in fewer patients in group 2, there was no significant difference in PONV scores between the groups ($p > 0.05$). In group 1, there was nausea in four and vomiting in seven patients, whereas in group 2, there was nausea in two patients and vomiting in two patients (Table 2).

When pain scores 30 min after surgery were considered, pain scores were significantly lower in group 2 than in group 1 ($p < 0.05$) (Fig. 1). Additional analgesic needs during the postoperative period were significantly lower in group 2 compared to group 1 ($p < 0.05$). Fifteen patients needed additional analgesic doses in group 1, while only six patients needed additional analgesic doses in group 2.

Discussion

Regional anesthesia is used as an adjunct to general anesthesia in children. Several studies have reported that preoperative regional blocks reduce the need for intraoperative anesthetic and opiates, and it contributes to postoperative analgesia.^{9–12} In ophthalmological surgery, several types of regional blocks are used including peribulbar, retrobulbar, and sub-Tenon's blocks. However, in peribulbar and retrobulbar blocks, systemic life-threatening complications or ocular complications may occur. These conditions may include subarachnoid, intravenous local anesthetics injections, ocular complications, such as globe perforation, nerve injury, and retrobulbar hemorrhage that may potentially cause loss of vision.^{13–16} As sub-Tenon's block is performed under direct visualization, it provides a safe anesthesia with minimal risk for severe complications.^{17,18}

Table 2 Incidence of side effects and supplementary drug requirements presented as *n* (%).

	Group 1 (<i>n</i> = 20)	Group 2 (<i>n</i> = 20)	<i>p</i>
Intraoperative OCR	10 (50%)	7 (35%)	0.337
Intraoperative atropine	4 (20%)	4 (20%)	1
Nausea/vomiting	4 (20%)/7 (35%)	2 (10%)/2 (10%)	0.061
Supplementary drug requirements	15 (75%)	6 (30%)	0.010

OCR, a trigeminal–vagal reflex response manifesting as cardiac arrhythmias and hypotension, occurs in response to retraction of extra-ocular muscles during strabismus surgery. Several maneuvers have been proposed to eliminate or reduce OCR in the literature. However, none of these methods are considered effective, safe, or acceptable.^{1,3} Intramuscular administration of anticholinergic agents used in premedication, such as atropine and glycopyrrolate, are inadequate in preventing OCR.¹⁹ In strabismus surgery, manipulation of extraocular muscles also increases PONV incidence by stimulating the oculometric reflex.^{1,3–5}

A study in which propofol anesthesia was used in pediatric strabismus surgery reported that sub-Tenon's block significantly decreased OCR and PONV incidence.⁵ In our study, although OCR and PONV were less commonly observed in the group that underwent sub-Tenon's block, the difference between groups was not significant. The difference between two study groups, despite identical numbers of patients in groups, could be due to the distinct anesthetic methods used. Propofol infusion could have contributed to decreased PONV incidence. However, this does not explain the lower incidence of OCR.

In the pediatric population, another major problem is postoperative pain management. In recent years, sub-Tenon's block has frequently been used in ophthalmic surgery, as it provides akinesia in the globe and has potential advantages over needle-based blocks.^{1,17,20} In a sub-Tenon's block, local anesthetic is injected posterior to Tenon's capsule and distributed with extra-ocular muscles, thereby exerting anesthetic and analgesic effects.^{20,21}

A study by Steib et al.⁵ reported that sub-Tenon's block decreased postoperative pain when compared to a control group that was injected with saline. In another study, sub-Tenon's block was compared to an intravenous fentanyl injection and reported that sub-Tenon's block provided better analgesia.⁷ In our study, postoperative pain scores and the need for additional analgesic were decreased in the group that underwent sub-Tenon's block; these results are in agreement with literature.^{5,10,22}

In conclusion, we think that sub-Tenon's block, combined with general anesthesia, is not effective or reliable in decreasing OCR and PONV. Further studies with larger sample sizes are needed; however, a sub-Tenon's block is safe for reducing postoperative pain and the need for additional analgesia in pediatric strabismus surgery.

Authorship

KT, MC, EAT, MK and ID conceived the study and participated in its design and coordination and helped to draft the manuscript. SH, SA and ST performed the review of the literature, wrote the initial draft and performed the statistical analyses. MC and EAT performed surgery and drafted the manuscript. ID and ST analyzed the data. All authors read and approved the final manuscript.

Conflicts of interest

The authors declare no conflicts of interest.

References

- McGoldrick KE, Gayer SI. Anesthesia and the eye. In: Barash PG, Cullen BF, Stoelting RK, editors. *Clinical anesthesia*. 5th ed. Philadelphia: Lippencott Williams & Wilkins; 2006. p. 974–96.
- Blanc VF, Hardy JF, Milot J, et al. The oculocardiac reflex: a graphic and statistical analysis in infants and children. *Can Anaesth Soc J*. 1983;30:360–9.
- Donlon JV, Doyle JDJ. Anesthesia for eye, ear, nose and throat surgery. In: Miller RD, editor. *Anesthesia*. New York: Churchill Livingstone; 1990. p. 2001–23.
- Wier PM, Munro HM, Reynolds PI, et al. Propofol infusion and the incidence of emesis in pediatric outpatient strabismus surgery. *Anesth Analg*. 1993;76:760–4.
- Steib A, Karcenty A, Calache E, et al. Effects of subtenon anesthesia combined with general anesthesia on perioperative analgesic requirements in pediatric strabismus surgery. *Reg Anesth Pain Med*. 2005;30:478–83.
- Suresh S, Wheeler M. Practical pediatric regional anesthesia. *Anesthesiol Clin North Am*. 2002;20:83–113.
- Ghai B, Ram J, Makkar JK, et al. Subtenon block compared to intravenous fentanyl for perioperative analgesia in pediatric cataract surgery. *Anesth Analg*. 2009;108:1132–8.
- Sethi S, Ghai B, Sen I, et al. Efficacy of subtenon block in infants – a comparison with intravenous fentanyl for perioperative analgesia in infantile cataract surgery. *Paediatr Anaesth*. 2013;23:1015–20.
- Ates Y, Unal N, Cuhruk H, et al. Postoperative analgesia in children using preemptive retrobulbar block and local anesthetic infiltration in strabismus surgery. *Reg Anesth Pain Med*. 1998;23:569–74.
- Sheard RM, Mehta JS, Barry JS, et al. Subtenons lidocaine injection for postoperative pain relief after strabismus surgery in children: a pilot study. *J AAPOS*. 2003;7:38–41.
- Subramaniam R, Subbarayudu S, Rewari V, et al. Usefulness of pre-emptive peribulbar block in pediatric vitreoretinal surgery: a prospective study. *Reg Anesth Pain Med*. 2003;28:43–7.
- Chhabra A, Sinha R, Subramaniam R, et al. Comparison of sub-Tenon's block with i.v. fentanyl for paediatric vitreoretinal surgery. *Br J Anaesth*. 2009;103:739–43.
- Rodrigues-Coleman H, Spaide R. Ocular complications of needle perforations during retrobulbar and peribulbar injections. *Ophthalmol Clin North Am*. 2001;14:573–9.
- Parulekar MV, Berg S, Elston JS. Adjunctive peribulbar anaesthesia for paediatric ophthalmic surgery: are the risks justified? *Paediatr Anaesth*. 2002;12:85–6.
- Wong DH. Regional anaesthesia for intraocular surgery. *Can J Anaesth*. 1993;40:635–57.
- Troll GF. Regional ophthalmic anesthesia: safe techniques and avoidance of complications. *J Clin Anesth*. 1995;7:163–72.
- Guise PA. Sub-tenon anesthesia: a prospective study of 6,000 blocks. *Anesthesiology*. 2003;98:964–8.
- Anderson CJ. Circumferential perilimbal anesthesia. *J Cataract Refract Surg*. 1996;22:1009–12.
- Mirakur RK, Clarke RS, Dundee JW, et al. Anticholinergic drugs in anaesthesia. A survey of their present position. *Anaesthesia*. 1978;33:133–8.
- Ripart J, Metge L, Prat-Pradal D, et al. Medial canthus single-injection episcleral (sub-tenon anesthesia): computed tomography imaging. *Anesth Analg*. 1998;87:42–5.
- Niemi-Murola L, Krootila K, Kivisaari R, et al. Localization of local anesthetic solution by magnetic resonance imaging. *Ophthalmology*. 2004;111:342–7.
- Sheard RM, Mehta JS, Barry JS, et al. Subtenons lidocaine injection for postoperative pain relief after strabismus surgery in children: a prospective randomized controlled trial. *J AAPOS*. 2004;8:314–7.