

Contents lists available at [ScienceDirect](http://www.sciencedirect.com)

International Journal of Surgery Case Reports

journal homepage: www.casereports.com

Three complications of pair (puncture, aspiration, injection, reaspiration) in one case: Recurrent hemobilia, cyst infection and pneumonia

B. Sevinç^{a,*}, Ö. Karahan^b, S. Bakdik^c, N. Aksoy^d, M.A. Eryilmaz^d

^a Sarıkaya State Hospital, General Surgery Clinic, Turkey

^b Konya University, Meram Medical Faculty, General Surgery Clinic, Turkey

^c Konya Education and Research Hospital, Radiology Department, Turkey

^d Konya Education and Research Hospital, General Surgery Clinic, Turkey

ARTICLE INFO

Article history:

Received 5 January 2015

Received in revised form 29 January 2015

Accepted 2 February 2015

Available online 7 February 2015

Keywords:

Hemobilia

PAIR

Hydatid Cyst

ERCP

ABSTRACT

INTRODUCTION: With the appropriate indications, puncture, aspiration, injection and reaspiration (PAIR) is the most effective minimal invasive method used in the treatment of hydatid cysts. Hemobilia is the hemorrhagia in bile ducts in consequence of any reason. In literature there is no case with hemobilia because of PAIR. This is the first case with recurrent hemobilia, infection in cyst cavity and pneumonia because of PAIR.

CASE: A 66 years old female patient was admitted to hospital with complaints of abdominal pain, hematemesis and melaena. She gave the history of PAIR for two hydatid cysts. At physical examination, there were jaundice, tenderness at right subcostal area and melaena at rectal digital examination. Hemobilia was detected by abdominal ultrasonography and magnetic resonance cholangiopancreatography (MRCP). An endoscopic retrograde cholangiopancreatography (ERCP) and endoscopic sphincterotomy were performed. The patient was discharged after 6 days hospital stay. One day after the discharge the patient was admitted to hospital with the same complaints again. Performing ERCP and balloon extraction, the hematoma filling the common bile duct was removed. After the patient was hemodynamically stable for 3 days, she was discharged from the hospital. A week after that the patient was admitted to hospital with the clinical findings of infected hydatid cyst and pneumonia. The patient was treated medically with mechanical ventilation support for 8 days.

CONCLUSION: It should not be underestimated that, there can be serious complications of PAIR like hemobilia. Therefore, PAIR should be performed only in centers having appropriate medical and surgical facilities.

© 2015 The Authors. Published by Elsevier Ltd. on behalf of Surgical Associates Ltd. This is an open access article under the CC BY-NC-SA license (<http://creativecommons.org/licenses/by-nc-sa/4.0/>).

1. Introduction

As a zoonosis, hydatid cyst is one of the most important health problems of Turkey. Recently hydatid cysts can be treated as medically, surgically or by puncture, aspiration, injection, reaspiration (PAIR). With the appropriate indications, PAIR is the most effective minimal invasive treatment modality. It is superior to other modalities with low mortality, morbidity and recurrence rates and shorter hospital stay [1]. Usually one day hospital stay is enough, but complications may prolong this time just about 20 days [2]. The reported rate of minor complication is 11%, major complication is 2.8% and biliary fistula is 5.6% [3].

Hemobilia means bleeding into bile ducts because of any reason. It is mostly seen as a complication of surgical interventions to bile duct, gall bladder and liver, percutaneous transhepatic cholangiography (PTC), biliary drainage and catheterization of hepatic artery. Other reasons of hemobilia may be; trauma, gallbladder and bile duct inflammation, liver abscess, polyarteritis nodosa etc. [4–10]. In literature, there is no case with hemobilia because of percutaneous treatment of hydatid cyst. This is the first case reported with three mortal complications (recurrent hemobilia, infection of cyst cavity and pneumonia).

2. Case

Sixty six years old female patient, underwent PAIR, in operating theater, for her two type 1 hydatid cysts (each was 8 cm in diameter) on the 9th of July (Fig. 1). Six days after the PAIR (15th of July), she was admitted to hospital with abdominal pain,

* Corresponding author at: Sarıkaya State Hospital, Sarıkaya, Yozgat, Turkey.

Tel.: +90 5054880511.

E-mail address: drbarisvinc@gmail.com (B. Sevinç).

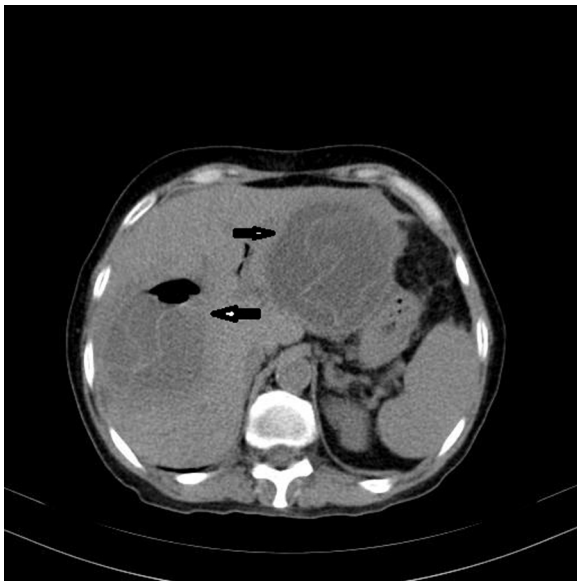

Fig. 1. CT image showing the hydatid cyst that PAIR was performed.

jaundice, hematemesis and melaena. Her pain was recurrent and colic in character. At physical exam, she had tachycardia (110/min), jaundice, tenderness in right upper quadrant of abdomen and melaena at rectal digital examination. She had a hemoglobin value of 8 gr/dl. She had been accepted to intensive care unit (ICU), a central line was attained and 3 units of erythrocyte suspension were administered with appropriate fluid and electrolyte resuscitation. Hemobilia was detected by abdominal ultrasonography and magnetic resonance cholangiopancreatography (MRCP) (Figs. 2, 3 and 4). By performing endoscopic retrograde cholangiopancreatography (ERCP) and endoscopic sphincterotomy, blood degradation products were cleaned from the common bile duct. After the patient stayed hemodynamically stabilized, she was discharged from the hospital in 21th July.

One day after the discharge, the patient was admitted to hospital with hemobilia again. She was accepted to ICU and IV fluid and electrolytes had been administered. On 22nd of July an ERCP was performed and with the help of balloon the hematoma filling the common bile duct was removed (Fig. 5). Beside the fluid and electrolyte treatment, 2 units of erythrocyte suspension was

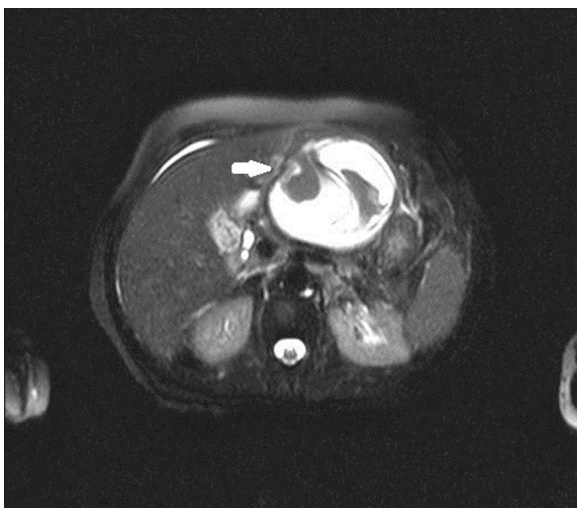

Fig. 2. MRI image showing the drained cyst consisting blood in left lobe of liver, magnetic resonance cholangiopancreatography.

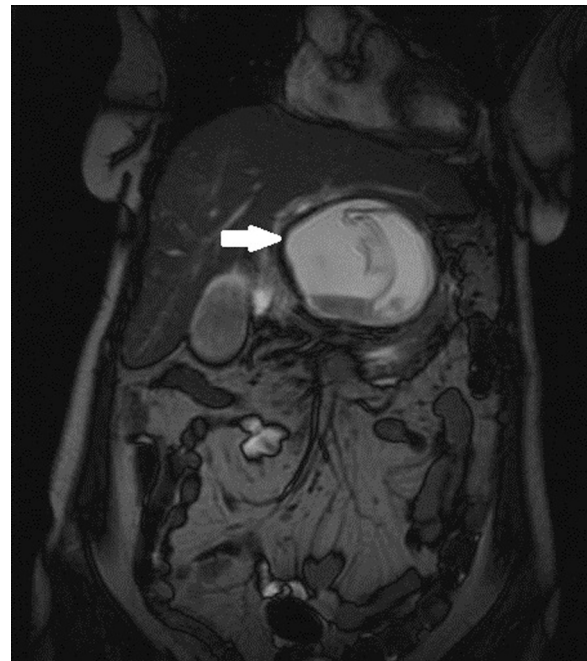

Fig. 3. MRCP image showing hematoma in gall bladder (magnetic resonance cholangiopancreatography).

administered. The patient stayed stable hemodynamically; therefore we did not make any intervention for hemorrhagia. During the following three days, patient was stable, fed orally. When the laboratory findings decreased to normal values, the patient was discharged on 26th of July.

Four days after the discharge (30th July), the patient was admitted to the hospital again with the complaints of fever, palpitations, loss of appetite, nausea and vomiting. The patient had the clinical laboratory finding of infected hydatid cyst and pneumonia (Fig. 6). The two hydatid cyst cavities had turned into abscess formation and they had been drained percutaneously.

She stayed at 3rd degree ICU and had mechanical ventilation support for 8 days because of severe pneumonia. Culture

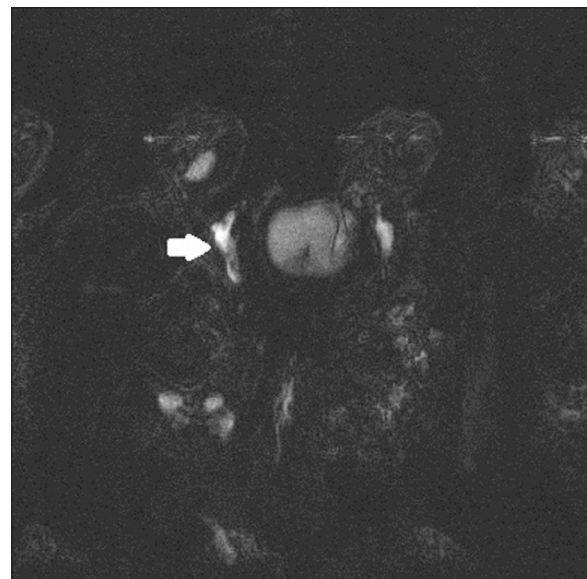

Fig. 4. MRCP image showing hematoma filling the common bile duct, magnetic resonance cholangiopancreatography.

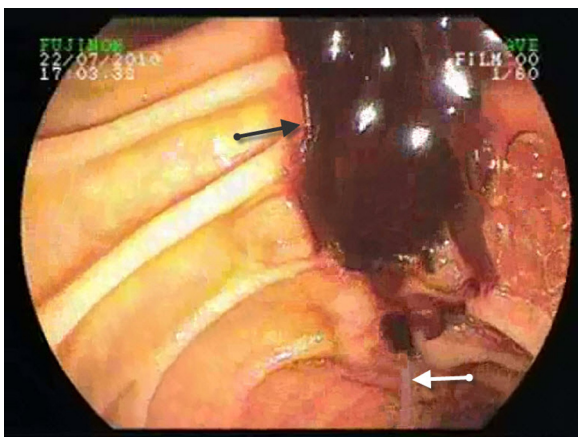


Fig. 5. Hematoma removed by endoscopic retrograde cholangiopancreatography (ERCP). Black arrow: hematoma removed from the common bile duct, white arrow: ERCP catheter.

results of both two abscess and sputum revealed acinetobacteria and enterococcus. According to those culture results and suggestions of infectious diseases specialist, she had been under therapy with sulbactam-sulpherazon (2×1 go), amikacin (2×500 mg) and vancomycin (4×500 mg). After the infectious clinic had been recovered, on the 19th of August blood drained from the drainage tube located in cyst cavity in left hepatic lobe and she had melaena for two times. Besides, she did not need any blood transfusion and two days later her stool was normal. Dynamic liver computerized tomography revealed no reason such as vessel abnormality or aneurysm that can explain the hemorrhage. We prepared for arterial embolization; however, there was no need for this intervention. After the drainage tubes had been removed, the patient was monitored for one week and the antibiotherapy continued. After one week monitorization she had no problem and was fully healthy. She was discharged from the hospital on the 31st of August. Two weeks later on the 16th of September, at the first control visit, she was healthy. At plain chest x-ray atelectasia at right lower zone and radiological recover at left lung was detected (Fig. 7). At abdominal ultrasonography the hydatid cyst in the right lobe of liver was smaller.

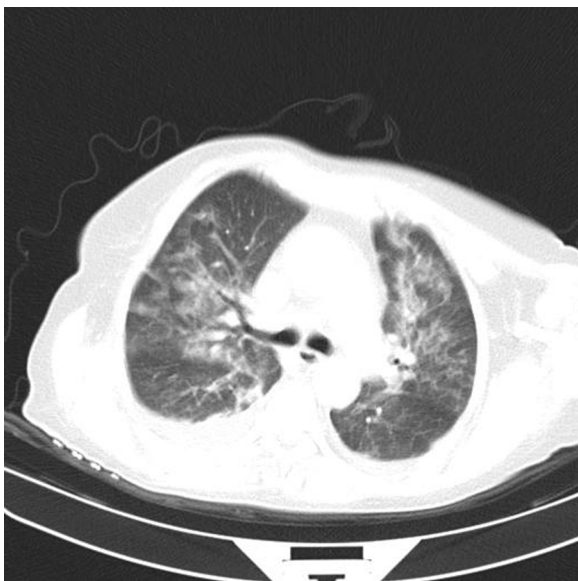


Fig. 6. Thorax computed tomography showing pneumonia.

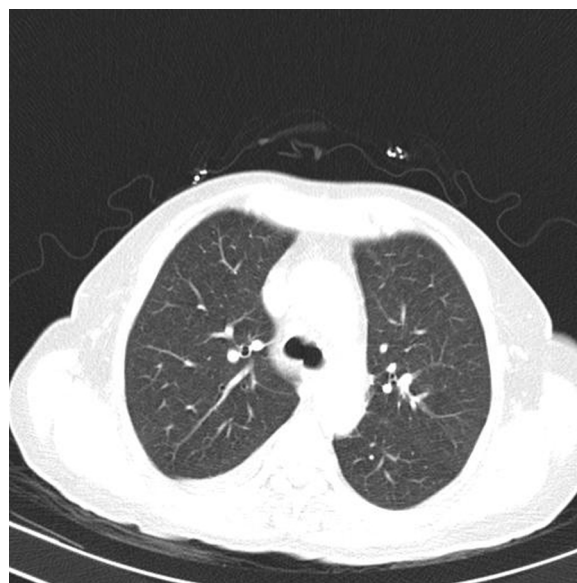

Fig. 7. Thorax computed tomography, treated pneumonia.

At her control visit on the 22nd of November, at abdominal ultrasonography cyst cavity at right lobe was disappeared and postoperative changes were seen. The cyst at left lobe was measured 56×40 mm in diameter. She gained 4 kg after her last discharge.

3. Discussion

It was reported that complication and recurrence rates of PAIR are better than surgery [11] and percutaneous drainage is the best method among the methods used recently [3]. Furthermore, PAIR is not such a method that has no complication. They are very rare but life threatening complications may occur [12].

PAIR has been performed in our hospital for 6 years. During this period, it has been performed to 256 hydatid cysts successfully. We met serious complications in 2 (0,8%) of those 256 cases. We met anaphylactic shock in one case and hemobilia, cyst infection and pneumonia, as we reported, in this case.

After PAIR had been performed, the patient had no problem and one day after the procedure she was discharged from the hospital. She was admitted to hospital with hemobilia 6 day after the procedure. She had abdominal pain, cholic in character, jaundice, hematemesis and melaena as typical symptoms of hemobilia. All the laboratory findings, ultrasonography, MRCP and ERCP confirmed the diagnosis. Hemobilia occurred out of the hospital for two times and at the hospital for one time. The first two attacks of hemobilia required blood transfusion not exceeding 3 units of erythrocyte transfusion and at the third attack there was no need for transfusion.

For the treatment of hemobilia, which cannot be controlled medically, transcatheterial arterial embolization can be performed successfully [13]. In our case we prepared the patient for this implementation, but there was no need. We only performed endoscopic sphincterotomy to facilitate bile drainage from the common bile duct.

After the first attack patient was discharged from the hospital, but she was readmitted to hospital one day after the discharge. She had the same clinical findings and was discharged from the hospital after 5 days of therapy.

She was accepted to hospital with cyst infection and pneumonia 4 days later. This time she stayed at hospital for 31 days (8

days in ICU). At this time antibiotherapy according to culture and antibiography results had been administered.

For a PAIR without complication the patient stays at hospital for one day. This period can be between 17–20 days for a patient in the event of complication [2,3]. Our patient had stayed at hospital for a total of 43 days and she was fully recovered 53 days after the implementation. Hemobilia has many reasons but the leading one is iatrogenic traumas [4–10].

We searched the literature, but we could not find PAIR as a cause of hemobilia. There was only one case, but in this report hemobilia because of PAIR was only stated at discussion [12]. There was no clear finding that hemobilia had occurred due to PAIR. Our case with recurrent hemobilia, infection in cyst cavity and pneumonia is the first case in literature.

PAIR in hydatid cyst treatment is superior to other modalities [1,3]. However, when complications occur, hospital stay prolongs [2], cost of the treatment increases and there can be mortal complications, as seen in our case. The complications seen in our case were accurately diagnosed and treated in our hospital.

Result

PAIR is a useful method and the major complications are very rare. Our case is a recurrent hemobilia patient because of PAIR. It should not be underestimated that there can be hemobilia and other mortal complications because of PAIR. Therefore, PAIR should only be performed in centers with appropriate medical and surgical modalities.

Competing interests

The authors declare that they have no competing interests.

Consent

Written informed consent was obtained from the patient for publication of this Case report and any accompanying images. A copy of the written consent is available for review by the Editor-in-Chief of this journal.

Authors' contributions

Ö. Karahan carried out the ERCP procedures and followed the case, participated in the sequence alignment and drafted the manuscript.

B. Sevinç participated in the sequence alignment and drafted the manuscript.

S. Bakdik participated in the sequence alignment.

N. Aksoy participated in the design of the study and participated in the sequence alignment.

M.A. Eryilmaz conceived of the study, and participated in its design and coordination and helped to draft the manuscript. All authors read and approved the final manuscript.

References

- [1] O. Akhan, M.N. Ozmen, Percutaneous treatment of liver hydatid cysts, *Eur. J. Radiol.* 32 (1999) 76–85.
- [2] N. Örmeci, I. Soykan, A. Bektaş, et al., A new percutaneous approach for the treatment of hydatid cysts of the liver, *Am. J. Gastroenterol.* 96 (2001) 2225–2230.
- [3] B. Üstünsöz, O. Akhan, M.A. Kamiloğlu, et al., Percutaneous treatment of hydatid cyst: long-term results, *AJR* 172 (1999) 91–96.
- [4] P. Sandblom, F. Saegesser, V. Mirkovitch, Hepatic haemobilia: haemorrhage from the intrahepatic biliary tract, a review, *World J. Surg.* 8 (1984) 41–50.
- [5] D.V. Sreenivas, C. Bharavi, F. Anjum, et al., Spontaneous hemobilia in a hemophiliac treated by factor VIII replacement and nasobiliary drainage, *Digest. Dis. Sci.* 43 (1998) 2606–2609.
- [6] Y.-E. Joo, H.-S. Kim, S.-K.I. Cho, et al., Hemobilia caused by liver abscess due to intrahepatic duct stones, *J. Gastroenterol.* 38 (2003) 507–511.
- [7] M. Tola, M. Yurdakul, T. Cumhuri, et al., Treatment of laparoscopic cholecystectomy complication of hemobilia by selective arterial embolization, *Turk. J. Gastroenterol.* 12 (2001) 308–310.
- [8] J.M. Dobbins, P.M. Rao, R.A. Novelline, Posttraumatic hemobilia, *Emerg. Radiol.* 4 (1997) 180–183.
- [9] Z. Yazıcı, G. Savcı, M. Parlak, E. Tuncel, Polyarteritis nodosa presenting with hemobilia and intestinal hemorrhage, *Eur. Radiol.* 7 (1997) 1059–1061.
- [10] H. Rhim, H.K. Lim, Y.-S. Kim, et al., Hemobilia after radiofrequency ablation of hepatocellular carcinoma, *Abdom. Imaging* 32 (2007) 719–724.
- [11] R.A. Smego, P. Sebanego, Treatment options for hepatic cyst echinococcosis, *Int. J. Infect. Dis.* 9 (2005) 69–76.
- [12] S. Gruttadauria, A. Luca, D. Cintorino, et al., Hepatic hydatid cyst causing thrombosis of the inferior vena cava and complicated by hemobilia: a multimodal sequential approach in the treatment, *Digest. Dis. Sci.* 48 (2003) 358–364.
- [13] D.N. Srivastava, S. Sharma, S. Pal, et al., Transcatheter arterial embolization in the management of hemobilia, *Abdom. Imaging* 31 (2006) 439–448.

Open Access

This article is published Open Access at scimedirect.com. It is distributed under the [IJSCR Supplemental terms and conditions](#), which permits unrestricted non commercial use, distribution, and reproduction in any medium, provided the original authors and source are credited.