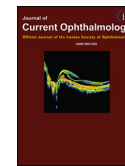


Available online at [www.sciencedirect.com](http://www.sciencedirect.com)**ScienceDirect**

Journal of Current Ophthalmology 28 (2016) 199–205

<http://www.journals.elsevier.com/journal-of-current-ophthalmology>

Original research

# Outcomes of vitrectomy, membranectomy and internal limiting membrane peeling in patients with refractory diabetic macular edema and non-tractional epiretinal membrane

Fariba Ghassemi <sup>a</sup>, Fatemeh Bazvand <sup>a</sup>, Ramak Roohipoor <sup>a</sup>, Mehdi Yaseri <sup>b</sup>, Narges Hassanpoor <sup>a</sup>,  
Mohammad Zarei <sup>a,\*</sup><sup>a</sup> Eye Research Center, Farabi Eye Hospital, Tehran University of Medical Sciences, Iran<sup>b</sup> Department of Epidemiology and Biostatistics, School of Public Health, Tehran University of Medical Sciences, Iran

Received 10 March 2016; accepted 2 August 2016

Available online 27 August 2016

## Abstract

**Purpose:** To evaluate the efficacy of vitrectomy, membranectomy, and internal limiting membrane (ILM) peeling on macular thickness and best corrected visual acuity (BCVA) in patients with refractory diffuse diabetic macular edema (DME) and non-tractional epiretinal membrane (NT-ERM).

**Methods:** This prospective interventional case series included eyes with refractory DME (central subfield macular thickness [CSMT] > 300 μm) after at least two intravitreal injections of bevacizumab (IVB) and one intravitreal injection of triamcinolone (IVT), and accompanying NT-ERM. Complete ophthalmic examination, baseline spectral domain optical coherence tomography (SD-OCT), and fluorescein angiography (FA) were performed prior to 23 gauge pars plana vitrectomy with membranectomy and internal limiting membrane (ILM) peeling. Postoperative evaluation was done with clinical examination and SD-OCT. Linear mix model analysis was used to study postoperative results.

**Results:** Twelve eyes from 11 patients (5 males) with a mean age of 60.33 ± 9.01 (range 46–73 years) were included. The mean follow-up time was 13.5 ± 4.48 months (range 4–20 months). A significant reduction in CSMT was found (from 559 ± 89 μm to 354 ± 76 μm; P = 0.001), with a non-significant BCVA change (from 0.84 ± 0.32 logMAR to 0.72 ± 0.2 logMAR; P = 0.967). There was no significant correlation between CSMT and BCVA (partial correlation = -0.115, P = 0.445) and also between estimated mean CSMT change per month and estimated mean BCVA change per month (r = 0.337, P = 0.283).

**Conclusion:** In this series, our results did not show that vitrectomy, membranectomy, and ILM peeling result in significant improvement of BCVA in eyes with refractory DME and non-tractional ERM in spite of central macular thickness reduction.

Copyright © 2016, Iranian Society of Ophthalmology. Production and hosting by Elsevier B.V. This is an open access article under the CC BY-NC-ND license (<http://creativecommons.org/licenses/by-nc-nd/4.0/>).

**Keywords:** Refractory diabetic macular edema; Epiretinal membrane; Vitrectomy; Internal limiting membrane

Founding source: There are no founding sources to report.

Financial disclosure: No authors have relevant financial relationship to disclose.

Conflict of interests: None of the authors have any proprietary interests or conflicts of interest related to this submission.

\* Correspondence author. Eye Research Center, Farabi Eye Hospital, Qazvin Square, South Kargar Street, Tehran 1336616351, Iran.

E-mail address: [mzareiran@yahoo.com](mailto:mzareiran@yahoo.com) (M. Zarei).

Peer review under responsibility of the Iranian Society of Ophthalmology.

<http://dx.doi.org/10.1016/j.joco.2016.08.006>

2452-2325/Copyright © 2016, Iranian Society of Ophthalmology. Production and hosting by Elsevier B.V. This is an open access article under the CC BY-NC-ND license (<http://creativecommons.org/licenses/by-nc-nd/4.0/>).

## Introduction

In diabetes mellitus, impairment of inner and outer blood retinal barriers may lead to macular edema and subsequent visual loss.<sup>1</sup> There is a high prevalence of visually significant macular edema in patients with diabetes mellitus, and it can be progressive.<sup>2,3</sup> Diabetic macular edema (DME) has been classified into focal and diffuse types, the latter considered less responsive to laser treatment.<sup>1,4,5</sup>

Currently available options in management of DME are metabolic control, macular photocoagulation (MPC), intravitreal administration of corticosteroids or anti vascular endothelial growth factor (VEGF) agents, and various combinations of these methods.<sup>4,6–8</sup> However, some cases of DME are refractory to these interventions.<sup>9</sup> In some patients, a mechanical component via vitreomacular traction (VMT) or tractional epiretinal membrane (T-ERM) may contribute to pathogenesis of DME. In such cases, performing vitrectomy and surgical relieving of mechanical traction has been suggested as an effective treatment for DME.<sup>10</sup>

In patients with no demonstrable tractional component, the role of vitrectomy is more controversial.<sup>1,11–14</sup> Some authors have suggested that internal limiting membrane (ILM) is an important contributing factor in the development of DME; therefore, vitrectomy with ILM peeling may have a role in treatment of cases with refractory DME without apparent traction by improving oxygenation of the retina and relieving “subtle” traction on the retinal surface.<sup>1,11–13</sup> In these studies, anatomical outcomes are generally promising, but visual outcomes are varied.<sup>1,11,12,14</sup>

There is another group of patients with refractory DME who have an ERM over macula without clinical or OCT evidence of mechanical traction (non-tractional ERM: NT-ERM). The results of vitrectomy in patients with refractory DME and

NT-ERM are not clearly known. The aim of this study was to investigate the potential role of surgical treatment in these patients.

## Methods

This non-comparative prospective interventional case series was conducted from September 2012 to March 2015. Tenets of the Helsinki Declaration were followed. Informed consent was obtained from all patients.

Fluorescein angiography (FA) was performed for all eyes, and eyes with proliferative diabetic retinopathy or non-regressed proliferative diabetic retinopathy were treated with panretinal photocoagulation prior to entering the study.

The inclusion criteria were presence of refractory diffuse DME and a NT-ERM. Refractory DME was defined as central subfield macular thickness (CSMT) > 300  $\mu\text{m}$  as measured by spectral domain optical coherence tomography (SD-OCT) (Spectralis, Heidelberg Engineering, Germany) despite glycemic control (hemoglobin A1C of 7.0% or lower) after at least two monthly intravitreal injection of 1.25 mg bevacizumab (IVB) with at least one simultaneous intravitreal injection of 1 mg triamcinolone acetonide (IVT).

The ERM was defined as a highly reflective membrane at the vitreomacular interface on SD-OCT. Only eyes with foveal involvement of ERM were included. NT-ERM was defined as the presence of an ERM in SD-OCT horizontal raster scans uniformly attached to macula without visible tautness or retinal striae on vitreomacular interface in biomicroscopic examination, points of focal attachment or tentings of the underlying inner surface of the retina in SD-OCT images (Fig. 1). If there was any step-off in retinal thickness at the borders of the membrane-retinal attachment area, the ERM was considered tractional.

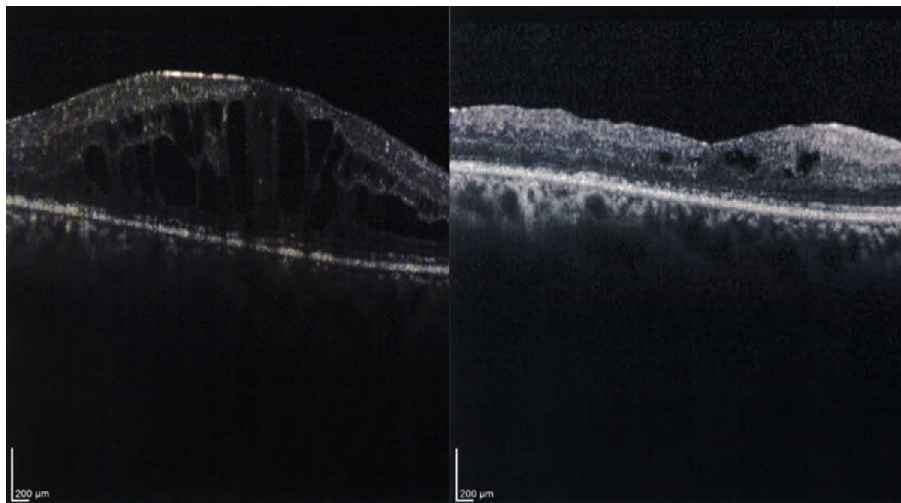


Fig. 1. Left: Preoperative horizontal OCT scan showing properties of “non-tractional ERM (NT-ERM)”: an ERM in SD-OCT images uniformly attached to macula without visible tautness or retinal striae in biomicroscopic examination, points of focal attachment or tentings of the underlying inner surface of the retina”. Right: The same eye 9 months following vitrectomy, membranectomy, and internal limiting membrane peeling. Despite reduction in thickness, intraretinal cystoid spaces can be seen.

Patients with any uncontrolled ocular disease (other than DME or cataract), angiographic macular ischemia, presence of any systemic condition that was associated with unacceptably high surgical risks, occurrence of any major perioperative complication, and loss to follow-up visits in the first three postoperative months were excluded. Major perioperative complications were those with significant visual consequences: vitreous loss in combined phaco-vitreotomy procedures, iatrogenic insult to macula or optic nerve, endophthalmitis, significant intraoperative/early postoperative choroidal effusion/hemorrhage, significant intraoperative/early postoperative vitreous cavity hemorrhage, intraoperative/early postoperative retinal detachment. In case of later occurrence of conditions not directly related to DME but with significant visual consequences, data attributed to periods following these events were not used. Ophthalmic examinations including refraction, best corrected visual acuity (BCVA) assessment (Snellen visual acuity and equivalent logarithm of the minimum angle of resolution (logMAR), applanation tonometry, and funduscopy were done for all patients. Baseline SD-OCT and FA were performed for all patients. Complete ocular examination and SD-OCT were repeated in each follow-up visit.

#### Method of surgery

All operations were performed by one surgeon (M.Z.). Under local or general anesthesia, a 3-port 23-gauge triamcinolone acetate assisted pars plana vitrectomy was done. If visually significant cataract was present, phacoemulsification with implantation of intraocular lens in capsular bag was performed prior to vitrectomy. Following epiretinal membrane removal and staining with brilliant blue G (MembraneBlue Dual, D.O.R.C. International), arcade-to-arcade ILM peeling was performed. In case of peripheral retinal breaks following laser treatment, air or SF6 tamponade was used. None of the cases received periocular injection of long acting steroids at the end of surgery.

#### Statistical analysis

The analysis of data was performed using SPSS software version 16.0. All data was reported with mean  $\pm$  SD. Data did not have normal distribution. Due to factors which were not controllable by authors, the time interval between follow-up visits and length of follow-up periods were not the same for all patients. Considering these, we used linear mixed model to analyze changes in BCVA and CSMT throughout the study. As there was no extreme outlier in quantitative data, we reported “mean” which for clinicians is more tangible than “median”. P values  $< 0.05$  were considered statistically significant.

#### Results

Fourteen eyes from 13 patients were entered in this study. Two patients were missed to follow-up after first postoperative month. Data from the remaining twelve eyes (5 males) with a mean age of  $60.33 \pm 9.01$  (range:46–73) years were used. All eyes had clear evidence of diabetic retinopathy. Demographic data are summarized in Table 1. The mean follow-up duration was  $13.5 \pm 4.48$  (range: 4 to 20) months. Microstructural pattern of DME was cystoid type in 5 eyes, spongy-cystoid in 4 eyes, and cystoid-subretinal fluid in 3 eyes. Two eyes (No. 8 and No. 11) had juxtafoveal exudates. Severe retinal ischemia outside the macula was detected on FA in all eyes. Before entering the study, patients had received a mean of  $5.58 \pm 3.50$  (range: 2–14) IVB and a mean of  $1.75 \pm 0.62$  (range: 1–3) IVT injections. No intravitreal injections were administered during follow-up period. Two eyes were pseudophakic. Combined phacoemulsification-vitreotomy was performed for 3 eyes (eye Nos. 9, 11, and 12). The remaining seven eyes had no significant cataracts initially, but 5 of them needed cataract surgery throughout the study with a mean time interval between vitrectomy and cataract extraction of  $10.80 \pm 2.58$  (range: 7–14) months. In three eyes, a subtle recurrent ERM was detected over the fovea at postoperative months 7, 11 and 13; recurrent ERMs were very fine

Table 1  
Demographic and clinical data of patients with refractory diabetic macular edema and non-tractional ERM.

NO of eye	Gender/age	Involved eye	Diabetic retinopathy	Number of IVB	Number of IVT	Follow up visits (post-operative months)	Baseline CSMT ( $\mu$ m)	Final CSMT ( $\mu$ m)	Baseline BCVA (logMAR)	Final BCVA (logMAR)
1	M/70	OS	Severe NPDR	4	2	1,5,13,15	531	318	0.52	0.69
2	M/71	OS	Severe NPDR	4	1	1,5,9,18	609	196	0.69	1
3	M/62	OD	Regressed PDR	5	2	1,3,7,17	445	397	0.52	0.69
4	F/56	OD	Regressed PDR	7	1	1,5,9,13	645	367	0.69	0.52
5	F/46	OD	Regressed PDR	4	1	1,4,7,9	514	312	1	0.69
6	F/50	OD	Regressed PDR	14	2	1,4,6,11,14,17,20	623	442	1.52	0.69
7	F/50	OS	Severe NPDR	11	2	2,7,10,12,17	714	237	0.69	0.82
8	F/66	OS	Severe NPDR	3	2	3,10,13	454	357	1	1
9	F/57	OS	Regressed PDR	4	2	1,3,9	495	431	1.30	1
10	M/73	OS	Moderate NPDR	4	2	3,11,13	595	373	0.69	0.52
11	F/66	OS	Regressed PDR	5	3	7,9,10,14	637	366	0.52	1
12	M/57	OS	Severe NPDR	2	1	1,4	449	307	1	0.69

NO: number, IVB: intravitreal bevacizumab, IVT: intravitreal triamcinolone, CSMT: central subfield macular thickness, BCVA: best corrected visual acuity, F: female, M: male, OD: oculus dexter, OS: oculus sinister,  $\mu$ m: micrometer, logMAR: logarithm of minimum angle of resolution, PDR: proliferative diabetic retinopathy, NPDR: non-proliferative diabetic retinopathy.

hyperreflective, interrupted lines on SD-OCT, and considered insignificant. In eye No. 5, full thickness macular hole and retinal detachment developed 11 months after vitrectomy, which was treated with repeat vitrectomy and silicone oil instillation. The last available data from this case before occurrence of retinal detachment (from postoperative month 9) were used for analysis. Mean BCVA (logMAR) changed from  $0.84 \pm 0.32$  at baseline (range: 0.52–1.52) to  $0.72 \pm 0.26$  at last visit (range: 0.10–1.00). Mean CSMT changed from  $559 \pm 89 \mu\text{m}$  at baseline (range: 445–714) to  $354 \pm 76 \mu\text{m}$  (range: 196–511) at last visit. Linear mixed model analysis showed a significant reduction in CSMT ( $P = 0.001$ ), and an insignificant trend of improvement in BCVA ( $P = 0.967$ ) were observed (Fig. 2). We found a mean decrease of  $83 \mu\text{m}$  per 10 months in CSMT (95% CI; range: 36 to 130) (Fig. 1). There was no statistically significant

correlation between change in CSMT and BCVA (partial correlation =  $-0.115$ ,  $P = 0.445$ ) (Fig. 2). Linear mixed model analysis also confirmed this result by showing that each  $1000 \mu\text{m}$  decrease in CSMT would correspond to 0.16 improvement in logMAR BCVA (95% CI: 0.08 to 1.21,  $P = 0.758$ ). The estimated mean CSMT change per month did not statistically significantly correlate with the estimated mean BCVA change per month ( $r = 0.337$ ,  $P = 0.283$ ) (Fig. 2).

At last follow-up visit, compared to baseline, three eyes gained 3 lines or more, and two eyes lost 3 lines or more of visual acuity.

## Discussion

DME is one of the main causes of visual loss in diabetic patients and may be refractory to conventional treatment.<sup>14</sup> In

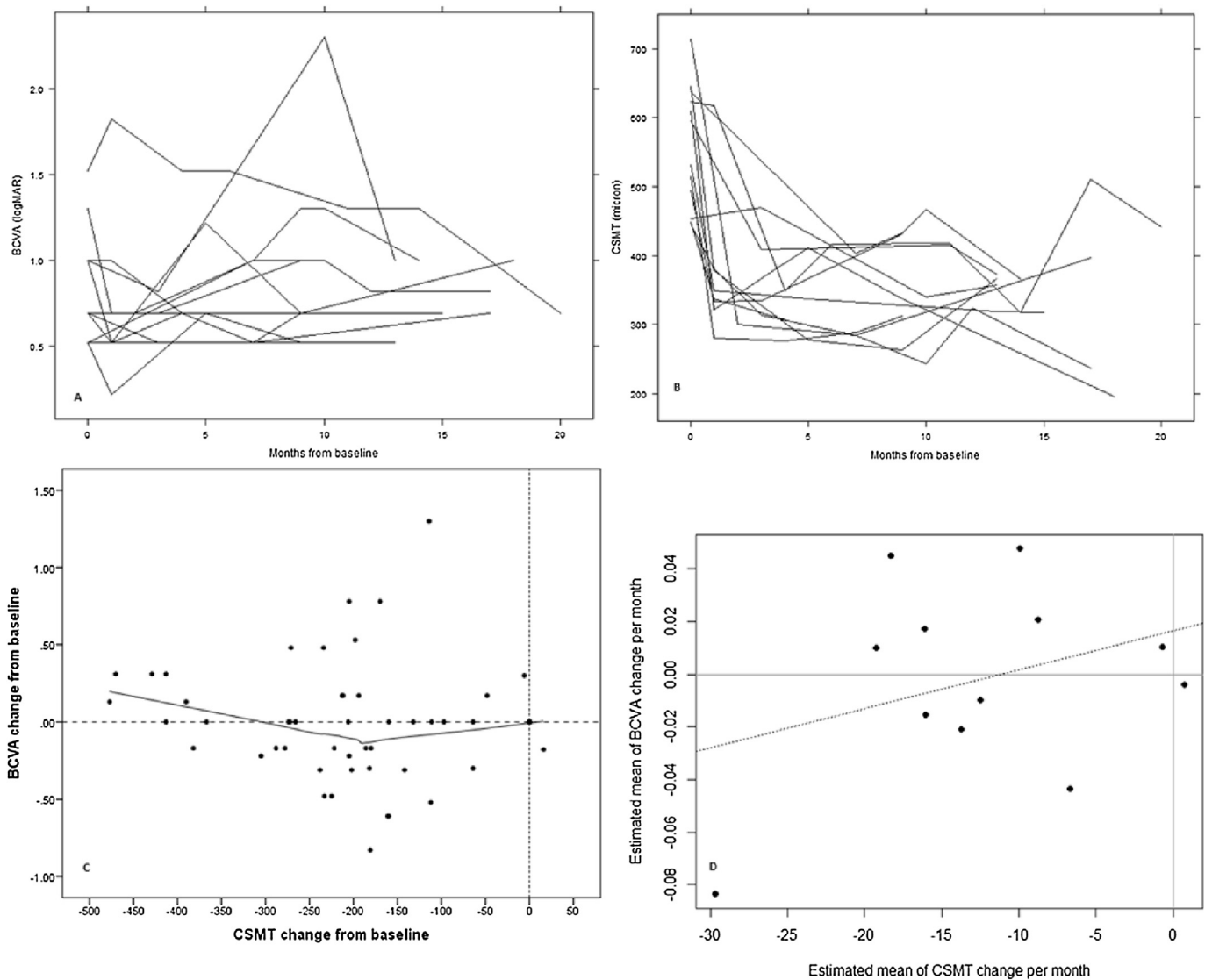


Fig. 2. Changes in best corrected visual acuity (BCVA) and central subfield macular thickness (CSMT) of the study eyes. Top left: line plot shows changes in BCVA ( $P = 0.967$ ; linear mixed model). Top right: line plot shows changes in CSMT ( $P = 0.001$ ; linear mixed model). Bottom left: scatter plot of correlation between change in CSMT and BCVA (partial correlation =  $-0.115$ ,  $P = 0.445$ ). Bottom right: Correlation between estimated mean CSMT change per month and estimated mean BCVA change per month ( $r = 0.337$ ,  $P = 0.283$ ).

patients with VMT or a tractional ERM, vitrectomy is recommended.<sup>10</sup>

The role of vitrectomy in cases of refractory DME without tractional component is more controversial.<sup>15–18</sup> Although some studies have suggested that ILM peeling may help obtain better results,<sup>15,16</sup> others have reported similar results by vitrectomy without ILM peeling.<sup>17,18</sup> Moreover, ILM removal has been suggested to have a role in preventing recurrence of ERM.<sup>1</sup>

The presence of an ERM does not necessarily mean that there is mechanical traction on macula. To confirm a tractional effect of an ERM on macula, visible retinal striae in biomicroscopic examination, OCT findings of multiple focal attachments or tentings of the underlying inner surface of the retina, and step-off in retinal thickness at the borders of membrane-retinal attachment area have all been suggested as evidences of traction.<sup>19</sup> In the absence of these signs, ERM may be considered non-tractional. The role of NT-ERMs in pathogenesis of DME is not clear. One may consider that NT-ERMs can contribute to DME development via hypothetical mechanisms including exerting subtle tractional forces beyond the sensitivity of current commercial SD-OCT technology or interference with nutrition or oxygenation of retina. However, the potential role of vitrectomy in these cases of refractory DME is unknown. To the best of the authors' knowledge, our study is the first to address this subject.

In this study, we performed vitrectomy with membranectomy and ILM peeling for patients with NT-ERM and refractory diffuse DME. In our experience, we had encountered some patients refractory to intravitreal anti-VEGF agents alone, but responsive to addition of intravitreal triamcinolone acetonide, sometimes with dramatic decreases in CSMT. Therefore, we decided that it would be necessary to try at least one intravitreal injection of triamcinolone acetonide before considering the cases "refractory".

After vitrectomy, a significant decline in CSMT was observed. Mean CSMT reduced from baseline  $559.25 \pm 89.65 \mu\text{m}$  to final  $354.91 \pm 76.41 \mu\text{m}$ . In comparison, we found a mean reduction of  $83 \mu\text{m}$  per 10 months in CSMT. Other studies reported similar results for vitrectomy in patients with refractory DME and no vitreomacular interface abnormality.<sup>1,20</sup> Kim et al<sup>20</sup> performed vitrectomy in combination with IVT, and macular laser photocoagulation in DME patients with no ERM and reported a significant decrease in macular thickness from  $433.3 \pm 77.9 \mu\text{m}$  before surgery to  $310.1 \pm 80.1 \mu\text{m}$  6 months after procedure. They also noted a mild increase in thickness after postoperative month 3. They divided their patients into 2 groups including cases with DME refractory to conventional treatment (macular photocoagulation) and cases with DME refractory to anti-VEGF treatment, and found that the former group showed significantly more decline in thickness than the latter group. In another study, Kim et al<sup>21</sup> evaluated the efficacy of combined vitrectomy, IVT, and MPC on macular thickness and BCVA of 40 eyes with refractory DME with a long-term follow-up of 3 years. They reported a significant trend toward continuing decline in macular thickness during the 3 years after operation (reduction

from  $499.1 \pm 174.9 \mu\text{m}$  to  $219.4 \pm 66.6 \mu\text{m}$ ). Other studies<sup>1,22,23</sup> have found similar results regarding changes in macular thickness after vitrectomy. All these data support that vitrectomy is effective in reduction of macular thickness in cases of intractable DME. Although we found no previous studies addressing anatomical results of vitrectomy in refractory DME and NT-ERM, anatomical outcomes in our study are comparable with results of studies on vitrectomy in refractory DME with no vitreomacular interface abnormality.

Reports on the effect of vitrectomy on BCVA are more heterogenous. We found no previous study addressing visual results of vitrectomy in refractory DME with NT-ERM. We compared our results with studies addressing vitrectomy in refractory DME without vitreomacular interface abnormality. Our data showed an insignificant BCVA improvement in the last follow-up comparable to reported results by Dehghan et al who reported an insignificant improvement from  $1.00 \pm 0.80 \log\text{MAR}$  to  $0.82 \pm 0.18 \log\text{MAR}$ .<sup>1</sup> This is in contradiction with results from the study of Kim et al<sup>20</sup> which reported a significant improvement in BCVA (from  $0.44 \pm 0.15 \log\text{MAR}$  to  $0.34 \pm 0.22 \log\text{MAR}$  at 6 months). They found mild reduction in BCVA after 3 months and attributed it to cataract progression. Considering these discrepancies, two points are noteworthy. First, baseline mean BCVA in the study by Kim et al<sup>20</sup> was considerably better than ours and the study by Dehghan et al. Second, the number of recruited eyes in the study by Kim et al (28 eyes) was more than our study (12 eyes) and the study by Dehghan et al<sup>1</sup> (12 eyes). These differences may explain different results, at least partially. However, significant improvement of BCVA has been reported by other studies<sup>21–23</sup> with baseline mean BCVAs worse than the aforementioned study by Kim et al and by a study<sup>23</sup> with a number of participants comparable to our study. Moreover, Rosenblatt et al have found worse baseline visual acuity as the only clinical variable that is associated with improvement in postoperative visual acuity.<sup>22</sup> Therefore, other factors such as differences in inclusion criteria, previous treatments, degree of chronicity, macular ischemia, and diabetic retinopathy may contribute to literature discrepancy.<sup>1</sup> Two eyes (No. 8 and No. 11) in our study had juxtafoveal exudates which are reported to be an indicator of poorer visual prognosis.<sup>24</sup>

When designing this study, partly based on ethical reasons, the authors decided to perform combined phaco-vitrectomy surgery only when there was a visually significant cataract at the entry of the study. Post-vitrectomy cataract development might be considered as one of the confounding factors in analysis of our data. Only two eyes of seven phakic eyes that had not had cataract extraction at first did not need cataract extraction at the end of study. Considering that one of these two developed retinal detachment at follow-up month 11 and was therefore excluded from the study afterward, it seems reasonable to conclude that the vast majority of phakic eyes would eventually need cataract surgery following vitrectomy. This is in accordance with other studies.<sup>21,25</sup> The improvement of visual acuity may partly be secondary to removing the cataract in some eyes.

Another factor that may limit visual improvement in spite of decreased macular thickness is macular ischemia. Although we excluded patients with macular ischemia from our study, it should be noted that in patients with chronic DME, extensive macular fluorescein leakage can make the diagnosis of macular ischemia very difficult. On the other hand, all our patients showed severe ischemia outside the macula. It is hard to rule out macular ischemia when nearby retina shows severe capillary non-perfusion. Authors think that undiagnosed macular ischemia may have an important role in limiting visual improvement despite anatomic improvement. New imaging tools like optical coherence tomography angiography (OCTA) may help to identify capillary non-perfusion in these circumstances more accurately.

Preventing of postoperative ERM formation has been suggested as an advantage of ILM peeling.<sup>1</sup> Although we observed subtle evidence of recurrent ERM in 3 eyes at 7, 11, and 13 months after the first operation, these membranes were not clinically significant and barely detectable.

There was no statistically significant correlation between change in CSMT and BCVA. The correlation of estimated mean CSMT change per month and estimated mean BCVA change per month was not statistically significant. This inconsistency between macular thickness and BCVA might reflect the permanent damage to the retinal tissue, especially photoreceptors due to ischemia and long-term inflammatory process. Various inflammatory factors such as cytokines and VEGF have been introduced as causative factors of DME.<sup>26,27</sup>

It is well known that ERM can lead to macular edema, regardless of presence of diabetes. Although development of an idiopathic ERM in a diabetic patient cannot be completely ruled out, we believe that ERMs in our patients were secondary to diabetic ocular disease because all eyes had clear evidence of diabetic retinopathy. It should be noted that there is currently no practical way to differentiate a severely thickened ILM from a NT-ERM in SD-OCT, and our definition of NT-ERM in this study was based on SD-OCT findings.

“Taut posterior hyaloids face” is another entity that may be confused with NT-ERM. In 1992, Lewis et al observed that vitrectomy can improve visual prognosis in some eyes with DME and macular traction. They introduced the term “taut posterior hyaloid” to describe the clinically observed alteration of the vitreoretinal interface in some patients who benefit from vitrectomy.<sup>28</sup> Since then, there have been similar reports on the beneficial effects of vitrectomy in these patients.<sup>29,30</sup> The term “taut posterior hyaloid” has been used in literature to describe the clinical finding of “thickening and traction of posterior hyaloid membrane”<sup>29</sup> or “premacular posterior hyaloid which was attached and appeared taut”.<sup>30</sup> Recently, this term has been used much less commonly than previous years, probably due to increasingly sensitive OCT devices, which can define characteristics of vitreomacular interface much more precisely, compared to clinical examinations. However, the main feature of a “taut posterior hyaloid” is visible evidence of traction or tautness in clinical exam. On the other hand, a prerequisite of defining a membrane as “NT-ERM” is lack

of any visible evidence of traction or tautness in clinical examination.

The small number of eyes is the major limitation of our study which was at least partly due to strict inclusion criteria. Heterogeneous follow-up schedules were another important limitation. We tried to minimize the detrimental effect of this limitation by using linear mixed model to analyze our data. Also, we did not have a control group of patients treated with alternative modalities.

The definition of refractory DME differs in various studies. In older studies refractory or persistent DME is defined based on response to macular laser photocoagulation.<sup>23,31</sup> After introducing anti VEGF agent, new definitions of refractory DME were used. For example, in the study by Yuksel et al on the role of intravitreal bevacizumab in refractory DME, cases with central foveal thickness >300  $\mu\text{m}$  following at least one previous focal laser photocoagulation with or without an intravitreal or subtenon injection of triamcinolone acetonide was considered to have refractory DME.<sup>32</sup> This heterogeneity in defining refractory DME is reflected in recent studies.<sup>33–35</sup> Recently, Hussain et al have found that there are no standard protocols for defining ‘treatment failure’.<sup>36</sup> It seems that there is no consensus on the definition of refractory DME and this should be considered when comparing outcomes of various studies.

In conclusion, our study showed that vitrectomy with membranectomy and ILM peeling cannot statistically significantly improve BCVA despite reducing central macular thickness in eyes with refractory DME and non-tractional ERM. However, we cannot generalize this conclusion to eyes in earlier stages and less protracted course. Based on similarities in anatomical and visual outcomes, we think that in patients with non-tractional ERM, pathogenesis of refractory DME is more similar to the pathogenesis of refractory DME in patients without vitreomacular interface abnormalities rather than patients with tractional vitreoretinal interface abnormalities. Future studies with a long-term follow-up, larger population size, proper control group, and more homogenous follow-up schedules may help to further elucidate the contribution of non-tractional ERM in the pathogenesis of refractory DME and the role of vitrectomy in its treatment.

## References

1. Dehghan MH, Salehipour M, Naghib J, Babaeian M, Karimi S, Yaseri M. Pars plana vitrectomy with internal limiting membrane peeling for refractory diffuse diabetic macular edema. *J Ophthalmic Vis Res.* 2010;5(3): 162–167.
2. Clark JB, Grey RH, Lim KK, Burns-Cox CJ. Loss of vision before ophthalmic referral in blind and partially sighted diabetics in Bristol. *Br J Ophthalmol.* 1994;78:741–744.
3. Klein R, Klein BE, Moss SE. Visual impairment in diabetes. *Ophthalmology.* 1984;91:1–9.
4. The Early Treatment Diabetic Retinopathy Study Research Group. Photocoagulation for diabetic macular edema. Early treatment diabetic retinopathy study report number 1. *Arch Ophthalmol.* 1985;103: 1796–1806.
5. McDonald HR, Schatz H. Grid photocoagulation for diffuse macular edema. *Retina.* 1985;5:65–72.

6. Jonas JB, Sofker A. Intraocular injection of crystalline cortisone as adjunctive treatment of diabetic macular edema. *Am J Ophthalmol*. 2001; 132:425–427.
7. Kang SW, Sa HS, Cho HY, Kim JI. Macular grid photocoagulation after intravitreal triamcinolone acetonide for diffuse diabetic macular edema. *Arch Ophthalmol*. 2006;124:653–658.
8. Chun DW, Heier JS, Topping TM, et al. A pilot study of multiple intravitreal injections of ranibizumab in patients with center-involving clinically significant diabetic macular edema. *Ophthalmology*. 2006;113: 1706–1712.
9. Massin P, Bandello F, Garweg JG, et al. Safety and efficacy of ranibizumab in diabetic macular edema (RESOLVE Study): a 12-month, randomized, controlled, double-masked, multicenter phase II study. *Diabetes Care*. 2010;33:2399–2405.
10. Haller JA, Qin H, Apte RS, et al. Vitrectomy outcomes in eyes with diabetic macular edema and vitreomacular traction. *Ophthalmology*. 2010; 117:1087–1093.
11. Figueroa MS, Contreras I, Noval S. Surgical and anatomical outcomes of pars plana vitrectomy for diffuse nontractional diabetic macular edema. *Retina*. 2008;28:420–426.
12. Kimura T, Kiryu J, Nishiwaki H, et al. Efficacy of surgical removal of the internal limiting membrane in diabetic cystoid macular edema. *Retina*. 2005;25:454–461.
13. Stefansson E. The therapeutic effects of retinal laser treatment and vitrectomy: a theory based on oxygen and vascular physiology. *Acta Ophthalmol Scand*. 2001;79:435–440.
14. Yamamoto T, Hitani K, Tsukahara I, et al. Early postoperative retinal thickness changes and complications after vitrectomy for diabetic macular edema. *Am J Ophthalmol*. 2003;135:14–19.
15. Gandorfer A, Messmer EM, Uibig MW, Kampik A. Resolution of diabetic macular edema after surgical removal of the posterior hyaloid and the inner limiting membrane. *Retina*. 2000;20:126–133.
16. Stefanitou M, Aspiotis M, Kalogeropoulos C, et al. Vitrectomy results for diffuse diabetic macular edema with and without inner limiting membrane removal. *Eur J Ophthalmol*. 2004;14(2):137–143.
17. Yamamoto T, Hitani K, Sato Y, Yamashita H, Takeuchi S. Vitrectomy for diabetic macular edema with and without internal limiting membrane removal. *Ophthalmologica*. 2005;219:206–213.
18. Kamura Y, Sato Y, Isomae T, Shimada H. Effects of internal limiting membrane peeling in vitrectomy on diabetic cystoid macular edema patients. *Jpn J Ophthalmol*. 2005;49:297–300.
19. Wiley HE, Ferris FL. Nonproliferative diabetic retinopathy and diabetic macular edema. In: Ryan SJ, ed. *Retina*. 5th ed. Los Angeles: Elsevier; 2013:951–953.
20. Kim JH, Kang SW, Ha HS, Kim JR. Vitrectomy combined with intravitreal triamcinolone acetonide injection and macular laser photocoagulation for nontractional diabetic macular edema. *Korean J Ophthalmol*. 2013;27(3):186–193.
21. Kim YT, Kang SW, Kim SJ, Kim SM, Chung SE. Combination of vitrectomy, IVTA, and laser photocoagulation for diabetic macular edema unresponsive to prior treatments; 3-year results. *Graefes Arch Clin Exp Ophthalmol*. 2012 May;250(5):679–684.
22. Rosenblatt BJ, Shah GK, Sharma S, Bakal J. Pars plana vitrectomy with internal limiting membranectomy for refractory diabetic macular edema without a taut posterior hyaloid. *Graefes Arch Clin Exp Ophthalmol*. 2005 Jan;243(1):20–25.
23. Recchia FM, Ruby AJ, Carvalho Recchia CA. Pars plana vitrectomy with removal of the internal limiting membrane in the treatment of persistent diabetic macular edema. *Am J Ophthalmol*. 2005 Mar;139(3): 447–454.
24. Kumagai K, Furukawa M, Ogino N, et al. Long-term follow-up of vitrectomy for diffuse nontractional diabetic macular edema. *Retina*. 2009; 29:464–472.
25. Grigorian R, Bhagat N, Lanzetta P, Tutela A, Zarbin M. Pars plana vitrectomy for refractory diabetic macular edema. *Semin Ophthalmol*. 2003; 18(3):116–120.
26. Adamis AP, Miller JW, Bernal MT, et al. Increased vascular endothelial growth factor levels in the vitreous of eyes with proliferative diabetic retinopathy. *Am J Ophthalmol*. 1994;118:445–450.
27. Antcliff RJ, Marshall J. The pathogenesis of edema in diabetic maculopathy. *Semin Ophthalmol*. 1999;14:223–232.
28. Lewis H, Abrams GW, Blumenkranz MS, Campo RV. Vitrectomy for diabetic macular traction and edema associated with posterior hyaloidal traction. *Ophthalmology*. 1992;99(5):753–759.
29. Harbour JW, Smiddy WE, Flynn Jr HW, Rubsamen PE. Vitrectomy for refractory diabetic edema associated with a thickened and taut posterior hyaloid membrane. *Am J Ophthalmol*. 1996;121(4):405–413.
30. Pendergast SD, Hassan TS, Williams GA, et al. Vitrectomy for diffuse diabetic macular edema associated with a taut premacular posterior hyaloid. *Am J Ophthalmol*. 2000;130(2):178–186.
31. Martidis A, Duker JS, Greenberg PB, et al. Intravitreal triamcinolone for refractory diabetic macular edema. *Ophthalmology*. 2002;109(5): 920–927.
32. Yuksel E, Ozdek S, Yuksel N, Hasanreisoglu B. Intravitreal bevacizumab treatment for refractory diabetic macular edema. *Int Ophthalmol*. 2013; 33(6):659–663.
33. Lee DH, Kim YJ, Yoon YH. Minimally invasive microincision vitrectomy surgery with an intraoperative dexamethasone implant for refractory diabetic macular edema. *Ophthalmologica*. 2016;235(3):150–156.
34. Kim M, Cho YJ, Lee CH, Lee SC. Effect of intravitreal dexamethasone implant on retinal and choroidal thickness in refractory diabetic macular oedema after multiple anti-VEGF injections. *Eye*. 2016;30(5): 718–725.
35. Bansal P, Gupta V, Gupta A, Dogra MR, Ram J. Efficacy of Ozurdex implant in recalcitrant diabetic macular edema—a single-center experience. *Int Ophthalmol*. 2016;36(2):207–216.
36. Hussain RM, Ciulla TA. Treatment strategies for refractory diabetic macular edema: switching anti-VEGF treatments, adopting corticosteroid-based treatments, and combination therapy. *Expert Opin Biol Ther*. 2016; 16(3):365–374.