

## CASE REPORT

# Complete remission of a periorbital dermatofibrosarcoma protuberans with adjuvant imatinib mesylate in a child

Hsi Yen, MD,<sup>a</sup> Shin-Chen Pan, MD, PhD,<sup>b</sup> Chien-Hun Huang, MD,<sup>a</sup> and Tak-Wah Wong, MD, PhD<sup>a,c</sup>  
Tainan, Taiwan

**Key words:** Bednar tumor; dermatofibrosarcoma protuberans; imatinib mesylate; pediatric; target therapy; tyrosine kinase inhibitor.

**D**ermatofibrosarcoma protuberans (DFSP) is a rare soft-tissue neoplasm in children with low-grade malignant potential; metastasis is rare but there is risk of local recurrence after treatment.<sup>1</sup> An adequate surgical tumor-free margin is vital for long-term outcome and survival after wide excision or Mohs micrographic surgery.<sup>1</sup> However, such surgeries may result in severe functional and cosmetic defects at anatomically critical areas. Neoadjuvant or adjuvant imatinib mesylate therapy may help control tumor progression, but treatment experience in pediatric DFSP is limited to case reports and there is no established treatment protocol. We report a toddler boy with a DFSP near his left eye treated with adjuvant imatinib mesylate after an inadequate postoperative tumor-free margin.

## CASE REPORT

A 22-month-old Taiwanese boy presented with an asymptomatic bluish nodule measuring 0.6 × 0.4 cm over the nasal root near the left medial canthus. Not present at birth, the nodule was first noted by his parents when he was 11 months old with discoloration but no discomfort was reported. Infantile hemangioma was diagnosed and regular follow-up advised. The tumor grew to 1.0 × 0.6 cm in the following 8 months (Fig 1, A) and he was referred to a plastic surgeon for tumor excision. Histopathology revealed Bednar tumor, a pigmented variant of DFSP. An adequate tumor-free margin (2–4 cm) without mutilation was impossible because

of the sensitive nature of tumor location. He subsequently received a wider tumor excision and reconstruction with cheek flap advancement. The re-excision margin was designed to be 2 to 3 mm around the initial excision scar and 1 mm near the nasal side wall for preservation of the nasal canaliculi. The final histopathological postoperative tumor-free margins were 1 mm peripherally around the tumor and 3 mm deep. Postoperative radiation therapy was not recommended because it could affect normal bone growth and lead to face deformity. Treatment was started with imatinib mesylate, a tyrosine kinase inhibitor, at a dose of 430 mg/m<sup>2</sup>/d. The dose was tapered to 280 mg/m<sup>2</sup>/d 4 weeks later because of poor appetite. No other significant side effects were noted. Six months and 20 months after initiating imatinib, magnetic resonance images of the head revealed no evidence of recurrence. He received imatinib daily for a total of 18 months and remained disease free at 23 months' follow-up. Physical examination revealed a soft, healing surgical scar without any signs of local recurrence (Fig 1, B).

## DISCUSSION

Early diagnosis of pediatric DFSP is critical to minimize surgical disfiguration. However, definite diagnosis is usually difficult in neonates or infants with congenital DFSP because of its diverse presentation in childhood. The tumor may clinically mimic a vascular birthmark, vascular tumor, morphea, a

From the Department of Dermatology,<sup>a</sup> Section of Plastic and Reconstructive Surgery, Department of Surgery,<sup>b</sup> and Department of Biochemistry and Molecular Biology,<sup>c</sup> National Cheng Kung University Medical College and Hospital.

Supported by the Ministry of Science and Technology, Taiwan (MOST103-2314-B-006-024; Dr Wong).

Conflicts of interest: None declared.

Correspondence to: Tak-Wah Wong, MD, PhD, Department of Dermatology, Department of Biochemistry and Molecular Biology, National Cheng Kung University Medical College and

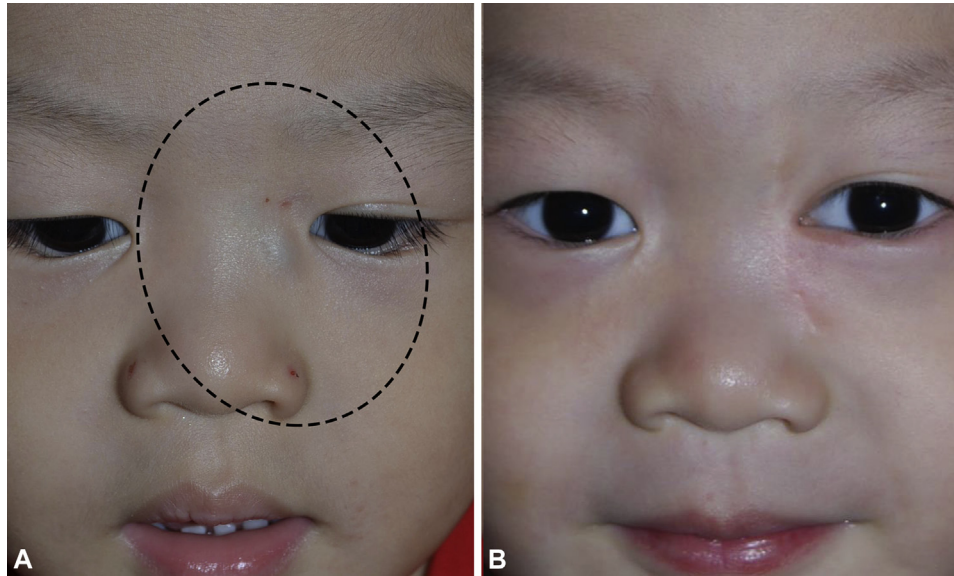
Hospital, 138 Sheng-Li Road, Tainan, Taiwan 704. E-mail: [tw Wong@mail.ncku.edu.tw](mailto:tw Wong@mail.ncku.edu.tw).

JAAD Case Reports 2015;1:172-4.

2352-5126

© 2015 by the American Academy of Dermatology, Inc. Published by Elsevier, Inc. This is an open access article under the CC BY-NC-ND license (<http://creativecommons.org/licenses/by-nc-nd/4.0/>).

<http://dx.doi.org/10.1016/j.jidcr.2015.04.003>



**Fig 1.** A bluish tumor located on the left medial canthus region in a 22-month-old boy that was proved as dermatofibrosarcoma protuberans histopathologically. **A**, Even a minimal 2-cm surgical tumor-free margin (*dashed line*) would result in severe disfigurement. **B**, There was no tumor recurrence at 23 months' follow-up with 18 months of adjuvant daily oral imatinib, a tyrosine kinase inhibitor.

hamartoma, dermoid cyst, or other entities in its early stages.<sup>2</sup> A histopathological tumor-free surgical margin is the most important prognostic factor in patients with DFSP. In a series of 159 patients, local recurrence rate was 18% in patients with positive or close (<1 mm) margins versus 3% in patients with negative margins at a median follow-up of 57 months.<sup>3</sup> According to the National Comprehensive Cancer Network guideline, resection with 2- to 4-cm margins to the depth of muscular fascia or pericranium is recommended when clinically feasible, although some experts recommend 1- to 2-cm margins in children younger than 5 years.<sup>4,5</sup> The overall prognosis of pediatric DFSP is excellent with adequate free surgical margin. Of the 166 cases reported with available follow-up data, only 1 patient died of aggressive local recurrence.<sup>5</sup> Nevertheless, without adjuvant therapy the 1-mm tumor-free margin near the eye poses a theoretical local recurrence rate of 3% to 18% in our case.

Most pediatric DFSPs, like their adult counterparts, are characterized by a distinctive gene rearrangement that fuses collagen type I $\alpha$ 1 chain gene of chromosome 17 with platelet-derived growth factor  $\beta$ -chain gene (PDGFB) of chromosome 22, up-regulating the PDGFB receptor tyrosine kinase and stimulating tumor growth and malignant transformation.<sup>6</sup> Imatinib mesylate, an adenosine triphosphate analog, competitively inhibits the binding site of the PDGFB receptor.<sup>6</sup> Although imatinib

has been demonstrated to achieve a response in 65% of reported adult cases, its effectiveness in pediatric DFSP remains in the investigational phase because of limited studies.<sup>7</sup> Only 5 cases have been reported (Table I) in the English-language literature. Nevertheless, initial results are encouraging, although doses and duration of therapy have not been standardized. Polymerase chain reaction has been used for molecular diagnosis in DFSP, and although polymerase chain reaction was not performed in our patient, the collagen type I $\alpha$ 1 chain gene-PDGFB fusion was assumed to be positive in this case given the 100% positive rate reported in another study using sensitive multiplex reverse transcription polymerase chain reaction screening of DFSP.<sup>8</sup> Gooskens et al<sup>5</sup> suggested using this molecular marker as a guide for postoperative imatinib therapy decision-making to assure continuous remission. In their case series, they found gene fusion in all 3 resected pediatric DFSP tumor tissues that had been treated with neoadjuvant imatinib. Adjuvant imatinib was initiated in 2 patients with positive molecular marker at resection margin despite complete histologic remission. The remaining patient with histologic and molecular tumor-free resection margins was not treated with adjuvant imatinib and stayed clinically free of disease at 3 years' follow-up. Based on this observation, we recommend molecular analysis of resection margins in all pediatric DFSP cases if available. Nevertheless,

**Table I.** Pediatric dermatofibrosarcoma protuberans cases treated with imatinib mesylate

Case	Age	Presentation	Surgical treatment	Use and dosage, mg/m <sup>2</sup> /d	Duration	Adverse reaction	Response
1 (Current report)	22 mo	Facial nodule over left nasal root	Incomplete excision followed by wider re-excision	Adjuvant, 280-430	18 mo	Poor appetite, subsided after tapering dose	Free of disease at 23 mo follow-up
2 <sup>9</sup>	18 mo	Large lower extremity mass	None	Neoadjuvant, 400-520	23 wk	None	Reduction in subcutaneous tumor size by 60%
3 <sup>5</sup>	14 y	Relapse in skull	2 Incomplete excisions followed by radical re-excision	Neoadjuvant and adjuvant, 400	6 mo neoadjuvant, followed by 12 mo adjuvant	None	Free of disease at 3.5 y follow-up
4 <sup>5</sup>	12 mo	Right buttock	Tumor excision up to muscle fascia	Neoadjuvant, 500	12 mo	None	Free of disease at 3 y follow-up
5 <sup>5</sup>	3 y	Left groin	Tumor excision	Neoadjuvant and adjuvant, 500	6 mo neoadjuvant, followed by 3 mo adjuvant	None	Complete remission at 6 mo after treatment
6 <sup>10</sup>	Newborn	Massive back tumor	Partial tumor excision	Adjuvant, 50 mg/d	8 mo	Not reported	No enlargement of residual tumor at 1 y follow-up

the clinical value of minimal residual molecular disease in DFSP needs further evaluation by larger studies.

We emphasize early biopsy of a lesion suspicious for DFSP in children. When the lesion is unresectable or tumor-free margins positive or suboptimal, imatinib mesylate is a viable target neoadjuvant or adjuvant therapy. Our case suggests that postoperative imatinib mesylate may achieve tumor remission with minimal side effects.

**REFERENCES**

1. Kornik RI, Muchard LK, Teng JM. Dermatofibrosarcoma protuberans in children: an update on the diagnosis and treatment. *Pediatr Dermatol.* 2012;29:707-713.
2. Maire G, Fraitag S, Galmiche L, et al. A clinical, histologic, and molecular study of 9 cases of congenital dermatofibrosarcoma protuberans. *Arch Dermatol.* 2007;143:203-210.
3. Bowne WB, Antonescu CR, Leung DH, et al. Dermatofibrosarcoma protuberans: a clinicopathologic analysis of patients treated and followed at a single institution. *Cancer.* 2000;88:2711-2720.
4. Bichakjian CK, Olencki T, Alam M, et al. Dermatofibrosarcoma protuberans, version 1.2014. *J Natl Compr Canc Netw.* 2014;12:863-868.
5. Gooskens SL, Oranje AP, van Adrichem LN, et al. Imatinib mesylate for children with dermatofibrosarcoma protuberans (DFSP). *Pediatr Blood Cancer.* 2010;55:369-373.
6. Sirvent N, Maire G, Pedetour F. Genetics of dermatofibrosarcoma protuberans family of tumors: from ring chromosomes to tyrosine kinase inhibitor treatment. *Genes Chromosomes Cancer.* 2003;37:1-19.
7. Lemm D, Mugge LO, Mentzel T, Hoffken K. Current treatment options in dermatofibrosarcoma protuberans. *J Cancer Res Clin Oncol.* 2009;135:653-665.
8. Patel KU, Szabo SS, Hernandez VS, et al. Dermatofibrosarcoma protuberans COL1A1-PDGFB fusion is identified in virtually all dermatofibrosarcoma protuberans cases when investigated by newly developed multiplex reverse transcription polymerase chain reaction and fluorescence in situ hybridization assays. *Hum Pathol.* 2008;39:184-193.
9. Price VE, Fletcher JA, Zielenska M, et al. Imatinib mesylate: an attractive alternative in young children with large, surgically challenging dermatofibrosarcoma protuberans. *Pediatr Blood Cancer.* 2005;44:511-515.
10. Suzuki D, Kobayashi R, Yasuda K, et al. Congenital dermatofibrosarcoma protuberans in a newborn infant with a massive back tumor: favorable effects of oral imatinib on the control of residual tumor growth. *J Pediatr Hematol Oncol.* 2011;33:e304-e306.