

Relations Between Cardiac and Vascular Structure in Patients With Primary and Secondary Hypertension

DAMIANO RIZZONI, MD, MARIA LORENZA MUIESAN, MD, ENZO PORTERI, MD, MASSIMO SALVETTI, MD, MAURIZIO CASTELLANO, MD, GIORGIO BETTONI, MD, GUIDO TIBERIO, MD,* STEFANO MARIA GIULINI, MD,* CRISTINA MONTEDURO, MD, GUIDO GARAVELLI, MD,† ENRICO AGABITI-ROSEI, MD

Brescia, Italy

Background. Data on cardiac and vascular structure in secondary hypertension are generally scarce, and no data on the interrelations between cardiac mass and structural characteristics of the vessel wall, both in large and in small resistance arteries, are presently available.

Objectives. The aim of this study was to investigate the relation between structural changes in subcutaneous small arteries, left ventricular mass and wall thickness of the common carotid artery in patients with primary and secondary hypertension.

Methods. Seventy-four subjects were included in the study: 11 patients with pheochromocytoma, 14 with primary aldosteronism (PA), 19 with renovascular hypertension (RVH), 18 with essential hypertension (EH) and 12 normotensive (NT) control subjects. All subjects were submitted to a biopsy of subcutaneous fat. Morphologic characteristics of subcutaneous small resistance arteries (relaxed diameter <300 μm) were directly evaluated using a micromyographic technique. All subjects were submitted to cal-

culatation of left ventricular mass index (LVMI) and common carotid artery intima-media thickness (CCIMT), using ultrasound technique.

Results. The correlation coefficients between the media to lumen ratio in subcutaneous small arteries (M/L) and LVMI or between M/L and CCIMT were closer in RVH than in pheochromocytoma, EH or NT; in PA the correlation coefficients were slightly less close than those in RVH. An excess prevalence of carotid plaques in RVH was observed.

Conclusions. A close relation between small resistance artery morphology and cardiac or carotid artery structure may be observed in those hypertensive patients in whom the renin-angiotensin-aldosterone system is activated. In contrast, in NT, EH and pheochromocytoma no significant correlation between M/L and LVMI or CCIMT was observed.

(J Am Coll Cardiol 1998;32:985-92)

©1998 by the American College of Cardiology

Arterial hypertension is frequently associated with the presence of structural alterations in the heart, carotid artery and small resistance arteries. The presence of left ventricular hypertrophy (LVH), an increased thickness of carotid artery walls or a greater media to lumen ratio (M/L) in small resistance arteries may be extremely important in hypertension, both from a pathophysiologic and a clinical prognostic point of view (1-3). Whether the cardiovascular changes are a cause or a consequence of hypertension remains controversial, however (4-6).

Vascular and cardiac structure may be influenced by circulating, autocrine or paracrine hormonal factors. Patients with

secondary forms of hypertension are characterized by an abnormal increase in the production of some neurohumoral factors, such as angiotensin II, aldosterone or catecholamines, all of which have been demonstrated to be able to stimulate smooth muscle cell growth in vitro (7,8). Recent data suggest that patients with renovascular hypertension (RVH) may have an increased prevalence of LVH (9,10) and carotid artery lesions (11), as well as more evident alterations in small resistance arteries (12), as compared with patients with pheochromocytoma or essential hypertension (EH). Also, patients with primary aldosteronism (PA) seem to be characterized by more evident cardiovascular structural alterations (9,12-15). Patients with pheochromocytoma seem to present a pattern of cardiovascular structural alterations similar to those usually observed in patients with EH (9,16). In a previous study we demonstrated that structural alterations observed in subcutaneous small resistance arteries of patients with RVH could be ascribed, at least in part, to smooth muscle cell growth, whereas in patients with EH and those with pheochromocytoma, the vascular structural alterations can be almost entirely explained by eutrophic remodeling (12). However, data on cardiac and vascular structure in secondary hypertension are

Chair of Semeiotica and Metodologia Medica, *Chair of Chirurgia Generale, University of Brescia, and †Divisione di Medicina, Ospedale di Cremona, Brescia, Italy. Financial support for this study was obtained by the Italian Ministry of University and Scientific Research and by the Center for the Study of Hypertension and Cardiorespiratory Risk Factors of the University of Brescia.

Manuscript received January 12, 1998; revised manuscript received May 26, 1998, accepted June 4, 1998.

Address for correspondence: Dr. Damiano Rizzoni, U.O.P. Scienze Mediche, University of Brescia, c/o 1^a Medicina, Spedali Civili, 25100 Brescia, Italy. E-mail: Damiano.Rizzoni@scherling-plough.it

Abbreviations and Acronyms

CCIMT	= common carotid artery intima-media thickness
EH	= essential hypertension
LVH	= left ventricular hypertrophy
LVMI	= left ventricular mass index
M/L	= media to lumen ratio in subcutaneous small arteries
NT	= normotensive or normotension
PA	= primary aldosteronism
RVH	= renovascular hypertension

generally scarce, and no data on the interrelations between cardiac mass and structural characteristics of the vessel wall, both in large and in small resistance arteries, are presently available.

Therefore, we considered it worthwhile to investigate the relations between subcutaneous small resistance arteries, cardiac mass and wall thickness of the common carotid artery in patients with primary and secondary hypertension, as well as in normotensive (NT) control subjects, using reliable minimally invasive or noninvasive techniques. Our working hypothesis was the following: if the growth factors exert a key role in the genesis of cardiovascular structural alterations, then a closer correlation between cardiac mass and vascular structural changes should be observed in those patients showing increased circulating or tissue levels of growth factors, such as angiotensin II, aldosterone or catecholamines, as compared with NT control subjects and patients with EH.

Methods

Patient group. Seventy-four subjects were included in the study. Forty-four patients had a secondary form of hypertension: 11 had a pheochromocytoma, 14 had PA and 19 had RVH. Data were compared with those obtained in 12 NT subjects and in 18 patients with EH. Hypertensive patients had a clinic blood pressure (average of three different sphygmomanometric measurements, each performed on three separate days, after a washout period of at least 2 weeks if previously treated with antihypertensive drugs) $>140/90$ mm Hg. NT control subjects had a systolic blood pressure <140 mm Hg and a diastolic blood pressure <90 mm Hg. All hypertensive patients had been previously treated for various periods of time with calcium channel blockers, angiotensin-converting enzyme inhibitors, diuretic agents or beta-blockers. There was no statistically significant difference in the therapeutic regimens of the different groups.

Venous blood samples were taken with the participants in the supine position, after a washout period of at least 2 weeks, for measurement of plasma renin activity (radioimmunoassay Renctk, Sorin Biomedica, Turin, Italy), plasma and urinary aldosterone (radioimmunoassay Aldoctk, Sorin Biomedica, Turin, Italy), as well as plasma or urinary norepinephrine and epinephrine (high performance liquid chromatography) (17).

The diagnosis of secondary forms of hypertension was made

on the basis of an indication for renal artery revascularization ($n = 19$) or adrenal tumor resection ($n = 21$), after proper investigation by imaging techniques and humoral assessments. In one case a bilateral renal artery stenosis was demonstrated by angiography, but the patient refused intervention. In four cases a bilateral adrenal hyperplasia associated with high plasma and urinary aldosterone levels was demonstrated. In these cases no surgical correction was performed. Thirty-eight patients had surgical repair or renal artery angioplasty, and their hypertension was cured, except for four patients with RVH whose blood pressure was significantly reduced, but antihypertensive monotherapy was still required after 6 months. All these patients were previously placed on a combination therapy (three or four drugs). EH was diagnosed on the basis of persistently elevated levels of blood pressure, after careful exclusion of secondary causes.

Micromyography. All participants underwent a biopsy of subcutaneous fat from the gluteal or anterior abdominal region. The biopsy of the abdominal subcutaneous fat was taken during a surgical procedure (usually a cholecystectomy in NT subjects and patients with EH or an adrenalectomy or a vascular surgical intervention on the renal arteries in patients with secondary hypertension). In the remaining cases a standard skin biopsy of the gluteal region (3 cm long, 0.5 cm wide, 1.5 cm deep) was performed (18,19). The percentage of skin biopsies taken from the abdomen was similar in the five groups of subjects ($\sim 20\%$ to 25%). We have previously demonstrated that no difference in the morphology of small resistance arteries obtained from the subcutaneous fat taken from the gluteal or anterior abdominal region could be observed (12).

The protocol of the study was approved by the Ethics Committee of our institution (Medical School, University of Brescia), and written informed consent was obtained from each participant. The procedures followed were in accordance with institutional guidelines.

Small arteries (~ 160 to 280 μm average diameter in relaxed conditions, 2 mm long) were dissected from the subcutaneous fat of the biopsies and mounted as a ring preparation on an isometric myograph (410 A, JP Trading, Aarhus, Denmark), by threading onto two stainless-steel wires (40 μm diameter). The two wires were attached to a force transducer and micrometer, respectively, as previously described by Mulvany et al. (20,21). Vessels were warmed to 37°C and allowed to equilibrate for at least 30 min in physiologic saline solution with the following composition (in mmol/liters): NaCl 119, NaHCO_3 24, KCl 4.7, KH_2PO_4 1.18, MgSO_4 1.17, CaCl_2 2.5 and glucose 5.5—kept constantly at 37°C and bubbled with 5% carbon dioxide and oxygen. The vessel internal circumference was set to give a wall tension of 0.1 mN/mm.

Vessel wall and media thicknesses were measured at 12 sites, which were then averaged, using a light microscope with immersion lens (Lab 20, Carl Zeiss S.P.A., Milan, Italy) at $\times 600$ magnification, which provides a resolution of 0.2 μm . Lower magnification was used for measurement of the distance between the wires and length of the blood vessel. The rest tension–internal circumference relation was determined, and

vessels were set to the normalized circumference L_1 , where $L_1 = 0.9 L_{100}$ and L_{100} = the internal circumference the vessels would have had in vivo, when relaxed and under a transmural pressure of 100 mm Hg, as described previously by Mulvany et al. (20,21). From L_1 , the normalized internal diameter, l_1 , was calculated. Assuming that the cross-sectional area remains constant when the vessel is extended to L_1 , the wall and media thicknesses were automatically calculated also in normalized condition. Wall and media thicknesses, as well as the M/L of blood vessels in normalized condition (vessels extended to L_1), were obtained assuming a constant wall and media volume, from wall and media cross-sectional areas calculated from wall and media thicknesses measured in unstretched vessels, as previously described (20,21). The average values obtained from two vessels in each experiment were considered. For further details see also references 22 and 23.

Echocardiography. In 11 patients with pheochromocytoma, 14 with PA, 19 with RVH, 18 with EH and 12 NT control subjects, a standard echocardiographic evaluation (HP Sonos 1000 or 1500, Hewlett Packard) was performed. Echocardiographic studies were performed in the morning, with the subject in supine left lateral decubitus position, after 30 min of rest. Only two physicians were responsible for recording the echocardiograms. Echocardiographic tracings were of good technical quality and were recorded on light-sensitive paper at a paper speed of 50 mm/s. Two-dimensional imaging of the longitudinal parasternal view was checked to avoid angulation of the ultrasonic beam, and consequent changes in the left ventricular shape. Left ventricular internal dimensions and left ventricular posterior wall and interventricular septum thicknesses, were measured according to the recommendations of the American Society of Echocardiography (24). Left ventricular volumes were calculated using the cube formula. Left ventricular mass was calculated according to the Penn Convention (25) and indexed to body surface area, calculated by the formula of Dubois and Dubois (26). LVH was considered present if the left ventricular mass index (LVMI) exceeded 110 g/m^2 in women and 131 g/m^2 in men (27,28).

Echocardiographic tracings were calculated blindly by two expert independent readers, and the average measurements were considered. Intraobserver and interobserver coefficients of variation of measurements for LVMI in both NT subjects and hypertensive patients were 8.2 and 9.2%, respectively. For further details on the methods used, see references 3, 29 and 30.

Carotid ultrasound. In 11 patients with pheochromocytoma, 12 with PA, 14 with RVH, 17 with EH and 11 NT control subjects, B-mode imaging of the carotid arteries was obtained using a Hewlett Packard Sonos 1000 or 1500 echocardiographic unit equipped with a 7.5-MHz imaging transducer. The subjects were studied lying in the supine position, with slight hyperextension of the neck, and the common carotid artery, the carotid bifurcation and the extracranial portions of internal and external carotid arteries were identified. The average duration of the scanning was 30 min, and the entire scanning procedure was recorded on a 1/2-in. super VHS videotape. All

carotid measurements were subsequently performed by two independent readers who had no knowledge of the subjects' identity, echocardiographic measurements and risk factors, and average values were considered; VCR recordings of the entire scanning were analyzed using the measure morphometry software of the echocardiographic unit.

Measurements included end-diastolic (minimal diameter) intima-media thickness of the far walls (distance from the leading edge of the first echogenic line to the leading edge of the second echogenic line), as described previously by Pignoli et al. (31). Several measures were obtained in each arterial segment (6 to 12), according to a previously described protocol (32-34), and the mean value of all measurements on the far wall for each segment was calculated. The thickness of the intima-media layers was measured at end-diastole and the mean maximal value was calculated in at least six points—in the left and right common carotid artery, carotid bifurcation and internal carotid artery. Wall thickness in the carotid artery was never measured at the level of a discrete plaque.

The interobserver and intraobserver coefficients of variation for measurements of intima-media thickness in our laboratory is 7.6% and 6.9%, respectively (3), comparable with those reported by Salonen et al. (35).

Definitions of early atherosclerotic lesions for studies that use B-mode imaging to study the artery wall are variable, and several criteria for defining normal walls, intima-media thickening and plaque have been proposed (32-34,36). In this study, the criteria of Salonen et al. (36) were applied: a normal wall was considered when intima-media thickness was $<1 \text{ mm}$; carotid wall thickening was considered when intima-media thickness was $>1 \text{ mm}$; and a plaque was considered in the presence of wall thickening either with mineralization or with focal protrusion in the lumen at least 50% greater than the surrounding wall (usually $>2 \text{ mm}$).

Statistical analysis. All data are expressed as the mean value \pm SD, unless otherwise stated. One-way analysis of variance was used to evaluate differences among groups. The relation between continuous variables was evaluated by linear regression. A separate analysis of subgroups, with a test of equality of lines (difference in slopes and/or intercepts) across groups, was performed. Differences in the incidence of carotid plaques among groups were evaluated by the chi-square test and the Fisher exact test. All analyses were carried out with the BMDP statistical package (BMDP software programs 7D, 1V 4F and 1R, BMDP Statistical Software Inc.). In consideration of the multiple comparisons performed, we have adopted a conservative approach, and therefore the significance levels was set at 1%.

Results

The five groups of subjects did not differ by age (Table 1), serum lipids or smoking habits. Systolic and diastolic blood pressures were similar in the four groups of hypertensive patients, although there was a small, although not significant, tendency to greater values in patients with RVH (Table 1). The

Table 1. Demographic and Clinical Data in the Different Groups

Variable	Pheo (n = 11)	PA (n = 14)	RVH (n = 19)	EH (n = 18)	NT (n = 12)
Age (years)	49 ± 23	52 ± 13	55 ± 11	55 ± 6	54 ± 14
Gender (M/F)	5/6	4/10	10/9	11/7	6/6
Weight (kg)	63 ± 14	69 ± 14	67 ± 11	69 ± 10	69 ± 11
Height (cm)	163 ± 9	163 ± 6	166 ± 8	168 ± 9	164 ± 14
Body surface area (m ²)	1.74 ± 0.21	1.80 ± 0.15	1.80 ± 0.16	1.82 ± 0.15	1.81 ± 0.18
Systolic blood pressure (mm Hg)	159 ± 19*	169 ± 28*	171 ± 22*	161 ± 7*	128 ± 8
Diastolic blood pressure (mm Hg)	99 ± 20*	104 ± 9†	106 ± 13*	98 ± 7*	79 ± 7
Plasma renin activity (ng/ml per h)	NA	0.21 ± 0.27‡	8.75 ± 8.67‡‡	1.1 ± 1.0	0.9 ± 1.1
Plasma aldosterone (pmol/ml)	NA	1.12 ± 0.58†	1.01 ± 0.77†	0.42 ± 0.31	0.30 ± 0.26
Urinary aldosterone (nmol/24 h)	NA	289 ± 192†	184 ± 142	31.0 ± 22.0	36.3 ± 25.4
Plasma norepinephrine (nmol/liters)	26.9 ± 29.5†	NA	NA	2.6 ± 3.0	2.2 ± 2.2
Plasma epinephrine (nmol/liters)	14.8 ± 16.5	NA	NA	0.51 ± 0.61	0.43 ± 0.52
Urinary norepinephrine (nmol/24 h)	4,450 ± 4,298†§	151 ± 57	140 ± 93	333 ± 284	261 ± 251
Urinary epinephrine (nmol/24 h)	313 ± 403	35 ± 43	67 ± 88	82 ± 77	67 ± 74
Serum cholesterol (mmol/liters)	5.1 ± 0.83	5.3 ± 1.50	5.5 ± 1.09	5.6 ± 1.21	5.1 ± 1.58
Serum triglycerides (mmol/liters)	1.4 ± 0.51	1.2 ± 0.56	1.6 ± 0.87	1.7 ± 0.82	1.5 ± 0.70

*p < 0.001 and †p < 0.01 compared with normotensive control subjects. ‡p < 0.01 and §p < 0.001 compared with patients with essential hypertension. Data are presented as the mean value ± SD. EH = patients with essential hypertension; NA = data not available; NT = normotensive control subjects; PA = patients with primary aldosteronism; Pheo = patients with pheochromocytoma; RVH = patients with renovascular hypertension.

known duration of hypertension was about 3 to 4 years in all hypertensive groups.

Humoral data. A statistically significant increase in plasma and urinary norepinephrine was observed in patients with pheochromocytoma, as compared with NT subjects and patients with EH (Table 1). Plasma renin activity was increased in patients with RVH and was reduced in patients with PA, as compared with the remaining groups (Table 1). Plasma and urinary aldosterone levels were significantly increased in patients with PA, whereas only plasma aldosterone significantly increased in patients with RVH.

Morphology of small subcutaneous resistance arteries. In comparison with NT subjects, the M/L ratio was significantly increased in all hypertensive patients. In patients with PA and those with RVH the increase in the M/L ratio was more pronounced. In addition, the difference between values ob-

tained in these patients and values obtained in patients with pheochromocytoma and those with EH was statistically significant (Table 2). The normalized internal diameter was significantly smaller in patients with PA and those with RVH, as compared with NT control subjects (Table 2).

Cardiac structure. LVMI, calculated according to the Penn Convention, was significantly greater in patients with EH and in those with RVH than in NT control subjects (Table 2). The percentage of patients with LVH was 36% in patients with pheochromocytoma, 29% in those with PA, 68% in those with RVH and 39% in those with EH. LVH was never observed in normotensive controls.

The septal thickness was greater in patients with EH and those with RVH than in NT control subjects. The posterior wall thickness was significantly greater in patients with RVH and those with PA than in NT control subjects. In addition, in

Table 2. Morphologic Characteristics of Patients With Primary and Secondary Hypertension as Well as in Normotensive Control Subjects

	Pheo	PA	RVH	EH	NT
Small resistance vessel data					
Media/lumen ratio	0.080 ± 0.020*	0.105 ± 0.028*	0.130 ± 0.045*‡¶	0.093 ± 0.023*	0.058 ± 0.01
Media thickness (mm)	19.9 ± 6.34	21.6 ± 4.8	25.2 ± 7.1	22.9 ± 4.22	19.6 ± 5.91
Internal diameter (mm)	254 ± 59	220 ± 81†	217 ± 80†	258 ± 67	312 ± 72
Echocardiographic data					
Left ventricular mass index (g/m ²)	115 ± 39	105 ± 27	130 ± 27*	120 ± 24†	92 ± 25
Relative wall thickness (mm)	0.40 ± 0.04	0.43 ± 0.07†	0.43 ± 0.07†	0.36 ± 0.07	0.32 ± 0.11
Posterior wall thickness (mm)	0.85 ± 0.14	0.90 ± 0.15†	0.96 ± 0.15*‡	0.83 ± 0.13	0.77 ± 0.06
Septum thickness (mm)	0.99 ± 0.18	0.99 ± 0.17	1.06 ± 0.16*	1.09 ± 0.2*	0.85 ± 0.09
Carotid artery data					
Common carotid artery intima-media thickness (mm)	0.86 ± 0.24	0.77 ± 0.21	0.98 ± 0.29†	0.80 ± 0.17	0.70 ± 0.14
Carotid bifurcation intima-media thickness (mm)	1.25 ± 0.43	0.85 ± 0.28	1.37 ± 0.62	1.08 ± 0.29	0.96 ± 0.24
Internal carotid artery intima-media thickness (mm)	0.88 ± 0.43	0.64 ± 0.12	0.99 ± 0.5	0.81 ± 0.22	0.74 ± 0.22

*p < 0.001 and †p < 0.01 compared with normotensive control subjects. ‡p < 0.01 compared with patients with essential hypertension. ¶p < 0.001 compared with patients with pheochromocytoma. Data are presented as the mean value ± SD. Abbreviations as in Table 1.

Table 3. Correlation Coefficients Between Indexes of Cardiac and Vascular Structure in the Different Groups

	M/L Ratio vs. CCIMT	M/L Ratio vs. LVMI	CCIMT vs. LVMI
All subjects	0.53*	0.44*	0.50*
Pheo	-0.07	-0.25	0.45
PA	0.43	0.50	0.19
RVH	0.74†	0.59†	0.74†
EH	0.02	0.20	0.21
NT	0.29	0.20	0.24

* $p < 0.01$. † $p < 0.001$. Statistical comparison of slopes and intercepts of linear regression analysis; P values of significance of differences between RVH and the other groups: M/L ratio-CCIMT vs. EH $p = 0.007$, vs. NT $p = 0.001$, vs. Pheo $p = 0.0003$. M/L ratio-LVMI vs. EH $p = 0.007$, vs. NT $p = 0.003$, vs. Pheo $p = 0.0005$.

patients with RVH the posterior wall thickness was significantly greater than that in patients with EH. No difference in relative wall thickness was observed among the various groups of patients (Table 2).

Carotid artery structure. The common carotid artery intima-media thickness (CCIMT) was significantly greater in patients with RVH than in patients with EH and NT control subjects (Table 2). Data for carotid bifurcation and internal carotid artery intima media-thickness are reported in Table 2.

There was an excess prevalence of plaques in patients with RVH and possibly also in patients with pheochromocytoma, as compared with patients in the other groups (Table 3).

Linear regression analysis. The correlation coefficients between the M/L ratio, LVMI and CCIMT are reported in Table 3. In patients with RVH, the correlation between the M/L ratio, LVMI and CCIMT was closer than in the other groups (Figs. 1 and 2). There was a significant difference in the slope or intercepts of the regression lines between patients with renovascular hypertension and the remaining groups of subjects (Table 4, Figs. 1 and 2).

One of the patients with RVH showed very high values of M/L ratio, LVMI and CCIMT. To evaluate the effect of this single patient on the regression outcome, we have recalculated the correlation coefficient values without the "outlier." A modest reduction in the correlation coefficient was observed (M/L ratio-LVMI: $r = 0.45$, $p < 0.05$; M/L ratio-CCIMT: $r = 0.63$, $p < 0.01$), without substantial changes in the level of statistical significance.

No significant correlation was observed between morphologic data (in particular, the M/L ratio in small resistance arteries, LVMI and CCIMT) and systolic or diastolic arterial pressure, age, plasma renin activity, PRA aldosterone, catecholamines or other clinical factors. In particular, the correlation coefficients between systolic and diastolic blood pressure and morphologic findings were < 0.30 and were similar in the different groups, although they were slightly weaker in the patients with RVH (systolic blood pressure-M/L ratio in small arteries: $r = 0.08$).

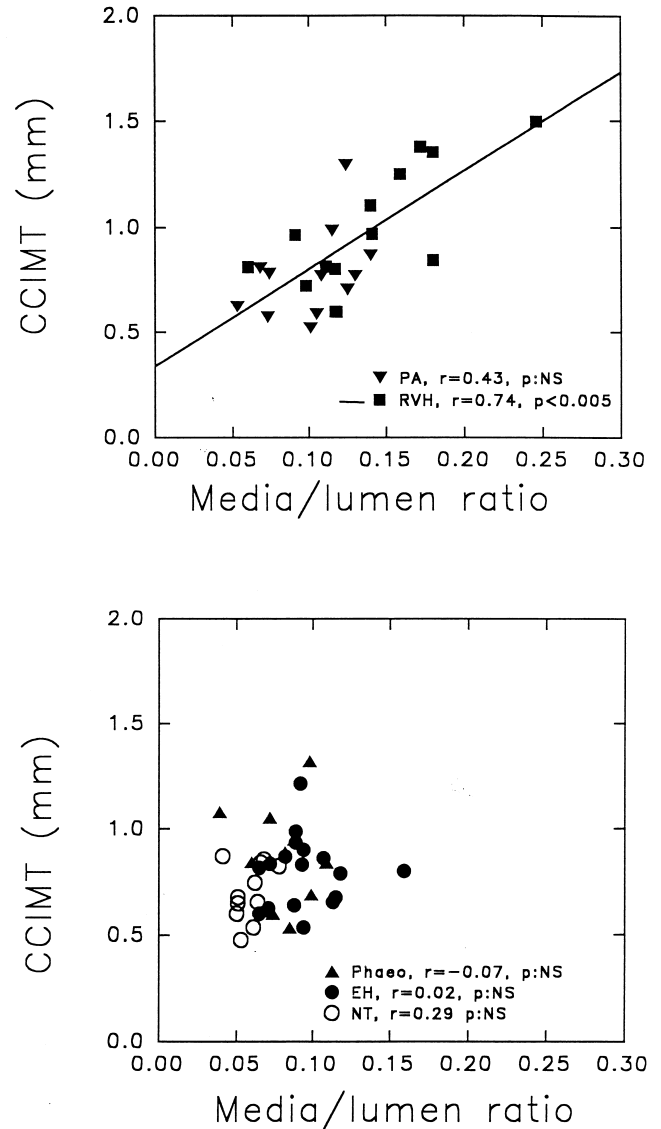


Figure 1. Linear regression between M/L ratio and CCIMT in patients with PA (solid triangles pointing down) and RVH (solid squares, solid line) (top of figure) as well as in patients with pheochromocytoma (solid triangles pointing up), EH (solid circles) and in NT control subjects (open circles) (bottom of figure). See text for the number of subjects in each group.

Discussion

For the first time, to our knowledge, this study has examined the relation between cardiac and vascular structure in a rather large group of patients with primary or secondary hypertension, using direct, reliable and well assessed techniques.

Extent of cardiovascular alterations. We have observed that cardiac and vascular structural changes were more evident in patients with RVH. It should be emphasized, however, that an important, although not statistically significant trend toward higher systolic and diastolic blood pressure was observed in those patients with an increased activation of the renin-

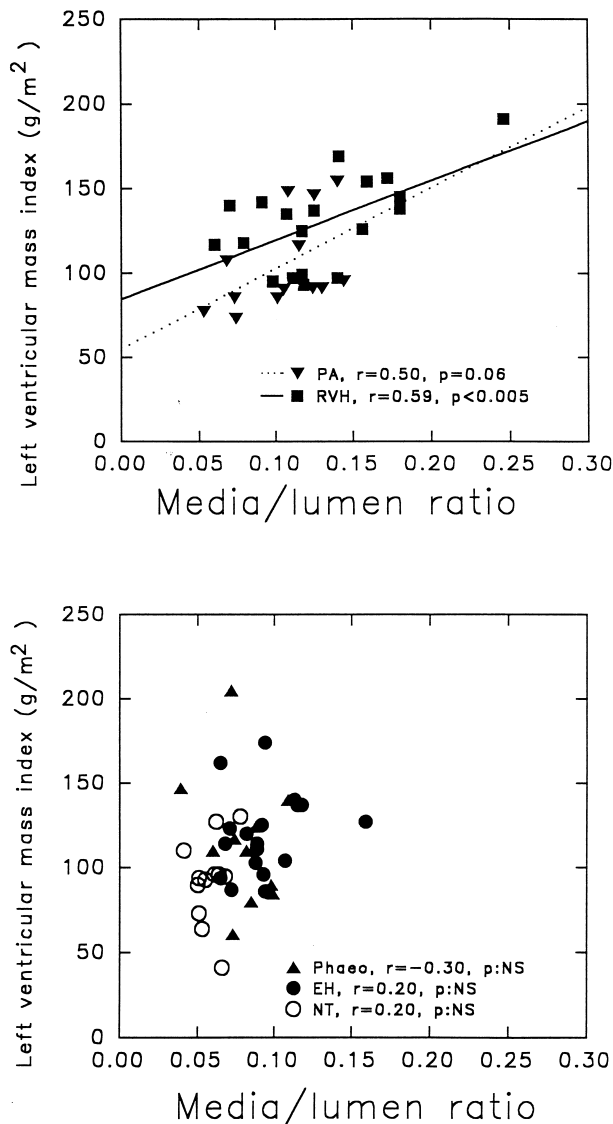


Figure 2. Linear regression between M/L ratio and LVMI in patients with PA (solid triangles pointing down, dotted line) and RVH (solid squares, solid line) (top of figure) as well as in patients with pheochromocytoma (solid triangles pointing up), EH (solid circles) and in NT control subjects (open circles) (bottom of figure). See text for the number of subjects in each group.

angiotensin-aldosterone system. Therefore, it is not possible to completely rule out a partial role of hemodynamic factors in this observation. However, it seems reasonable that the growth-promoting properties of the renin-angiotensin system may account for a great part of the pronounced cardiovascular changes observed. Circulatory renin has been demonstrated to be correlated to clinical outcomes in hypertension (37), and the possible link may be represented by alterations of the cardiovascular structure.

Correlations between indexes of cardiovascular structure.

In the present study we have also demonstrated that a close correlation between indexes of cardiac and vascular structure could be observed in patients in whom the renin-angiotensin-

Table 4. Incidence and Total Number of Atherosclerotic Plaques in the Carotid Arteries

Patient Groups	Incidence of Plaques (Percentage of Subjects Having at Least One Plaque)	Total Number of Plaques in Each Group
Pheo (n = 11)	64%	14
PA (n = 12)	42%	6
RVH (n = 14)	86%	31
EH (n = 17)	65%	21
NT (n = 11)	27%	3

Distribution of plaques—chi-square test: RVH vs. NT $p = 0.003$; RVH vs. PA $p = 0.02$; NT vs. EH $p = 0.05$. Total number of plaques—chi-square test: RVH vs. EH $p = 0.036$; RVH vs. NT $p = 0.00003$; RVH vs. PA $p = 0.0003$; Pheo vs. PA $p = 0.047$; Pheo vs. NT $p = 0.008$; PA vs. EH $p = 0.04$; NT vs. EH $p = 0.007$. Abbreviations as in Table 1.

aldosterone system is activated, such as in those with RVH or, to a lesser extent, those with PA. It is not possible, on an a priori basis, to postulate which is the primary etiologic event in the relations (i.e., whether small vessel changes may determine cardiac or carotid changes or vice versa). An increased growth factor activation (namely, angiotensin II in patients with RVH) would stimulate, at the same time, different vascular and cardiac targets. In patients with EH the level of growth factor stimulation is probably too low to allow for the detection of a clear-cut correlation, whereas in the other two groups of patients with secondary hypertension, the growth factors involved are probably less potent than angiotensin II. Another possibility is represented by a synergistic action between aldosterone and angiotensin II in patients with RVH. In a previous study performed in patients with EH, a statistically significant correlation between the M/L ratio of subcutaneous small resistance arteries and LVMI was observed (38). However, if patients were subclassified according to the presence or absence of LVH, the correlation was found only among patients with LVH, but not in patients with normal left ventricular mass or in NT control subjects (38). In the past years, some studies have demonstrated the presence of an association between carotid atherosclerotic lesions and LVH (39,40). A correlation between carotid artery measures and left ventricular mass was also observed in hypertensive patients (41-43) and in general populations of NT and hypertensive subjects (3,44,45), suggesting a parallel cardiac and vascular adaptation in hypertension (46,47). However, the correlation coefficients between indexes of cardiac and carotid artery structure vary greatly among the different studies (from 0.20 to 0.49). In our study, a weak correlation between CCIMT and LVMI was observed in patients with EH. Patients with EH can hardly be considered a homogeneous group, because they include patients with different pathophysiologic characteristics (i.e., low, normal and high circulating levels of renin). It is possible that a closer correlation between cardiac and vascular structure could be observed in patients with EH with a more pronounced activation of tissue or of the circulating renin-angiotensin-aldosterone system, although in our study no

significant correlation between plasma renin activity (PRA) and cardiac mass, CCIMT or M/L ratio of small resistance arteries could be observed, probably owing to the relatively low reliability of PRA as an index of tissue renin-angiotensin-aldosterone system activation. Changes in the vascular wall might also be the consequence of compensatory neurohumoral activation, secondary to a reduction in cardiac output possibly present in patients with LVH, with consequent vasoconstriction and growth stimulation. However, in our study cardiac function was between normal limits in all patients. It is also possible that the effects of angiotensin II on cardiovascular structure could be mediated, at least in part, by a stimulation of endothelin-1 (48), which was demonstrated to possess growth-promoting properties. It cannot, however, be excluded that additional neurohumoral factors, beside angiotensin II, endothelin-1 and aldosterone, may have influenced vascular growth. Although no significant correlation between blood pressure and vascular structure was observed in any group, the observation of a particularly weak correlation in patients with RVH (compared with relatively strong correlations between indexes of cardiac and vascular structure) strengthens our argument about the importance of growth factor activation rather than blood pressure alone.

Carotid plaques. In our group of patients with RVH and, to a lesser extent, with pheochromocytoma, a higher prevalence of atherosclerotic lesions in the common carotid artery was detected. It is possible that the humoral determinants of the vessel wall remodeling and of the development of atherosclerotic plaques may be partially different. Nevertheless, in the common carotid artery of patients with RVH a greater incidence of both vascular plaque and media hypertrophy seems to be present. This finding could also have clinical importance, as suggested by the observation of an association between the renin-angiotensin system and hypertensive cerebrovascular disease (37,49). It is possible, however, that structural alterations in the common carotid artery may be associated with an abnormality in compliance of large arteries, and subsequently to an elevation of resistance to cardiac output ejection from the left ventricle, which may increase the stress on the heart, thus leading to LVH (50). In addition, it is also possible that concomitant atherosclerotic disease may be present in coronary arteries, with consequent ischemia triggering changes in the myocardium and compensatory ventricular hypertrophy. However, in our study, no clinical, electrocardiographic or echocardiographic sign of myocardial ischemia was present in any patients.

Cardiac mass in PA. In previous studies, an increase in LVMI was observed in patients with PA as compared with those with EH (14,15). In our group of patients, we observed only a small increase in wall thickness. A possible explanation of these conflicting findings could be a different duration of hypertension or a slightly lower prevalence of females in our study. However, our data clearly indicate that for the same duration and severity of hypertension, patients with PA have fewer cardiac structural changes than do patients with RVH. In our study and in that of Rossi et al. (15), no signs of left ventricular enlargement were observed, whereas in the study of

Shigematsu et al. (14), a modest increase in left ventricular end-diastolic dimension index was detected. Several publications have demonstrated the presence of fibrotic changes in the myocardium of patients with PA (51,52). Although these fibrotic changes may lead to some abnormalities in left ventricular compliance and relaxation, left ventricular mass may not necessarily be increased.

Cardiac mass in pheochromocytoma. In our study the pattern of cardiovascular alterations in patients with pheochromocytoma was similar to that observed in patients with EH, despite the fact that catecholamines seem to have growth-promoting properties in vitro (7,53,54). Our findings are in agreement with previous observations; in fact, left ventricular mass seems to not necessarily be higher in patients with pheochromocytoma, as compared with patients with EH and equivalent blood pressure levels (9,16). It is therefore possible that these in vitro observations (53,54) may hardly be extrapolated to the clinical setting.

Clinical implications. Our findings may have important clinical implications. If a relevant role of the circulating or tissue renin-angiotensin-aldosterone system in the simultaneous development of cardiac and vascular structural alterations is accepted, then it is advisable to look for the presence of alterations both at the cardiac and at different vascular levels when an excessive stimulation of this system occurs. In addition, from a therapeutic point of view, our data suggest that drugs which can reduce the renin-angiotensin-aldosterone system activity may be particularly advantageous in those situations where pronounced cardiovascular structural alterations are present at the same time. These points should be further evaluated and clarified in the future.

Conclusions. Cardiac and vascular structural changes were more evident in patients with RVH. A close relation between small resistance artery morphology and cardiac or carotid artery structure may be observed in those patients in whom the renin-angiotensin-aldosterone system is activated. In contrast, in patients with EH or pheochromocytoma or in NT control subjects, no significant correlation between the M/L ratio and LVMI or CCIMT was observed.

References

1. Muiesan ML, Salvetti M, Rizzoni D, Castellano M, Donato F, Agabiti Rosei E. Association of changes in left ventricular mass with prognosis during long-term antihypertensive treatment. *J Hypertens* 1995;13:1091-6.
2. Salonen R, Tervahauta M, Salonen JT, Pekkanen J, Nissinen A, Karvonen MJ. Ultrasonographic manifestations of common carotid artery atherosclerosis in elderly eastern Finnish men: prevalence and association with cardiovascular diseases and risk factors. *Arterioscler Thromb* 1994;14:1631-40.
3. Muiesan ML, Pasini GF, Salvetti M, et al. Cardiac and vascular structural changes: prevalence and relation to ambulatory blood pressure in a middle-aged general population in northern Italy: the Vobarno study. *Hypertension* 1996;27:1046-52.
4. Rizzoni D, Castellano M, Porteri E, Bettoni G, Muiesan ML, Agabiti-Rosei E. Vascular structural and functional alterations before and after the development of hypertension in SHR. *Am J Hypertens* 1994;7:193-200.
5. Giannattasio C, Cattaneo B, Mangoni Carugo S, et al. Cardiac and vascular structural changes in normotensive subjects with parental hypertension. *J Hypertens* 1995;13:259-64.

6. Mulvany MJ. Resistance vessel growth and remodeling: cause or consequence in cardiovascular disease. *J Human Hypertens* 1995;9:479-85.
7. Pauletto P, Sarzani R, Rappelli A, Pessina AC, Sartore S. Vascular smooth muscle cell differentiation and growth response in hypertension. In: Laragh JH, Brenner BM, editors. *Hypertension: Pathophysiology, Diagnosis and Management*. 2nd edition. New York: Raven Press, 1995:697-709.
8. Schelling P, Fischer H, Ganten D. Angiotensin and cell growth: a link to cardiovascular hypertrophy? *J Hypertens* 1991;9:3-15.
9. Denolle T, Chatellier G, Julien J, Battaglia C, Luo P, Plouin PF. Left ventricular mass and geometry before and after etiologic treatment in renovascular hypertension, aldosterone-producing adenoma, and pheochromocytoma. *Am J Hypertens* 1993;6:907-13.
10. Losito A, Fagugli RM, Zampi I, et al. Comparison of target organ damage in renovascular and essential hypertension. *Am J Hypertens* 1996;9:1062-67.
11. Rossi GP, Rossi A, Zanin L, et al. Excess prevalence of extracranial carotid artery lesions in renovascular hypertension. *Am J Hypertens* 1992;5:8-15.
12. Rizzoni D, Porteri E, Castellano M, et al. Vascular hypertrophy and remodeling in secondary hypertension. *Hypertension* 1996;28:785-90.
13. Rossi GP, Rossi A, Zanin L, Calabrò A, Crepaldi G, Pessina AC. Prevalence of extracranial carotid artery lesions at duplex in primary aldosteronism. *Am J Hypertens* 1993;6:8-14.
14. Shigematsu Y, Hamada M, Okayama H, et al. Left ventricular hypertrophy precedes other target-organ damage in primary aldosteronism. *Hypertension* 1997;29:723-7.
15. Rossi GP, Sacchetto A, Pavan E, et al. Remodeling of the left ventricle in primary aldosteronism due to Conn's adenoma. *Circulation* 1997;95:1471-8.
16. Fouad-Tarazi F, Imamura M, Bravo EL, et al. Differences in left ventricular structural and functional changes between pheochromocytoma and essential hypertension: role of circulating catecholamines. *Am J Hypertens* 1992;5:134-40.
17. Beschi M, Castellano M, Agabiti Rosei E, Rizzoni D, Rossini P, Muiasan G. Assessment of semi-automated catecholamine assay by HPLC: choice of reverse-phase C18 or cation-exchange columns. *Chromatographia* 1987;24:455-9.
18. Aalkjaer C, Heagerty AM, Petersen KK, Swales JD, Mulvany MJ. Evidence for increased media thickness, increased neural amine uptake, and depressed excitation-contraction coupling in isolated resistance vessels from essential hypertensives. *Circ Res* 1987;61:181-6.
19. Aalkjaer C, Eiskjaer H, Mulvany MJ, et al. Abnormal structure and function of isolated subcutaneous resistance vessels from essential hypertensive patients despite antihypertensive treatment. *J Hypertens* 1989;7:305-10.
20. Mulvany MJ, Halpern W. Contractile properties of small resistance vessels in spontaneously hypertensive and normotensive rats. *Circ Res* 1977;41:19-26.
21. Mulvany MJ, Hansen PK, Aalkjaer C. Direct evidence that the greater contractility of resistance vessels in spontaneously hypertensive rats is associated with a narrowed lumen, a thickened media, and an increased number of smooth muscle cell layers. *Circ Res* 1978;43:854-64.
22. Rizzoni D, Castellano M, Porteri E, Bettoni G, Muiasan ML, Agabiti Rosei E. Delayed development of hypertension after short-term nifedipine treatment. *Hypertension* 1994;24:131-9.
23. Rizzoni D, Castellano M, Porteri E, et al. Effects of low and high doses of fosinopril on the structure and function of resistance arteries. *Hypertension* 1995;26:118-23.
24. Sahn DJ, De Maria A, Kisslo J, Weyman A. Recommendations regarding quantitation in M-mode echocardiography: results of a survey of echocardiographic measurements. *Circulation* 1978;58:1072-83.
25. Devereux RB, Reichek N. Echocardiographic determination of left ventricular mass in man: anatomic validation of the method. *Circulation* 1977;55:613-8.
26. Dubois D, Dubois EF. A formula to estimate the approximate surface area if height and weight be known. *Arch Intern Med* 1916;17:863-71.
27. Savage DD, Garrison RJ, Kannel WB, et al. The spectrum of left ventricular hypertrophy in a general population sample: the Framingham study. *Circulation* 1987;75 Suppl I:1-26-30.
28. Devereux RB, Lutas EM, Casale PN, et al. Standardization of M-mode echocardiographic left ventricular anatomic measurements. *J Am Coll Cardiol* 1984;4:1222-30.
29. Agabiti-Rosei E, Muiasan ML, Rizzoni D, et al. Cardiovascular structural changes and calcium antagonist therapy in patients with hypertension. *J Cardiovasc Pharmacol* 1994;24 Suppl A:S37-43.
30. Rizzoni D, Muiasan ML, Montani G, Zulli R, Calebich S, Agabiti Rosei E. Relationship between initial cardiovascular structural changes and daytime and nighttime blood pressure monitoring. *Am J Hypertens* 1992;5:180-6.
31. Pignoli P, Tremoli E, Poli A, Oreste P, Paoletti R. Intimal plus medial thickness of the arterial wall: a direct measurement with ultrasound imaging. *Circulation* 1986;74:1399-1406.
32. Bond MG, Barnes RW, Riley WA, et al., for the ARIC Study Group. High resolution B-mode ultrasound scanning methods in the Atherosclerosis Risk in Communities (ARIC) study. *J Neuroimag* 1991;1:68-73.
33. Riley WA, Barnes RW, Bond MG, Evans GW, Chambless LE, Heiss G. High resolution B-mode ultrasound reading methods in the Atherosclerosis Risk in Communities (ARIC) cohort. *J Neuroimag* 1991;1:168-72.
34. Furberg CD, Byington RP, Borhani NA, the MIDAS Research Group. Multicenter Isradipine Diuretic Atherosclerosis Study (MIDAS) design features. *Am J Med* 1989;86 Suppl 4A:37-9.
35. Salonen R, Haapanen A, Salonen JT. Measurement of intima-media thickness of common carotid arteries with high resolution B-mode ultrasonography: inter- and intraobserver variability. *Ultrasound Med Biol* 1991;17:225-30.
36. Salonen R, Seppanen K, Rauramaa R, Salonen JT. Prevalence of carotid atherosclerosis and serum cholesterol levels in Eastern Finland. *Atherosclerosis* 1988;8:788-92.
37. Alderman MH, Madhavan S, Ooi WL, Cohen H, Sealey JE, Laragh JH. Association of renin/sodium profile with risk of myocardial infarction in patients with hypertension. *N Engl J Med* 1991;324:1098-1104.
38. Sihm I, Schroeder AP, Aalkjaer C, et al. The relation between peripheral vascular structure, left ventricular hypertrophy and ambulatory blood pressure in essential hypertension. *Am J Hypertens* 1995;8:987-96.
39. Aronow WS, Kronzon I, Schoenfeld MR. Left ventricular hypertrophy is more prevalent in patients with systemic hypertension with extracranial carotid arterial disease than in patients with systemic hypertension without extracranial carotid artery disease. *Am J Cardiol* 1995;76:192-3.
40. Roman MJ, Pickering TG, Schwartz JE, Pini R, Devereux RB. Association of carotid atherosclerosis and left ventricular hypertrophy. *J Am Coll Cardiol* 1995;25:83-90.
41. Cuspidi C, Marabini M, Lonati L, et al. Cardiac and carotid structure in patients with established hypertension and white-coat hypertension. *J Hypertens* 1995;13:1707-11.
42. Pierdomenico SD, Lapenna D, Guglielmi MD, et al. Vascular changes in hypertensive patients with different left ventricular geometry. *J Hypertens* 1995;13:1701-6.
43. Cuspidi C, Lonati L, Sampieri L, Leonetti G, Zanchetti A. Similarities and differences in structural and functional changes of left ventricle and carotid arteries in young borderline hypertensives and in athletes. *J Hypertens* 1996;16:759-64.
44. Hughes AD, Sinclair AM, Geroulakos G, et al. Structural changes in the heart and carotid arteries associated with hypertension in humans. *J Human Hypertens* 1993;7:395-7.
45. Kronmal RA, Smith VE, O'Leary DH, Polak JF, Gardin JM, Manolio TA. Carotid artery measures are strongly associated with left ventricular mass in older adults (a report from the Cardiovascular Health Study). *Am J Cardiol* 1996;77:628-33.
46. Roman MMJ, Pickering TG, Pini R, Schwartz JE, Devereux RB. Determinants of cardiac and vascular hypertrophy in hypertension. *Hypertension* 1995;26:369-73.
47. Roman M, Saba PS, Pini R, et al. Parallel cardiac and vascular adaptation in hypertension. *Circulation* 1992;86:1909-18.
48. Schiffrin EL, Deng LY, Sventek P, Day R. Enhanced expression of endothelin-1 gene in severe human essential hypertension. *J Hypertens* 1997;15:57-63.
49. Rossi GP, Rossi A, Sacchetto A, Pavan E, Pessina AC. Hypertensive cerebrovascular disease and the renin-angiotensin system. *Stroke* 1995;26:1700-6.
50. Bouthier JD, De Luca N, Safar ME, Simon AC. Cardiac hypertrophy and arterial distensibility in essential hypertension. *Am Heart J* 1985;109:1345-52.
51. Brilla CG, Weber KT. Mineralocorticoid excess, dietary sodium and myocardial fibrosis. *J Lab Clin Med* 1992;120:893-901.
52. Young M, Fullerton M, Dilley R, Funder J. Mineralocorticoids, hypertension and cardiac fibrosis. *J Clin Invest* 1994;93:2578-83.
53. Simpson P, McGrath A, Savion S. Myocyte hypertrophy in neonatal rat heart cultures and its regulation by serum and catecholamines. *Circ Res* 1982;51:787-90.
54. Zierhut W, Zimmer HG. Significance of myocardial α - and β -adrenoceptors in catecholamine-induced cardiac hypertrophy. *Circ Res* 1989;65:1417-25.