DERMATOLOGICA SINICA 32 (2014) 33–36

Contents lists available at SciVerse ScienceDirect

Dermatologica Sinica

journal homepage: http://www.derm-sinica.com

CASE REPORT

A Taiwanese woman with Dowling-Degos disease: An electron microscopic study with pathophysiological significance

Wei-Tai Yu, Yung-Shun Su, Chih-Hung Lee*

Department of Dermatology, Kaohsiung Municipal Hsiao-Kang Hospital and Kaohsiung Medical University, Kaohsiung, Taiwan

ARTICLE INFO

Article history:
Received: Aug 24, 2012
Revised: Jan 16, 2013
Accepted: Jan 24, 2013

Keywords:
Dowling-Degos disease
electron microscope
keratin 5/14
reticulated pigmentation
Taiwan

ABSTRACT

Herein we report a rare case of classical Dowling-Degos disease (DDD) in a Taiwanese woman. A 23-year-old Taiwanese woman presented with generalized hyperpigmentation in irregular and reticulated shapes that she had had since junior high school. Her mother and two sisters had also developed similar pigmentations, starting during their teenage years. The patient did not have previous skin lesions or a history of trauma. She did not have any nail or hair abnormalities. Viewed through a microscope, the hyperpigmented area was found to have elongated rete ridges, the tips of which were found to have a concentration of melanin. Based on the disease onset, family history, clinical and histopathological manifestations, the patient was diagnosed as having DDD. We performed an electron microscopic study revealing a greater number of mature melanosomes in the keratinocytes in the pigmented skin than in those in the nonpigmented skin. The numbers of melanosomes in the melanocytes were similar in both types of skin. This is the first direct comparison of ultrastructural features in pigmented and uninvolved skin in Taiwanese with DDD. We follow the discussion of the case with the differential diagnosis and genetic abnormalities of diseases with reticulate pigmentations. This case report reminds us that keratin 5/14 plays a role in both keratinocyte integrity and melanin transfer.

Copyright © 2013, Taiwanese Dermatological Association.
Published by Elsevier Taiwan LLC. All rights reserved.

Introduction

Dowling-Degos disease (DDD) is an autosomal dominant disease that usually presents with reticulated pigmentations predominantly located in major flexural skin beginning in the teenage years.[1] It is also known as reticular pigmented anomaly of the flexures or postpubertal reticulate hyperpigmentation. These lesions are reticular and dark brown. Microscopically, there is a filiform epidermal down growth of epidermal rete ridges, with a concentration of melanin at the tips, without an increase in numbers of melanocytes. The genetic abnormalities of DDD are not unique to one gene. For example, genetic studies from affected families have identified mutations[2] and deletions[3] in the keratin 5 locus in DDD. However, Li et al found a gene locus responsible for DDD that maps to chromosome 17p13.3 in a Chinese family with DDD.[4] Thus, there appears to be phenotypic and genotypic heterogenecity in the pathogenesis of DDD.

Case report

A 23-year-old female presented to our dermatology outpatient clinic with the chief complaint of reticulated hyperpigmentation with irregular shapes, which she had had since junior high school (Figure 1A). According to the patient, her mother and sisters had also developed similar hyperpigmentation starting in their teenage years. She had neither previous skin lesions nor trauma history. The pigmented lesions were neither pruritic nor painful. There were no nail or hair abnormalities. Her mother, and her older and younger sisters had similar skin manifestations; however, her father and her brother did not have any abnormal hyperpigmentations (Figure 2). Skin biopsy over her hyperpigmented area revealed typical features of DDD, including filiform down growth of rete ridges and a concentration of melanin at the tips of the rete ridges (Figure 1B).

Further microscopic examination showed no significant changes in DOPA-reactive melanocytes (data not shown). Fontana-Masson stain showed that melanin expression was increased in the lesional skin (upper left, Figure 3). The patient was diagnosed with

Conflicts of interest: The authors declare that they have no financial or non-financial conflicts of interest related to the subject matter or materials discussed in this article.

* Corresponding author. Department of Dermatology, Kaohsiung Municipal Hsiao-Kang Hospital and Kaohsiung Medical University, 100 Shih-Chuan 1st Road, Kaohsiung 807, Taiwan. Tel.: +886 (0) 7 3121101x6105; fax: +886 (0) 7 3596111.
E-mail addresses: dermlee@gmail.com, zielee@hotmail.com (C.-H. Lee).

1027-8117/$ – see front matter Copyright © 2013, Taiwanese Dermatological Association. Published by Elsevier Taiwan LLC. All rights reserved.
http://dx.doi.org/10.1016/j.dsi.2013.01.003

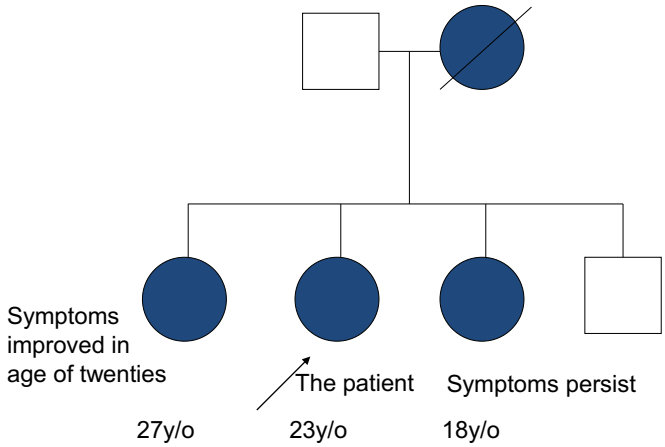

Figure 1 Family pedigree of the patient with Dowling-Degos disease.

DDD considering the disease onset, family history, clinical and histopathological manifestations. We then used a transmission electron microscope to identify whether the generation and maturation of melanosomes in lesional skin were different from those in normal skin.

Ultrastructurally, keratinocytes are readily recognized by the presence of keratin tonofilaments. Melanocytes are recognized by the presence of melanosomes in different stages without tonofilaments and desomosomes.[5] Melanosomes in different stages are distinguished by the presence of pigments, the structure and arrangements of internal membranes.[6] We counted and compared the numbers of mature melanosomes in melanocytes and the numbers of stage IV melanosomes among the mature melanosomes in basal and suprabasal keratinocytes.

Lesional skin and normal skin melanocytes had a similar number and proportion of mature melanosomes and had similar distributions and shapes. The percentage of mature melanosome among the total melanosomes was similar in melanocytes. In lesional skin, particularly in the portion of epidermal projection, the basal keratinocytes contained a significant percentage of Stage IV melanosomes among the mature melanosomes (Stage III and Stage IV). The relative percentage of Stage IV melanosomes among the mature melanosomes was significantly higher in the suprabasal keratinocytes in lesional skin than in the keratinocytes in normal skin. The similar numbers of melanosomes in melanocytes and the increased percentages of Stage IV melanosomes among mature melanosomes in suprabasal and basal keratinocytes suggest that the hyperpigmentations in the lesional skin of DDD might result from abnormalities in melanosome transfer and/or melanosome

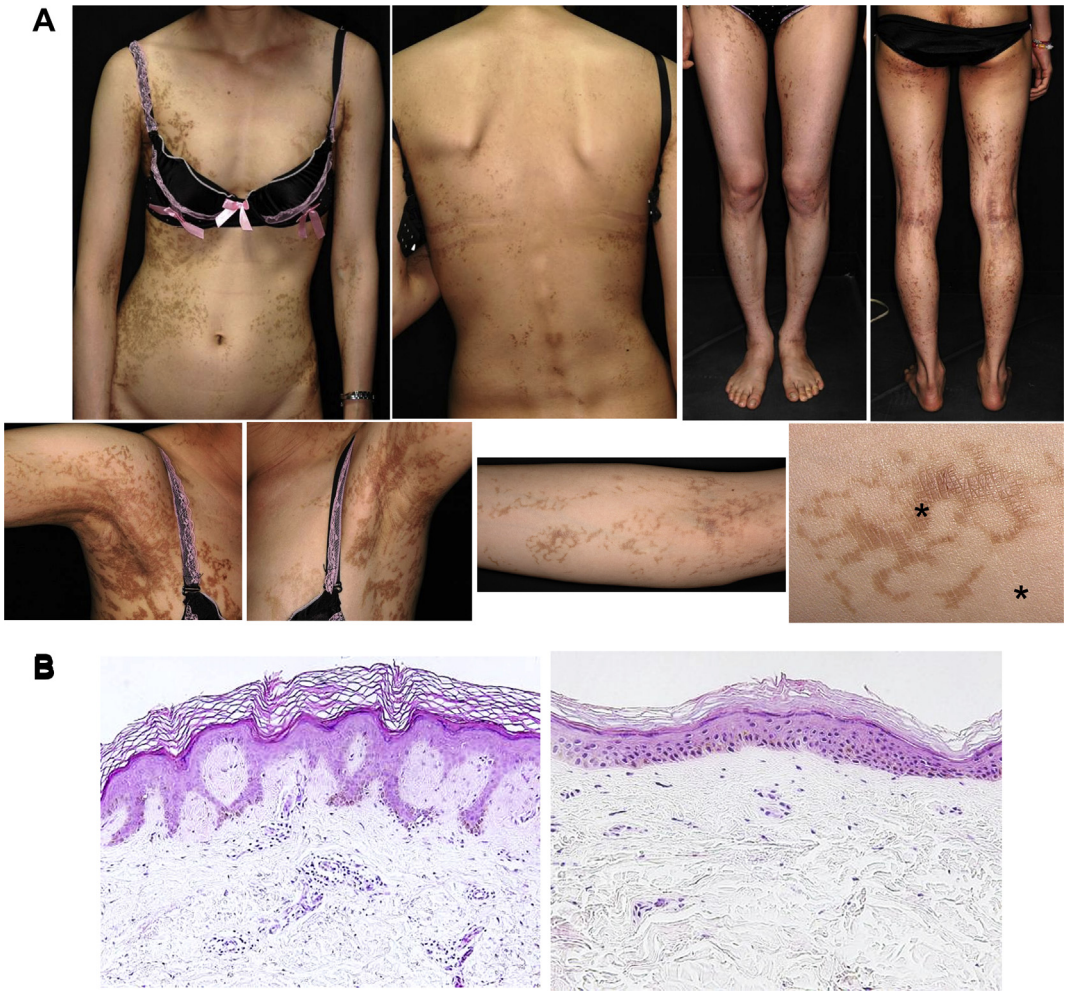

Figure 2 (A) Clinical features of a Taiwanese woman with Dowling-Degos disease. There was increased reticulate pigmentation in the flexural skin. * Indicates biopsy areas. (B) Histological and electron microscopic features of the lesional vs. nonlesional skin of the patient with Dowling-Degos disease. There was a filiform down growth of rete ridges and concentration of melanin at the tips of the rete ridges.

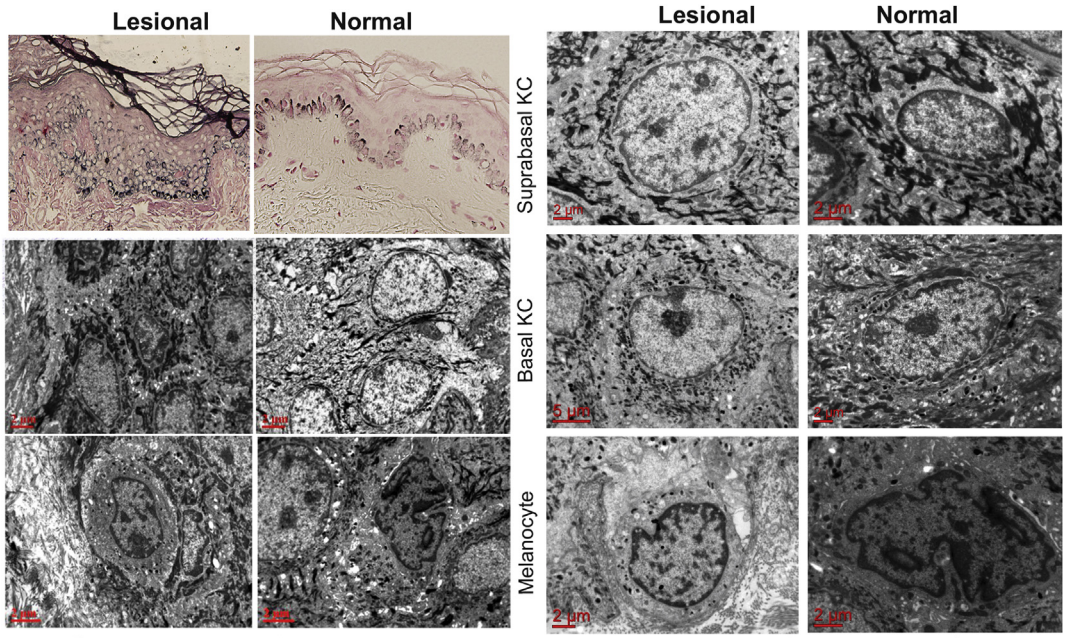

Cells	Parameter	lesional	normal
Suprabasal KC	# Stage 4 melanosome / # Mature melanosome	0.84 ± 0.11 **	0.33 ± 0.15
Basal KC	# Stage 4 melanosome / # Mature melanosome	0.56 ± 0.10 *	0.43 ± 0.11
Melanocyte	# Mature melanosomes / # Total melaonsomes	0.71 ± 0.12	0.64 ± 0.13

Mature melanosomes include those in stage 3 and stage 4.

Immature melanosomes include those in stage 1 and stage 2.

* p<0.05, **p<0.01

Figure 3 Fontana-Masson stain (upper left panel). The lesional skin and normal skin samples were stained for melanins. There was an increase in melanins in the lesional skin of Dowling-Degos disease. Electron microscopic findings (upper right panel) in melanocytes, basal keratinocytes, and suprabasal keratinocytes in lesional and normal skin. There were similar numbers of melanosomes in melanocytes; however, there were increased percentages of stage IV melanosomes among mature melanosomes in suprabasal and basal keratinocytes. Data are quantified in the table ($n = 3$, * $p < 0.05$).

maturation. After the patient was diagnosed as having DDD, we prescribed a topical retinoid acid, which produced only fair results after 6 months.

Discussion

Dowling et al first described DDD as a benign form of acanthosis nigricans.[7] Degos et al later helped delineate DDD from classical acanthosis nigricans.[8] The differential diagnosis of DDD from acanthosis nigricans is important because the latter might be associated with internal malignancies or insulin resistance.[9] Microscopically, the lesions from the pigmented skin of patients with DDD show elongated epidermal rete ridges with basal filiform hyperpigmentations.[10] Classical DDD is distinct from generalized DDD by the reticulate pigmentations without concomitant hypopigmentations.[1]

This report is the first to compare the lesional skin and nonlesional skin in DDD in Taiwanese of Han Chinese origin. The first ultrastructural study of DDD, which was reported in France, showed strong melanocytic activity with a substantial increase of the melanosomes in the pigmented skin but not in uninvolved axillary skin; however, in the keratinocytes the melanosomes were distributed in a dispersed pattern as in black skin.[11] Twenty-five years later, Zhang et al described the second electron microscopic investigation studying the affected skin of a Chinese woman with DDD.[12] They found regular melanosomes in all stages of maturation in melanocytes and increased mature melanosomes in scattering or capping patterns in the keratinocytes.[12]

Until the current study, there has been no direct comparison of the lesional skin and nonlesional skin in the Chinese population. We first compared the lesional skin and nonlesional skin of a Taiwanese woman with DDD clinically, histopathologically, and ultrastructurally. The number, shape, proportion, and distribution of melanosomes in melanocytes were similar in both lesional skin and normal skin. However, the percentage of stage IV melanosomes among the mature melanosomes was found to be increased in basal and suprabasal keratinocytes in lesional skin compared to unaffected skin. These ultrastructural findings suggest that defective melanosome transfer and/or maturation of melanosomes might be involved in the pathogenesis of DDD.

There are a large number of reticulated pigmentations that need to be distinguished, including dyskeratosis congenita (DKC), X-linked reticulate pigmentary disorder (XLRPD), Naegeli-Franceschetti-Jadassohn syndrome (NFJS), dermatopathia pigmentosa reticularis (DPR), DDD, reticulate acropigmentation of Kitamura (RAPK), and dyschromatosis hereditaria universalis (DHU).[13] DKC is characterized by nail atrophy, leukoplakia, and bone marrow failure.[14] NFJS is

featured as diffuse palmoplantar keratoderma with nail and teeth changes.[15] DPR can be distinguished by the presence of palmoplantar keratoderma with punctiform accentuation, nail and eye changes.[16] RAPK presents clinically with reticulate and freckle-like hyperpigmentation beginning on the dorsal hands in childhood, and microscopically shows increasing numbers of melanocytes.[17] DHU is characterized by variegated hyper–hypo pigmentation starting at a very young age,[6] while XLRPD shows amyloid deposits in the dermis of lesional skin.[18] The case of DDD in this study had no nail abnormalities and no deposits of amyloid, which excluded the diagnosis of DKC, NFJS and DPR, and the diagnosis of XLRPD, respectively. Disease onset helped exclude DHU. Disease onset and the fact there was no increase in DOPA-reactive melanocytes excluded RAPK, although several reports showed that the features of RAPK and DDD overlap.

DKC is caused by a number of genes, all of which encode products involved in telomere maintenance.[19] NFJS and DPR may share similar haploinsufficiency of keratin 14.[20,21] RAPK is usually sporadic. While no genetic studies have been performed yet, there appear to be some phenotypic similarities between DDD and RAPK. DHU may be caused by mutations of double-stranded RNA-specific adenosine deaminase gene.[22] DDD, as mentioned earlier, might result from mutations in keratin 5/14 or in chromosome 17. Thus, NFJS, DPR, and DDD might share some mutational loci. The common features of pigmentary abnormalities and the shared genetic abnormalities of keratin 5/14 in NFJS, DPR, and DDD suggest that keratin 5/14 in basal keratinocytes plays an important role in melanosome transfer. Planko et al found an association between keratin 14 with abnormal epidermal growth and impaired melanin transfer.[23] Certain K5/14 mutations also are known to result in the development of epidermolysis bullosa simplex (EBS), a mechanobullous disorder without pigmentary abnormalities. However, DDD usually occurs without blisters, suggesting a site-specific mutation genetic profile in keratin 5/14 might result in either cytoskeletal changes or melanin transfers. Studying 53 patients with EBS, Arin et al identified one patient that had compound heterozygosity for KRT5 mutations causing both DDD and EBS.[24] One question that needs resolution is why reticulate pigmentations, but not general hyperpigmentations, appear in the context of similar gene defects. The possible explanations may include genetic mosaicism and special distribution of melanin transfer.

In conclusion, we present the case of a Taiwanese woman with a family history of classical DDD. We directly compared the clinical, histopathological, and ultrastructural features between the pigmented skin and the uninvolved skin in samples taken from this patient. This case report suggests that the pigmentary abnormalities of DDD might result from abnormal melanosome transfer or maturation.

References

1. Wu YH, Lin YC. Generalized Dowling-Degos disease. *J Am Acad Dermatol* 2007;**57**:327–34.
2. Betz RC, Planko L, Eigelshoven S, et al. Loss-of-function mutations in the keratin 5 gene lead to Dowling-Degos disease. *Am J Hum Genet* 2006;**78**: 510–9.
3. Liao H, Zhao Y, Baty DU, McGrath JA, Mellerio JE, McLean WH. A heterozygous frameshift mutation in the V1 domain of keratin 5 in a family with Dowling-Degos disease. *J Invest Dermatol* 2007;**127**:298–300.
4. Li CR, Xing QH, Li M, et al. A gene locus responsible for reticulate pigmented anomaly of the flexures maps to chromosome 17p13.3. *J Invest Dermatol* 2006;**126**:1297–301.
5. Ando H, Niki Y, Yoshida M, et al. Keratinocytes in culture accumulate phagocytosed melanosomes in the perinuclear area. *Pigment Cell Melanoma Res* 2010;**23**:129–33.
6. Nuber UA, Tinschert S, Mundlos S, Hauber I. Dyschromatosis universalis hereditaria: familial case and ultrastructural skin investigation. *Am J Med Genet A* 2004;**125A**:261–6.
7. Dowling GB, Freudenthal W. Acanthosis nigricans. *Proc R Soc Med* 1938;**31**: 1147–50.
8. Degos R, Ossipowski B. Reticulated pigmentary dermatosis of the folds: relation to acanthosis nigricans. *Ann Dermatol Syphiligr (Paris)* 1954;**81**:147–51.
9. Howell JB, Freeman RG. Reticular pigmented anomaly of the flexures. *Arch Dermatol* 1978;**114**:400–3.
10. Jones EW, Grice K. Reticulate pigmented anomaly of the flexures. Dowling Degos disease, a new genodermatosis. *Arch Dermatol* 1978;**114**:1150–7.
11. Grosshans E, Geiger JM, Hanau D, Jelen G, Heid E. Ultrastructure of early pigmentary changes in Dowling-Degos' disease. *J Cutan Pathol* 1980;**7**: 77–87.
12. Zhang RZ, Zhu WY. A study of immunohistochemical and electron microscopic changes in Dowling-Degos disease. *J Dermatol* 2005;**32**:12–8.
13. Schnur RE, Heymann WR. Reticulate hyperpigmentation. *Semin Cutan Med Surg* 1997;**16**:72–80.
14. Sirinavin C, Trowbridge AA. Dyskeratosis congenita: clinical features and genetic aspects. Report of a family and review of the literature. *J Med Genet* 1975;**12**:339–54.
15. Itin PH, Lautenschlager S, Meyer R, Mevorah B, Rufli T. Natural history of the Naegeli-Franceschetti-Jadassohn syndrome and further delineation of its clinical manifestations. *J Am Acad Dermatol* 1993;**28**:942–50.
16. Rycroft RJ, Calnan CD, Allenby CF. Dermatopathia pigmentosa reticularis. *Clin Exp Dermatol* 1977;**2**:39–44.
17. Kitamura K. Peticulate acropigmentation, a world-wide disease. *Hautarzt* 1976;**27**:352–4 [in German].
18. Gedeon AK, Mulley JC, Kozman H, Donnelly A, Partington MW. Localisation of the gene for X-linked reticulate pigmentary disorder with systemic manifestations (PDR), previously known as X-linked cutaneous amyloidosis. *Am J Med Genet* 1994;**52**:75–8.
19. Mason PJ, Bessler M. The genetics of dyskeratosis congenita. *Cancer Genet* 2011;**204**:635–45.
20. Titeux M, Decha A, Pironon N, et al. A new case of keratin 14 functional knockout causes severe recessive EBS and questions the haploinsufficiency model of Naegeli-Franceschetti-Jadassohn syndrome. *J Invest Dermatol* 2011;**131**:2131–3.
21. Lugassy J, Itin P, Ishida-Yamamoto A, et al. Naegeli-Franceschetti-Jadassohn syndrome and dermatopathia pigmentosa reticularis: two allelic ectodermal dysplasias caused by dominant mutations in KRT14. *Am J Hum Genet* 2006;**79**: 724–30.
22. Suzuki N, Suzuki T, Inagaki K, et al. Mutation analysis of the ADAR1 gene in dyschromatosis symmetrica hereditaria and genetic differentiation from both dyschromatosis universalis hereditaria and acropigmentatio reticularis. *J Invest Dermatol* 2005;**124**:1186–92.
23. Planko L, Bohse K, Hohfeld J, et al. Identification of a keratin-associated protein with a putative role in vesicle transport. *Eur J Cell Biol* 2007;**86**: 827–39.
24. Arin MJ, Grimberg G, Schumann H, et al. Identification of novel and known KRT5 and KRT14 mutations in 53 patients with epidermolysis bullosa simplex: correlation between genotype and phenotype. *Br J Dermatol* 2010;**162**: 1365–9.