



Original Article

Screening of flavonoids rich fractions of three Indian medicinal plants used for the management of liver diseases



Arti Gupta^{a,*}, Navin R. Sheth^b, Sonia Pandey^a, Jitendra S. Yadav^c, Shrikant V. Joshi^a

^a Maliba Pharmacy College, Uka Tarsadia University Bardoli, Gujarat, India

^b Department of Pharmacognosy, Saurashtra University, Rajkot, Gujarat, India

^c Department of Pharmaceutics, Vidyabharti Trust College of Pharmacy, Bardoli, Gujarat, India

ARTICLE INFO

Article history:

Received 15 April 2015

Accepted 7 June 2015

Available online 21 August 2015

Keywords:

Paracetamol

Flavonoid-rich fractions

Butea monosperma

Bauhinia variegata

Ocimum gratissimum

Hepatoprotective activity

ABSTRACT

The decoctions of the *Butea monosperma* (Lam.) Taub., Fabaceae, *Bauhinia variegata* L., Fabaceae, and *Ocimum gratissimum* L., Lamiaceae, are traditionally used for the treatment of various types of hepatic disorder. Phytochemical studies have shown that total flavonoids from these plants were the major constituents of the picked out part of each plant. The present study was planned to investigate the hepatoprotective effect of flavonoid rich fractions of the *B. monosperma*, *B. variegata* and *O. gratissimum* against paracetamol induced liver damage. Flavonoid rich fractions were isolated by solvent fractionation from each plant. Each fraction was subjected to various qualitative chemical tests to find out the metabolites. Flavonoid fractions of each plant were subjected for pharmacological screening. The rats were monitored for change in liver morphology, biochemical parameters like serum glutamate pyruvate transaminase, serum glutamate oxaloacetate transaminase, alkaline phosphatase and total bilirubin for the groups receiving the flavonoid-rich fractions. All flavonoid rich fractions showed significant hepatoprotective activity. The histological studies supported the biochemical parameters. From the results of biochemical analysis and histopathological studies, it can be accomplished that in the ethyl acetate fraction of *O. gratissimum* showed highest hepatoprotective activity as compared to other fractions. The present study was the first evidence of flavonoid-rich fractions of each plant have a remarkable hepatoprotective effect. All fractions contain a potent hepatoprotective agent suggested to be a flavone, which may find clinical application in amelioration of paracetamol-induced liver damage.

© 2015 Sociedade Brasileira de Farmacognosia. Published by Elsevier Editora Ltda. All rights reserved.

Introduction

Liver diseases remain one of the serious health problems (Baranisrinivasan et al., 2009). Modern medications have little role to alleviation of hepatic disease and the plant-based preparations which are chiefly available medicines employed for the treatment of liver disorders (Raju et al., 2008). The strength of these plant products must be established, thus as to identify newer medications acting against hepatic injury. In the absence of a reliable liver protective drug in the modern system of medication, a number of medicinal plants in Ayurveda are recommended for the treatment of liver disorders. Natural treatments from medicinal plants are thought to be efficacious and safe medicaments for hepatotoxicity.

Butea monosperma (Lam.) Taub. (BM) belongs to family Fabaceae is a medium size deciduous tree, found throughout India and

traditionally used for the treatment of hepatopathy, ulcers, tumors, and diabetes (Kirtikar et al., 1999). The plant mainly contains flavones (quercetin) (Nadkarni, 1994; Gupta et al., 2013a), kinotannic acid and gallic acid.

Bauhinia variegata L. (BV) belongs to the family Fabaceae commonly known as Kachnar, is found to be beneficial in Ayurveda as a tonic to the liver and anti-inflammatory, healing activity, antioxidant activity (Bodakhe and Ram, 2007). It has been reported to contain quercetin, rutin, apigenin and apigenin 7-O-glucoside. Flavonoids and quercetin in particular are strong antioxidants and are known to regulate the activities of various enzyme systems due to their interaction with various biomolecules (Maldonado et al., 2003).

Ocimum gratissimum L. (OG) belongs to family Lamiaceae is an erect, multi-branched perennial shrub that grows up to a height of two meters with a tap root and many adventitious rootlets (Ramachandran et al., 1986). Essential oils obtained from *Ocimum* species showed various medicinal potentials in chemo-preventive, anti-carcinogenic, free radical scavenging, and radio-protective

* Corresponding author.

E-mail: arti.gupta@utu.ac.in (A. Gupta).

uses (Gupta et al., 2002; Onajobi, 1986; Prakash and Gupta, 2000). Additionally, OG leaf also revealed significant chemo-preventive effects on chemical-induced papilloma genesis by modulating metabolizing enzymes such as cytochrome P450, glutathione-S-transferase, and aryl hydrocarbon hydroxylase (Karthikeyan et al., 1999; Prashar et al., 1994). A recent study indicated that administered orally aqueous extract of OG leaf could oxidative and toxicant activity and enhance specific activities of hepatic antioxidant enzymes in rats (Ighodaro and Ebuehi, 2008). Notably, recent study also showed that the OG leaf aqueous extract (OGAE) may be important in protecting H9c2 cells from H₂O₂-induced cell death by inhibiting the mitochondrial dependent apoptosis pathway (Lee et al., 2010). Epicatechin, caffeic acid, rutin, gallic acid, quercetin, epigallocatechin gallate were identified as major components of phenolic acids and flavonoids in OGAE (Chiu et al., 2012; Grayer et al., 2000). Ursolic acid was determined in dichloromethane and ethyl acetate fractions of methanolic extract of *O. gratissimum* in previously published report (Gupta et al., 2013b).

The flavonoid, quercetin in acetone fraction of *B. monosperma*, ethyl acetate and *n*-butanol fractions of *B. variegata*; dichloromethane and ethyl acetate fractions of *O. gratissimum* were identified in previously published report (Gupta et al., 2013a).

Quercetin (flavonoid) and ursolic acid (triterpenic acid) are well known for its hepatoprotective effects in acute chemically induced liver injury and chronic liver fibrosis and cirrhosis (Janbaz et al., 2004).

Although these studies strongly implicated the medicinal effects of the above plants, there is no study for the beneficial effects of flavonoid rich fractions of these plants on paracetamol-induced hepatic injury. Therefore, in order to fully develop the medical plant resources and to justify the use of this preparation in traditional medicine for the treatment of liver complaint, the present study was designed to investigate the hepatoprotective effect of the flavonoid-rich fractions obtained from different parts of *B. monosperma*, *B. variegata* and *O. gratissimum* against paracetamol-induced liver injury *in vivo*.

Materials and methods

Animals

Albino Wistar male rats (125–175 g) were used for determination of maximum tolerable dose (MTD) and evaluation of hepatoprotective activity. The animals were housed in polypropylene cages at 25 ± 1 °C with the relative humidity of 55 ± 5% under 12/12 h light/dark cycles. They were received standard chow and water during experimentation. The food was withdrawn on the day before the experiment, but free access of water was allowed.

A minimum of six animals was used in each group. Throughout the experiment, animals were treated according to the suggested international ethical guidelines for the maintenance of laboratory animals. The study protocol was approved by the Institutional Animal Ethics Committee, according to the regulation of the Committee for the Purpose of Control and Supervision of Experiments on Animals (MPC 1007: dated: 30/01/2010).

Plant materials

The fresh bark of *Butea monosperma* (Lam.) Taub., Fabaceae (BM), *Bauhinia variegata* L., Fabaceae (BV) and fresh leaves of *Ocimum gratissimum* L., Lamiaceae (OG) were collected from the campus of Maliba pharmacy college, Bardoli. Voucher specimen (No: MPC/13032010/01, 2 and 03) has been deposited in the Department of Bioscience, Veer Narmad South Gujarat University, Surat, India. Rats were used for hepatoprotective study, with prior approval

from the Institutional Animal Ethical Committee (Registration No. 717/02/a/CPCSEA/30 Jan 2010) of Maliba Pharmacy College, Uka Tarsadia University.

Extraction and fractionation procedures

The dried and powdered material of each plant (500 g) was extracted with methanol at room temperature for three weeks with shaking and stirring. Combined methanolic extracts were evaporated to dryness under reduced pressure below 40 °C and then dissolved in distilled water and subjected to solvent–solvent fractionation.

B. monosperma: Methanolic extract obtained was fractionated with petroleum ether, benzene, chloroform and acetone in the order of their increasing polarity to obtain respective fractions (Sharma and Deshwal, 2011).

B. variegata: Methanolic extract was fractionated with hexane, ethyl acetate and *n*-butanol in the order of their increasing polarity to obtain respective fractions (Silva et al., 2008).

O. gratissimum: Methanolic extract was fractionated with hexane, dichloromethane and ethyl acetate in the order of their increasing polarity to obtain respective fractions (Chattopadhyay, 2003).

Each fraction was concentrated to dryness under reduced pressure and below (40–50 °C) on a rotary evaporator to give acetone fraction of *B. monosperma* [yield 9.4%, w/w], ethyl acetate fraction [yield 2.2%, w/w] and *n*-butanol fraction [yield 5.0%, w/w] of *B. variegata* and dichloromethane fraction [yield 4.2% w/w] and ethyl acetate fraction [yield 4.8%, w/w] of *O. gratissimum*, respectively.

Establishment of qualitative and quantitative phytoprofile of fractionated extracts

Qualitative phytochemical analysis

Each fraction was subjected to various qualitative chemical tests using reported methods to determine the presence or absence of metabolites *viz.*, alkaloids, tannins, flavonoid, steroid, terpenoids and phenolic compounds etc. (Khandelwal, 2001).

Chemical test for flavonoids. Chemical tests were performed for flavonoids according to Macdonald (Macdonald et al., 2010).

Quantitative phytochemical analysis

Determination of total phenols. Each sample was mixed with 1 ml Folin-Ciocalteu reagent and 0.8 ml of 7.5% Na₂CO₃. The resultant mixture was evaluated at 765 nm after 2 h at room temperature. The mean of three readings was used and the total phenolic content was expressed in milligram of gallic acid equivalents/1 g extract. The coefficient of determination was found to be $r^2 = 0.992$ (Yuvaraj et al., 2011).

Determination of total flavonoids. Standard quercetin was used to create the calibration curve [0.04, 0.02, 0.0025 and 0.00125 mg/ml in 80% ethanol (v/v)]. The standard solutions and test samples (0.5 ml) of each fraction was mixed with 1.5 ml of 95% ethanol (v/v), 0.1 ml of 10% aluminum chloride (w/v), 0.1 ml of 1 mol/l sodium acetate and 2.8 ml water. The volume of 10% aluminum chloride was substituted by the same volume of distilled water in the blank. After incubation at room temperature for 30 min, the absorbance of the reaction mixture of each sample and standard solution was measured at 415 nm. The mean of three readings was used and the total flavonoid content was expressed in milligram of quercetin equivalents/1 g extract. The coefficient of determination was $r^2 = 0.99020$ (Kosalec et al., 2004).

In vivo hepatoprotective activity of selected flavonoid fractions of *B. monosperma*, *B. variegata* and *O. gratissimum* against paracetamol-induced toxicity

Test animals

Male Wistar rats (125–175 g) were used for determination of maximum tolerable dose and evaluation of hepatoprotective activity of flavonoid rich fractions of *B. monosperma*, *B. variegata* and *O. gratissimum*. The animals were housed in polypropylene cages at $25 \pm 1^\circ\text{C}$ with the relative humidity of $55 \pm 5\%$ less than 12/12 h light/dark cycles. They were received a standard chow and water *ad libitum* during experimentation. The food was withdrawn on the day before the experiment, but free access of water was allowed. A minimum of six animals was used in each group. Throughout the experiments, animals were treated according to the suggested international ethical guidelines for the maintenance of laboratory animals. The study protocol was approved by the Institutional Animal Ethics Committee, according to the regulation of committee for the purpose of control and supervision of experiments on animals (MPC 1007: dated: 30/01/2010).

Preparation and administration of test samples

The approved IAEC method was adopted for screening of hepatoprotective activity. Dried fractions were suspended in 1% CMC solution before oral administration to animals. Animals were divided into five groups of six rats each were used for the study. Group 1 and 2 received normal saline (1 ml/kg orally) for seven days. Groups 3, 4, 5, 6, 7 and 8 received 100 mg/kg bw dose of silymarin, acetone fraction of *B. monosperma*, ethyl acetate and *n*-butanol fractions of *B. variegata* and dichloromethane and ethyl acetate fractions of *O. gratissimum* at 100 mg/kg of each orally, once a day for seven days. On the fifth day, after the administration of the respective treatments, all the animals in groups 2, 3, 4, 5, 6, 7 and 8th were administered paracetamol (PCM) 2 g/kg orally. On the seventh day, the blood samples were collected *via* orbital sinus puncture for the estimation of biochemical marker enzymes. Then the liver was carefully isolated and cleaned off extraneous tissue and preserved in 10% neutral formalin and then subjected to histopathological studies (Parasuraman et al., 2010; Puratchikody et al., 2006).

Assessment of biochemical parameters of liver

The enzymatic parameters of serum like serum glutamate pyruvate transaminase (SGPT), serum glutamate oxaloacetate transaminase (SGOT) and serum alkaline phosphatase (ALP) and non-enzymatic parameter like total bilirubin (TB) were assayed according to standard methods (Varley et al., 1994).

Statistical analysis

The outcomes are shown as mean \pm S.E.M. ($n = 6$). Statistical significance was determined by one-way analysis of variance with $p < 0.01$ and $p < 0.05$ considered significant followed by Dunnett Multiple Comparisons Test. The analysis was performed by Graph Pad InStat software.

Results

Phytochemical screening

Preliminary phytochemical screening of alcoholic extract and its fractions showed the presence of flavonoids, steroids, terpenoids, tannins and phenolic compounds. The chemical test analysis demonstrated that acetone fraction of *B. monosperma*, ethyl acetate

fraction and *n*-butanol fraction of *B. variegata*, dichloromethane and ethyl acetate fractions of *O. gratissimum* were rich in phenolic compounds. The phenolic content in *B. monosperma* (acetone fraction), *B. variegata* (ethyl acetate and *n*-butanol fractions) and *O. gratissimum* (dichloromethane and ethyl acetate fractions) were found to be 452 ± 1.6 , 712.4 ± 2.4 , 442.5 ± 1.1 , 735 ± 2.1 and 1365 ± 1.4 mg gallic acid/1 g fraction respectively. The flavonoid content in *B. monosperma* (acetone fraction), *B. variegata* (ethyl acetate and *n*-butanol fractions) and *O. gratissimum* (dichloromethane and ethyl acetate fractions) were found to be 251 ± 1.8 , 417 ± 2.2 , 227 ± 3.2 , 394.5 ± 2.4 and 717 ± 5.2 mg quercetin/1 g fraction respectively. The phenol and flavonoid contents are responsible for hepatoprotective activity; hence these solvent fractions were taken for further work.

Evaluation of hepatoprotective activity

From the effects of acute toxicity study by previously published literature, 2000 mg/kg was considered as maximum tolerable dose of alcoholic extract of *B. monosperma* (Muralidhar et al., 2011), *B. variegata* (Balamurugan and Muralidharan, 2010) and *O. gratissimum* (Okoli et al., 2010). 1/20th of this dose was considered as an experimental dose for subsequent hepatoprotective studies. The effective dose of each fraction was decided on the basis of previously published reports, *i.e.* 100 mg/kg of body weight.

Paracetamol has enhanced the levels of SGPT, SGOT, ALP and total bilirubin. The results indicated that the flavonoid rich fractions of *B. monosperma*, *B. variegata* and *O. gratissimum* significantly reduced the elevated levels of SGPT, SGOT, ALP and bilirubin when compared to paracetamol treated group. The results are shown in Figs. 1 and 2.

Histopathological examination of the liver sections confirmed that the normal liver architecture was damaged with paracetamol administration. However, pretreatment of fractions of alcoholic extracts of *B. monosperma*, *B. variegata* and *O. gratissimum* at 100 mg/kg dose, significantly reduced the severity of histopathological injury (compared with the paracetamol group). The results of the biochemical tests and histopathological observations suggest that 100 mg/kg of each fraction is effective against liver toxicity. Rats treated with each flavonoid fraction of *B. monosperma*, *B. variegata* and *O. gratissimum* showed noticeable improvement in histopathological parameters. Thus, each fraction is considered as prominent on paracetamol-induced liver damage. Moreover, at necropsy, livers of rats treated with paracetamol appeared degeneration in hepatocytes, hepatic cell injury, focal necrosis, congestion in central vein, vascular swelling, kupffer cell proliferation. Furthermore, no gross pathological findings were noted in the livers of the other groups of rats. The results are shown in Table 1 and Fig. 3.

Discussion

Because *B. monosperma*, *B. variegata* and *O. gratissimum* are widely used in folk medicine for the treatment of liver diseases, we investigated the hepatoprotective activity of the flavonoid rich fractions of each plant using two paracetamol induced liver toxicity models. Several mechanisms may be linked up with the damage done to the liver by different hepatotoxins. In the paracetamol model, the drug is supposed to be eliminated mainly as sulfate and glucuronide. Just a modest quantity (5%) is metabolized *via* the cytochrome P₄₅₀ enzyme system to the alkylating metabolite, *N*-acetyl-*p*-benzoquinoneimine (NAPQI), which is responsible for the toxic side effects of paracetamol. Yet, upon administration of toxic doses of paracetamol, the sulfation and glucuronidation routes become

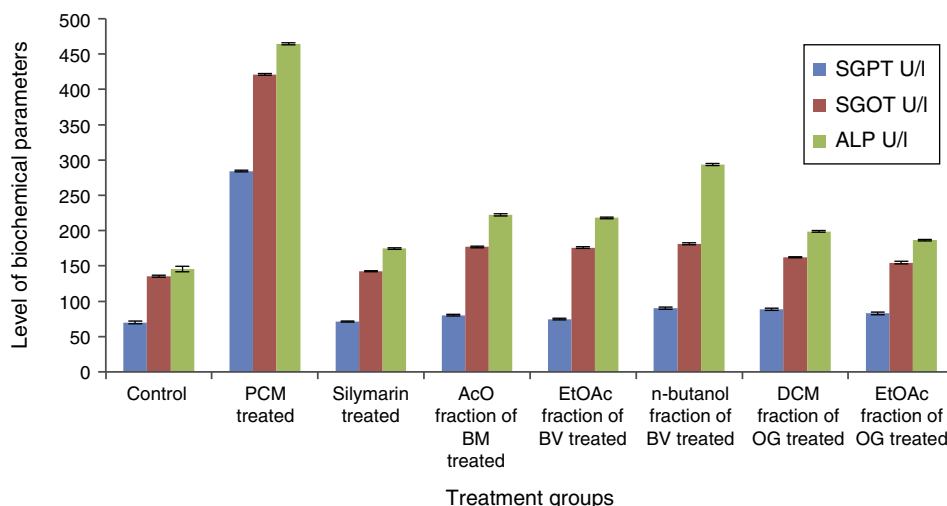


Fig. 1. Effect of all flavonoid fractions obtained from the alcoholic extract of *Butea monosperma*, *Bauhinia variegata* and *Ocimum gratissimum* on SGOT, SGPT and ALP (U/L) in paracetamol induced hepatic injury in rats.

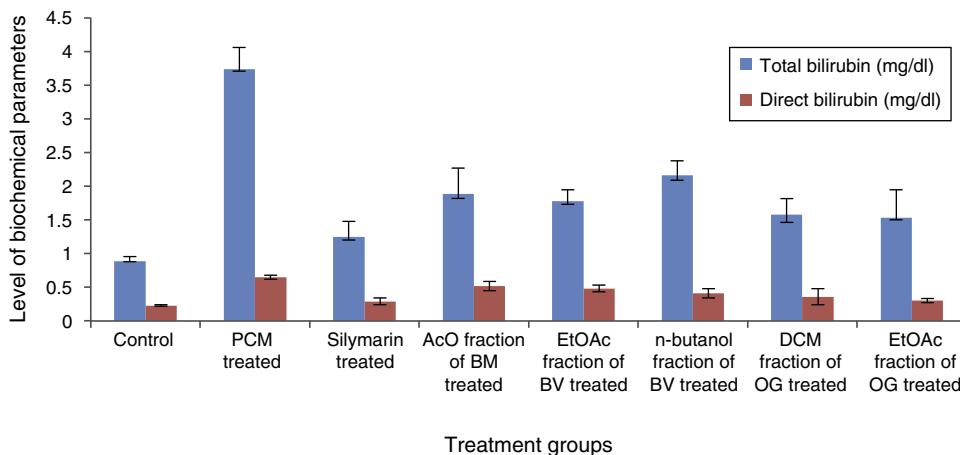


Fig. 2. Effect of all flavonoid fractions obtained from the alcoholic extract of *Butea monosperma*, *Bauhinia variegata* and *Ocimum gratissimum* on total bilirubin (mg/dl) in paracetamol induced hepatic injury in rats.

Table 1

Histopathological changes in the liver of rats.

Microscopic observation	Control	Paracetamol	Silymarin	Acetone fr. of BM	Ethyl acetate fraction of BV	n-Butanol fraction of BV	Dichloromethane fraction of OG	Ethyl acetate fraction of OG
Degeneration in hepatocytes	+	+++	++	++	++	++	++	++
Hepatic cell injury	∅	+++	++	+∟	+∟	+∟	+∟	+∟
Focal necrosis	∅	+++	∅	+∟	+∟	+∟	+∟	+∟
Congestion in central vein	+	+++	+	+∟	+∟	+∟	+∟	+∟
Vascular swelling	+	+++	+	++	+∟	+∟	+∟	+∟
Kupffer cell proliferation	∅	++	+	++	+∟	+∟	+∟	++

∅, absent; ∟, few; + mild; ++, moderate; +++, severe; +++++, extremely severe.

saturated, and thus, higher part of paracetamol molecules are oxidized to highly reactive NAPQI. Higher dose of paracetamol and NAPQI can alkylate and oxidize intracellular glutathione (GSH) and protein thiol groups, which result in the depletion of liver GSH pool and subsequently lead to increased lipid peroxidation and liver damage (Akah and Odo, 2010; Dong et al., 2000).

In this study, flavonoid fraction of *B. monosperma*, *B. variegata* and *O. gratissimum* demonstrated significant ($p < 0.01$ and $p < 0.05$) liver protection against the hepatic injuries caused by the paracetamol. It is apparent that several phytoconstituents have the power to induce microsomal enzymes either by accelerating the excretion of the hepatotoxin or by suppression of lipid peroxidation induced by

it (Mehta et al., 1999). Phytoconstituents like flavonoids (Baek et al., 1996; Pandit et al., 2004) and triterpenes (ursolic acid) (Xiong et al., 2003) are known to possess hepatoprotective activities. Liver protective herbal drugs contain a variety of chemical constituents like phenols and flavonoids (Sharma et al., 1991). There is every possibility that these active principles alone or in combination may be responsible for the hepatoprotection demonstrated in this work. Recently, total flavonoids were reported to protect animals from liver injury and liver fibrosis (Singab et al., 2005; Yuan et al., 2008; Zhong et al., 2007). The protective effect exhibited by the flavonoid fractions could be due to the protection of hepatic drug metabolizing enzymes. It is therefore concluded that the flavonoid fraction

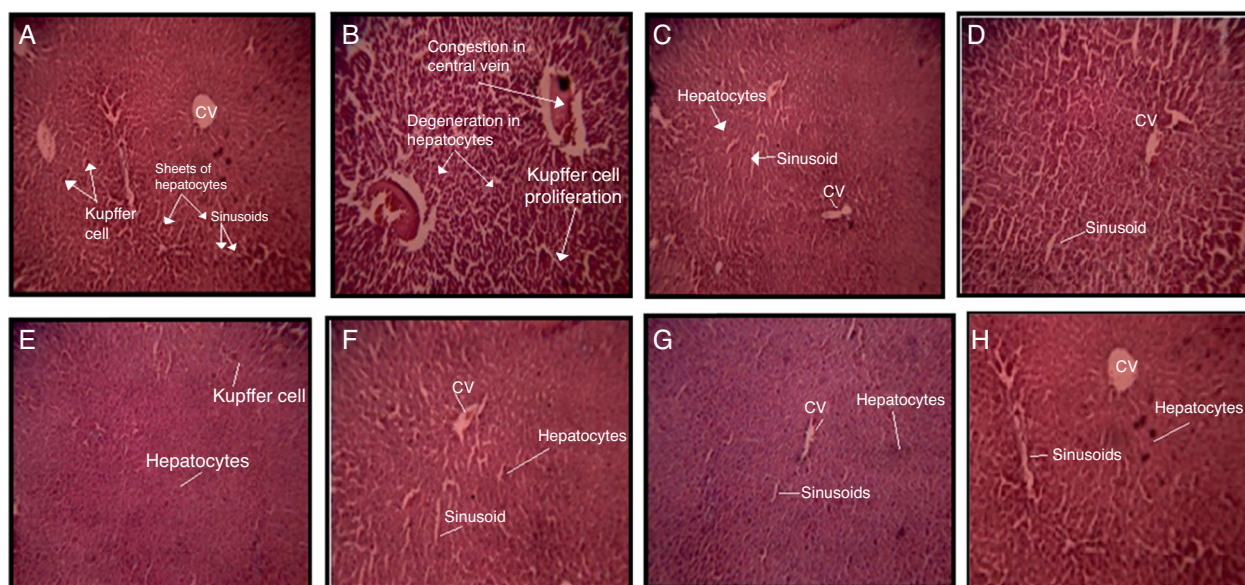


Fig. 3. The photomicrographs of liver section from rats: (A) received saline 0.5 ml as a normal control group (10 × 10); (B) paracetamol (2 g/kg) (10 × 10); (C) silymarin (100 mg/kg bw.) + paracetamol (10 × 10); (D) acetone fraction of BM (100 mg/kg bw.) + paracetamol; (E) ethyl acetate fraction of BV (100 mg/kg bw.) + paracetamol; (F) *n*-butanol fraction of BV (100 mg/kg bw.) + paracetamol; (G) dichloromethane fraction of the OG (100 mg/kg bw.) + paracetamol; and (H) ethyl acetate fraction of the OG (100 mg/kg bw.) + paracetamol.

of *B. monosperma*, *B. vareigata* and *O. gratissimum* have promising hepatoprotective potentials.

Conclusions

The hepatoprotective effect of flavonoid rich fractions of *B. monosperma*, *B. vareigata* and *O. gratissimum* may be attributed due to the reduced SGPT, SGOT, ALP and bilirubin and improved defense of the hepatocytes against the paracetamol. The histopathological studies also confirm the action of the drug. Thus the study scientifically supports the usage of flavonoid rich fractions of *B. monosperma*, *B. vareigata* and *O. gratissimum* for treatment of liver disorders and as a tonic. To elucidate the exact mechanism responsible for the hepatoprotective effects of flavonoid rich fractions of *B. monosperma*, *B. vareigata* and *O. gratissimum*, further experiments are being conducted in our laboratory.

Author contributions

The AG was responsible for the plant collections, performed the experiments, analyzed the data and wrote the report. JSY and SP supervised the entire work, analyzed the data and did a critical reading of the manuscript. SVJ helped in biological studies.

Conflicts of interest

The authors declare no conflicts of interest.

Acknowledgements

The authors express their sincere thanks to Dr. Bhavin Vyas and Janki Desai from Department of Pharmacology for their help.

References

- Akah, P.A., Odo, C.I., 2010. Hepatoprotective effect of the solvent fractions of the stem of *Hoslundia opposita* Vahl (Lamiaceae) against carbon tetrachloride- and paracetamol-induced liver damage in rats. *Int. J. Green Pharm.* 4, 54–58.
- Baek, N., Kim, Y., Kyung, J., Park, K., 1996. Isolation of anti-hepatotoxic agent from the root of *Astragalus membranaceus*. *Korean J. Pharmacogn.* 27, 111–116.
- Balamurugan, G., Muralidharan, P., 2010. Antiobesity effect of *Bauhinia variegata* L. bark extract on female rats fed on hypercaloric diet. *Bangladesh J. Pharmacol.* 5, 8–12.
- Baranisrinivasan, P., Elumalai, E.K., Sivakumar, C., Viviyana Therasa, S., David, E., 2009. Hepatoprotective effect of *Enicostemma littorale* blume and *Eclipta albaduring* ethanol induced oxidative stress in albino rats. *Int. J. Pharmacol.* 5, 268–272.
- Bodakhe, S.H., Ram, A., 2007. Hepatoprotective properties of *Bauhinia variegata* L. bark extract. *Yakugaku zasshi* 127, 1503–1507.
- Chattopadhyay, R., 2003. Possible mechanism of hepatoprotective activity of *Azadirachta indica* eaf extract: Part II. *J. Ethnopharmacol.* 89, 217–219.
- Chiu, C.-C., Huang, C.-Y., Chen, T.-Y., Kao, S.-H., Liu, J.-Y., Wang, Y.-W., Tzang, B.-S., Hsu, T.-C., 2012. Beneficial effects of *Ocimum gratissimum* aqueous extract on rats with CCl₄-induced acute liver injury. *Evid.-Based Complement. Altern. Med.*, <http://dx.doi.org/10.1155/2012/736752>.
- Dong, H., Haining, R.L., Thummel, K.E., Rettie, A.E., Nelson, S.D., 2000. Involvement of human cytochrome P450 2D6 in the bioactivation of acetaminophen. *Drug Metab. Dispos.* 28, 1397–1400.
- Grayer, R.J., Kite, G.C., Abou-Zaid, M., Archer, L.J., 2000. The application of atmospheric pressure chemical ionisation liquid chromatography–mass spectrometry in the chemotaxonomic study of flavonoids: characterisation of flavonoids from *Ocimum gratissimum* var. *gratissimum*. *Phytochem. Anal.* 11, 257–267.
- Gupta, A., Sheth, N.R., Pandey, S., Shah, D.R., Yadav, J.S., 2013a. Design and evaluation of herbal hepatoprotective formulation against paracetamol induced liver toxicity. *J. Young Pharm.* 5, 180–187.
- Gupta, A., Sheth, N.R., Pandey, S., Shah, D.R., Yadav, J.S., 2013b. Determination of ursolic acid in fractionated leaf extracts of *Ocimum gratissimum* L. and in developed herbal hepatoprotective tablet by HPTLC. *Pharmacogn. J.* 5, 156–162.
- Gupta, S., Prakash, J., Srivastava, S., 2002. Validation of traditional claim of *Tulsi*, *Ocimum sanctum* Linn. as a medicinal plant. *Indian J. Exp. Biol.* 40, 765–773.
- Ighodaro, O., Ebuehi, O., 2008. Aqueous leaf extract of *Ocimum gratissimum* potentiates activities of plasma and hepatic antioxidant enzymes in rats. *Niger. Q. J. Hosp. Med.* 19, 106–109.
- Janbaz, K., Saeed, S., Gilani, A., 2004. Studies on the protective effects of caffeic acid and quercetin on chemical-induced hepatotoxicity in rodents. *Phytomedicine* 11, 424–430.
- Karthikeyan, K., Ravichandran, P., Govindasamy, S., 1999. Chemopreventive effect of *Ocimum sanctum* on DMBA-induced hamster buccal pouch carcinogenesis. *Oral Oncol.* 35, 112–119.
- Khandelwal, K., 2001. *Pharmacognosy: techniques and experiments*. Nirali Prakashan 8, 3–40, 146–161.
- Kirtikar, K., Basu, B., Dun, D., Singh, B., Singh, M., 1999. *Indian medicinal plants Dehradun 1964–1965*.
- Kosalec, I., Bakmaz, M., Pepeljnjak, S., Vladimir-Knezevic, S., 2004. Quantitative analysis of the flavonoids in raw propolis from northern Croatia. *Acta Pharm. Zagreb* 54, 65–72.
- Lee, M.-J., Chen, H.-M., Tzang, B.-S., Lin, C.-W., Wang, C.-J., Liu, J.-Y., Kao, S.-H., 2010. *Ocimum gratissimum* aqueous extract protects H9c2 myocardial cells from H₂O₂-induced cell apoptosis through Akt signalling. *Evid.-Based Complement. Altern. Med.*, <http://dx.doi.org/10.1155/2011/578060>.
- Macdonald, I.O., Oludare, A.S., Olabiya, A., 2010. Phytoxic and anti-microbial activities of flavonoids in *Ocimum gratissimum*. *Life Sci. J.* 7, 3.

- Maldonado, P.D., Barrera, D., Rivero, I., Mata, R., Medina-Campos, O.N., Hernández-Pando, R., Pedraza-Chaverri, J., 2003. Antioxidant S-allylcysteine prevents gentamicin-induced oxidative stress and renal damage. *Free Rad. Biol. Med.* 35, 317–324.
- Mehta, R., Shankar, M., Geetha, M., Saluja, A., 1999. Hepatoprotective activity of *Trianthema portulacastrum*. *Indian Drugs* 36, 241–244.
- Muralidhar, A., Babu, K.S., Sankar, T.R., Reddanna, P., Latha, J., 2011. Evaluation of wound healing properties of bioactive fractions from the extract of *Butea monosperma* (Lam.) Taub (lam) stem bark. *Int. J. Phytomed.* 3, 41–49.
- Nadkarni, K.M., 1994. *Dr. KM Nadkarni's Indian materia medica. 1. Popular Prakashan.*
- Okoli, C., Ezike, A., Agwagah, O., Akah, P., 2010. Anticonvulsant and anxiolytic evaluation of leaf extracts of *Ocimum gratissimum*, a culinary herb. *Pharmacogn. Res.* 2, 36–40.
- Onajobi, F.D., 1986. Smooth muscle contracting lipid-soluble principles in chromatographic fractions of *Ocimum gratissimum*. *J. Ethnopharmacol.* 18, 3–11.
- Pandit, S., Sur, T., Jana, U., Debnath, P., Sen, S., Bhattacharyya, D., 2004. Prevention of carbon tetrachloride-induced hepatotoxicity in rats by *Adhatoda vasica* leaves. *Indian J. Pharmacol.* 36, 312–313.
- Parasuraman, S., Raveendran, R., Kesavan, R., 2010. Blood sample collection in small laboratory animals. *J. Pharmacol. Pharmacother.* 1, 87–93.
- Prakash, J., Gupta, S., 2000. Chemopreventive activity of *Ocimum sanctum* seed oil. *J. Ethnopharmacol.* 72, 29–34.
- Prashar, R., Kumar, A., Banerjee, S., Rao, A., 1994. Chemopreventive action by an extract from *Ocimum sanctum* on mouse skin papillomagenesis and its enhancement of skin glutathione S-transferase activity and acid soluble sulfhydryl level. *Anticancer Drugs* 5, 567–572.
- Puratchikody, A., Devi, C.N., Nagalakshmi, G., 2006. Wound healing activity of *Cyperus rotundus* linn. *Indian J. Pharm. Sci.* 68, 97–101.
- Raju, R.W., Radhika, S.S., Kunal, M.T., Kalpana, S.P., Sunil, S.J., 2008. Screening of roots of *Baliospermum montanum* for hepatoprotective activity against paracetamol induced liver damage in albino rats. *Int. J. Green Pharm.* 2, 220–223.
- Ramachandran, K., Kashyapa, K., Chand, R., 1986. *The Useful Plants of India. Council of Scientific and Industrial Research, New Delhi*, pp. 671–679.
- Sharma, A., Chakraborti, K., Handa, S., 1991. Antihepatotoxic activity of some Indian herbal formulations as compared to silymarin. *Fitoterapia* 62, 229–235.
- Sharma, A.K., Deshwal, N., 2011. An overview: on phytochemical and pharmacological studies of *Butea monosperma*. *Int. J. Pharm. Tech. Res.* 3, 864–871.
- Singab, A.N.B., Youssef, D.T., Noaman, E., Kotb, S., 2005. Hepatoprotective effect of flavonol glycosides rich fraction from Egyptian *Vicia calcarata* desf. against CCl₄-induced liver damage in rats. *Arch. Pharm. Res.* 28, 791–798.
- Silva, M.G., Vieira, I.G., Mendes, F.N., Albuquerque, I.L., dos Santos, R.N., Silva, F.O., Morais, S.M., 2008. Variation of ursolic acid content in eight *Ocimum* species from northeastern Brazil. *Molecules* 13, 2482–2487.
- Yuan, L.-P., Chen, F.-H., Ling, L., Dou, P.-F., Bo, H., Zhong, M.-M., Xia, L.-J., 2008. Protective effects of total flavonoids of *Bidens pilosa* L. (TFB) on animal liver injury and liver fibrosis. *J. Ethnopharmacol.* 116, 539–546.
- Yuvaraj, P., Louis, T., Madhavachandran, V., Gopinath, N., Rekha, S., 2011. Total phenolic content and screening of antioxidant activity of selected ayurvedic medicinal plants. *Ayurvedic Renaiss.* 91, 25–31.
- Varley, H., Van, E., Kass, I., 1994. *Practical clinical chemistry. William Heinemann Med. Books London* 1, 891–907.
- Xiong, X., Chen, W., Cui, J., Yi, S., Zhang, Z., Li, K., 2003. Zhong yao cai Zhongyao cai (Effects of ursolic acid on liver-protection and bile secretion). *J. Chin. Med. Mater.* 26, 578–581.
- Zhong, M.M., Chen, F.H., Yuan, L.P., Wang, X.H., Wu, F.R., Yuan, F.L., Cheng, W.M., 2007. Protective effect of total flavonoids from *Bidens bipinnata* L. against carbon tetrachloride-induced liver injury in mice. *J. Pharm. Pharmacol.* 59, 1017–1025.