



Journal of Coloproctology

www.jcol.org.br



Case Report

Repair of post polypectomy colonic perforation by Endoclip: a case report



Ahmad Hormati^{a,*}, Mohmad Reza Ghadir^a, Pezhman Alavinejad^b,
Seyed Saeed Sarkeshikian^a, Mahdi Pezeshki Modares^a

^a Division of Gastroenterology and Hepatology, Department of Internal Medicine, Qom University of Medical Sciences, Qom, Iran

^b Research Center for Infectious Diseases of Digestive System, Ahvaz Jundishapur University of Medical Sciences, Ahvaz, Iran

ARTICLE INFO

Article history:

Received 16 June 2015

Accepted 28 August 2015

Available online 21 September 2015

Keywords:

Polypectomy

Colonic perforation

Endoclip

Palavras-chave:

Polipectomia

Perfuração de cólon

Endoclip

ABSTRACT

A 73-year-old woman was admitted to evaluate for iron deficiency anemia, increased serum creatinine, and ascites. Her colonoscopy revealed a polyp at the junction of sigmoid and descending colon, and after polypectomy, a 6mm colonic perforation was seen. The perforation was detected by radiography and CT scan; and beside conservative management and antibiotics, her perforation was closed by using Endoclip. The patient was observed and discharged from hospital without any surgery 5 days later, and in follow-up there was no problem regarding perforation.

© 2015 Sociedade Brasileira de Coloproctologia. Published by Elsevier Editora Ltda. All rights reserved.

Reparo de perfuração de cólon pós-polipectomia por Endoclip: relato de caso

RESUMO

Mulher, 73 anos, internada para avaliação para anemia ferropriva, com aumento da creatinina sérica e ascite. A colonoscopia revelou um pólipó na junção dos colos sigmoide e descendente e, em seguida à polipectomia, foi observada uma perfuração de 6 mm no cólon, comprovada por radiografias e tomografia computadorizada. Além do tratamento conservador e da antibioticoterapia, a perfuração foi ocluída com Endoclip. A paciente ficou sob observação e recebeu alta do hospital sem qualquer cirurgia 5 dias mais tarde. Durante o seguimento, não foram observados problemas com relação à perfuração.

© 2015 Sociedade Brasileira de Coloproctologia. Publicado por Elsevier Editora Ltda. Todos os direitos reservados.

* Corresponding author.

E-mail: hormatia@yahoo.com (A. Hormati).

<http://dx.doi.org/10.1016/j.jcol.2015.08.002>

2237-9363/© 2015 Sociedade Brasileira de Coloproctologia. Published by Elsevier Editora Ltda. All rights reserved.

Introduction

Perforation is one of the most important complication of colonoscopy that is rare but potentially has a high rate of mortality and morbidity.^{1,2} Incidence of perforation is 0.016% in diagnostic colonoscopy but raises up to 5% following therapeutic colonoscopy³ and the most common site of perforation is sigmoid colon.⁴ In this case report, we review endoscopic management of colon perforation after polypectomy.

Case report

A 73-year-old lady has been admitted in hospital to evaluate for iron deficiency anemia, raising serum creatinine, and abdominal ascites. A diagnostic colonoscopy was requested due to her anemia, and colonoscopy revealed a few sessile polyps in sigmoid and descending colon. The patient was a candidate for polypectomy and an 1 cm sessile polyp at the junction of the sigmoid to descending colon was excised by snare following submucosal injection of 1 ml normal saline.

After polypectomy, a 6 mm perforation was induced (Fig. 1); the air pump was turned off and the secretions around site of perforation were suctioned. After injection of 2 ml normal saline at the borders, two Endoclip (Boston Scientific Co.) were inserted and the perforation was closed (Fig. 2). The luminal air was suctioned and the scope got retrieved. The patient was put on NPO, and intravenous antibiotics (Ceftriaxone plus Metronidazole) started. Abdominopelvic CT scan without contrast revealed the presence of a lot of free air in peritoneal cavity (Fig. 3).

Surgical consultation was requested and the patient was observed. During her daily visit, there was no sign of peritonitis of leukocytosis and vital signs were stable. Three days later, abdominopelvic CT scan with oral contrast revealed no contrast agent leakage (Fig. 4) so oral regimen was duly started. With serum hydration, the creatinine level declined from 2.3 to 0.8 and antibiotic regimen changed from intravenous to oral and continued for 2 weeks. The patient was discharged, and

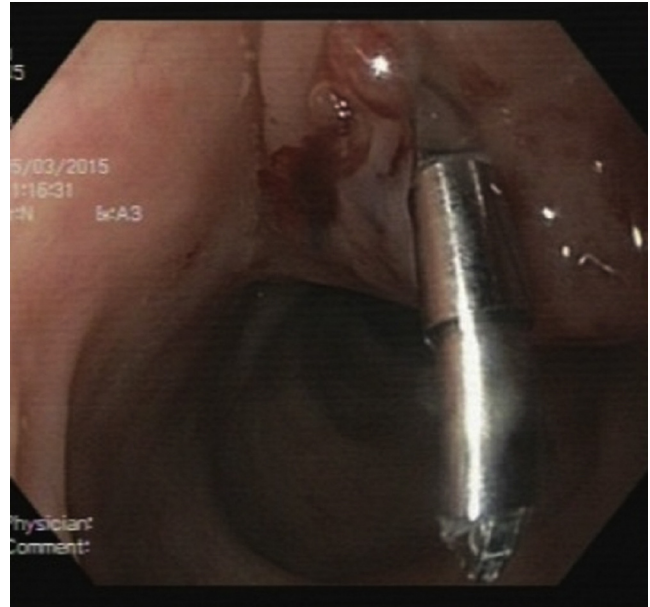


Fig. 2 – Closure of perforation with Endoclip.

in her follow-up 2 months later, the general condition was satisfactory with no loculated fluid collection in abdominal cavity. After improving of renal function and normalization of serum creatinine, the ascites gradually disappeared following the diuretic therapy.

Discussion

The possibility of perforation is higher among these conditions: polypectomy of polyps more than 2 cm or sessile polyps, submucosal dissection, polypectomy at rectosigmoid junction or junction of sigmoid to descending segment, colon diverticulosis, colonic obstruction, and history of abdominal surgery.^{3,5}

The most common clinical clues for diagnosing of perforation include visualization of site of perforation during

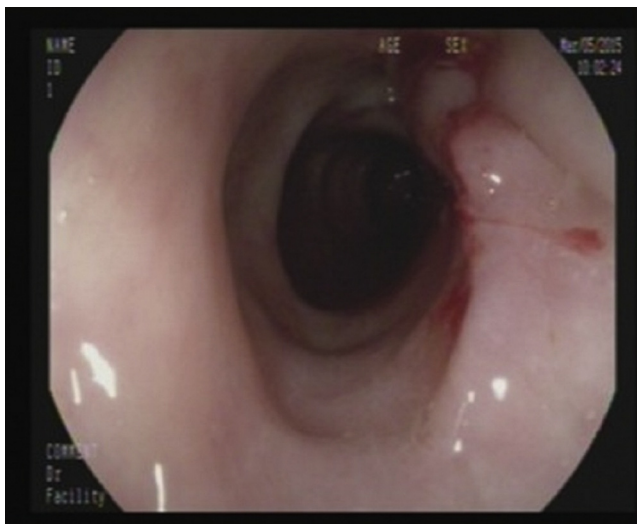


Fig. 1 – Perforated colon after polypectomy.

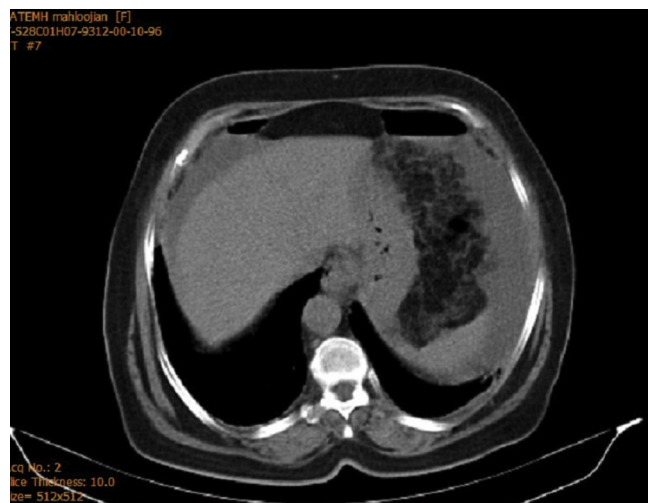


Fig. 3 – Free air in peritoneal cavity after perforation.

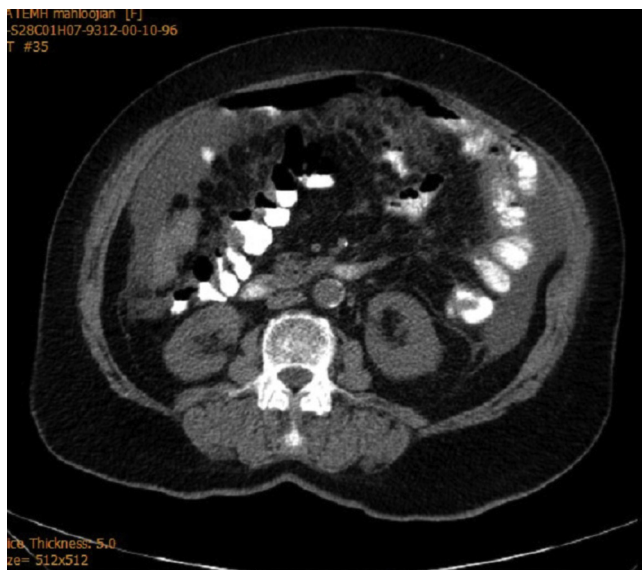


Fig. 4 – Absence of contrast agent leakage in follow-up CT scan.

colonoscopy, signs of peritonitis (abdominal pain and tenderness) in the first few hours and delayed symptoms following micro-perforations.² Presence of free air in radiography, CT scan or MRI or extravasation of contrast media could be diagnostic for perforation.

Choosing surgical or non-surgical therapy for perforation of colon is controversial but most of the patients need surgical intervention,⁶ although non-surgical or laparoscopic procedures are applicable in special situations.⁷ The conservative management which includes intravenous fluids, NPO, bowel rest and broad spectrum antibiotics, is just proper for patients with a good general condition. In the absence of any sign of peritonitis and in case of peritonitis, an urgent surgical intervention is necessary and advisable. The success rate of conservative management for colon perforation is about 33–73%.⁸ In small colonic perforations, results of therapeutic colonoscopy are better than conservative management.⁸ Endoscopic approach for closure of perforation includes using multi-channel scope and Endoclip which should be applied by an experienced endoscopist and is often successful in perforations less than 10 mm.^{7,9} During the procedure, the luminal air should be suctioned and the success rate declines dramatically if the laceration be more than 10 mm. After endoscopic repair, the patient should be observed with broad spectrum antibiotics and intravenous fluids.⁹ The success rate

of Endoclip was reported to be 69–93% and surgery has been recommended in the presence of any sign of peritonitis or failure of conservative and/or endoscopic treatment and deteriorating of clinical course.^{1,2,10}

In the presented case, by using single channel Pentax Scope (HD Series, EPK-i) and Endoclip (Boston Scientific Co.), the perforation was repaired successfully which highlights importance of adequate colonic prep and availability of accessory devices beside clinical experience.

Conflicts of interest

The authors declare no conflicts of interest.

REFERENCES

1. Lohsiriwat V, Sujarittanakarn S, Akaraviputh T, Lertakyamane N, Lohsiriwat D, Kachinthorn U. Colonoscopic perforation: a report from World Gastroenterology Organization endoscopy training center in Thailand. *World J Gastroenterol.* 2008;14:6722–5.
2. Lüning TH, Keemers-Gels ME, Barendregt WB, Tan AC, Rosman C. Colonoscopic perforations: a review of 30,366 patients. *Surg Endosc.* 2007;21:994–7.
3. Gatto NM, Frucht H, Sundararajan V, Jacobson JS, Grann VR, Neugut AI. Risk of perforation after colonoscopy and sigmoidoscopy: a population-based study. *J Natl Cancer Inst.* 2003;95:230–6.
4. Gedebou TM, Wong RA, Rappaport WD, Jaffe P, Kahsai D, Hunter GC. Clinical presentation and management of iatrogenic colon perforations. *Am J Surg.* 1996;172:454–7, discussion 457–458.
5. Wayne JD. Colonoscopic polypectomy. *Diagn Ther Endosc.* 2000;6:111–24.
6. Avgerinos DV, Llaguna OH, Lo AY, Leitman IM. Evolving management of colonoscopic perforations. *J Gastrointest Surg.* 2008;12:1783–9.
7. Barbagallo F, Castello G, Latteri S, Grasso E, Gagliardo S, La Greca G, et al. Successful endoscopic repair of an unusual colonic perforation following polypectomy using an endoclip device. *World J Gastroenterol.* 2007;13:2889–91.
8. Orsoni P, Berdah S, Verrier C, Caamano A, Sastre B, Boutboul R, et al. Colonic perforation due to colonoscopy: a retrospective study of 48 cases. *Endoscopy.* 1997;29:160–4.
9. Trecca A, Gaj F, Gagliardi G. Our experience with endoscopic repair of large colonoscopic perforations and review of the literature. *Tech Coloproctol.* 2008;12:315–21, discussion 322.
10. Tran DQ, Rosen L, Kim R, Riether RD, Stasik JJ, Khubchandani IT. Actual colonoscopy: what are the risks of perforation? *Am Surg.* 2001;67:845–7, discussion 847–848.