



Available online at

SciVerse ScienceDirect
www.sciencedirect.com

Elsevier Masson France

EM|consulte
www.em-consulte.com/en

Orthopaedics
& Traumatology
Surgery & Research

ORIGINAL ARTICLE

Traumatic diaphyseal bone defects in children

J. Sales de Gauzy^{a,*}, F. Fitoussi^b, J.-L. Jouve^c, C. Karger^d, A. Badina^e,
A.-C. Masquelet^f, the French Society of Orthopaedic Surgery and
Traumatology (SoFCOT) SofCOT, 56, rue Boissonade, 75014 Paris, France

^a Department of Pediatric Orthopaedic Surgery, Children Hospital, 330, avenue de Grande-Bretagne, 31059 Toulouse, France

^b Department of Pediatric Orthopaedic Surgery, Robert-Debré Hospital, 48, boulevard Serurier, 75019 Paris, France

^c Department of Pediatric Orthopaedic Surgery, Timone Children Hospital, 13385 Marseille, France

^d Department of Pediatric Surgery, Hautepierre Hospital, 67098 Strasbourg, France

^e Department of Pediatric Orthopaedic Surgery, Necker Enfants-malades Hospital, 149, rue de Sèvres, 75743 Paris, France

^f Department of Orthopaedic Surgery, Avicenne AP–HP Hospital, 123, route de Stalingrad, 93009 Bobigny, France

Accepted: 3 October 2011

KEYWORDS

Open fracture;
Bone defect;
Bone reconstruction;
Induced membrane;
Child

Summary Traumatic bone defects (BD) are rare in children. There are no pediatric series in the literature on this topic. The aim of this first pediatric series was to determine the epidemiological characteristics and evaluate the results of different treatments in this entity. *Material and methods:* This retrospective multicenter study evaluated diaphyseal bone defects in cases in which bone reconstruction was performed. BD was either initial and associated with trauma or secondary, resulting from infected non-union.

Results: The series included 27 patients (17 boys and 10 girls), mean age 11.4 years old (3–16) (20 traffic accidents). At the outset of all patients' history was an open fracture (one stage 1, seven stage 2, 11 stage 3A and seven stage 3B, 1 NR). BD involved 13 tibias, 9 femurs, three humerus, one radius and one ulna. Bone defects were initial in 20 cases and secondary in seven cases. They were less than 2 cm in two cases, between 2 and 5 cm in 9 cases, between 5 and 10 cm in 10 cases and more than 10 cm in six cases. Treatment of BD was immediate in one case and delayed in 26 cases. Techniques used included: induced membrane in 10 cases, bone transport in seven cases, bone autograft in eight cases, vascularized fibular transfer in one case, no bone reconstruction in one case. Union was obtained in 27 patients. Union was obtained within a mean 12.3 months BD (3–62). Fifteen patients presented with sequellae.

Discussion: Traumatic bone defects have a better prognosis in children than in adults. The thicker, more active and richly vascularized periosteum in children is an important prognostic factor. Treatment of BD requires good initial bone stabilization. Reconstruction depends on the integrity of the periosteum. In case of an intact periosteum, bone reconstruction does not seem

* Corresponding author.

E-mail address: salesdegauzy.j@chu-toulouse.fr (J. Sales de Gauzy).

necessary in young children. If one part of the periosteum is intact, a simple autograft seems sufficient even with extensive bone defects. In the absence of the periosteum or especially in case of infection, the induced membrane technique seems preferable, with bone transport or a vascularized bone transfer.

Level of evidence: IV: retrospective study.

© 2012 Elsevier Masson SAS. All rights reserved.

Introduction

In the general population, traumatic bone defects (BD) are rare with an estimated frequency of 0.4% for all fractures [1]. They are more frequent in open fractures: 11.4% in the series by Keating et al. [1].

This entity is also rare in children. In a series of 92 open tibial fractures in children, Hope et al. only found six cases of BD [2]; Buckley et al. found three cases of BD out of 42 open fractures of the tibia. [3]. There are no specific pediatric series. The only existing publications mention isolated cases, or involve rare pediatric cases included in adult series [2–8].

We identified files with children and adolescents for the symposium of the Société française de chirurgie orthopédique et traumatologique (SoFCOT)² on traumatic diaphyseal BD. The aim of this study was to determine the epidemiological characteristics of traumatic BD in children and evaluate the results of different treatments.

Materials and methods

This retrospective multicenter study included fractures of the humerus, the two bones of the forearm, the femur and the tibia. All other locations were excluded. Only files in which bone reconstruction was performed were included. Patients who underwent immediate amputation when bone defect developed were excluded. BD was either initial at the moment of the accident or secondary associated with septic pseudarthrosis. The extent of BD was classified into four types: type 1: BD of less than 2 cm; type 2: BD of between 2–5 cm; type 3: BD of between 5–10 cm; type 4: BD of more than 10 cm.

Of the 204 files that were consulted for the symposium (children and adults), we identified patients between 0 and 16 years old for this pediatric series.

Results

Epidemiology

Twenty-seven files were included, provided by 17 different institutions, between 1985 to 2009. There were 17 boys and

10 girls. The mean age of the patients when the accident occurred was 11.4 years old (3–16 years old) (Table 1).

The circumstances of the accident were: a road accident in 20 cases, a firearm accident in three cases, a farming accident in two cases and an accident during sports activities in one case. In one case, the cause of the accident was not noted. The 27 patients initially presented with an open fracture, which was classified according to Cauchoix and Duparc: one case of stage 1, seven cases of stage 2, 11 cases of stage 3A and seven cases of stage 3B. The stage was not identified in one file. In 11 cases, it was impossible to close the wound. A flap was performed in seven cases: one emergency, six during secondary surgery (between 6 and 47 days later).

In 13 cases, BD were located in the tibia, in nine cases in the femur, in three cases in the humerus, in one case in the radius and in one case in the ulna. There was a growth cartilage defect in two cases, and an associated epiphyseal bone defect in two cases.

There were initial BD in 20 cases and BD secondary to septic pseudarthrosis in seven cases. According to the extent of bone defect, there were: two type 1, 9 type 2, 10 type 3 and six type 4.

Two patients presented with initial ischemia requiring a revascularization procedure. Five patients presented with an associated neurological injury (radial nerve in two cases, sciatic nerve trunk in one case, fibular nerve in one case, tibial nerve in one case).

Twelve patients developed infection. Associated lesions were identified in eight patients including a homolateral fracture in all eight and three with a concussion. Associated risk factors included smoking in three and diabetes in one.

Treatment

Initial treatment included: immediate reconstruction in one case, placement of an acrylic spacer in four cases, shortening with joining of the fragments in three cases. In 19 cases, no interposition was performed. In three cases, internal fixation with pins or nails was performed and in 22 cases, an external fixator was used. In two patients, no osteosynthesis was used.

Treatment of BD was immediate in one case and delayed in 26 cases. Different techniques were used: the induced membrane technique in 10 cases (one case associated with an intertibiofibular graft), bone transport in seven cases (three cases underwent an associated bone graft), a bone autograft in eight cases, a vascularized fibular transfer in one case. There was no bone reconstruction in one case.

² Study presented at the symposium: traumatic diaphyseal substance loss. 85th Annual SoFCOT Meeting, Paris, France, November 2010.

Table 1 Results.

Case	Age (yrs)	Gender	Accident	Initial BD	Opening	Bone	BD Type	Infection	Treatment	Delay to union months	Sequella
1	3	F	Road	Yes	3b	Humerus	3	No	Autograft	3	Functional limitation
2	4	M	NI	Yes	2	Radius	3	NR	None	3	
3	6	M	Road	Yes	NI	Humerus	4	No	Induced membrane	5	Functional limitation
4	6	M	Farm	Yes	3b	Tibia	3	No	Bone transport	62	Limited knee ROM + malalignment + brace + ankle equinus
5	6	M	Road	Yes	2	Femur	4	No	Induced membrane	5	
6	8	M	Road	No	2	Tibia	2	Yes	Induced membrane	4	Ankle equinus
7	8	F	Road	Yes	3a	Tibia	2	No	Bone transport	6	
8	9	F	Road	No	3a	Femur	4	Yes	Autograft	19	Brace
9	9	M	Road	Yes	3b	Tibia	1	No	Autograft + ITFG	3	Malalignment + Brace
10	10	M	Firearm	Yes	3b	Humerus	2	No	Bone transport	6	
11	11	F	Road	Yes	3b	Tibia	3	No	Autograft	5	
12	11	M	Firearm	Yes	3a	Femur	4	No	Autograft	6	Cane and brace
13	12	M	Road	Yes	2	Femur	4	No	Induced membrane	3	Limited knee ROM
14	12	M	Sports	No	1	Ulna	1	Yes	Induced membrane	4	Functional limitation
15	13	F	Road	No	3a	Tibia	3	Yes	Bone transport	9	Malalignment + brace + ankle equinus
16	13	F	Farm	Yes	3a	Tibia	3	No	Bone transport + ITFG	10	
17	14	M	Road	Yes	3a	Femur	3	No	Bone transport	14	
18	14	F	Road	Yes	2	Femur	2	No	Bone transport	5	
19	14	M	Road	No	3a	Tibia	2	Yes	Induced membrane + ITFG	17	
20	15	F	Road	Yes	3a	Femur	3	No	Vascularized fibula	13	Limited knee ROM + Malalignment + equinus deformity
21	15	M	Road	No	3b	Tibia	2	Yes	Autograft ITFG	7	Limited knee ROM
22	15	F	Road	Yes	3a	Tibia	4	NR	Induced membrane	7	Cane
23	15	F	Road	Yes	2	Femur	2	Yes	Autograft	27	
24	16	M	Road	Yes	3a	Femur	3	Yes	Induced membrane	57	Limited knee ROM + Claw toes
25	16	M	Firearm	Yes	3b	Tibia	2	Yes	Autograft	20	
26	16	M	Road	No	3a	Tibia	3	Yes	Induced membrane	5	Malalignment
27	16	M	Road	Yes	2	Tibia	2	Yes	Induced membrane	8	

ITFG: intertibiobibular graft; NI: no information; BD: bone defect.

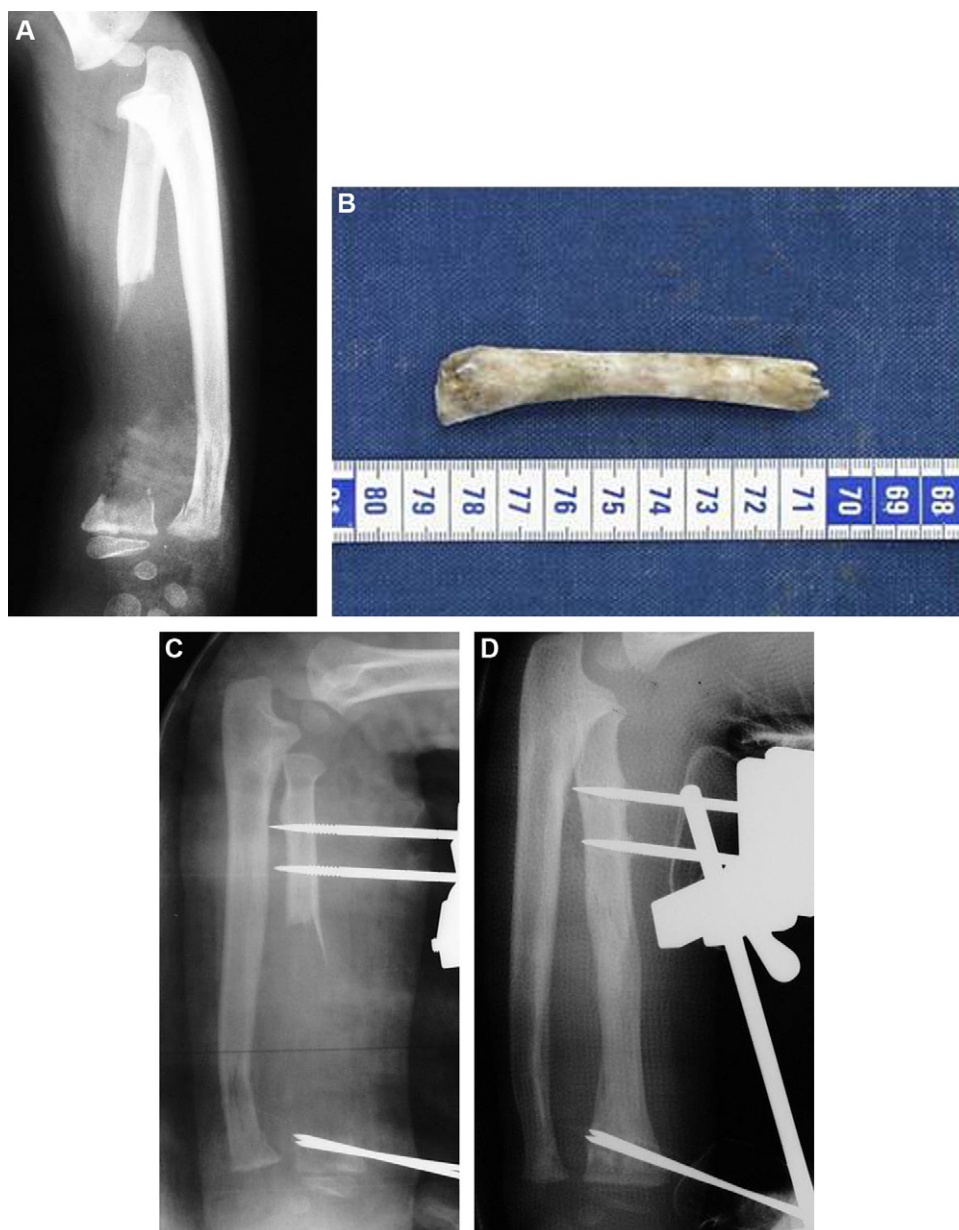


Figure 1 Case n°2. Four-year-old boy. A. Stage 2: open fracture of the radius, with 8 cm diaphyseal bone defects (BD). B. Diaphyseal BD only involves the bone, the periosteum is intact and continuous. C. Initial treatment included cleaning the wound and placement of an external fixator. No interposition of the diaphyseal BD was performed. D. At 2 months, complete reconstruction can be noted, thanks to the periosteum (Coll C Glorion).

Results of treatment

Union was obtained in 27 patients. Union occurred within a mean 12.3 months (3–62 months). Fifteen patients had sequelae: five limitations in knee range of motion (ROM), four cases of ankle equinus, one case of claw toe, five cases of malalignment. Five patients still have a protective brace; one patient walks with a cane. Six patients have not resumed sports activities.

Discussion

This is the largest published series of pediatric cases in the literature. Nevertheless, there are numerous limitations to

the study due to the retrospective and multicenter design of the review. Thus, in certain files, in particular the oldest, certain items could not be obtained. The responses for certain other items are imprecise, in particular for functional sequelae. ROM measurement of joint stiffness was not available, for example, and the presence or not of length discrepancies was not found in half the files. Nevertheless, this is the first series specifically in children and adolescents for this entity. Moreover, because of the large number of cases, we can draw certain conclusions.

This study confirms the rarity of traumatic bone defects in children. Although this was an extensive multicenter study, we only identified 27 cases over a period of 20 years (1985–2009). The frequency of this entity could not

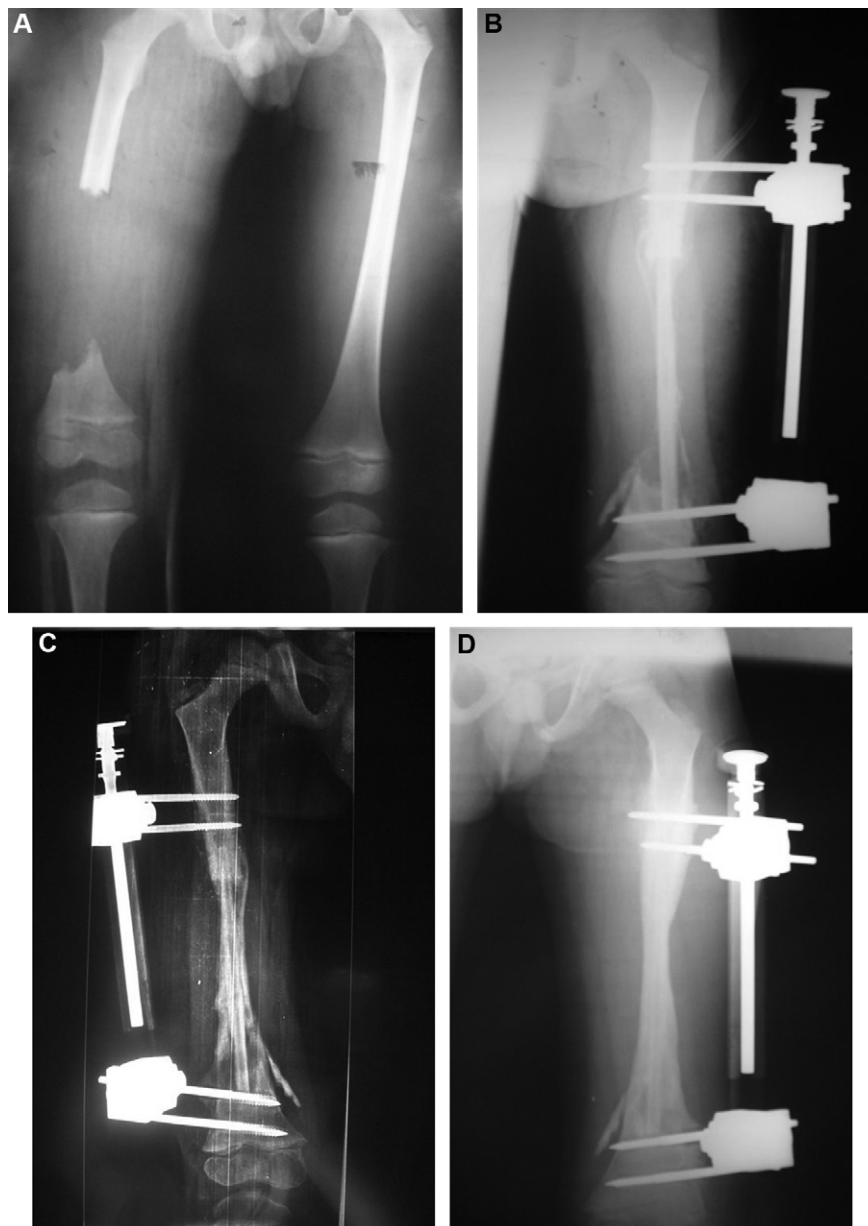


Figure 2 Case n° 5. Six-year-old boy. A. Stage 2: open fracture of the femur. Initial treatment included cleaning the wound and placement of an external fixator and a cement spacer. The periosteum was found to be continuous during surgery. B. Twenty-five days after the accident, a non-vascularized peroneal graft was performed. During surgery the beginning of periosteal ossification was noted. C. Sixty days after surgery, reconstruction is nearly complete and has developed from the periphery, thanks to the intact periosteum (Coll Dr Malek Ait Ouarab).

be determined because this is a non-exhaustive and non-continuous series. Indeed, a certain number of incomplete files were eliminated. Finally, patients who were amputated without an attempt at reconstruction were not included. Like in the literature, the tibia was the most frequent location in our series [2,3,5]. This was followed by the femur, and then the upper limbs which are much more rare. These data are comparable to adult series with, 68% in the tibia and 22% in the femur in the series by Keating et al. [1]. One of the reasons for this is the subcutaneous location of the tibia which increases the risk of open fractures and the bone breaking through the skin. Indeed, when

epidemiological data of traumatic BD are compared with those of open fractures of the tibia, the results are comparable. Thus, in our series, as in the literature [2,3] the most frequent cause of trauma was a road accident. Moreover, open fractures of the tibia are more frequent in boys, with 502 boys (74%) compared to 173 girls (26%) in the series by Baldwin et al. [4]. In our series, 63% of our patients were boys and 37% girls.

The treatment of traumatic BD varies. Numerous techniques can be used [9]: cancellous or corticocancellous autograft, the induced membrane technique associated with a cancellous autograft, free vascularized bone transfer, bone

transport by either shortening, then reconstruction or segmental bone transport. Finally, there are specific techniques for the tibia: intertibiofibular grafts and the fibula-pro-tibia technique.

Specific cases of children are rare in the literature and poorly documented. Autograft and bone transport are the most frequently used techniques in these cases. Liow and Montgomery reported six cases of BD between 1 and 6 cm; two cases of BD of 1 cm were treated by stabilization while BD of more than 1 cm were treated with bone transport [5]. The series by Hope and Cole of 92 open fractures of the tibia described six cases of diaphyseal BD: one patient was treated by vascularized bone transfer, two by bone graft, three by bone transport [2]. In the series by Buckley, three cases of BD were treated with an iliac graft [3].

The results in these three series were good. Indeed, union was obtained in the six cases reported by Liow and Montgomery [5]. Hope and Cole also obtained union in their six cases, with however, delayed union in three cases [2]. In these two series, the delay to union was not mentioned. Finally, union was obtained in the three patients in the series by Buckley et al. within 14.7 months [3].

In the adult, management depends upon the location and extent of BD. In the tibia, an autograft can be sufficient for BD of less than 6 cm. In BD less than 2 cm, the defect may resolve and union may occur spontaneously [10]. When BD are larger than 6 cm, there is an indication for another technique [7].

Three techniques were most frequent in our series: autograft (eight cases), bone transport (seven cases) and the induced membrane technique (10 cases). A change in strategy can be noted over the years. Bone transport was used between 1985 and 2000. The induced membrane technique [11] was used between 2003 and 2009. On the other hand, autograft has been used consistently. Whatever the technique or extent of BD in our series, good results were obtained, and union was obtained in all cases, while in the global series of the symposium including adults, union was only obtained in 93% of patients. Delay to union in the pediatric series was 12.3 months, which is shorter than in the global symposium series, in which union was obtained in 14.7 months.

It should be emphasized that the periosteum is a good prognostic factor in children. [12]. It is responsible for bone growth and thickness by differentiation of mesenchymal cells directly into osteoblasts. In children, the periosteum has several specificities: it is thicker, more vascularized and more active [13]. It is rich in growth factors and osteoprogenitor cells. The osteogenic potential of the periosteum can become active in a heterotopic environment as long as good vascularization is preserved [14]. In children, the periosteum is less firmly attached to cortical bone [13], so that BD can be observed in a periosteum which is totally or partially intact. Thus, thanks to the periosteum, growing bone has a significant power of reconstruction as long as the biological or mechanical environmental factors are favorable. This osteogenic activity of the periosteum explains the good results obtained with autograft even in the presence of extensive, type 3 or 4 BD. Several cases in our study illustrate the central role of the periosteum in the process of bone reconstruction. The presence of an intact or partially preserved periosteum allows ad integrum reconstruction

without additional bone transfer [6,15,16]. Case n°2 in our series is a good example of this (Fig. 1). Hinsche [17] reported cases of spontaneous union of femoral BD between 6 cm and 15 cm in young adults. These patients were only treated with intramedullary nailing with no bone grafts. This author feels that there is a genetic predisposition for bone healing. An essential element for reconstruction is stabilization of the fracture with a rigid system, either an external fixator or a nail. In the child, bone graft sometimes only plays a mechanical role as reconstruction occurs because the periosteum continues to surround the BD (Fig. 2).

The analysis of our series allows us to make certain recommendations on the management of traumatic BD in children. It is essential to obtain good initial stabilization in all cases. Reconstruction depends upon the integrity of the periosteum. If the periosteum is intact, bone reconstruction is not always necessary in young children. If part of the periosteum is intact, a simple autograft is enough, even with extensive BD. If the periosteum is absent or in case of infection, the induced membrane technique, bone transport or vascularized bone transfer should be chosen.

Disclosure of interest

The authors declare that they have no conflicts of interest concerning this article.

Acknowledgements

We would like to thank the following people for their participation in this study: Jérôme Cottalorda, Julio de Pablos, Christophe Glorion, Pierre Marry, Christian Morin, Malek Ait Ouarab, Virginie Rampal, Michel Robert, Virginie Vacquerie, T. Bauer, A. Fabre, D. Hannouche, D. Le Nen, H. Mathevon, P. Merloz, L. Obert, A. Poichotte, S. Rigal.

References

- [1] Keating JF, Simpson AHRW, Robinson CM. The management of fractures with bone loss. *J Bone Joint Surg Br* 2005;87-B:142–50.
- [2] Hope PG, Cole WG. Open fractures of the tibia in children. *J Bone Joint Surg Br* 1992;74-B:546–53.
- [3] Buckley SL, Smith G, Sponseller PD, Thompson JD, Griffin PP. Open fractures of the tibia in children. *J Bone joint Surg Am* 1990;72-A:1462–9.
- [4] Baldwin KD, Babatunde OM, Huffman GR, Hosalkar HS. Open fractures of the tibia in the pediatric population: a systematic review. *J Child Orthop* 2009;3:199–208.
- [5] Liow RYL, Montgomery RJ. Treatment of established and anticipated nonunion of the tibia in childhood. *J Pediatr Orthop* 2002;22:754–60.
- [6] Liu HC, Hsu CC. Regeneration of a segmental bone defect after acute osteomyelitis due to an animal bite. *Injury* 2004;35:1316–8.
- [7] Robinson CM, McLauchlan G, Christie J, McQueen MM, Court-Brown CM. Tibial Fractures with bone loss treated by primary reamed intramedullary nailing. *J Bone Joint Surg Br* 1995;77-B:906–13.
- [8] Sales de Gauzy J, Vidal H, Cahuzac JP. Primary shortening followed by callus distraction for the treatment of a post-traumatic bone defect. *J Trauma* 1993;34:461–3.

- [9] Masquelet AC. Traitement des pertes de substance osseuse diaphysaires post-traumatiques. In: Conférences d'enseignement de la SOFCOT. Paris: Elsevier; 2007 [p. 21–33].
- [10] Court-Brown CM, Keating JF, McQueen MM, Christie J. Exchange tibial nailing: its use in aseptic tibial non union. *J Bone Joint Surg Br* 1995;77-B:407–11.
- [11] Masquelet AC, Begue T. The concept of induced membrane for reconstruction of long bone defects. *Orthop Clin N Am* 2010;41:27–37.
- [12] Malizos KN, Papatheodorou LK. The healing potential of the periosteum. Molecular aspects. *Injury* 2005;36S:S13–9.
- [13] McKibbin B. The biology of fracture healing in long bones. *J Bone Joint Surg Br* 1978;60-B:150–62.
- [14] Dailiana ZH, Shiamishis G, Niokou D, et al. Heterotopic neosteogenesis from vascularized periosteum and bone grafts. *J Trauma* 2002;53:934–8.
- [15] Hakim GR. Regeneration and overgrowth after massive diaphyseal bone loss. *J Trauma* 2000;49:559–62.
- [16] Klein DM, Caligiuri DA, Riina J, Katzman BM. Spontaneous healing of a massive tibial cortical defect. *J Orthop Trauma* 1997;11:133–35.
- [17] Hinsche AF, Giannoudis PV, Matthews SE, Smith RM. Spontaneous healing of large femoral cortical bone defects: does genetic predisposition play a role? *Acta Orthop Belg* 2003;69:441–6.