

TCT-806

Transjugular Access As An Alternative To Standard Transfemoral Approach For Balloon Mitral Valvotomy In Patients With Structural AlterationsMithun J. Varghese¹, George Joseph²¹Christian Medical College, Vellore, Vellore, Tamil Nadu, ²Christian Medical College, Vellore, Tamil Nadu

Background: Percutaneous balloon mitral valvotomy (BMV) is the treatment of choice for mitral stenosis and can be successfully done in majority of patients with suitable morphology. However certain structural anomalies can make BMV using femoral approach technically difficult, or even impossible. A jugular approach can overcome many of these constraints.

Methods: We evaluated patients at our center who underwent transjugular BMV. In all the patients valve morphology was deemed suitable for BMV and the procedure was done using an over the wire single cylindrical balloon technique. Transthoracic echocardiogram before and after the procedure was done in all, to assess the valve area, morphology and mitral regurgitation (MR). The procedure was undertaken in 27 patients during the study period (11 males, 34±12 years).

Results: The transjugular BMV was completed in 26 out of 27 patients for the following indications- failed femoral procedure (10 patients), large left atrium (LA) (10 patients), inferior venacava anomalies (3 patients), dextrocardia (2 patients), scoliosis and rheumatic double outlet mitral valve (1 patient each). In comparison with previous femoral BMV series, our patients had several poor prognostic factors including higher incidence of atrial fibrillation (13 patients, 50%), prior cardiac surgery (5 patients, 19.2%), mean Wilkins score (8.4±1.2) and larger mean LA size (58±14mm). Procedural success was obtained in 24 patients and the mean valve area increased from 0.77±0.21 to 1.89±0.34 (p< 0.0001). Two patients developed severe MR and one required early mitral valve replacement.

Conclusions: Transjugular BMV offers a safe and effective alternative to standard transfemoral approach patients with anatomical alterations due to straight line access to mitral valve. This technique thus avoids a certain surgery in these patients and expands the role of catheter interventions in this common malady.

	Before BMV	After BMV	p value
Mean Pulmonary artery pressure (mm Hg)	42±18	31±15	<0.0001
Mean Left atrial pressure (mm Hg)	26±7	14±7	<0.0001
Mean Mitral valve gradient (mm Hg)	17.5±6.2	3.7±3.1	<0.0001
Mean mitral valve area by 2-D planimetry (mm Hg)	0.77±0.21	1.89±0.34	<0.0001

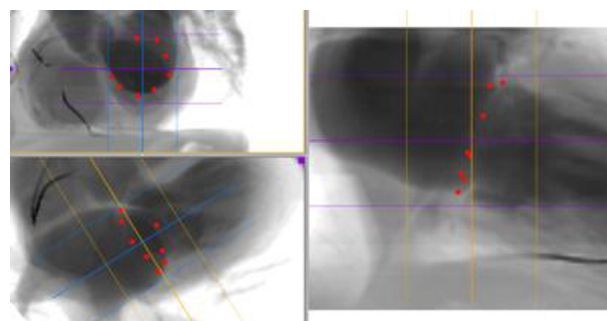
TCT-807

Multi-Slice Computed Tomography Procedural Planning For Transcatheter Mitral AnnuloplastyJovana Pavicevic¹, Andrea Guidotti¹, Tal Sheps¹, Maximilian Emmert¹, Etem Caliskan¹, Oliver Gaemperli¹, Fabian Nietlisbach¹¹University Hospital of Zurich, Zurich, Switzerland

Background: Transcatheter mitral annuloplasty (TMA) is an alternative therapy for non-surgical patients with functional mitral regurgitation (FMR). Multi-slice CT-scan (MSCT) has been used for device size selection and procedural planning. The aim of the study is to report the average measurements of a population undergoing TMA with the Cardioband device (Valtech Cardio, Israel).

Methods: MSCT of 16 consecutive patients undergoing TMA were prospectively analyzed. Multiplanar reconstruction was used to mark the anatomical targets and to determine the following variables: total annular size, posterior annular length (PAL), valve area, fluoroscopic working angle, distance of the circumflex artery and coronary sinus, and height of the fossa ovalis. According to measurements, the position of transeptal puncture and aim to the annulus were planned. Device size was chosen according to PAL (oversizing by 20%).

Results: Total annular size and mitral valve area were 126±14mm and 12±3cm², respectively. The posterior annular length (PAL) was 84±13.3mm. The predicted working angle was RAO 31±5°. The circumflex artery was patent in 13 patients (grafted in 4). The portion of the posterior annulus with the circumflex artery closer than 8mm and of the coronary sinus closer than 10mm were 9.1±5.2% and 31.8±11%, respectively. The lowest rim of the fossa to the annulus distance was 2.8±0.6mm at the commissure.



Conclusions: TMA was successful and device sizing was appropriate in all patients. No patient suffered coronary artery or coronary sinus injury.

TCT-808

15-year Outcomes and Predictors of Success for Percutaneous Mitral Commissurotomy for Rheumatic Mitral StenosisAl Fazir Omar¹, Amin Ariff², Robayah Zambahari², Mohd Ali Rosli³¹National Heart Institute, Kuala Lumpur, Malaysia, ²FRCP, Kuala Lumpur, Malaysia, ³AM(Mal), FNHAM, FAsCC, FAPSIC, Kuala Lumpur, Malaysia

Background: Rheumatic heart disease remains the most common acquired heart disease in children, especially in developing countries. This study aims to investigate the predictors of immediate procedural success and the immediate and long-term outcomes in patients undergoing percutaneous mitral commissurotomy (PTMC).

Methods: A total of 1552 patients with rheumatic mitral stenosis and underwent PTMC from 1989 to 2012 were identified. We divided the group according to Wilkins score as low risk (≤5), intermediate risk (6-8) and high-risk (≥9). Procedural success was defined as mitral valve area greater than 1.0cm² with a mean gradient of less than 10mmHg.

Results: The median age was 36 years old [IQR 28-45]. The majority of patients was female (78.5%) and did not have any other valve involvements (85.0%). Most of cases were elective (99.5%) although 103 patients were pregnant (6.6%) during PTMC. The mitral valve area increased from 0.8cm² [IQR 0.7-1.0] pre-procedure to 1.5cm² [IQR 1.3-1.7] post-procedure, with a reduction in the mean pressure gradient of 15mmHg [IQR 12-20] to 4mmHg [IQR 2-6] post-procedure (all p< 0.05). Using logistic regression analysis, no difference was seen in immediate procedural success between increasing age, previous PTMC, emergency cases, New York Heart Association status, balloon size or increasing risk groups (all p>0.05). During the 15-year follow-up, the majority of patients were still alive.

Conclusions: PTMC appears to be safe and effective in our population, irrespective of older age, higher NYHA class, higher Wilkins score and previous PTMC with good immediate and long-term outcomes.

