

## ORIGINAL ARTICLE

# Mediastinal Hydatid Cyst

Akram Traibi, Fouad Atoini, Abdelfettah Zidane, Adil Arsalane, El Hassane Kabiri

*Department of Thoracic Surgery, Mohammed V Military University Hospital, Rabat, Morocco.*

**Background:** The objective of this study was to report our experience in the management of hydatid cysts of the mediastinum.

**Methods:** Among 206 patients who underwent surgery in our department for intrathoracic hydatid cysts between September 2001 and September 2008, 7 patients (3.4%) aged 24 to 49 years (mean, 36.2 years) had mediastinal hydatid cysts. Imaging consisted of chest X-ray and computed tomography. Surgical approach was by posterolateral thoracotomy in all cases.

**Results:** The cyst was located in the posterior mediastinum in 3 cases (42.8%), in the anterior mediastinum in 2 cases (28.5%) and in the middle mediastinum in 2 cases (28.5%). Two patients had cysts in other thoracic locations (diaphragm, pleural). All cysts were intact. Surgical approach was right thoracotomy in 5 patients (71.4%) and left thoracotomy in 2 patients (28.5%). In 5 cases, a small part of the cyst wall intimately adherent to vital structures was left in place. There were no postoperative complications or mortality.

**Conclusion:** Mediastinal hydatid cyst is an uncommon disease. Because of the surrounding vital structures, the cyst should be removed immediately. Surgical removal remains the treatment of choice for mediastinal echinococcosis, without extensive resection when progression of dissection is impossible or dangerous. [*J Chin Med Assoc* 2010;73(1):3–7]

**Key Words:** echinococcosis, mediastinum, thoracic surgery

## Introduction

Human hydatid disease is caused by the larval form of *Echinococcus granulosus*. This disease is endemic in Morocco and poses a serious problem. The primary hosts for the infecting organism are essentially dogs, wolves and coyotes. The intermediate hosts are sheep, cattle, and deer. Humans enter the cycle through contact with infected canine feces. Liver and lungs are the most common sites of infection, but the cyst is seen elsewhere in the body.

Intrathoracic extrapulmonary localization is generally in the pleura, pericardium, diaphragm and chest wall; mediastinal cyst is exceptional.<sup>1,2</sup> We report on 7 cases of mediastinal hydatid cysts we have treated in a 7-year period. In this report, the clinical and diagnostic problems, and treatment are discussed.

## Methods

In a retrospective study from September 2001 to September 2008, it was found that 206 patients with

intrathoracic hydatid cysts were operated on in our department. Seven of them (3.4%) had mediastinal localization. The records of these cases were analyzed for age, sex, signs and symptoms at presentation, location of cyst, type of surgical procedure, and hospital stay (Table 1). Diagnostic tests included serological tests, chest X-ray, computed tomography (CT) and abdominal ultrasound. Hydatid cyst was surgically confirmed in all cases.

## Results

There were 6 men and 1 woman, with a mean age of 36.2 years, 3 of whom had a past history of surgery for hydatid cyst (liver and/or lung). One patient had a pulmonary hydatid cyst 2 years previously; the cyst was simple and we had performed cystectomy and capitonnage. One patient with simple hepatic and ruptured lung hydatid cyst (5 years previously) was treated by middle lobectomy and complete pericystectomy of the liver localization. In both cases, there were no complications or recurrence without adjuvant medical treatment.



\*Correspondence to: Dr El Hassane Kabiri, Immeuble 29 Appt 7, Résidence Mesk Ellil, Secteur 23, Riad 10100, Rabat, Morocco.

E-mail: hassankabiri@yahoo.com • Received: May 12, 2009 • Accepted: December 7, 2009

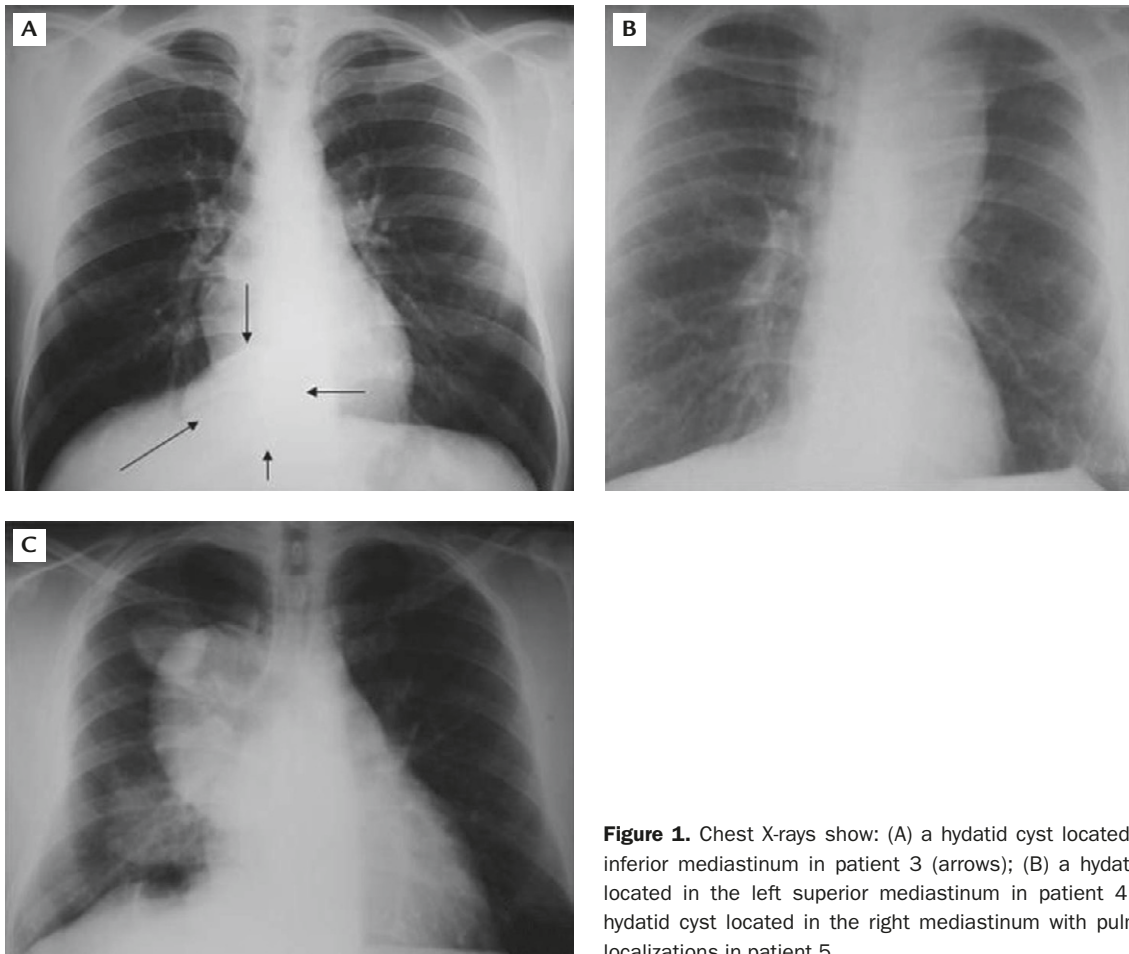
The third patient, with a hepatic hydatid cyst treated 4 years prior by dome resection technique and probable transdiaphragmatic dissemination, had received medical treatment for 6 months.

Five patients were symptomatic with chronic cough and dyspnea (2 cases), chest pain (3 cases) and in 1 case, the patient was dysphonic with recurrent nerve paralysis. Posteroanterior chest X-ray (Figure 1) and CT (Figure 2) revealed a mediastinal mass in all patients (Table 1). Three were in the posterior mediastinum (42.8%), 2 in the anterior mediastinum (28.5%) and 2 in the middle (28.5%). The mean sizes of the hydatid cysts were 76 × 46 mm and 50 × 35 mm in the symptomatic and asymptomatic forms, respectively.

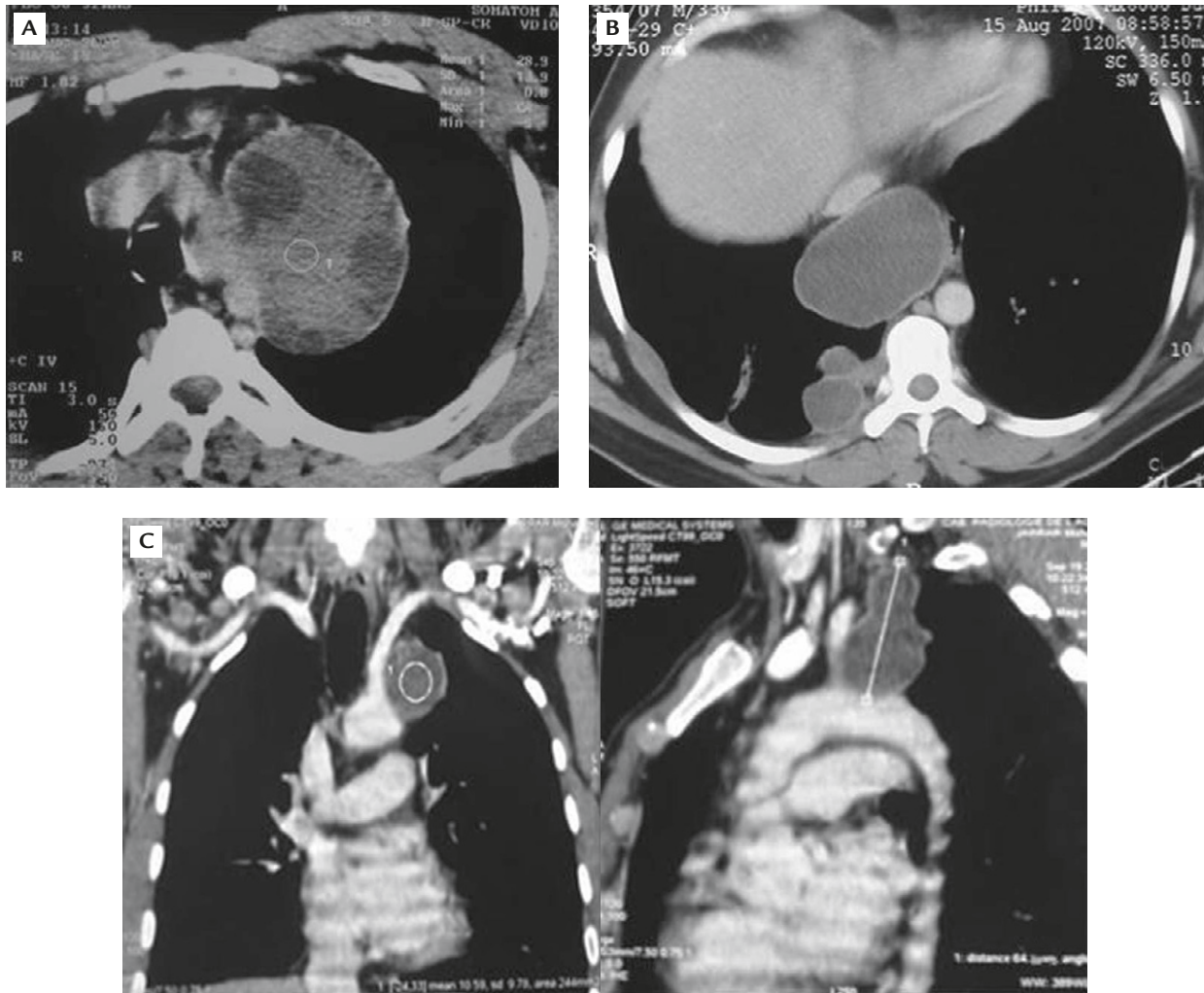
Abdominal echography was performed on all patients to check other locations for hydatidosis (liver, spleen, kidney). All locations were clear in all cases. Indirect hemagglutination or immunoelectrophoresis was done in all cases and was negative in 5 patients. Surgery was the primary treatment modality in all

patients. Technically, all patients were approached through a posterolateral thoracotomy (right in 5 cases, left in 2 cases).

Partial pericystectomy was performed in 5 patients as a small part of the cystic wall was left in place because it was intimately stuck to the vital structures of the mediastinum (superior, inferior vena cava, esophagus, recurrent nerve, pulmonary and/or subclavian artery) (Figure 3). We used sponges soaked with scolicidal agent ( $H_2O_2$ ) to prevent parasite dissemination. In all cases, the diagnosis was confirmed perioperatively, macroscopically (germinative membrane), and histologically. The mean hospital stay was 5 days, with no complications in any patient. Medical treatment was administered postoperatively to 3 patients with a history of pulmonary and/or hepatic surgery for hydatidosis. Postoperative mebendazole (10–14 mg/kg/day) was administered for 6 months with monthly hepatic function tests and chest X-rays to these 3 patients.



**Figure 1.** Chest X-rays show: (A) a hydatid cyst located in the inferior mediastinum in patient 3 (arrows); (B) a hydatid cyst located in the left superior mediastinum in patient 4; (C) a hydatid cyst located in the right mediastinum with pulmonary localizations in patient 5.



**Figure 2.** Computed tomography images show: (A) a left mediastinal multivesicular hydatid cyst in patient 4; (B) a cystic mass of the inferior mediastinum with pleural cystic masses in patient 5; (C) a subaortic cystic mass extending along the subclavian artery in patient 1.

In this series, follow-up ranged from 3 to 62 months (mean, 30.6 months). There was no recurrence of disease.

## Discussion

Hydatid cyst is a parasitic disease frequently seen in sheep and cattle raised in countries with poor sanitary conditions. The disease is a serious and endemic problem in Morocco. The parasite (*Echinococcus granulosus*) lives in the intestinal tract of carnivores, and its eggs reside in its last ring and are eliminated with the feces. The eggs, which contaminate grazing fields and irrigated land, are consumed by herbivores. Humans are infected from contaminated water, food, and direct contact with carnivores. The larvae

undergo encystation in the small intestine, penetrate the intestinal wall, and are carried by mesenteric vasculature to various locations within the body. The liver and lung are the most common locations, but the literature only describes 100 cases in the mediastinum.<sup>3</sup>

Hydatid cysts are rarely present in the mediastinum; the parasite localizes in the region after passing the hepatic and pulmonary filters, probably via an arterial branch of the thoracic aorta or via lymphatics.<sup>1,4</sup> Most patients with mediastinal hydatid cyst are symptomatic. The presenting symptoms are determined by the size and location of the cyst and the degree of compression or erosion of the mediastinal structures. In our patients, chest pain, cough, dyspnea and recurrent nerve paralysis<sup>5,6</sup> were the symptoms found. Vertebral destruction, superior vena cava syndrome, and possibly

**Table 1.** Patient characteristics

	Age (yr)/Sex	Symptoms	Radiology		Surgery	Hospital stay (d)	Follow-up (mo)
			Chest X-ray	CT			
1	44/M	– Recurrent nerve paralysis – Chest pain – Cough	Superior left mediastinal opacity	– Left mediastinal cystic mass (middle upper mediastinum) – Size: 70 × 44 × 37 mm	Incomplete resection (adherent to left subclavian artery & recurrent nerve)	4	16
2	27/F	– Chest pain – Surgery for right pulmonary hydatid cyst	Opacity on the right side	– Fluid cystic mass with calcifications in posterior mediastinum – Size: 40 × 34 mm	Complete resection	3	43
3	24/M	– Chest pain – Chronic cough – Dyspnea	Inferior mediastinal opacity	– Cystic posteroinferior mediastinal mass located between the IVC, the esophagus & thoracic aorta – Size: 75 × 52 mm	Incomplete resection (adherent to IVC & esophagus)	5	36
4	34/M	– Chronic cough – Surgery for right pulmonary & hepatic cyst	Superior mediastinal opacity	– Fluid cystic mass in middle left mediastinum – Size: 80 × 78 mm	Incomplete resection (adherent to subclavian artery)	6	3
5	33/M	– Asymptomatic – Surgery for hepatic hydatid cyst	Mass in the right hemithorax	– Two fluid cystic masses in anterior mediastinum – Pleural localization – Size: 80 × 50 mm, 30 × 25 mm	Incomplete resection (adherent to superior vena cava)	5	16
6	37/M	– Asymptomatic	Opacity on the right side	– Cystic fluid mass with calcifications in posterior mediastinum – Size: 40 × 30 mm	Complete resection	3	62
7	49/M	– Chest pain – Dyspnea – Fever	Multiple opacities in the right hemithorax	– Three fluid cystic masses in anterior mediastinum – Pleural & diaphragmatic cysts – Size: 84 × 56 mm, 45 × 30 mm, 40 × 30 mm	Incomplete resection (adherent to the great vessels)	7	38

CT = computed tomography; IVC = inferior vena cava.

Bernard-Horner's Syndrome<sup>7,8</sup> have been reported in the literature. Some patients are asymptomatic, the lesion being discovered fortuitously on chest X-ray.<sup>9</sup>

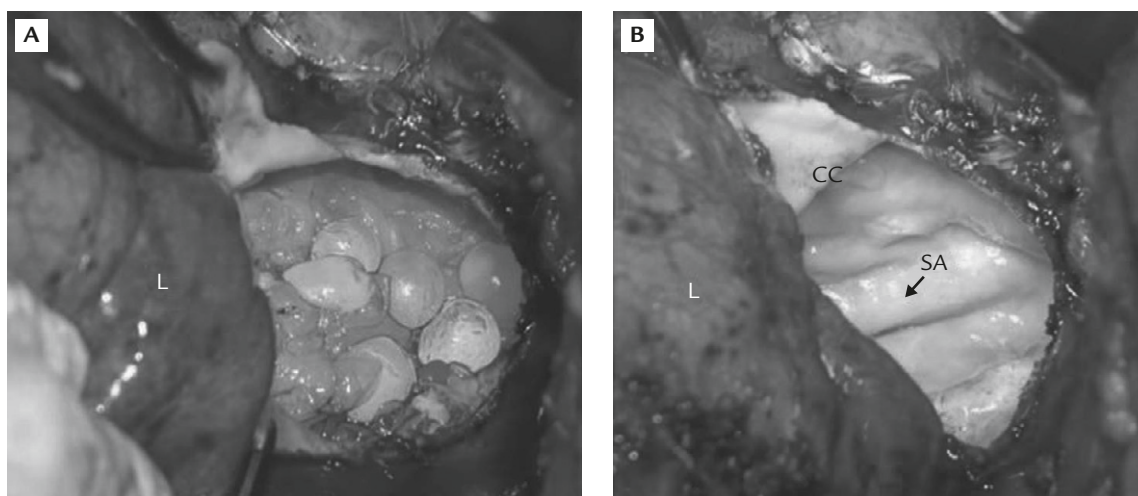
Chest X-ray and CT are the most commonly used modalities for diagnosis of mediastinal hydatid cyst. CT is considered essential and is important for displaying the morphology, density and limits of these lesions. Presence of calcifications should raise strong suspicions of a hydatid cyst. Thoracic magnetic resonance imaging permits study of the relationship to adjacent structures, specifically spinal involvement in cases where the cyst is in the posterior mediastinum or when there is a neurological sign.<sup>2,9,10</sup> Systematic abdominal ultrasound should be performed, considering that the liver

is the primary organ for hydatid disease and to search for other abdominal localizations.

It has been reported that for mediastinal hydatid cysts, more than 45% of cysts were located in the posterior mediastinum, with 36% in the anterior mediastinum, and 18% in the middle mediastinum.<sup>11</sup> In our series, the posterior mediastinum was also the most frequent location.

Serological tests are often negative when the cyst is intact and uncomplicated.<sup>1</sup> In our study, the serological test employed was observed to be positive in 2 cases.

The differential diagnoses of mediastinal cyst are still numerous even after CT scan, and in such cases can



**Figure 3.** Operative view in patient 4: (A) before and (B) after extraction of multivesicular daughter of the hydatid cyst. The cystic cavity is intimately adhered to the subclavian artery. L = lung; CC = cystic cavity; SA = subclavian artery.

only be made by surgery and include thymoma, tuberculoma necrotic carcinoma or abscesses in the anterior mediastinum, pleuro-pericardic cyst, cardiac tumors or masses in the middle mediastinum, and bronchogenic cyst, enteric cyst, lymphangioma or neurogenic tumors in the posterior mediastinum.<sup>1,12</sup> Complications of mediastinal hydatid cyst can be serious (rupture, fistula, infection, and compression of vital structures). For these reasons, surgical intervention is indicated. The aim of surgical treatment for hydatid cyst of the mediastinum is radical removal of the germinative membrane and pericyst. All of our patients were approached by posterolateral thoracotomy, with partial pericystectomy being the technique used to excise the cysts in 5 cases. We performed this approach because the lesions were adherent to some structures in the mediastinum and progression of dissection was impossible or dangerous.<sup>1,3,11</sup> Medical treatment was applied postoperatively in patients with operative perforated cysts and those with signs of dissemination.<sup>1,6</sup>

In conclusion, hydatid cyst of the mediastinum is uncommon, but should be considered in the differential diagnosis of mediastinal cyst lesions, especially in endemic regions. CT is the main tool for diagnosis and the study of possible extension. Surgery is the best treatment and must be carried out early to prevent complications. Additional adjuvant medical therapy is essential to avoid recurrence. Prevention is still the best way to eradicate this parasite.

## References

1. Kabiri EH, Al Aziz S, El Maslout A, Benosman A. Hydatid cyst: an unusual disease of the mediastinum. *Acta Chir Belg* 2001;101:283–6.
2. Ulkü R, Eren N, Cakir O, Balci A, Onat S. Extrapulmonary intrathoracic hydatid cysts. *Can J Surg* 2004;47:95–8.
3. Heras F, Ramos G, Duque JL, García Yuste M, Cerezal LJ, Matilla JM. Mediastinal hydatid cysts: 8 cases. *Arch Bronconeumol* 2000;36:221–4.
4. Zidane A, Arsalane A, Atoini F, Kabiri EH. Extra-pulmonary thoracic hydatid cysts. *Rev Pneumol Clin* 2006;62:386–9.
5. Kabiri EH, Atoini F, Kabiri MH. Primary mediastinal hydatid cyst causing a paralysis of the recurrent nerve. *Indian J Thorac Cardiovasc Surg* 2008;24:264–5.
6. Rashid M, Zafar Abbas S, Ahmad I, bin Asaf B, Faizan MA. Multivesicular mediastinal hydatid cyst presenting with left recurrent and phrenic nerve palsy. *JBR-BTR* 2008;91:155–7.
7. Purohit M, Srivastava CP, Yadav KS. Primary mediastinal hydatid cyst. *Indian J Chest Dis Allied Sci* 1999;41:57–60.
8. Sirmali M, Gezer S, Aydin E, Kaya S. Giant primary mediastinal hydatid cyst causing Horner's syndrome: report of a case. *Acta Chir Belg* 2005;105:221–3.
9. Ozpolat B, Ozeren M, Soyol T, Yucel E. Unusually located intrathoracic extrapulmonary mediastinal hydatid cyst manifesting as Pancoast syndrome. *J Thorac Cardiovasc Surg* 2005;129:688–9.
10. Zidi A, Zannad-Hantous S, Mestiri I, Ghrairi H, Baccouche I, Djilani H, Ben Miled Mrad K. Hydatid cyst of the mediastinum: 14 case reports. *J Radiol* 2006;87:1869–74.
11. Eroğlu A, Kürkçüoğlu C, Karaoğlanoğlu N, Tekinbaş C, Kaynar H, Onbaş O. Primary hydatid cysts of the mediastinum. *Eur J Cardiothorac Surg* 2002;22: 599–601.
12. Kabiri el H, Zidane A, Atoini F, Arsalane A, Bellamari H. Primary hydatid cyst of the posterior mediastinum. *Asian Cardiovasc Thorac Ann* 2007;15:c60–2.