

Covered Cheatham-Platinum Stents for Aortic Coarctation

Early and Intermediate-Term Results

Aphrodite Tzifa, MRCPCH,* Peter Ewert, MD,† Grazyna Brzezinska-Rajszyz, MD,‡ Bjoern Peters, MD,† Maria Zubrzycka, MD,‡ Eric Rosenthal, MRCP,* Felix Berger, MD,† Shakeel A. Qureshi, FRCP*

London, United Kingdom; Berlin, Germany; and Warsaw, Poland

OBJECTIVES	This study sought to evaluate the use of covered Cheatham-platinum (CP) stents in the treatment of aortic coarctation (CoA).
BACKGROUND	Aortic aneurysms and stent fractures have been encountered after surgical and transcatheter treatment for CoA. Covered stents have previously been used in the treatment of abdominal and thoracic aneurysms in adults. We implanted covered CP stents as a rescue treatment in patients with CoA aneurysms or previous stent-related complications and in patients at risk of developing complications because of complex CoA anatomy or advanced age.
METHODS	Thirty-three covered CP stents were implanted in 30 patients; 16 patients had had previous procedures. The remaining patients had complex or near-atretic CoA.
RESULTS	The mean patient age and weight were 28 (± 17.5) years (range 8 to 65 years), and 62 (± 13) kg (range 28 to 86 kg), respectively. The systolic gradient across the CoA decreased from a mean (\pm SD) of 36 \pm 20 mm Hg before to a mean of 4 \pm 4 mm Hg after the procedure ($p < 0.0001$), and the diameter of the CoA increased from 6.4 \pm 3.8 mm to 17.1 \pm 3.1 mm ($p < 0.0001$). The follow-up period was up to 40 months (mean, 11 months). All stents were patent and in good position on computed tomography or magnetic resonance imaging performed three to six months later. In 43% of the patients antihypertensive medication was either decreased or stopped.
CONCLUSIONS	Covered CP stents may be used as the therapy of choice in patients with complications after CoA repairs, whereas they provide a safe alternative to conventional stenting in patients with severe and complex CoA lesions or advanced age. (J Am Coll Cardiol 2006;47:1457-63) © 2006 by the American College of Cardiology Foundation

Thirty-three covered Cheatham-platinum (CP) stents were implanted in 30 patients in three institutions between September 2001 and February 2005. These represent 29% of 103 patients who underwent stenting of aortic coarctation (CoA) in these institutions during the same period. The mean age of the patients was 28 (± 17.5) years (range 8 to 67 years), and the mean weight was 62 (± 13) kg (range 28 to 86 kg). Detailed patient characteristics are given in Table 1. Only four patients were children below 14 years of age (8-, 12-, 13-, and 13-year-olds, weighing 28, 50, 54, and 83 kg, respectively).

Covered stents were chosen: 1) as a rescue treatment in patients with CoA aneurysms (Fig. 1) or previous stent-related complications (Fig. 2) and 2) in patients at risk of complications because of complex CoA anatomy (Fig. 3) or advanced age. Complex CoA anatomy was defined as near-aortic arch interruption or severe arch tortuosity. The latter CoA anatomy was considered high risk for the development of aneurysms because of the shear forces applied by the stent onto the intima of the tortuous arch and the high likelihood of cystic medial necrosis in adult patients with CoA. Advanced age was defined as age > 65 years.

Sixteen of 30 patients had had previous procedures, consisting of balloon dilation in 8, stent implantation in 5, and surgery in 3. Of these, aneurysms or stent-related complications had developed in 12 (such as fractures of stents, aneurysms, in-stent thrombus) (Fig. 4). Seven patients had severe, near-atretic native CoA; 7 patients had unfavorable arch anatomy for conventional stenting (i.e., arch tortuosity), 1 of whom had had balloon dilation previously; 2 patients had a coexisting patent ductus arteriosus; and in 2 patients a covered stent was inserted because of the severity of the CoA and the advanced age of the patient (65- and 67-year-olds) (Table 2).

Of the patients in whom covered stents were implanted to deal with previous aneurysms, five had undergone transcatheter interventions and three had undergone surgery. The mean time for the detection of aneurysm after transcatheter intervention was 4.8 months (range 0 to 12 months) and the mean time from detection to covered stent implantation was 16.8 months (range 0 to 48 months). In the surgical group, covered stents were implanted to deal with postoperative aneurysms 17, 30, and 35 years after repair.

A successful outcome was defined as a peak systolic pressure gradient after stent implantation of < 20 mm Hg. Aspirin was used in all patients for 6 weeks to 6 months after implantation of a covered CP stent, except for those patients already on warfarin, in whom aspirin was admin-

From the *Department of Congenital Heart Disease, Guy's and St. Thomas's Hospital, London, United Kingdom; †Department of Congenital Heart Disease, German Heart Institute, Berlin, Germany; and the ‡Department of Pediatric Cardiology, Children's Memorial Hospital, Warsaw, Poland.

Manuscript received June 12, 2005; revised manuscript received November 10, 2005, accepted November 15, 2005.

Abbreviations and Acronyms

CoA = aortic coarctation
CP = Cheatham-platinum

istered the day before the procedure and warfarin was recommenced immediately after the procedure.

Set-up. All procedures were performed under radiographic guidance in the cardiac catheterization laboratory, except for one, which was performed in the magnetic resonance imaging cardiac catheterization suite, aided by fluoroscopy.

Statistical analysis. Differences in the peak systolic pressure gradient and CoA diameter were assessed by paired *t* test analysis. Statistical significance was defined as *p* < 0.05.

Materials. The covered CP stents are currently only available outside of the U.S. Covered CP stents are made of a framework of platinum iridium wire welded in a zig pattern. The design consists of formed segments of wire that are laser-welded together. To facilitate this welded area, the “elbow” sections of the stents are pressed and welded together using laser energy. The welding process takes material from each of the segments being welded together to make the connection area, but makes each wire slightly weaker at the welded area because of the removal of material. The addition of a gold soldering to each weld spot fills any voids caused by the welding and transfers the stresses to a larger area of the stent (Figs. 5A and 5B). The gold also serves to encapsulate the welded area, once again adding to the total strength of the weld. The stent is then fitted with a covering of expanded polytetrafluoroethylene to achieve a solid tubular structure that retains fluid (Figs. 5C and 5D). The polytetrafluoroethylene covering is initially approximately 7 mm in diameter and will stretch over the range of diameters of expansion (usually from 12 to 24 mm diameter), and will always be taut over the stent when expanded. When the covering is mounted, it is folded over the crimped stent and expands uniformly when the balloon is inflated.

Technique of stent implantation. Informed consent was obtained from all patients or the parents of the children. The procedure was performed under general anesthesia in 17 patients, sedation with midazolam and propofol in 12 patients, and only local anesthetic in 1 patient who refused sedation. Femoral arterial access was gained percutaneously in all but 3 patients, in whom surgical arteriotomy was

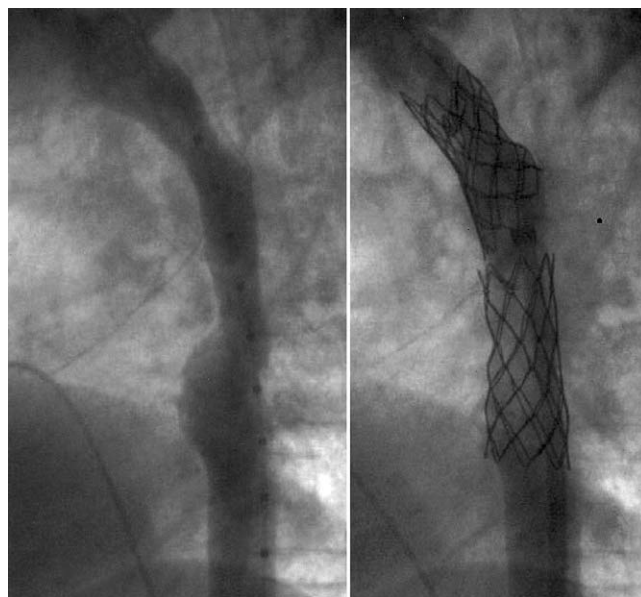


Figure 1. Covered stent implantation for long-segment aortic coarctation with aneurysm.

performed. When the CoA lesion was near-atretic, additional brachial arterial access was obtained for aortic arch angiograms and for crossing the CoA with a wire. In one patient, access was obtained via the femoral vein and the procedure was performed in an antegrade fashion through a ventricular septal defect.

After measurement of the initial gradients and angiography, the diameters of the transverse arch, CoA, and descending aorta above the diaphragm were measured using catheter magnification or the calibration markers on the catheters.

Cheatham-platinum stents covered with expanded polytetrafluoroethylene were used in all patients (NuMED Inc., Hopkinton, New York). The length of the chosen stent was based on the distance between the left subclavian artery (or the left common carotid artery if the subclavian artery had been used at previous surgery) to about 15 mm beyond the site of the CoA. The maximum balloon diameter was chosen based on either the transverse or the distal arch diameter, whichever was greater, and on occasions 1 to 2 mm greater.

A long sheath (usually Mullins, Cook, Bloomington, Indiana) placed over a 0.035-inch stiff exchange length guidewire was used in all patients for stent delivery. The wire was positioned in the ascending aorta in the majority of cases. The sheath size ranged between 10- and 16-F, and was chosen to be 2- to 3-F larger than that required for the introduction of the balloon catheters.

The stent was crimped onto a BIB balloon (NuMED Inc.), which is currently available only outside of the U.S. This balloon allows for readjustment of position after inflation of the inner balloon. Rapid right ventricular pacing was used during stent deployment in eight cases.

Table 1. Patient Characteristics (n = 30)

Mean age (yrs)	28.3 ± 17.5 (range 8-67)
Mean weight (kg)	62 ± 13 (range 28-86)
Patients <14 yrs (n)	4
Patients 14 to 18 yrs (n)	6
Patients >18 yrs (n)	20
Hypertension	21 (70%)
Isolated native aortic coarctation	14 (47%)
Previous interventions	16 (53%)
Aneurysms	8 (27%)

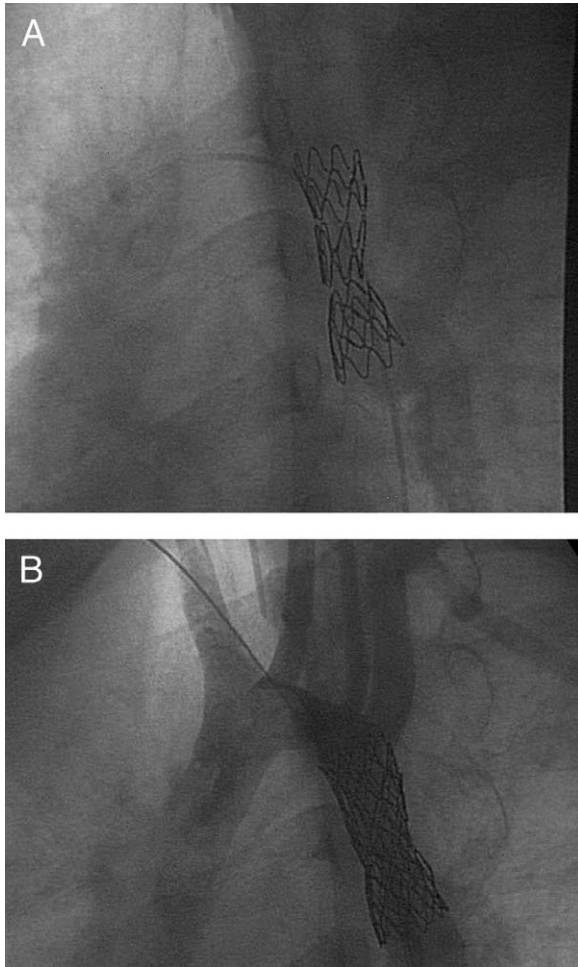


Figure 2. (A) Fractured stent before covered stent implantation. (B) Same patient as in panel A after covered stent implantation.

Hemostasis was achieved with the aid of Perclose devices in 21 of 30 cases (The Closer, Perclose Inc., Menlo Park, California, and Perclose AT, Abbott Vascular Devices, Redwood City, California). In three patients the arteriotomy was repaired surgically, whereas in six patients hemostasis was achieved by manual compression. Heparin at a dose of 50 to 100 IU/kg was given to maintain the activated clotting time >200 to 220 s during the procedure. Heparin infusion or subcutaneous low-molecular-weight heparin was administered for a total of 24 h. Antibiotics were given at the beginning of the procedure and continued for 24 h. Aspirin was administered to all patients the evening before the procedure at a dose of 3 to 5 mg/kg and continued for 6 weeks to 6 months.

RESULTS

Initial results. A total of 33 covered CP stents were implanted successfully in 30 patients. Two patients had two covered stents inserted on the day of the procedure, one because of a residual gradient of 26 mm Hg after insertion of the first covered stent and the second because of fracture of the welds of the covered stent used initially.

Median fluoroscopy time was 13 min. The systolic gradient between ascending and descending aorta decreased from a mean (\pm SD) of 36 ± 20 mm Hg to a mean of 4 ± 4 mm Hg ($p < 0.0001$), and the diameter of the CoA site increased from 6.4 ± 3.8 mm to 17.1 ± 3.1 mm ($p < 0.0001$). When a covered stent was used to deal with a previous aneurysm, the latter was completely excluded in all patients.

Immediate complications. Stent fracture was observed at the soldering joints in two patients. One patient underwent insertion of a second stent with reinforced soldering joints, whereas in the second patient no further stent insertion was required. Both of these stents were inserted in the early phase of our experience, before the newer CP stents with fortified welding joints became available.

One patient experienced a small subrenal aortic dissection that resolved six months later according to a diagnostic

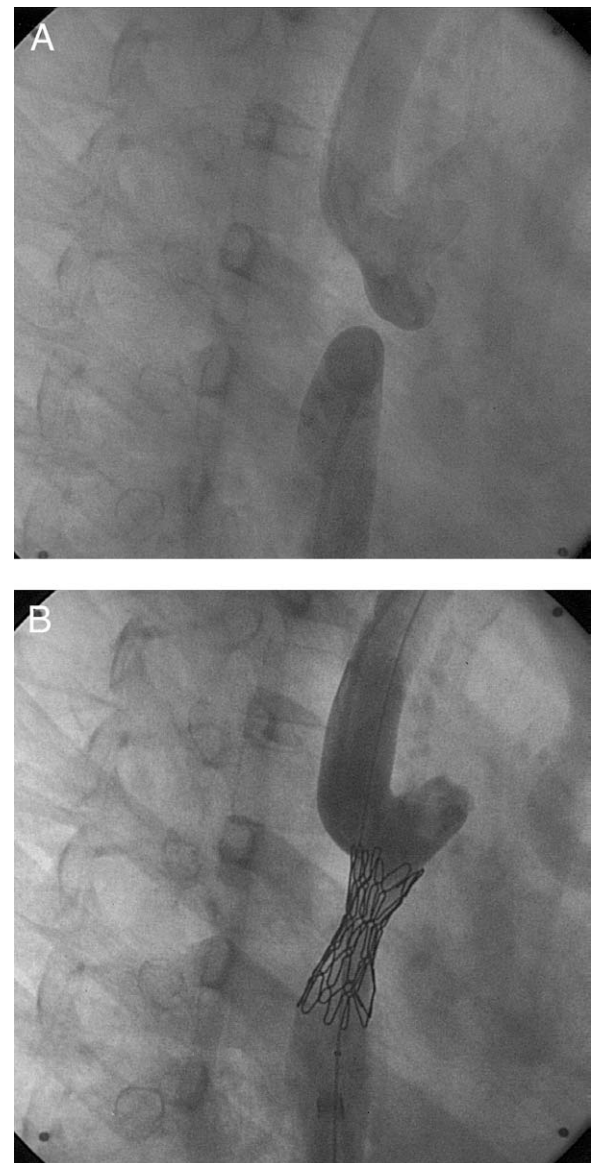


Figure 3. (A) Atretic aortic coarctation (CoA). (B) Same patient as in panel A after covered stent implantation.

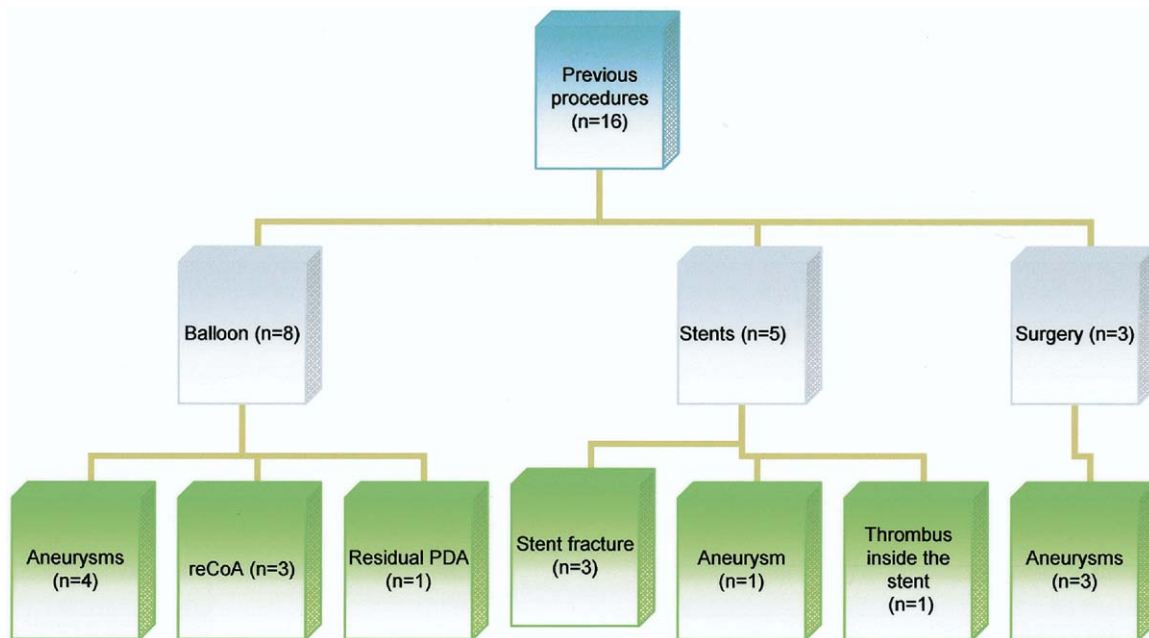


Figure 4. Breakdown of previous procedures with complications. CoA = aortic coarctation; PDA = patent ductus arteriosus.

angiogram, and a second patient had a small aneurysm of the right superficial femoral artery. Two patients experienced hematomas (one secondary to a neck line and the other at the site of femoral arterial cannulation). There have been no late complications.

Subsequent procedures. Four patients underwent further balloon dilation six months after the initial procedure. These were patients with nearly atretic lesions and extended distal arch hypoplasia, in whom, for safety reasons, we opted to insert a covered stent as a two-stage procedure with a suboptimal dilation initially and a full dilation later. The gradient across the CoA site decreased from 5 to 30 mm Hg after initial stent implantation to 0 to 10 mm Hg after the final stent dilation. One patient with New York Heart Association functional class III and a residual gradient of 15 mm Hg arising from a kink of the arch proximal to the stent underwent insertion of a second stent to cover the kink with good results and reduction of the residual gradient to 5 mm Hg.

Table 2. Indications for Insertion of Covered CP Stents

	No Previous Interventions (n = 14)	Previous Interventions (n = 16)
Near-atretic CoA	7	
Unfavorable CoA anatomy for conventional stenting (tortuous aortic arch and isthmus)	6	1
PDA	1	1
Aneurysms		8
Stent-related complications		4
Patient age and CoA severity		2

CoA = aortic coarctation; CP = Cheatham-platinum; PDA = patent ductus arteriosus.

Follow-up. The patients have been followed up for a period of up to 40 months (mean 11 months, median 12 months). Symptomatic patients have reported improvement of their exercise tolerance, and some patients have noticed significant improvement of their lower limb temperature and perfusion.

A spiral computed tomography or magnetic resonance imaging was performed 3 to 6 months after the procedure and confirmed good position of the stent, continued patency of the stent lumen and the head and neck vessels, and no residual CoA or aneurysm formation. No late stent fractures have been noted in our series to date.

Twenty-one of 30 patients were on antihypertensive medication before the procedure. In 9 of 21 (43%) patients, the medication was altered after stent implantation. In particular, in six patients the total number or dose of antihypertensive medications was reduced, whereas in three patients the medication was discontinued altogether. The systolic blood pressure overall decreased from a mean (\pm SD) of 146.6 ± 23.2 mm Hg before stent implantation to a mean of 134.2 ± 12.0 mm Hg on follow-up ($p = 0.004$).

DISCUSSION

The treatment of CoA has been the focus of many studies in the past few decades. Surgical repair, first performed by Crafoord and Nylin in 1944 (1), was initially the only available option, but in some cases it was complicated by restenosis, aneurysm formation (2,3), late hypertension, and premature death, particularly when the repair was performed after the first year of life (4,5). To deal with postoperative complications such as restenosis after surgical

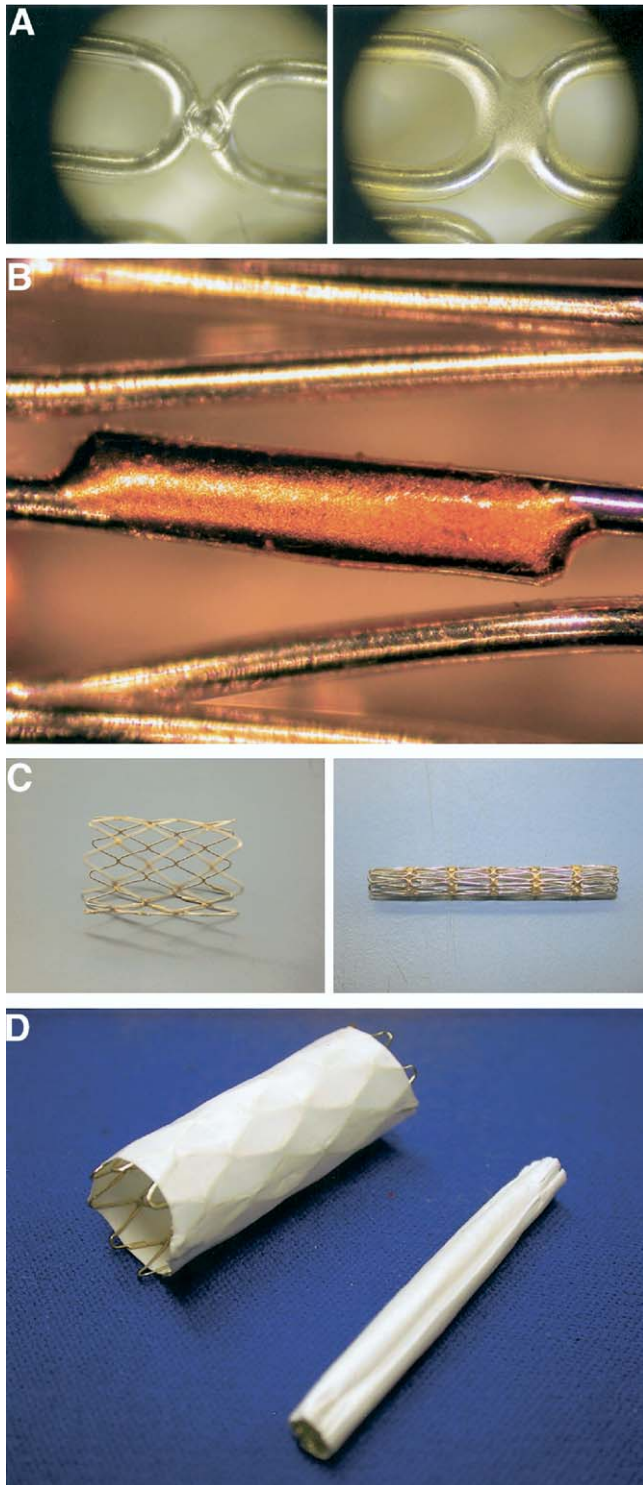


Figure 5. (A) Stent weld before and after the gold soldering process. (B) End weld encapsulated in gold. (C) Bare welds of the covered Cheatham-platinum (CP) stent. (D) Expanded and unexpanded covered CP stent.

repair with subsequent hypertension, balloon dilation of re-CoA was introduced in 1982 (6-8). It has been a widely used technique since then, although not without its problems: intimal and medial vessel wall tears, aneurysm forma-

tion, residual CoA, and re-CoA have been well described, whereas the severity of the underlying disease increases the procedural morbidity and mortality (4,9,10). Similar complications have been encountered at follow-up of patients with native CoA treated with balloon dilation (11-14). The incidence of early and late aneurysms after balloon angioplasty has been reported to be between 5% and 11.5% (4,7,12-16). Furthermore, increasing age has been found to be a risk factor for a suboptimal outcome. This has been attributed to the presence of fibrotic changes in the aorta secondary to longstanding obstruction, which may deem the lesion less amenable to ballooning (4,16). Cystic medial necrosis observed after percutaneous balloon angioplasty of CoA has also been suggested to be an additional potential factor contributing to adverse consequences, such as re-CoA and aneurysms (17,18).

In the mid-1980s, endovascular stents were used in the treatment of congenital heart disease (19,20), and a few years later balloon-expandable stents were used in the treatment of CoA in children (21-26). The advantages of balloon-expandable stents were: 1) provision of support to the vessel wall and apposition of the torn vessel intima to the media, and 2) the ability to perform redilatation to accommodate the patient's somatic growth. Although initially used to reduce vessel wall disruption, aneurysm formation after stent implantation or aortic dissection after stent dilatation have also been encountered with this technique in up to 5% of patients (4,26,27). These complications are inevitable consequences of the mechanism of dilation of the CoA site and so cannot be completely abolished.

Thoracic atherosclerotic aneurysms and infrarenal aortic aneurysms in adults have been managed with insertion of stent grafts since the early 1990s (28,29), whereas treatment of an abdominal aortic pseudoaneurysm with covered stents in a pediatric patient was first reported in 2000 in an adolescent girl with neurofibromatosis and abdominal CoA (30).

In 1999, the first covered stent was used to treat coexistent CoA and aneurysm of the aorta in a young man (31). Since then, very little has emerged in the literature on the use of covered stents in the treatment of CoA, and the existing studies were performed on a small number of patients (32-37). Several different covered stents have been used in the previously mentioned studies: 1) the AneurRx (Medtronic, Watford, England) self-expanding stent covered with a stretchable polytetrafluoroethylene membrane (31); 2) the graft Jomed stents (Jomed, Rangendingen, Germany) (32); 3) the self-expanding stent grafts (Braile stent, Braile Biomedica, Sao José do Rio Preto, Brazil) (37); and 4) the balloon-expandable Cheatham-platinum stents covered with expanded polytetrafluoroethylene (Figs. 5C and 5D). The latter stents are a more recent introduction (33,34,36,37), and are currently not available in the U.S.

The use of covered CP stents in patients with CoA can prevent or deal with the complications of aneurysm formation and stent fractures encountered with previously used

techniques by “sealing” the stenotic dilated area, the aneurysm, or the stent fracture. They provide increased safety in extreme forms of CoA or tortuous lesions, and can also be successfully used even in the case of fracture of a covered stent or a stent graft.

Their use is limited to patients that are (nearly) fully grown, because currently they can only be redilated up to 25 mm, and at diameters of up to 22 mm they can shorten by one-eighth of their initial length.

One of the main initial concerns with the use of covered stents was occlusion of a significant aortic side branch. It is obviously important to avoid covering the main arteries such as the innominate or the left common carotid arteries, but the left subclavian artery can be covered if necessary. The experience from vascular radiologists implanting stent grafts in the thoracic aorta has suggested that stent-graft-induced occlusion of the ostial left subclavian artery is tolerated well without chronic functional deficit in the absence of stenotic vertebral and/or carotid arteries and with a documented intact vertebrobasilar system (38). Furthermore, occlusion of a spinal artery, which would result in the most severe complication, is unlikely after implantation of a covered stent in the thoracic aorta, because the spinal artery originates below the level of the ninth thoracic vertebra in over 90% of the patients (39,40).

Since 2001 we have implanted 33 covered CP stents in 30 patients with complicated lesions after surgical or transcatheter repair and in patients at risk of developing complications because of the complex CoA anatomy (aortic arch and isthmus tortuosity or near interruption) or advanced age. Because covered stents can only be dilated up to a certain diameter, our patient population was fully grown patients in 87% of cases (26 of 30 patients), whereas 3 of our 4 pediatric patients were of adult size and weight at the time of the procedure.

In all cases, insertion of a covered stent dealt successfully with the aneurysmal areas and previous stent fractures with good hemodynamic and angiographic results at the end of the procedure. All aneurysms were completely excluded, and no aortic side branches were covered during covered stent implantation. When used to treat severe native CoA, no complications were noted at follow-up, up to 40 months later. In two cases, covered CP stents were used to simultaneously treat the CoA as well as a patent arterial duct, which was covered fully. This indication has been reported previously (36,37,41).

Two stent fractures at the soldering joints occurred in the early phase of our experience with the initial stent type. Since May 2002 the covered CP stents have been produced with reinforced golden soldering joints (Figs. 5A and 5B). We believe that stent fracture is unlikely with the reinforced stent when it is implanted in the target areas, and thus far we are not aware of any fractures when implanted in the aortic position.

CONCLUSIONS

Our study is a follow-up evaluation of our previous preliminary experience on the use of covered CP stents for aortic CoA, with inclusion of a much larger number of patients. Our early and intermediate-term results on the use of covered CP stents, as a rescue treatment in patients with CoA aneurysms or stent complications and in patients at risk of developing complications because of complex CoA anatomy, seem encouraging, with potential advantages over repeat surgery or further conventional stent insertion. Further studies and late follow-up of these patients are required.

Acknowledgments

The authors thank and acknowledge Mr. Allen Tower and Mr. Douglas Villnave of NuMed Inc. for their help and support in the development and modification of the CP stent.

Reprint requests and correspondence: Dr. Shakeel A. Qureshi, Department of Congenital Heart Disease, Evelina Children's Hospital, St. Thomas's Hospital, Lambeth Palace Road, London SE1 7EH, England. E-mail: shakeel.qureshi@gstt.nhs.uk.

REFERENCES

1. Crafoord C, Nylin G. Congenital coarctation of the aorta and its surgical treatment. *J Thorac Surg* 1945;14:347-61.
2. Bromberg BI, Beekman RH, Rocchini AP, et al. Aortic aneurysm after patch aortoplasty repair of coarctation: a prospective analysis of prevalence, screening tests and risks. *J Am Coll Cardiol* 1989; 14:734-41.
3. Parks WJ, Ngo TD, Plauth WH, et al. Incidence of aneurysm formation after Dacron patch aortoplasty repair for coarctation of the aorta: long term results and assessment utilizing magnetic resonance angiography with three dimensional surface rendering. *J Am Coll Cardiol* 1995;26:266-71.
4. Ovaert C, Benson LN, Nykanen D, Freedom RM. Transcatheter treatment of coarctation of the aorta: a review. *Pediatr Cardiol* 1998;19:27-44.
5. Cohen M, Fuster V, Steele PM, Driscoll D, McGoon DC. Coarctation of the aorta. Long term follow-up and prediction of outcome after surgical correction. *Circulation* 1989;80:840-5.
6. Singer MI, Rowen M, Dorsey TJ. Transluminal aortic balloon angioplasty for coarctation of the aorta in the newborn. *Am Heart J* 1982;103:131-2.
7. Hijazi ZM, Fahey JT, Kleinman CS, et al. Balloon angioplasty for recurrent coarctation of the aorta: immediate and long term results. *Circulation* 1991;84:1150-6.
8. Maheshwari S, Bruckheimer E, Fahey JT, et al. Balloon angioplasty of postsurgical recoarctation in infants: the risk of restenosis and long term follow-up. *J Am Coll Cardiol* 2000;35:209-13.
9. Hellenbrand WE, Allen HD, Golinko RJ, et al. Balloon angioplasty for aortic recoarctation: results of the valvuloplasty and angioplasty of congenital anomalies registry. *Am J Cardiol* 1990;65:793-7.
10. Ino T, Ohkubo M. Dilation mechanism, causes of restenosis and stenting in balloon coarctation angioplasty. *Acta Paediatr* 1997;86: 367-71.
11. Tynan M, Finley JP, Fontes V, et al. Balloon angioplasty for the treatment of native coarctation: results of the valvuloplasty and angioplasty of congenital anomalies registry. *Am J Cardiol* 1990;65: 790-2.
12. Fletcher SE, Nihill MR, Grifka RG, O'Laughlin MP, Mullins CE. Balloon angioplasty of native coarctation of the aorta: midterm follow-up and prognostic factors. *J Am Coll Cardiol* 1995;25:730-4.

13. Rao PS, Galal O, Smith PA, Wilson AD. Five to nine year follow-up results of balloon angioplasty of native coarctation in infants and children. *J Am Coll Cardiol* 1996;27:462-70.
14. Mendelsohn AM, Lloyd TR, Crowley D, et al. Late follow-up of balloon angioplasty in children with a native coarctation of the aorta. *Am J Cardiol* 1994;74:696-700.
15. Marshall A, Perry SB, Keane JF, et al. Early results and medium-term follow-up of stent implantation for mild residual or recurrent aortic coarctation. *Am Heart J* 2000;139:1054-60.
16. McCrindle BW, Jones TK, Morrow WR, Hagler DJ, Lloyd TR, Nouri S, Latson LA. Acute results of balloon angioplasty of native coarctation versus recurrent aortic obstruction are equivalent. *J Am Coll Cardiol* 1996;28:1810-7.
17. Isner JM, Donaldson RF, Fulton D, Bhan I, Payne DD, Cleveland RJ. Cystic medial necrosis in coarctation of the aorta: a potential factor contributing to adverse consequences observed after percutaneous balloon angioplasty of coarctation sites. *Circulation* 1987;75:689-95.
18. Rao PS, Waterman B. Relation of biophysical response of coarcted aortic segment to balloon dilatation with development of recoarctation following balloon angioplasty of native coarctation. *Heart* 1998;79:407-11.
19. Palmaz JC. Balloon expandable intravascular stent. *AJR Am J Roentgenol* 1988;150:1263-9.
20. O'Laughlin MP, Perry SB, Lock JE, Mullins CE. Use of endovascular stents in congenital heart disease. *Circulation* 1991;83:1923-39.
21. Ebeid MR, Prieto LR, Latson LA. Use of balloon expandable stents for coarctation of the aorta: initial results and intermediate term follow-up. *J Am Coll Cardiol* 1997;30:1847-52.
22. Cheatham JP. Stenting of coarctation of the aorta. *Catheter Cardiovasc Interv* 2001;54:112-25.
23. Magee AG, Brzezinska-Rajszyz G, Qureshi SA, Rosenthal E, Zubrzycka M, Ksiazek J, Tynan M. Stent implantation for aortic coarctation and recoarctation. *Heart* 1999;82:600-6.
24. Thanopoulos BD, Hadjiniakolaou L, Konstadopoulou GN, Tsaousis GS, Triposkiadis F, Spiropoulos P. Stent treatment for coarctation of the aorta: intermediate term follow-up and technical considerations. *Heart* 2000;84:65-70.
25. Hamdan MA, Maheshwari S, Fahey JT, Hellenbrand WE. Endovascular stents for coarctation of the aorta: initial results and intermediate term follow-up. *J Am Coll Cardiol* 2001;38:1518-23.
26. De Lezo JS, Pan M, Romero M, et al. Immediate and follow-up findings after stent treatment for severe coarctation of aorta. *Am J Cardiol* 1999;83:400-6.
27. Varma C, Benson LN, Butany J, McLaughlin PR. Aortic dissection after stent dilatation for coarctation of the aorta: a case report and literature review. *Catheter Cardiovasc Interv* 2003;59:528-35.
28. Taylor PR, Gaines PA, McGuinness CL, Beard JD, Cooper G, Reidy JF. Thoracic aortic stent grafts-early experience from two centers using commercially available devices. *Eur J Vasc Endovasc Surg* 2001;22:70-6.
29. White GH, Lennox AF, May J. Covered stents in the management of infrarenal aortic aneurysms. In: Rao PS, Kern MJ, editors. *Catheter Based Devices*. Philadelphia, PA: Lippincott, Williams & Wilkins, 2003:427-38.
30. Khan MS, Moore JW. Treatment of abdominal aortic pseudoaneurysm with covered stents in a paediatric patient. *Catheter Cardiovasc Interv* 2000;50:445-8.
31. Gunn J, Cleveland T, Gaines P. Covered stent to treat coexistent coarctation and aneurysm of the aorta in a young man. *Heart* 1999;82:351.
32. DeGiovanni JV. Covered stents in the treatment of aortic coarctation. *J Interv Cardiol* 2001;14:187-90.
33. Qureshi SA, Zubrzycka M, Brzezinska-Rajszyz G, Kosciesza A, Ksiazek J. Use of covered Cheatham-platinum stents in aortic coarctation and recoarctation. *Cardiol Young* 2004;14:50-4.
34. Ewert P, Abdul-Khalid H, Peters B, Nagdyman N, Schubert S, Lange PE. Transcatheter therapy of long extreme subaortic coarctations with covered stents. *Catheter Cardiovasc Interv* 2004;63:236-9.
35. Forbes T, Matisoff D, Dysart J, et al. Treatment of coexisting coarctation and aneurysm of the aorta with covered stent in a pediatric patient. *Pediatr Cardiol* 2003;24:289-91.
36. Sadiq M, Malick NH, Qureshi SA. Simultaneous treatment of native coarctation of the aorta combined with patent ductus arteriosus using a covered stent. *Catheter Cardiovasc Interv* 2003;59:387-90.
37. Pedra CA, Fontes VF, Esteves CA, et al. Use of covered stents in the management of coarctation of the aorta. *Pediatr Cardiol* 2005;26:431-9.
38. Rehders TC, Petzsch M, Ince H, et al. Intentional occlusion of the left subclavian artery during stent-graft implantation in the thoracic aorta: risk and relevance. *J Endovasc Ther* 2004;11:659-66.
39. Wada T, Yao H, Miyamoto T, Mukai S, Yamamura M. Prevention and detection of spinal cord injury during thoracic and thoraco-abdominal aortic repairs. *Ann Thorac Surg* 2001;72:80-4.
40. Connolly JE. Prevention of spinal cord complications in aortic surgery. *Am J Surg* 1998;176:92-101.
41. Hijazi ZM. Need for covered stents for congenital cardiac intervention. *Catheter Cardiovasc Interv* 2003;59:391.