



REVISTA BRASILEIRA DE REUMATOLOGIA

www.reumatologia.com.br



SOCIEDADE BRASILEIRA
DE REUMATOLOGIA

Case report

Colonic perforation due to invasive amebic colitis during anti-TNF therapy for spondyloarthritis[☆]



Juan Pablo Restrepo^{a,*}, María del Pilar Molina^b

^a Universidad Quindío, Quindío, Colômbia

^b Universidad Libre, Quindío, Colombia

ARTICLE INFO

Article history:

Received 7 July 2013

Accepted 27 September 2013

Available online 23 October 2014

Keywords:

Anti-TNF Inhibitors

Colonic Perforation

Amebic Colitis

ABSTRACT

TNF blockade has been successful in the treatment of some rheumatic diseases such as spondyloarthritis. Many infectious complications have been reported with anti-TNF therapy, mainly bacterial, mycobacterial, viral and fungal infections. *Entamoeba histolytica* is an extracellular protozoan parasite that mainly causes colitis and hepatic abscess; bowel perforation is an uncommon complication with high mortality. TNF is considered the principal mediator of cell immunity against amebiasis. Initially, it is chemotactic to *E. histolytica*, enhancing its adherence to enterocyte via galactose inhibitable lectin, and then activating macrophages to kill ameba though the release of NO, so that TNF blocking could be harmful, increasing amebic virulence. We describe the case of a 46-year-old woman with spondyloarthritis who presented a colonic perforation due to invasive amebic colitis during anti-TNF use.

© 2014 Elsevier Editora Ltda. All rights reserved.

Perfuração do colo por colite amebiana invasiva durante terapia anti-TNF para espondiloartrite

RESUMO

O bloqueio do TNF tem tido sucesso no tratamento de algumas doenças reumáticas, como a espondiloartrite. Relatam-se muitas complicações infecciosas com a terapia anti-TNF, principalmente infecções bacterianas, micobacterianas, virais e fúngicas. A *Entamoeba histolytica* é um protozoário extracelular que causa principalmente colite e abscesso hepático, sendo que a perfuração intestinal é uma complicação rara, com alta mortalidade. O TNF é considerado o principal mediador da imunidade celular contra a amebíase. Inicialmente, é quimiotático para a *E. histolytica*, potencializando sua adesão ao enterócito por meio da lectina galactose-inibível, e depois ativando os macrófagos para matarem a ameba pela

Palavras chave:

Inibidores Anti-TNF, Perfuração do colo, Colite amebiana

DOI of original article: <http://dx.doi.org/10.1016/j.rbr.2013.09.004>.

[☆] The case was originated in Servicio Occidental de Salud, Rheumatology section, Cali, Colombia.

* Corresponding author.

E-mail: jprestrep@lycos.com (J.P. Restrepo).

<http://dx.doi.org/10.1016/j.rbre.2013.09.004>

2255-5021/© 2014 Elsevier Editora Ltda. All rights reserved.

liberação de NO; assim, o bloqueio do TNF poderia ser prejudicial, aumentando a virulência amebiana. Descreve-se o caso de uma mulher de 46 anos com espondiloartrite que apresentou uma perfuração do colo por colite amebiana invasiva durante uso de anti-TNF.

© 2014 Elsevier Editora Ltda. Todos os direitos reservados.

Introduction

TNF (tumoral necrosis factor) is a major cytokine involved in the pathogenesis of rheumatoid arthritis and spondyloarthritis. TNF inhibitors have been showed to be effective in the treatment of axial and peripheral spondyloarthritis and in some extraarticular manifestations, however some infectious complications have been reported. These included bacterial, mycobacterial, viral and fungal infection. Amebic infection has not been described during anti-TNF inhibitor. We describe a 46-year-old woman with spondyloarthritis who presented a colonic perforation due to invasive amebic colitis during anti-TNF use.

Case report

A 46-year-old female with a previous diagnosis of spondyloarthritis based on ASAS criteria,¹ who was been treated with subcutaneous adalimumab 40 mg every other week during 4 months and good disease control activity. She presented diffuse abdominal pain and mucous diarrhea for 2 weeks. Physical exam revealed distended abdomen without bowel sounds and diffuse rebound tenderness, so a diagnosis of acute peritonitis was done. Laboratory tests gave the following results: leucocyte count: 11.980/mm³ with 73% of neutrophils, hemoglobin: 9.6 gr/dL, CRP: 55 mgr/L. Emergency laparotomy showed multiple and small colonic perforations and severe peritonitis; right hemicolectomy, mucous fistula of ileon and intraperitoneal drainage were performed. Metronidazole, ertapenem, teclozan were administered during her hospitalization in intensive care unit. Histopathological examination of the resected gut revealed extensive areas of ulceration with abundant trophozoites of *E histolytica* (Figs. 1 and 2). One month later the patient was discharged without other complication. At this time the patient is being medicated with naproxen 250 mgr BID with partial response, while ileostomy closure is done to resume adalimumab.

Discussion

Entamoeba histolytica is an extracellular protozoan parasite that causes mainly colitis and hepatic abscess and it is responsible of 100.000 deaths worldwide every year. Bowel perforation occurs between 1%-6% of the patients with amebiasis but its mortality is extremely high ranging from 55% to 100%.²

TNF plays an important role in the pathogenesis of parasitic infection^{3,4} and it is considered the principal mediator of cell immunity against amebiasis. Gamma interferon, colony-stimulating factor 1 act synergistically with TNF in

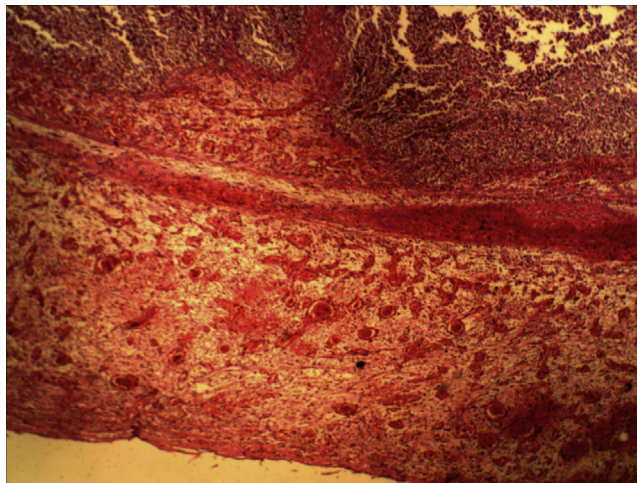


Figure 1 – Histological examination of the resected colon demonstrated extensive mucosal ulceration.

macrophage activation using a murine mode.⁵ TNF produced by macrophages can kill *E histolytica* in vitro.⁶

Oppositely, Blasquez et al demonstrated that TNF can enhance amebic virulence and is chemotactic for *E histolytica*.⁷ Amebic adherence to colonic mucosa is mediated by galactose inhibitable lectin⁸ which is a potent stimulant of TNF production. Nitric oxid (NO) is a major effector molecule produced by activated macrophages for in vitro toxicity against *E histolytica* trophozoites and its production is increased by TNF.⁹ Macrophages isolated from amoebic liver granulomas are defective for the production of

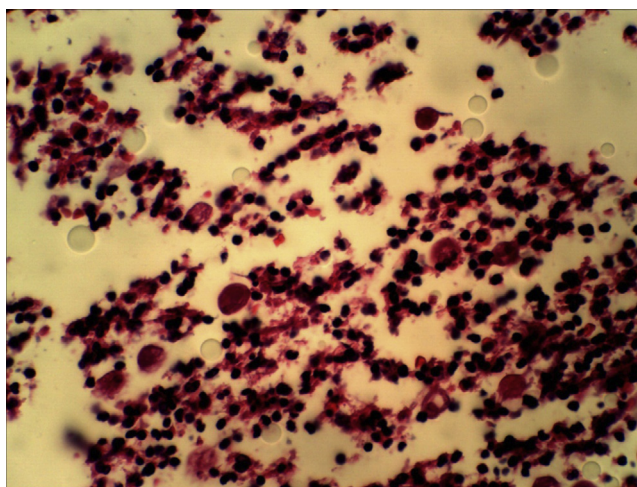


Figure 2 – High power view of trophozoites of *E histolytica* in right colon (40x).

TNF,¹⁰ NO,¹¹ H₂O₂.¹² Finally anti-TNF antibodies inhibit TNF release, NO production, and amebicidal activity by activated murine macrophages.¹³

In conclusion TNF has a dual role, initially is chemotactic to *E. histolytica*, enhancing its adherence to enterocyte via galactose inhibitable lectin and then activating macrophages to kill ameba though the release NO so that TNF blocking could be harmful increasing amebic virulence. From our knowledge this is the first case of colonic perforation due to invasive amebic colitis during anti-TNF therapy. We recommend deworming against *E. histolytica* in endemic areas prior the beginning of anti-TNF therapy and regularly during its use.

REFERENCES

- Rudwaleit M, Van der Heijde D, Ladewé R. The development of assessment of spondyloarthritis international society classification criteria for axial spondyloarthritis (part II): validation and final selection. *Ann Rheum Dis*. 2009;68:777-83.
- Ishida H, Inokuma S, Murata N, Hashimoto D, Satoh K, Ohta S. Fulminant amoebic colitis with perforation successfully treated by staged surgery: a case report. *J Gastroenterol*. 2003;38:92-6.
- Clark I, Cowden W, Butcher G, Hunt N. Possible roles of tumor necrosis factor in the pathology of malaria. *Am J Pathol*. 1987;129:192-9.
- Moll H, Kerstin B, Bogdan C, Solbach W, Rollinghoff M. Production of tumor necrosis factor during murine cutaneous leishmaniasis. *Parasite Immunol*. 1990;12:438-94.
- Denis M, Chadee K. Cytokine activation of murine macrophages for in vitro killing of *Entamoeba histolytica* trophozoites. *Infect Immun*. 1989;57:1750-6.
- Denis M, Chadee K. Human neutrophils activated by interferon- γ and tumour necrosis factor- α kill *Entamoeba histolytica* in vitro. *J Leukocyte Biol*. 1989;46:270-4.
- Blasquez S, Zimmer C, Guigon G, Olivo-Marin J, Guillén N, Labruyère E. Human tumor necrosis factor is a chemoattractant for the parasite *Entamoeba histolytica*. *Infect Immun*. 2006;74:1407-11.
- Petri W, Smith R, Schlesinger P, Murphy C, Ravdin J. Isolation of the galactose-binding lectin which mediates the in vitro adherence of *Entamoeba histolytica*. *J Clin Invest*. 1987;80:1238-44.
- Lin J, Chadee K. Macrophage cytotoxicity against *Entamoeba histolytica* trophozoites is mediated by nitric oxide from L-arginine. *Immunol*. 1992;148:3999-4005.
- Wang W, Keller K, Chadee K. Modulation of tumour necrosis factor production in macrophages in *Entamoeba histolytica* infections. *Infect Immun*. 1992;60:3169-74.
- Wang W, Keller K, Chadee K. *Entamoeba histolytica* modulates the nitric oxide synthase gene and nitric oxide production for cytotoxicity against amoebae and tumour cells. *Immunol*. 1994;83:601-10.
- Denis M, Chadee K. In vitro and in vivo studies of macrophage functions in amoebiasis. *Infect Immun*. 1988;56:3126-31.
- Lin JY, Seguin R, Keller K, Chadee K. Tumor necrosis factor alpha augments nitric oxide-dependent macrophage cytotoxicity against *Entamoeba histolytica* by enhanced expression of the nitric oxide synthase gene. *Infect Immun*. 1994;62:1534-41.