



Metastatic pheochromocytoma to liver without elevation of metanephrines and catecholamines[☆]



Javier López-Gómez^{a,*}, Ma. Alejandra Salazar-Álvarez^a, Rodrigo Y. Adame^a,
Alejandro Alfaro-Goldaracena^a, Erwin R. Flores-Vazquez^a, Sergio H. Gonzalez-Infante^a,
Alejandro E. Padilla-Rosciano^b, Horacio N. López-Basave^b

^a Department of Oncologic Surgery, National Cancer Institute, Mexico City, Av. San Fernando No. 22, Col. Seccion XVI, C.P. 14080, Mexico

^b Surgical Department of Gastrointestinal Tumors, National Cancer Institute, Mexico City, Av. San Fernando No. 22, Col. Seccion XVI, C.P. 14080, Mexico

ARTICLE INFO

Article history:

Received 19 August 2016

Received in revised form 20 October 2016

Accepted 21 October 2016

Available online 22 October 2016

Keywords:

Metastatic pheochromocytoma

Synchronous metastases

M

etanephrines - Catecholamines

ABSTRACT

INTRODUCTION: Malignant pheochromocytoma represents 10% of all patients with pheochromocytoma. Of these cases, only 5–9% presents without elevation of metanephrines and catecholamines.

PRESENTATION OF CASE: A 43-year-old female patient presented with an abdominal tumor. An exploratory laparotomy was performed and the final report was a pheochromocytoma. After ten years, multiple liver lesions were detected and surgical treatment was performed. Pathological evaluation revealed a malignant pheochromocytoma with negative margins after 5 years of follow-up without evidence of disease.

DISCUSSION: The recurrence rate of malignant pheochromocytoma is 15–20% at ten years and a 5-year survival rate that ranges from 50% to 80%. The presence of synchronous metastases is rare (10–27%), but have been reported until 20 years later with the most common metastatic sites being the local lymph nodes, bone (50%), liver (50%) and lung (30%). The prognostic factor such as size >6 cm, age over 45 years, synchronous metastasis and no tumor excision are related with poor prognosis.

CONCLUSION: Surgical treatment offers the best survival rate and the only chance of cure so far and the goal is an R0 resection as in our case. So it should be the treatment of choice.

© 2016 The Authors. Published by Elsevier Ltd on behalf of IJS Publishing Group Ltd. This is an open access article under the CC BY-NC-ND license (<http://creativecommons.org/licenses/by-nc-nd/4.0/>).

1. Introduction

Pheochromocytomas are neuroendocrine tumors from chromaffin cells of the adrenal medulla, with a prevalence in the general population of only 2 cases per million. It is estimated that up to 5% of patients presenting with adrenal incidentalomas are found to have pheochromocytomas. [1,13]. Of this, only 10% are malignant pheochromocytoma characterized by the presence of metastasis which spread to organs where no chromaffin cells are present. [1].

The clinical presentations in approximately 40–88% are the classic symptoms of headaches, sweating, palpitations, and paroxysmal or sustained hypertension, but might be asymptomatic as well [2,12]. Hypertension represents the main morbidity and mortality risk factor. It requires specialized handling especially in patients who are candidates for surgery. The diagnosis requires

biochemical test but they not always rise (4–9%) and there is no way to differentiate the malignant variant [1,2,13].

The location of the tumor is essential in patients with resectable metastasis because surgery offers the only chance of cure and the best survival rate of 80% at 5 years [1,2,5]. MRI has a higher sensitivity and specificity in the case of hepatic metastasis. [2,9]. Today the PET/CT with FDG is the study of choice compared with CT and other functional studies 123I-MIBG [2,10].

Symptomatic treatment with alpha- and beta-adrenergic blockade should be offered to patients with good results. Systemic chemotherapy, radiopharmaceutical therapy using beta-emitting isotopes coupled with metaiodobenzylguanidine (MIBG) or somatostatin analogue had poor results. [1,2]. The molecular targeting therapies such as Sunitinib seem to have adverse effects particularly some mutations (SDH/VHL) [7]. Surgical resection is the only curative therapeutic modality. However, rarely feasible, the resection of hepatic metastases improve symptoms and survival [1,2,5].

[☆] Key learning points: (1) Metastatic pheochromocytoma (2) Metastatic pheochromocytoma to liver.

* Corresponding author at: Department of Oncologic Surgery, National Cancer Institute, Mexico city, Av. San Fernando No. 22, Col. Seccion XVI, C.P. 14080, Mexico.

E-mail addresses: javierlopgom@hotmail.com, dr.javierlopgom@gmail.com (J. López-Gómez).

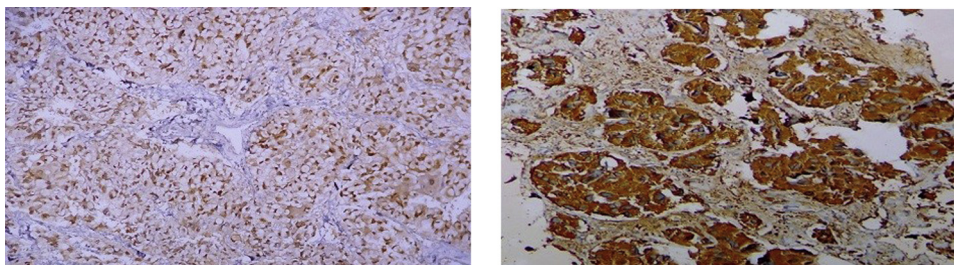


Fig. 1. 1.1) Immunohistochemistry: Pheochromocytoma. 1.2) S100 positiv. Immunohistochemistry: Pheochromocytoma. Cromogranina.

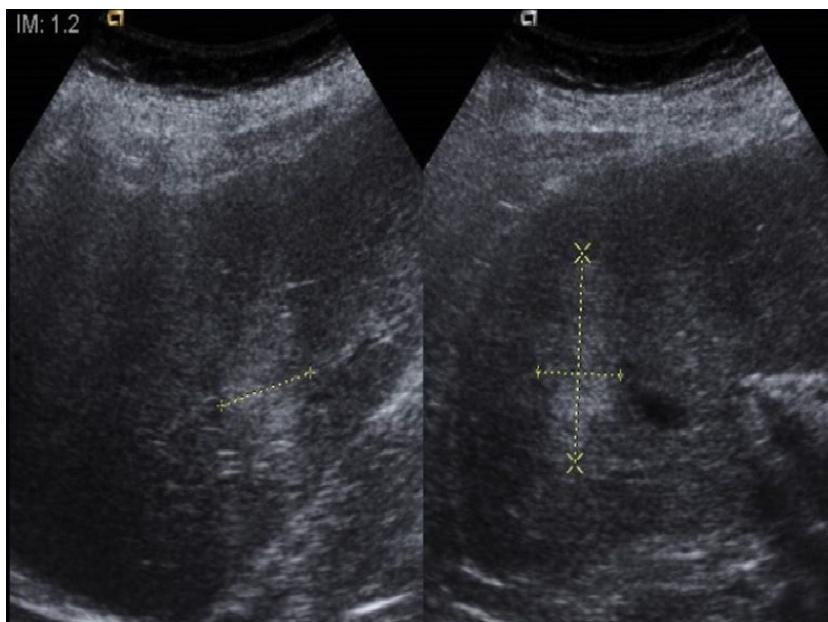


Fig. 2. Abdominal ultrasound showing a 4 × 5 cm mass in liver.

2. Clinical case

A 43-year-old female patient with antecedent ovarian cystadenoma was admitted in our institute with 1-year history of lower abdominal pain. Patient evaluation revealed a non-painful, firm abdominal mass, of 5 × 6 cm diameter in the right flank. Complete analysis and tumors markers were negative for germ cell tumor (alpha-fetoprotein and human chorionic gonadotropin). Abdominal computerized tomography scan (CT) showed a solid mass, with central necrosis, located in the hepatorenal space as incidentaloma with negative metanephrines and catecholamines.

We decided a surgical treatment. An exploratory laparotomy was performed and right nephrectomy, finding a tumor above the upper pole of the right kidney with infiltration of the inferior vena cava. No intraoperative complications were reported and the post-operative course was successful. Pathologic evaluation revealed a pheochromocytoma confirmed by immunohistochemistry (positive in chromogranin A, S100 protein, inaptofisin and imentin, Negative in CK –7). (Fig. 1.1, 1.2)

The patient was under surveillance without recurrence for 10 years, abdominal ultrasound showed a 4 × 5 cm mass in segments IVA and V of the liver. (Fig. 2). The magnetic resonance revealed lesions in liver suggestive of malignancy in segments IVA, VI and VII (Fig. 3). CT – guided biopsy was performed and reported Metastatic pheochromocytoma, with negative metanephrines and catecholamines test. During follow-up chromogranin A was not used because there is no evidence to support this.

VI and VII segmentectomies of the liver were performed, suspicious lesions were found in II and IVA segments, so we decided to make metastasectomy of these lesions, with four metastatic lesions resected in total. The pathological evaluation revealed a malignant pheochromocytoma in all segments of liver with negative margins (Fig. 4 4.1, 4.2, 4.3).

There is no evidence of recurrence after 5 years of surveillance after last surgery. At the time, the patient is completely asymptomatic, with negatives CT scans and normal measurements of urinary and plasma fractionated metanephrines and catecholamines during follow-up.

3. Discussion

Pheochromocytomas are neuroendocrine tumors from chromaffin cells of the adrenal medulla having a prevalence in the general population of only 2 cases per million, it is estimated that up to 5% of patients presenting with adrenal incidentalomas are found to have pheochromocytomas. [1,13]. The characteristic of malignant pheochromocytoma is the presence of metastasis which spread to organs where no chromaffin cells are present. Approximately 10% of pheochromocytomas are malignant [1]. The recurrence rate is 15–20% at ten years and a 5-year survival rate that ranges from 50% to 80% [1,2]. The presence of synchronous metastases is rare (10–27%), but have been reported until 20 years later with the most common metastatic sites being the local lymph nodes, bone (50%), liver (50%) and lung (30%) [1,3]. The prognostic

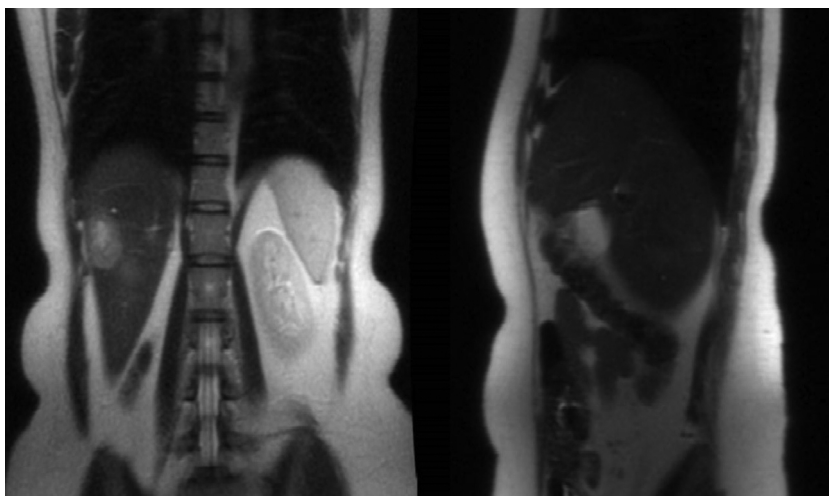


Fig. 3. Abdominal RM: A 3 × 2 cm mass in liver.

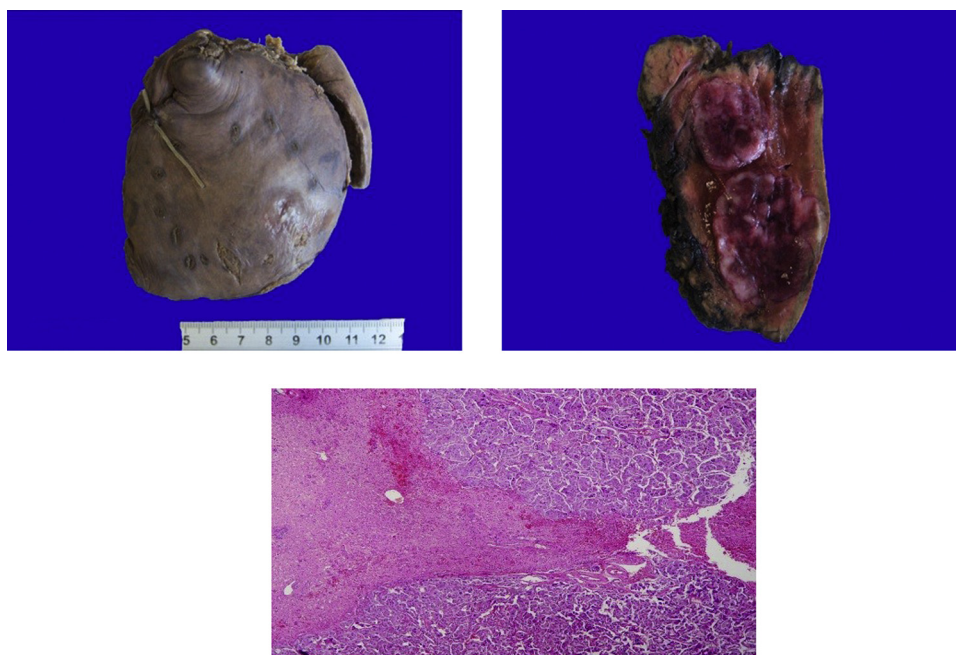


Fig. 4. 4.1.) Hepatic segmentectomy. 4.2.) Hepatic segmentectomy. 2 nodules poorly defined, fle. 4.3.) Pathological evaluation. Liver parenchyma infiltrate.

factor such as size >6 cm, age over 45 years, synchronous metastasis and no tumor excision are related with poor prognosis [1].

Genetic alterations of these genes are associated with transcriptome changes and are divided into 2 main clusters: cluster 1 including the von Hippel-Lindau (VHL) gene, the succinate dehydrogenase (SDH) complex, the fumarate hydratase (FH), the hypoxia-inducible factor 2-alpha (HIF2A) and the propyl hydroxylase domain-containing protein 1 and 2 (PHD1, PHD2) genes; and cluster 2 including the rearranged during transfection proto-oncogene (RET), the neurofibromin 1 (NF1), the transmembrane protein 127 (TMEM 127) and the Myc-associated factor X (MAX) genes [4]. A germline mutation in one of the susceptibility genes identified so far explains approximately 40% of cases with the remaining 60% considered to be sporadic. [2]. The only predictor of malignancy is the SDHB gene germline mutation as it is found in more than 40% of cases and are associated with response to temozolomide [12]. The clinical presentation is similar to non-malignant form, 40 to 88% presents with headaches, sweating, palpita-

tions, and paroxysmal or sustained hypertension, non-secreting benign pheochromocytomas are presented as incidentalomas, a recent study show that they are more likely to present with vertigo/dizziness than those with positive tumor markers (28% vs 3%) [2,13]. There are no data in the medical literature of the clinical presentation in patients with malignant pheochromocytomas without elevation of metanephrines and catecholamines. The initial biochemical test is the measurement of free plasma and urinary fractionated metanephrines, a more than fourfold elevation is associated with a 100% probability [8]. But they not always rise (4–9%) and there is no way to differentiate the malignant variant as in this case report [1,2,13].

Both MRI and CT exert a 85–100% sensitivity with a 50% specificity, and are important in the planning of surgical treatment. The size of tumor >45 mm is one of the important features that suggest malignancy. MRI has a higher sensitivity and specificity for staging and follow-up especially in the case of hepatic metastasis. [2,9] Currently, the PET/CT with FDG is the study of choice for the anatomic

location compared with CT and other functional studies 123I-MIBG [2,10].

The Adrenal gland Scaled Score (PASS) is the main histological tool to separate benign from malignant pheochromocytoma, a cut of >4 has a sensitivity of 50% and specificity of 45% to separate tumors with a potential for a biologically aggressive behavior [11]. Currently, no absolute molecular or immunohistochemical marker is available to differentiate malignant pheochromocytoma, but a cut of >3 Ki-67/Mib-1 nuclear antigen is correlating mostly with aggressive behavior [1].

Symptomatic treatment with alpha- and beta-adrenergic blockade in lytic bone metastases with the use of bisphosphonates, radiotherapy or radiofrequency ablation with good results is advisable. The strategy of wait and see is a good option for asymptomatic patients, 50% of patients had stable disease after 1 year of follow-up, requires monitoring with paraclinical studies and progression (20% by RECIST criteria) is indicative of disease intervention [2]. Systemic chemotherapy responses of 65% the combination with cyclophosphamide, vincristine and dacarbazine. Other alternative regimens include etoposide and cisplatin, anthracycline plus CVD and arabinoside. Its preferred in rapidly progressive tumors [2]. CVD obtains 37% tumor and 40% hormonal response, complete remission in only 4% of patients. The overall median survival varies from 24 months to 6 years depending on catecholamine and tumor response and the median progression-free survival ranges from 20 to 40 months [6]. Radiopharmaceutical therapy using beta-emitting isotopes coupled with metaiodobenzylguanidine (MIBG) with responses partial response (RECIST criteria) of 84.6% or somatostatin analogue with poor results. [1,2]. The molecular targeting therapies under study have shown a role of inhibiting tyrosine kinase such as Sunitinib with benefit in metastatic SDH or VHL mutated [7]. All these therapies have been unsatisfactory. Surgical resection is the only curative therapeutic modality. However, rarely feasible, the resection of hepatic metastases improve symptoms and survival, the effect is greater in patients with a Ki-67 <20% and R0 resection [1,2,5].

We present a patient who presents with incidentaloma which caused an exploratory laparotomy reaching the diagnosis of pheochromocytoma. During follow-up ten years after, multiple liver lesions were detected with negative metanephrines and catecholamines test, CT-guided biopsy was performed and reported metastatic pheochromocytoma. We decided to perform a segmentectomy of VI and VII and metastasectomy of the segments II and IVa with R0 margins. A 5-year follow-up was without evidence of disease.

4. Conclusions

The malignant pheochromocytoma is a rare entity. We present a case without elevation of biochemical markers and asymptomatic which is extremely rare. Based on this case, we recommend following up with US, CT or MRI in patients with pheochromocytoma treated indefinitely because metachronous metastasis may appear. Finding liver lesions should make us think about the malignant variant. Surgical treatment offers the best survival rate and the only chance of cure so far and the goal is an R0 resection as in our case. So it should be the treatment of choice

Consent

Written informed consent was obtained from the patient for publication of this case report and case series and accompanying images. A copy of the written consent is available for review by the Editor-in-Chief of this journal on request. This work has been reported in line with the SCARE criteria [14].

Conflict of interest

None of the authors have conflict of interest.

Sources of funding

None of the authors have sources of funding.

Ethical approval

Approval has been given.

Author contribution

Dr. Javier López-Gómez – Design, data collection, data analysis, writing the paper.

Dra. Ma. Alejandra Salazar-Álvarez – Data collection and writing the paper.

Dr. Rodrigo Y. Adame – Data collection and writing the paper.

Dr. Alejandro Alfaro-Goldaracena – Data collection and writing the paper.

Dr. Erwin R. Flores-Vazquez – Data collection and writing the paper.

Dr. Sergio H. Gonzalez-Infante – Data collection and writing the paper.

Dr. Alejandro E. Padilla-Rosciano – Data analysis, data interpretation and writing the paper.

Dr. Horacio N. López-Basave – Data analysis, data interpretation and writing the paper.

Guarantor

Javier López-Gómez.

References

- [1] Y.M. Choi, T.-Y. Sung, W.G. Kim, J.J. Lee, J.-S. Ryu, T.Y. Kim, W.B. Kim, S.J. Hong, D.E. Song, Y.K. Shong, Clinical course and prognostic factors in patients with malignant pheochromocytoma and paraganglioma: a single institution experience, *J. Surg. Oncol.* (2015), <http://dx.doi.org/10.1002/jso.24063>, n/a-n/a.
- [2] A. Angelousi, E. Kassi, G. Zografos, G. Kaltsas, Metastatic pheochromocytoma and paraganglioma, *Eur. J. Clin. Invest.* 45 (2015) 986–997, <http://dx.doi.org/10.1111/eci.12495>.
- [3] E.L. Bravo, R. Tagle, Pheochromocytoma: state-of-the-art and future prospects, *Endocr. Rev.* 24 (2003) 539–553, <http://dx.doi.org/10.1210/er.2002-0013>.
- [4] J. Favier, L. Amar, A.-P. Gimenez-Roqueplo, Paraganglioma and pheochromocytoma: from genetics to personalized medicine, *Nat. Rev. Endocrinol.* 11 (2015) 101–111, <http://dx.doi.org/10.1038/nrendo.2014.188>.
- [5] F.M. Watzka, C. Fottner, M. Miederer, A. Schad, M.M. Weber, G. Otto, H. Lang, T.J. Musholt, Surgical therapy of neuroendocrine neoplasm with hepatic metastasis: patient selection and prognosis, *Langenbecks Arch. Surg.* 400 (2015) 349–358, <http://dx.doi.org/10.1007/s00423-015-1277-z>.
- [6] N.D. Niemeijer, G. Alblas, L.T. Van Hulsteijn, O.M. Dekkers, E.P.M. Corssmit, Chemotherapy with cyclophosphamide, vincristine and dacarbazine for malignant paraganglioma and pheochromocytoma: systematic review and meta-analysis, *Clin. Endocrinol. (Oxf.)* 81 (2014) 642–651, <http://dx.doi.org/10.1111/cen.12542>.
- [7] L.E. et al, C. Jimenez, M.E. Cabanillas, L. Santarpia, E. Jonasch, K.L. Kyle, Use of the tyrosine kinase inhibitor sunitinib in a patient with von Hippel-Lindau disease: targeting angiogenic factors in pheochromocytoma and other von Hippel-Lindau disease-related tumors, *J. Clin. Endocrinol. Metab.* 94 (2009) 386–391.
- [8] G. Eisenhofer, J.W.M. Lenders, G. Siegert, S.R. Bornstein, P. Friberg, D. Milosevic, M. Mannelli, W.M. Linehan, K. Adams, H.J. Timmers, K. Pacak, Plasma methoxytyramine: a novel biomarker of metastatic pheochromocytoma and paraganglioma in relation to established risk factors of tumour size, location and SDHB mutation status, *Eur. J. Cancer* 48 (2012) 1739–1749, <http://dx.doi.org/10.1016/j.ejca.2011.07.016>.
- [9] E. Baudin, M.A. Habra, F. Deschamps, G. Cote, F. Dumont, M. Cabanillas, J. Arfi-Roufe, A. Berdelou, B. Moon, A. Al Ghuzlan, S. Patel, S. Lebouilleux, C. Jimenez, Therapy of endocrine disease: treatment of malignant pheochromocytoma and paraganglioma, *Eur. J. Endocrinol.* 171 (2014) R111–R122, <http://dx.doi.org/10.1530/EJE-14-0113>.

- [10] H.J.L.M. Timmers, C.C. Chen, J.A. Carrasquillo, M. Whatley, A. Ling, G. Eisenhofer, K.S. King, J.U. Rao, R.A. Wesley, K.T. Adams, K. Pacak, Staging and functional characterization of pheochromocytoma and paraganglioma by 18F-fluorodeoxyglucose (18F-FDG) positron emission tomography, *J. Natl. Cancer Inst.* 104 (2012) 700–708, <http://dx.doi.org/10.1093/jnci/djs188>.
- [11] M. Mlika, N. Kourda, M.M. Zorgati, S. Bahri, S. Ben Ammar, R. Zermani, Prognostic value of Pheochromocytoma of the Adrenal Gland Scaled Score (Pass score) tests to separate benign from malignant neoplasms, *Tunis. Med.* 91 (2013) 209–215.
- [12] J. Hadoux, J. Favier, J.Y. Scoazec, S. Leboulleux, A. Al Ghuzlan, C. Caramella, D. Deandreis, I. Borget, C. Lorient, C. Chougnet, E. Letouze, J. Young, L. Amar, J. Bertherat, R. Libe, F. Dumont, F. Deschamps, M. Schlumberger, A.P. Gimenez-Roqueplo, E. Baudin, SDHB mutations are associated with response to temozolomide in patients with metastatic pheochromocytoma or paraganglioma, *Int. J. Cancer* 135 (2014) 2711–2720, <http://dx.doi.org/10.1002/ijc.28913>.
- [13] M.G. Heavner, L.S. Krane, S.M. Winters, M. Mirzazadeh, Pheochromocytoma diagnosed pathologically with previous negative serum markers, *J. Surg. Oncol.* 112 (2015) 492–495, <http://dx.doi.org/10.1002/jso.24031>.
- [14] R.A. Agha, A.J. Fowler, A. Saeta, I. Barai, S. Rajmohan, D.P. Orgill, The SCARE statement: consensus-based surgical case report guidelines, *Int. J. Surg.* (2016).

Open Access

This article is published Open Access at sciendo.com. It is distributed under the [IJSCR Supplemental terms and conditions](#), which permits unrestricted non commercial use, distribution, and reproduction in any medium, provided the original authors and source are credited.