

# Spontaneous iliac artery dissection treated with a combination of covered and self-expandable stents to preserve hypogastric patency

Giovanni Spinella, MD, Bianca Pane, MD, Maria Cecilia Perfumo, MD, and Domenico Palombo, MD, *Genoa, Italy*

A 56-year-old man presented with abdominal pain in the left lower quadrant. Computed tomography angiography showed the presence of an iliac axis dissection.

Two Viabahn (W. L. Gore & Associates, Flagstaff, Ariz) covered stents were placed, starting from the beginning of the left common iliac artery to the iliac bifurcation, closing the proximal dissection tear in the left common iliac artery. A self-expandable EverFlex stent (EV3-Covidien, Plymouth, Minn) was then placed, bridging the covered stent and the left external iliac artery, covering the re-entry tear.

There were no postoperative complications. During follow-up, we observed a progressive and complete thrombosis of the false lumen in 12 months. (*J Vasc Surg Cases* 2016;2:14-7.)

Spontaneous iliac artery dissection (IAD) is a rare pathologic process.<sup>1</sup> Only a few cases are reported in the literature. Rupture is the most frequent complication, occurring especially in the case of a collagen disorder, and it might be fatal.<sup>2</sup>

Treatment options may be medical therapy, open repair, or endovascular treatment. Open repair is reserved for the most urgent cases, in which there has been aneurysm rupture. Endovascular treatment or conservative management with medical therapy might be the most suitable choice in elective cases.<sup>3-7</sup>

We report a case of idiopathic symptomatic IAD treated with endovascular repair. The patient signed informed consent that allowed treatment and publication of personal and clinical data, following the principles outlined in the Declaration of Helsinki. We obtained our Institutional Review Board approval for the publication of data.

## CASE REPORT

A 56-year-old man presented to our hospital with abdominal pain in the left lower quadrant. Blood pressure was 190/110 mm Hg, and he was not taking antihypertensive drugs. Computed tomography (CT) angiography showed the presence of an IAD. In

particular, a proximal entry tear was found in the common iliac artery, and the distal re-entry tear was at the origin of the proximal external iliac artery (Fig 1). The hypogastric artery and external iliac artery were patent. There were neither clinical nor CT signs of reduced left limb perfusion. Common iliac artery diameter (true and false lumen) was 2 cm.

The patient was in good general condition and had no comorbidities. No personal or family history of collagen disease was reported. No clinical sign of Marfan syndrome or other similar disease was evident. The patient had no history of vascular procedures or surgeries. Blood pressure was stabilized with beta blockers and nitrates.

Preoperative endovascular planning showed common iliac artery proximal diameter of 9 mm, proximal neck length of 10 mm (proximal iliac artery), and common iliac artery length of 66 mm. External iliac artery diameter was 8 mm.

The patient underwent surgery 2 days after presentation, once blood pressure stabilization was achieved; he was treated under general anesthesia. The left common femoral artery was surgically exposed, and a 7F introducer was positioned. Another 7F introducer was positioned percutaneously in the right common femoral artery, and systemic heparinization was performed.

A 7F catheter for image acquisition was inserted from the right access up to the abdominal aorta at the level of the iliac bifurcation. A road map of the left iliac axis was taken. The road map was used to place a Bern 5F catheter through the true lumen in the abdominal aorta, using a Terumo 0.035-inch guidewire.

The Terumo guidewire was then replaced with a stiff 0.035-inch Supra Core guidewire (Abbott Vascular, Abbott Park, Ill), and the 7F introducer was replaced with a 10F introducer. Two Viabahn (10 × 50 mm; 11 × 50 mm; W. L. Gore & Associates, Flagstaff, Ariz) covered stents were placed, starting from the beginning of the left common iliac artery to the iliac bifurcation, closing the proximal dissection tear in the left common iliac artery. A self-expandable EverFlex stent (9 × 80 mm; EV3-Covidien, Plymouth, Minn) was then placed, bridging the covered stent and the left external iliac artery, covering the re-entry tear. The stents were not ballooned.

From the Vascular and Endovascular Surgery Unit, University Hospital IRCCS San Martino-IST, University of Genoa.

Author conflict of interest: none.

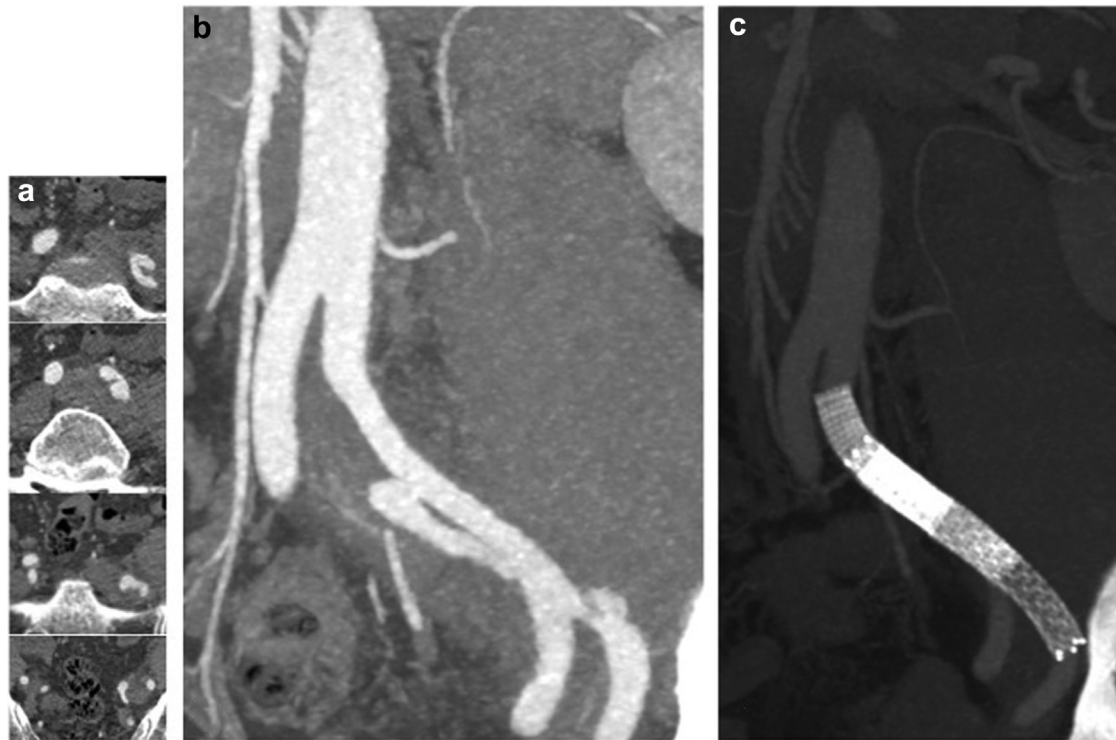
Correspondence: Giovanni Spinella, MD, Vascular and Endovascular Surgery Unit, University Hospital IRCCS San Martino-IST, Largo Rosanna Benzi, 10, 16132 Genoa, Italy (e-mail: [spinella.giovannis@gmail.com](mailto:spinella.giovannis@gmail.com)).

The editors and reviewers of this article have no relevant financial relationships to disclose per the Journal policy that requires reviewers to decline review of any manuscript for which they may have a conflict of interest.

2352-667X

Copyright © 2016 The Authors. Published by Elsevier Inc. on behalf of the Society for Vascular Surgery. This is an open access article under the CC BY-NC-ND license (<http://creativecommons.org/licenses/by-nc-nd/4.0/>).

<http://dx.doi.org/10.1016/j.jvsc.2016.02.003>



**Fig 1.** a and b, Preoperative computed tomography (CT) angiography showing iliac axis dissection. c, Postoperative CT angiography (12 months of follow-up) showing complete false lumen thrombosis, patency of hypogastric and external iliac arteries, and covered and uncovered stents.

Control angiography showed patency of the common, hypogastric, and external left iliac arteries. Moreover, it showed closure of the proximal dissection tear; the false lumen was supplied only by the distal re-entry tear.

After treatment, abdominal pain subsided. There were no postoperative complications, and the patient was discharged 4 days after surgery, with double antiplatelet therapy (clopidogrel, 75 mg/d; and acetylsalicylic acid, 100 mg/d) and antihypertensive therapy (atenolol, 100 mg/d; and angiotensin-converting enzyme inhibitor, 2.5 mg/d).

Follow-up was performed by CT angiography at 1 month and 12 months after treatment. During follow-up, a progressive thrombosis of the false lumen was observed, and it went to complete obliteration of the false lumen in 12 months. The common, external, and hypogastric arteries remained patent (Fig 2).

## DISCUSSION

According to our research of the literature, this is the second case report related to idiopathic IAD. Other causes of IAD in the literature are Marfan syndrome, pregnancy, fibromuscular dysplasia,  $\alpha_1$ -antitrypsin deficiency, athletic training, trauma, and atherosclerosis.<sup>8-14</sup>

The indication for treatment of spontaneous, idiopathic iliac dissection is not yet clear because it is a rare disease. Cases complicated by rupture should be treated on an emergency basis. To date, the most common treatment in these cases is open surgery. In case of symptoms

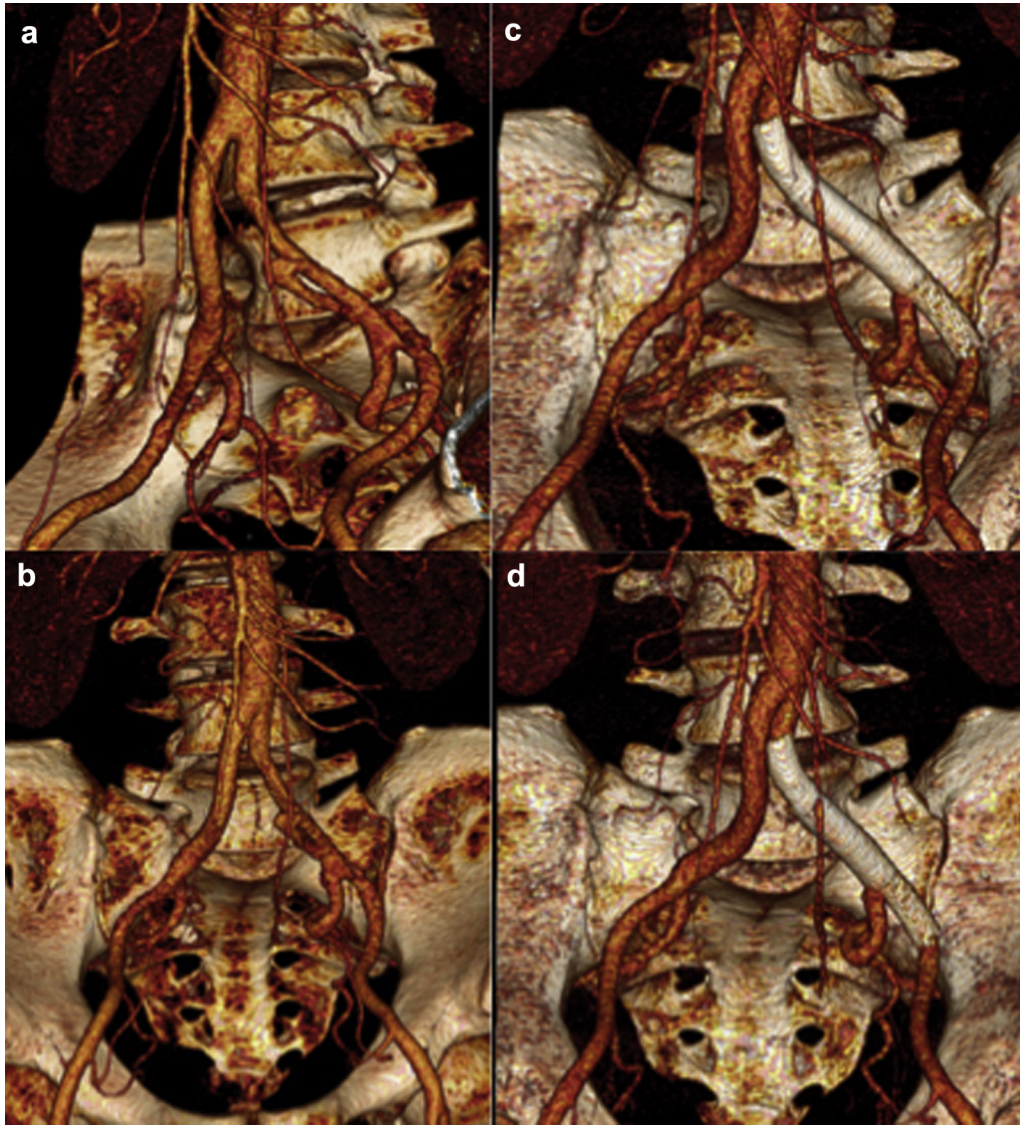
(mainly pain) without evidence of rupture, endovascular treatment, if feasible, may be considered.<sup>3-7</sup>

In this case, the patient was symptomatic but not ruptured, and after evaluation of feasibility, endovascular treatment was chosen. The IAD was treated with both covered and uncovered stents. It was elected to handle this case as if it were an aortic type B dissection. The goal of endovascular treatment was to exclude the false lumen by closing the proximal entry tear. A treatment option similar to the PETTICOAT technique (Provisional ExTension to Induce Complete ATtachment) was used, but a self-expandable nitinol stent was chosen to allow better compliance with the iliac axis morphology.<sup>15</sup>

The aim of treatment in this case was both to obtain thrombosis of the false lumen and to maintain the distal and hypogastric artery perfusion. Endovascular treatment in IAD has already been discussed by Kwak et al; the authors reported two iliac axis dissections, treated by positioning of a self-expandable stent. Follow-up showed good results.<sup>16</sup>

Recently, Yoshida et al reported a total endovascular treatment of common IAD, using two covered stents, to preserve pelvic circulation. The authors deployed the covered stents in the common iliac artery and external iliac artery. The origin of the hypogastric artery was not covered.<sup>17</sup>

In this case, the choice was to place a covered stent to close the tear in the proximal common iliac artery and to



**Fig 2.** Preoperative volume rendering anteroposterior (a) and lateral (b) projections show left iliac axis dissection. Postoperative volume rendering anteroposterior (c) and lateral (d) projections show complete false lumen thrombosis, patency of hypogastric and external iliac arteries, and covered and uncovered stents.

use an uncovered stent between the covered stent and the external iliac artery. This choice was made because the preoperative CT angiogram showed that the distal re-entry tear was very close to the origin of the hypogastric artery; therefore, the use of a covered stent could cause occlusion of the hypogastric artery.

To prevent ischemic complications, at least one hypogastric artery should be preserved during any endovascular treatment.<sup>18</sup> In young patients, especially with idiopathic IAD, it is our opinion that if possible, it would be better to preserve hypogastric artery patency because the contralateral iliac artery could be affected by other vascular diseases (aneurysms, stenosis) with the aging process.

The outcome of endovascular treatment during follow-up was satisfying, and a substantial shrinking of the false lumen was observed.

Whereas it is not advisable to use endovascular devices in IAD caused by collagen disease, there apparently is no contraindication to endovascular treatment in idiopathic IAD.<sup>19</sup>

## CONCLUSIONS

Endovascular treatment of IAD could be a viable treatment option, especially if it is performed electively and in idiopathic dissection. Because endovascular treatment can preserve the patency of the hypogastric artery, it might be considered whenever possible.

## REFERENCES

1. Dueppers P, Jankowiak S, Schelzig H, Wagenhäuser MU, Oberhuber A. Spontaneous rupture of an isolated iliac artery dissection in a young man because of cystic medial degeneration Erdheim-Gsell. *Ann Vasc Surg* 2015;29:596.e11-3.
2. Honjo O, Yamada Y, Kuroko Y, Kushida Y, Une D, Hioki K. Spontaneous dissection and rupture of common iliac artery in a patient with fibromuscular dysplasia: a case report and review of the literature on iliac artery dissections secondary to fibromuscular dysplasia. *J Vasc Surg* 2004;40:1032-6.
3. Engin C, Calkavur T, Apaydin AZ, Durmaz I. Bilateral spontaneous and isolated dissection of the external iliac arteries: report of a case. *EJVES Extra* 2005;9:19-21.
4. Thevenet A, Latil JL, Albat B. Fibromuscular disease of the external iliac artery. *Ann Vasc Surg* 1992;6:199-204.
5. Cook PS, Eroses LS, Selzer PM, Rivera FJ, Palmaz JC. Dissection of the external iliac artery in highly trained athletes. *J Vasc Surg* 1995;22:173-7.
6. Molkara AM, Abou-Zamzam AM, Teruya TH, Bianchi C, Killeen JD. Chronic ergot toxicity presenting with bilateral external iliac artery dissection and lower extremity rest pain. *Ann Vasc Surg* 2006;20:803-8.
7. Fukui S, Chelbi E, Paraskevas N, Soury P, Gigou F, Petit MD, et al. Bilateral dissection of external iliac artery. *Ann Vasc Surg* 2007;21:373-5.
8. Lyden SP, Srivastava SD, Waldman DL, Green RM. Common iliac artery dissection after blunt trauma: case report of endovascular repair and literature review. *J Trauma* 2001;50:339-42.
9. Teh LG, Sieunarine K, Van Schie G, Vasudevan T. Spontaneous common iliac artery dissection after exercise. *J Endovasc Ther* 2003;10:163-6.
10. Nolte JE, Rutherford RB, Nawaz S, Rosenberger A, Speers WC, Krupski WC. Arterial dissections associated with pregnancy. *J Vasc Surg* 1995;21:515-20.
11. Cattani S, Mariette X, Labrousse F, Brouet JC. Iliac artery dissection in  $\alpha_1$ -antitrypsin deficiency. *Lancet* 1994;343:1371-2.
12. Mounier-Vehier C, Millaire A, Vrtovnik F, Marache P, Ducloux G. [Dissecting aneurysm of the left iliac artery disclosing Marfan's disease]. *Ann Cardiol Angeiol (Paris)* 1991;40:537-40.
13. Willson TD, Revesz E, Podbielski FJ, Blecha MJ. External iliac artery dissection secondary to endofibrosis in a cyclist. *J Vasc Surg* 2010;52:219-21.
14. Abayazeed A, Hayman E, Moghadamfalahi M, Cain D. Vascular type Ehlers-Danlos syndrome with fatal spontaneous rupture of a right common iliac artery dissection: case report and review of literature. *J Radiol Case Rep* 2014;8:63-9.
15. Melissano G, Bertoglio L, Rinaldi E, Civilini E, Tshomba Y, Kahlberg A, et al. Volume changes in aortic true and false lumen after the "PETTICOAT" procedure for type B aortic dissection. *J Vasc Surg* 2012;55:641-51.
16. Kwak HS, Han YM, Chung GH, Yu HC, Jeong YJ. Isolated spontaneous dissection of the common iliac artery: percutaneous stent placement in two patients. *Cardiovasc Intervent Radiol* 2006;29:883-5.
17. Yoshida Rde A, Kolvenbach R, Vieira PR, Moura R, Jaldin RG, Yoshida WB. Endovascular treatment of spontaneous isolated common and external iliac artery dissections with preservation of pelvic blood flow. *Ann Vasc Surg* 2015;29:126.e9-14.
18. Peter H, Aaron YC, Alok V. Hypogastric artery preservation during endovascular aortic aneurysm repair: is it important? *Semin Vasc Surg* 2009;22:193-200.
19. Akin I, Kische S, Rehders TC, Chatterjee T, Schneider H, Körber T, et al. Current role of endovascular therapy in Marfan patients with previous aortic surgery. *Vasc Health Risk Manag* 2008;4:59-66.

Submitted Sep 27, 2015; accepted Feb 2, 2016.