

Myocardial Cell Transplantation

Catheter-Based Autologous Bone Marrow Myocardial Injection in No-Option Patients With Advanced Coronary Artery Disease

A Feasibility Study

Shmuel Fuchs, MD,* Lowell F. Satler, MD,* Ran Kornowski, MD,† Petros Okubagzi, MD,* Giora Weisz, MD,‡ Richard Baffour, MD,* Ron Waksman, MD,* Neil J. Weissman, MD,* Manuel Cerqueira, MD,* Martin B. Leon, MD,‡ Stephen E. Epstein, MD*

Washington, DC; Petach-Tikva, Israel; and New York, New York

OBJECTIVES	We conducted a pilot study to evaluate the feasibility of transendocardial delivery of autologous bone marrow (ABM) strategy in patients with severe symptomatic chronic myocardial ischemia not amenable to conventional revascularization.
BACKGROUND	Transendocardial injection of ABM cells appears to enhance perfusion of ischemic porcine myocardium.
METHODS	Ten patients underwent transendocardial injection of freshly aspirated and filtered unfractionated ABM using left ventricular electromechanical guidance. Twelve injections of 0.2 ml each were successfully delivered into ischemic noninfarcted myocardium pre-identified by single-photon emission computed tomography perfusion imaging.
RESULTS	Autologous bone marrow injection was successful in all patients and was associated with no serious adverse effects; in particular, there was no arrhythmia, evidence of infection, myocardial inflammation, or increased scar formation. Two patients were readmitted for recurrent chest pain. At three months, Canadian Cardiovascular Society angina score significantly improved (3.1 ± 0.3 vs. 2.0 ± 0.94 , $p = 0.001$), as well as stress-induced ischemia occurring within the injected territories (2.1 ± 0.8 vs. 1.6 ± 0.8 , $p < 0.001$). Treadmill exercise duration, available in nine patients, increased, but the change was not significant (391 ± 155 vs. 485 ± 198 , $p = 0.11$).
CONCLUSIONS	This study provides preliminary clinical data indicating feasibility of catheter-based transendocardial delivery of ABM to ischemic myocardium. (J Am Coll Cardiol 2003;41:1721-4) © 2003 by the American College of Cardiology Foundation

Despite multiple clinical studies, efficacy of various angiogenesis strategies to improve myocardial perfusion remains unproven (1,2). Previous efforts, however, involved delivery of a *single* angiogenesis factor. Given the complexity of natural angiogenesis processes, such a strategy might provide a suboptimal stimulus to collateral development. Therefore, we tested a cell-based strategy, based on the hypothesis that the cells secrete, in a time- and concentration-appropriate manner, *multiple* angiogenesis factors needed for optimal collateral development.

Preclinical studies demonstrated that administration of autologous bone marrow (ABM)-derived cells to ischemic porcine myocardium is safe and appears to improve collateral flow (3,4). The present phase I pilot study was designed

to examine the feasibility of percutaneous transendocardial injection of unfractionated ABM in patients with advanced coronary artery disease.

METHODS

Patient selection. Patients were eligible for the study if they had Canadian Cardiovascular Society (CCS) angina class III to IV despite best tolerated medical therapy, no conventional revascularization treatment option, reversible myocardial ischemia on single-photon emission computed tomography imaging, and at least one major epicardial vascular conduit with $>70\%$ and one with $<70\%$ diameter stenosis. Exclusion criteria included abnormal hemoglobin, platelets, or leukocyte count; conditions that may adversely affect bone marrow (BM) (such as malignancy or human immunodeficiency virus infection), ejection fraction (EF) $<30\%$, and recent (<1 month) myocardial infarction or class III unstable angina. The study was approved by the local Institutional Review Board of each of the sites and the U.S. Food and Drug Administration. Informed consent was obtained from all patients before enrollment.

BM. Bone marrow was aspirated from the iliac crest, mixed with heparin (20 U per ml of BM), and filtered as previously

From the *Cardiovascular Research Institute, MedStar Research Institute, Washington Hospital Center, Washington, DC; †Rabin Medical Center, Petach-Tikva, Israel; and the ‡Cardiovascular Research Foundation, Lenox Hill Hospital, New York, New York. This research was supported by grants from the Cardiovascular Research Institute, Washington, DC; Cardiovascular Research Foundation, New York, New York; and MediVas LLC, San Diego, California. Drs. Fuchs, Kornowski, Leon, and Epstein are minor shareholders in a startup company dedicated to the field of cell therapy for angiogenesis. They also have a pending patent for intramyocardial injection of autologous bone marrow.

Manuscript received October 21, 2002; revised manuscript received February 5, 2003, accepted February 13, 2003.

Abbreviations and Acronyms

ABM	= autologous bone marrow
BM	= bone marrow
CCS	= Canadian Cardiovascular Society
CK	= creatine kinase
EF	= ejection fraction
HUVECs	= human umbilical endothelial cells
LV	= left ventricle/ventricular
MCP-1	= macrophage chemoattractant protein-1
SPECT	= single-photon emission computed tomography
VEGF	= vascular endothelial growth factor

described (4). Filtered BM was assessed morphologically and tested for viability (TriPan Blue staining), absence of clots, bone spicules, and gross bacterial contamination.

Bone marrow cell population was analyzed by fluorescence-activated cell sorting using anti-CD34, anti-CD45, anti-CD117, anti-CD3, anti-CD4, anti-CD8, and anti-CD41 antibodies (Becton Dickinson, Burlingame, California).

Assessment of BM-derived angiogenic growth factors.

Freshly aspirated and filtered BM cells of nine patients were cultured for four weeks, and levels of vascular endothelial growth factor (VEGF) and macrophage chemoattractant protein-1 (MCP-1) in the conditioned medium were measured separately for each of the samples as previously described (4). The effect of conditioned medium on human umbilical endothelial cell (HUVEC) proliferation was also measured by direct counting (4).

BM injection. Left ventricular (LV) electromechanical mapping and injection procedures (Biosense, Johnson and Johnson, Warren, New Jersey) have been described (5,6). Upon completion of LV mapping, 12 injections of 0.2 ml of BM each (total 2.4 ml) were delivered into a predefined myocardial ischemic territory (SPECT data) approximately 1 cm apart. We avoided injecting into the LV apex or mitral valve area (Fig. 1).

Perfusion and function. All tests were assessed at baseline and at three-month follow-up. Myocardial perfusion was assessed by dual isotope SPECT imaging using thallium-201 for rest and technetium-99-sestamibi for adenosine-stress imaging. A semiquantitative (score 0 to 4) 17-segment model was used for analysis (7). Reversible ischemia was defined per segment as stress-rest score ≥ 1 . Transthoracic echocardiography was used to assess global LV function and regional wall motion (score 1 to 4) using identical segmentation. Images were interpreted by core laboratories blind to injection location, study sequence, and patient clinical status. Change in perfusion was determined by grouping and averaging stress score of all segments with evidence of reversible ischemia at baseline lying within the entire area of distribution of each coronary artery, whether or not a given segment was injected. Exercise capacity was assessed using a modified Beth-Israel/Bruce treadmill protocol.

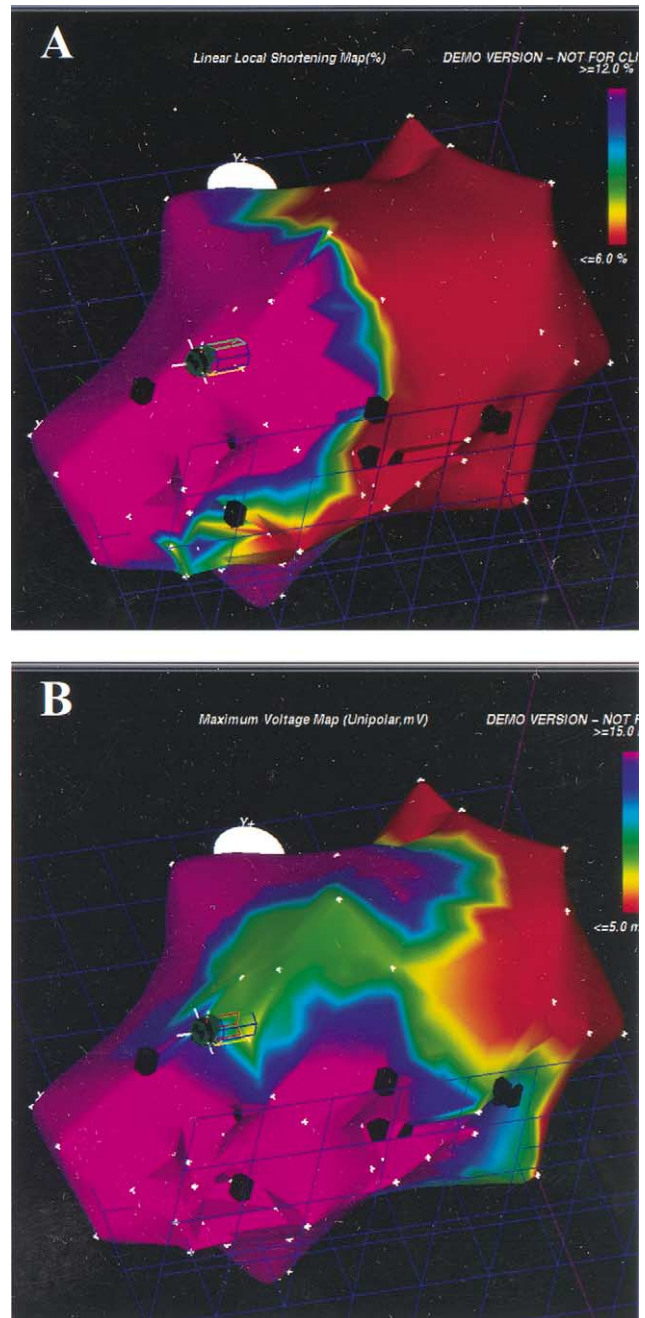


Figure 1. Left ventricular electromechanical maps (left oblique, bottom view projection) after 12 intramyocardial injections of autologous bone marrow. Injections were delivered into an ischemic right coronary artery territory. Local shortening (A) and unipolar voltage (B) amplitudes are color-coded and the exact location of each of the injection sites is tagged on the maps in real-time (black tags).

Patient follow-up. Echocardiography was performed within 2 h postprocedure. Serial blood samples for creatine kinase (CK)-MB were drawn and 12-lead electrocardiograms were acquired over 24 h postprocedure. Follow-up included CK-MB, complete blood count, physical examination, and event assessment. Bone marrow cultures for bacteria and fungi were followed for one month. Changes from baseline to three months in CCS angina class and

Table 1. Baseline Demographics and Clinical Data

Characteristics	Mean \pm SD or n (%)
Mean age (yrs)	55 \pm 7
Male gender	7 (70)
Angina class III	9 (90)
Angina class IV	1 (10)
Systemic hypertension	6 (60)
Diabetes mellitus	5 (50)
Insulin-dependent	1 (10)
Non-insulin-dependent	4 (40)
Hyperlipidemia	9 (90)
Smoking	8 (80)
Ejection fraction (%)	47 \pm 10
Prior myocardial infarction	8 (80)
Prior bypass surgery	9 (90)
Prior PCI	10 (100)
Premature coronary artery disease	4 (40)
Nitrates	8 (80)
Beta-blockers	9 (90)
Calcium antagonists	6 (60)
Aspirin	10 (100)
Plavix	5 (50)
HMG-CoA reductase inhibitors	9 (90)

HMG-CoA = hydroxymethylglutaryl coenzyme A; PCI = percutaneous coronary intervention.

quality of life assessed by the Seattle Angina Questionnaire (8) were measured.

Statistical analysis. Data are presented as mean \pm SD. Quantitative data were compared using paired, two-tailed Student *t* test. Qualitative (categorical) data, presented as frequencies, were compared using chi-square statistics. Repeated measure of variance was used to compare the concentration of VEGF and MCP-1 in the BM-conditioned medium collected at weeks 1, 2, 3, and 4. One-way analysis of variance was used to compare the effects of conditioned medium on HUVECs proliferation. A value of $p < 0.05$ was considered significant.

RESULTS

Patients. Baseline demographics and clinical data of the patients are summarized in Table 1.

BM. Cell viability was $\geq 95\%$ in all patients. The filtered BM had no clots or bone spicules, had normal morphology, and stained negative for bacteria. The BM aspiration and processing time was approximated 2.5 h.

The injected BM contained $32.6 \pm 27.5 \times 10^6$ /ml nucleated cells with the following cell fraction: polymorphonuclear cells $74.6 \pm 6.5\%$, lymphocytes $19.3 \pm 8.1\%$, monocytes $3.5 \pm 1.0\%$, and megakaryocytes $2.6 \pm 2.3\%$. The CD34+ fraction was $2.6 \pm 1.6\%$, of which $47.9 \pm 15.1\%$ co-expressed CD45. Among the double positive (CD45/CD34), $85 \pm 14\%$ co-expressed the stem cell factor receptor CD117 (c-kit).

Secretion of angiogenic growth factors by human BM cells. Over a four-week period VEGF and MCP-1 levels in the conditioned medium increased gradually from 0 to $6,472 \pm 2,448$ ng/ml ($p < 0.001$) and $2,094 \pm 293$ ng/ml

($p < 0.001$), respectively. The BM conditioned medium collected at four weeks increased, in a dose-related manner (10, 50, and 100 μ l), proliferation of HUVECs by 25%, 50%, and 100% compared with controls ($p < 0.001$).

Procedural data. All patients were successfully injected with 12 injections. Left ventricular mapping and injection were associated with induction of ventricular premature beats, but no sustained ventricular or other arrhythmia occurred, and no significant changes were noted in blood pressure and heart rate.

Average mapping and BM injection procedure time was 30 ± 13 min and 28 ± 9 min, respectively. Overall, 45 segments were injected with an average of 4.5 ± 1.1 injections per segment with a mean distance of 12 ± 2 mm between injection points.

Clinical outcomes. There were no deaths, myocardial infarction, pericardial effusion, revascularization procedures, or stroke. None of the patients experienced endocarditis, myocarditis, or systemic infection, and all BM cultures were negative for bacteria and fungi. In-hospital peak CK-MB was within normal range in five patients and mildly elevated (1.1 to 1.9 times upper normal) in the remaining. Troponin I, available in eight patients, ranged between 0.16 and 0.62 ng/ml (infarction cutoff >0.8 ng/ml). All patients but one were discharged within 24 h of the procedure. In this patient a difficulty in advancing the mapping catheter was noted; the procedure was completed successfully via the other groin. Postprocedure magnetic resonance imaging revealed confined thoracic-abdominal dissection. The patient was followed conservatively and was discharged after three days. Three patients were readmitted to the hospital: one for atypical and two for typical chest pains not associated with electrocardiographic changes or myocardial enzyme elevation.

At three months, angina symptoms improved in eight patients and did not change in two patients, (CCS angina class 3.1 ± 0.3 vs. 2.0 ± 0.94 , $p = 0.001$). Similar improvement was noted in angina stability score (15.6 ± 22.9 vs. 62.5 ± 32.7 , $p = 0.002$), angina frequency (21.3 ± 27.0 vs. 32.5 ± 24.3 $p = 0.03$), and quality of life (26.0 ± 17.5 vs. 46.9 ± 23.1 , $p = 0.01$).

Myocardial perfusion and function. At baseline, a total of 62 segments had reversible ischemia: 52 within territories subsequently injected (left anterior descending artery territory = 19, left circumflex artery = 23, and right coronary artery = 10) and 10 within noninjected (remote) territories. Stress score improved in segments within the injected but not within remote territories (Fig. 2), whereas rest score of these segments remained unchanged (0.25 ± 0.56 vs. 0.23 ± 0.47 , $p = 0.85$). There was no change in EF ($47 \pm 10\%$ vs. $52 \pm 6\%$, $p = 0.24$). The majority of segments within the injected territories ($n = 91$, 80%) had normal baseline wall motion score, and none showed deterioration; among segments with abnormal baseline score, 2 improved and 21 showed no change. Exercise duration time, in the nine

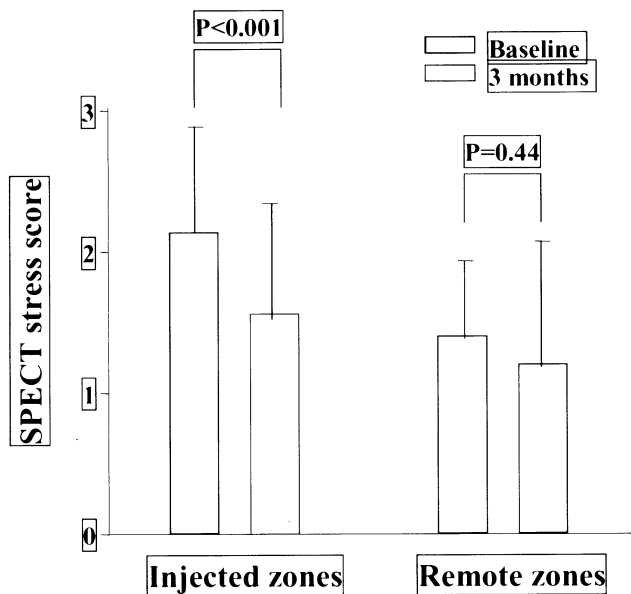


Figure 2. Semiquantitative stress scores of segments with baseline reversible ischemia within injected and remote coronary artery territories. SPECT = single-photon emission computed tomography.

patients undergoing this evaluation, increased from 391 ± 155 to 485 ± 198 ($p = 0.11$).

DISCUSSION

The current study is the first to assess the feasibility and potential safety of stand-alone transcatheter delivery of unfractionated ABM cells in patients with advanced coronary artery disease. Autologous bone marrow injection was associated with no serious adverse effects; in particular, there was no arrhythmia, evidence of infection, myocardial inflammation, or increased fibrosis. The study also suggests potential efficacy. However, it must be emphasized that no definitive safety- or efficacy-related conclusions can be drawn given the small number of patients and the study design.

We employed the ABM strategy because the BM contains diverse cells capable of secreting numerous cytokines and chemokines (3,4) as well as various progenitor and stem cells. The activity of these cells could potentially induce deleterious myocardial effects. We observed, however, no evidence of myocarditis and no adverse effect on regional myocardial perfusion or function. These results are in accord with our porcine study (4), and with a preliminary report of transepical injection of BM-derived mononuclear cells as an adjunct to bypass grafting surgery (9).

The magnitude of clinical improvement observed in the current study is in accord with previous trials of therapeutic angiogenesis (1,10). However, the variable outcome of angina symptoms among these patients, including spontaneous improvement, underscores the need for a large cohort-study to control for time-dependent natural variability and potentially important placebo effect.

The perfusion improvement we observed was in stress,

but not in rest perfusion. This is in accord with a recent study employing transcatheter (6) delivery of VEGF, but not with a study employing intracoronary delivery of VEGF (11). The improvement we measured, however, may be fortuitous and due to the relatively small number of patients studied or to natural biologic variability in myocardial blood flow, rather than to treatment effect.

In conclusion, transcatheter administration of freshly aspirated ABM is potentially feasible. The results do not prove efficacy. We believe, however, that they do warrant larger controlled blinded studies, and should stimulate further investigational efforts to optimize this cell-based approach to enhancing collateral flow.

Reprint requests and correspondence: Dr. Shmuel Fuchs, Cardiovascular Research Institute, Washington Hospital Center, 110 Irving Street NW, 4B-1, Washington, DC 20010. E-mail: sfuchsel2002@yahoo.com.

REFERENCES

- Grines CL, Watkins MW, Helmer G, et al. Angiogenic Gene Therapy (AGENT) trial in patients with stable angina pectoris. *Circulation* 2002;105:1291-7.
- Simons M, Annex BH, Laham RJ, et al. Pharmacological treatment of coronary artery disease with recombinant fibroblast growth factor-2: double-blind, randomized, controlled clinical trial. *Circulation* 2002; 105:788-93.
- Kamihata H, Matsubara H, Nishiue T, et al. Implantation of bone marrow mononuclear cells into ischemic myocardium enhances collateral perfusion and regional function via side supply of angioblasts, angiogenic ligands, and cytokines. *Circulation* 2001;104:1046-52.
- Fuchs S, Baffour R, Zhou YF, et al. Transcatheter delivery of autologous bone marrow enhances collateral perfusion and regional function in pigs with chronic experimental myocardial ischemia. *J Am Coll Cardiol* 2001;37:1726-32.
- Kornowski R, Leon MB, Fuchs S, et al. Electromagnetic guidance for catheter-based transcatheter injection: a platform for intramyocardial angiogenesis therapy. Results in normal and ischemic porcine models. *J Am Coll Cardiol* 2000;35:1031-9.
- Losordo DW, Vale PR, Hendel RC, et al. Phase 1/2 placebo-controlled, double-blind, dose-escalating trial of myocardial vascular endothelial growth factor 2 gene transfer by catheter delivery in patients with chronic myocardial ischemia. *Circulation* 2002;105: 2012-8.
- Cerqueira MD, Weissman NJ, Dilsizian V, et al. Standardized myocardial segmentation and nomenclature for tomographic imaging of the heart: a statement for healthcare professionals from the Cardiac Imaging Committee of the Council on Clinical Cardiology of the American Heart Association. *Circulation* 2002;105:539-42.
- Spertus JA, Winder JA, Dewhurst TA, et al. Development and evaluation of the Seattle Angina Questionnaire: a new functional status measure for coronary artery disease. *J Am Coll Cardiol* 1995;25:333-41.
- Hamano K, Nishida M, Hirata K, et al. Local implantation of autologous bone marrow cells for therapeutic angiogenesis in patients with ischemic heart disease: clinical trial and preliminary results. *Jpn Circ J* 2001;65:845-7.
- Udelson JE, Dilsizian V, Laham RJ, et al. Therapeutic angiogenesis with recombinant fibroblast growth factor-2 improves stress and rest myocardial perfusion abnormalities in patients with severe symptomatic chronic coronary artery disease. *Circulation* 2000;102:1605-10.
- Hendel RC, Henry TD, Rocha-Singh K, Isner JM, et al. Effect of intracoronary recombinant human vascular endothelial growth factor on myocardial perfusion: evidence for a dose-dependent effect. *Circulation* 2000;101:118-21.