

available at <http://www.tzuchimedjnl.com/>

Tzu Chi Medical Journal



Pathology Page

## Anal Condyloma Acuminatum

Yung-Hsiang Hsu\*

Department of Pathology, Buddhist Tzu Chi General Hospital and Tzu Chi University, Hualien, Taiwan

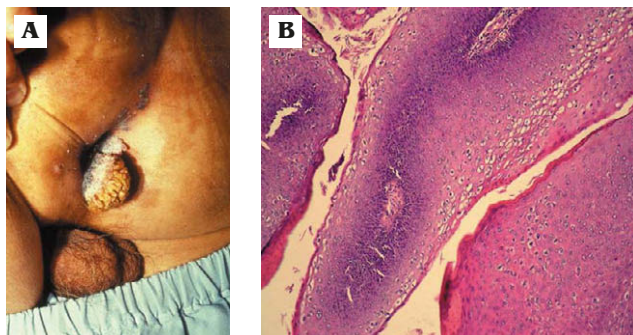
A 38-year-old man had an anal mass (Fig. 1A) for 3 months. Histopathology from a biopsy showed a papillary growth lesion with a fibrovascular core and characteristic formation of koilocytes (Fig. 1B) in the superficial area, diagnostic of condyloma acuminatum.

Condylomata acuminatum are sexually transmitted benign tumors that have a distinctly verrucous gross appearance, as in this patient. Although they may be solitary, they are more frequently multiple, often coalesce, and involve the perineal, vulvar and perianal

regions as well as the vagina and, less commonly, the cervix.

Histologically, they consist of a branching, tree-like proliferation of stratified squamous epithelium supported by fibrous stroma. Acanthosis, parakeratosis, hyperkeratosis and, most specifically, nuclear atypia in the surface cells with perinuclear vacuolation (called koilocytosis) are present.

Condylomata are caused by the human papillomavirus, specifically types 6 and 11. The virus life cycle is completed in the epithelium, specifically the mature superficial cells. Except in immunosuppressed individuals, condylomata acuminatum frequently regress spontaneously and are not considered to be precancerous lesions. (*Tzu Chi Med J* 2010;22(4):248)



**Fig. 1 — (A) A papillary growth lesion in the perianal area. (B) Histopathology shows fibrovascular stroma and koilocytosis in the superficial area (hematoxylin & eosin, 200×).**

### References

1. McCutcheon T. Anal condyloma acuminatum. *Gastroenterol Nurs* 2009;32:342–9.
2. Leddy MA, Anderson BL, Gall S, Schulkin J. Obstetrician–gynecologists and the HPV vaccine: practice patterns, beliefs, and knowledge. *J Pediatr Adolesc Gynecol* 2009; 22:239–46.
3. Hsueh PR. Human papillomavirus, genital warts, and vaccines. *J Microbiol Immunol Infect* 2009;42:101–6.
4. D’Ambrogio A, Yerly S, Sahli R, et al. Human papilloma virus type and recurrence rate after surgical clearance of anal condylomata acuminata. *Sex Transm Dis* 2009;36:536–40.

\*Corresponding author. Department of Pathology, Buddhist Tzu Chi General Hospital, 707, Section 3, Chung-Yang Road, Hualien, Taiwan.  
E-mail address: yhhsu@mail.tcu.edu.tw