




ELSEVIER

Contents lists available at ScienceDirect

Urology Case Reports

journal homepage: www.elsevier.com/locate/eucr

Oddities

A Case Report: Triorchidism; is a Rare Mistaken Cause for Extra Testicular Neoplasm



Ahmed H. Abduljabbar*

Department of Diagnostic Imaging, King Abdulaziz University Hospital, P.O. Box 80215, Jeddah 21589, Saudi Arabia

ARTICLE INFO

Article history:

Received 30 January 2015

Received in revised form

6 February 2015

Accepted 18 February 2015

Available online 14 March 2015

Keywords:

Triorchidism

Polyorchidism

Supernumerary testicle

A congenital testicular anomaly

ABSTRACT

Polyorchidism is a rare congenital anomaly of the male genitalia which refers to present an extra testicle; triorchidism is the commonest type. This report describes a case of 25-year-old male presented with testicular swelling and palpable scrotal mass, diagnosed as supernumerary testicle and tubular ectasia of the rete testis. The most common clinical presentation of triorchidism is painless swelling. Associated inguinal hernia or undescended testis is not uncommon findings. Treatment options will vary according to the type, size, number, anatomical location and vasculature.

© 2015 The Authors. Published by Elsevier Inc. This is an open access article under the CC BY-NC-ND license (<http://creativecommons.org/licenses/by-nc-nd/4.0/>).

Introduction

Polyorchidism is an uncommon pathology involving the genitourinary tract in which additional testicle is present. Less than 200 cases in the literature have been reported. The majority of the cases are clinically silent and detected incidentally with either scrotal or inguinal mass. The median age of presentation in 50% of the cases between 15 to 25 years of age.¹

Case report

A 25-year-old unmarried male patient presented to the outpatient clinic with a palpable mass in the left hemiscrotum. Physical examination revealed normal right testis and left non-tender rounded mass smaller than the normal appearing adjacent testicle, but it has a similar consistency. The mass has not changed in position with cough. There is no significant prior medical illness or history of trauma was given. Sonographic evaluation revealed two testicles on the left hemiscrotum with echotexture and vascularity similar to that of the right testicle, consistent with triorchidism (Fig. 1). MRI was performed to confirm the diagnosis of triorchidism and for better anatomical delineation. The superior left testicle measures 2.6 × 2.8 cm and demonstrates ectasia of the rete testis.

The inferior left testicle measures 2.5 × 1.6 cm. The testicles showed homogenous intermediate signal on T1-weighted images and high signal intensity on T2-weighted images (Figs. 2–3). There was no mass suspicious for malignancy. There is one apparent left vas deferens which bifurcate in the left scrotum to supply each testicle. It was difficult to confirm if 1 or 2 left epididymii is present. The right testicle is normal in size and morphology, measures 3.6 × 2.3 cm. Conservative management was determined. Plan is to continue physical examination and imaging surveillance.

Discussion

Polyorchidism is rare congenital anomaly defined as the presence of more than two testicles. Most commonly present in the scrotum (66%), inguinal canal (23%) or retroperitoneum (9%).² The etiology is still uncertain, but may be related to peritoneal folding, segmentation of the primitive gonads longitudinal or transverse division of the genital ridge.³ Functional classification system has been published by Leung based on embryologic development: type 1 supernumerary testis without epididymis and vas deference; type 2 supernumerary testis shared common epididymis and vas deference with ipsilateral testicle; type 3 supernumerary testis has its own epididymis but shares a common vas deferens with the ipsilateral testicle; type 4 there is complete duplication of testis, epididymis and vas.⁴ Associated anomalies with polyorchidism are testicular maldescent (40%), inguinal hernia (30%), testicular torsion (13%), hydrocele (9%), and hypospadias (1%).⁵ Most patients are

* Corresponding author. Tel.: +966 126408161, +966 562556664 (mobile); fax: +966 126408149.

E-mail address: dr_aj@hotmail.com.

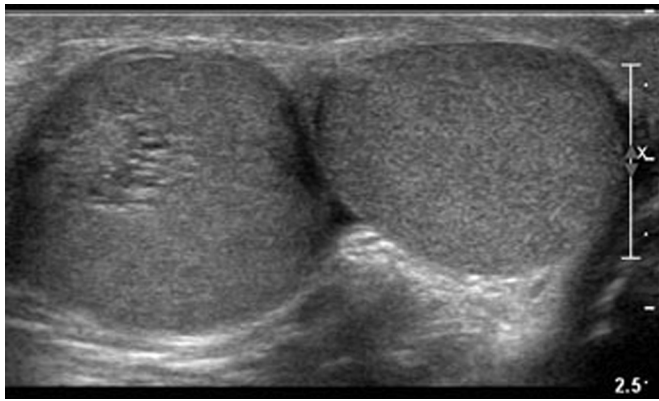


Figure 1. Sonogram of the scrotum demonstrate double testicles in the left hemiscrotum and tubular ectasia of the rete testis in superior testicle.

asymptomatic or present with painless scrotal mass. Testicular cancer is the most concerning cause of a painless scrotal mass. Although it is rare compared with other causes of extra testicular scrotal masses such as hydrocele, spermatocele, varicocele and less commonly polyorchidism. Therefore, further evaluation with imaging work-up is warranted to exclude underlying malignancy. The estimated increased risk of malignancy in supernumerary is about 6%, and the commonly encountered histological type include included seminoma, choriocarcinoma, and teratoma.⁵ Only non-scrotal location of supernumerary testis has shown an increased risk of malignancy. The management of supernumerary is varied between expectant observation and surgical removal depending on the fertility status and the location of the supernumerary testis. The benefits of preserving functioning supernumerary testis must be weighed against the increased risk of malignancy. Our patient is planning to have children in the future and the treatment plan was to continue on conservative management based on the patient's fertility purpose, presence of reproductive ability and the absence

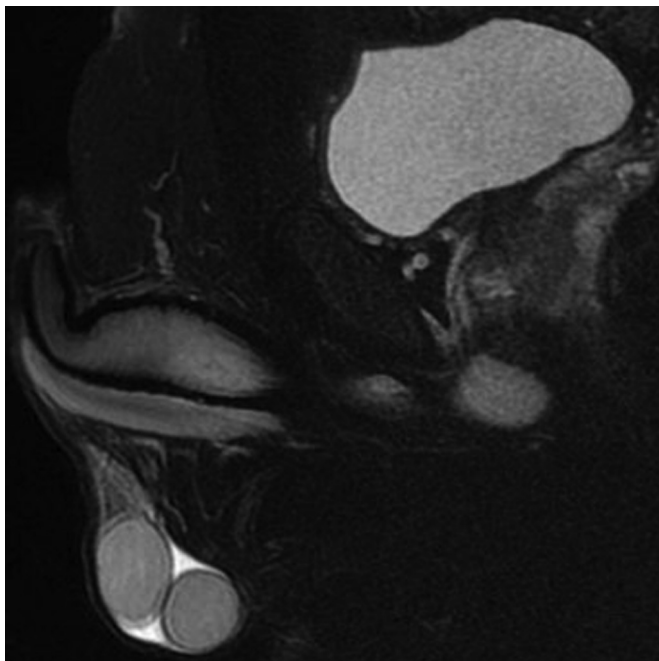


Figure 2. Sagittal MRI T2 FRFSE with fat saturation showing supernumerary testicle in the left side inferiorly, having the same MR imaging characteristics as the normal testes.

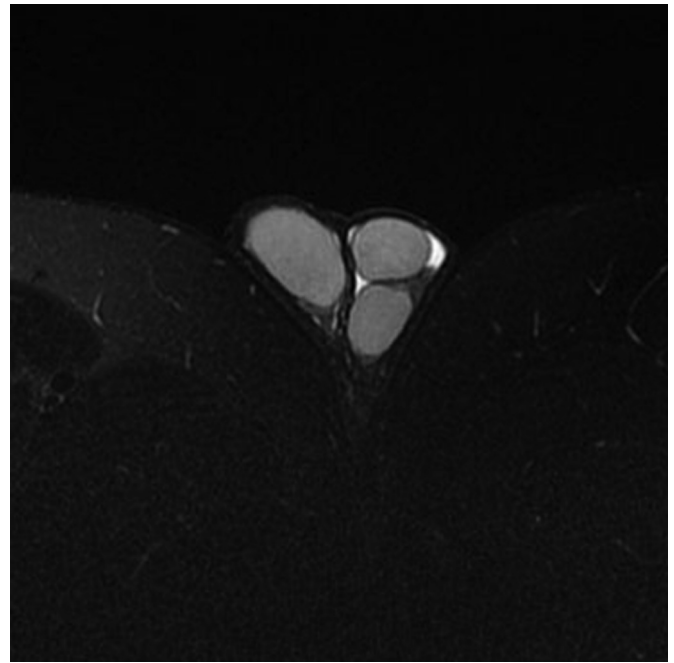


Figure 3. Axial MRI T2 FRFSE with fat saturation demonstrate three homogenous moderately high T2 signal intensity testicles inside the scrotal sac and confirm the diagnosis of triorchidism.

of malignancy. Functional classification has been suggested by Singer et al and have recommended excision of all non-functioning or ectopically located supernumerary testes. However, functioning intra-scrotal supernumerary tests is indicated for resection in the presence suspected malignancy on biopsy or imaging. Absent reproductive potential or patients desire to have a single testis and if regular follow-up is impossible.⁶

Patient with triorchidism harbor a higher chance of testicular cancer. Periodic self-examination is recommended, and the presence of new applications of technology in ultrasound and the addition of MRI for accurate diagnosis and classification. These strategies would appear to be safe to preserve a viable intra scrotal supernumerary testis found incidentally.

Conclusion

Triorchidism is a rare anomaly and should be included in differential diagnosis of solid extra testicular mass. Ultrasound is accurate and sufficient tool for diagnosis, however; MRI is superior for anatomical and functional classification. Polyorchidism is associated with undescended testes, inguinal hernia, infertility; and malignancy. Conservative management and imaging follow up versus surgical resection is made according to the type.

Competing interests

None declared.

Funding

None.

Ethical approval

Not required.

References

1. Kharrazi SM, Rahmani MR, Sakipour M, Khoob S. Polyorchidism: a case report and review of literature. *Urol J.* 2006;3(3):180–183.
2. Kheirandish P, Chinegwundoh F. An unusual case of triorchidism. *JRSM Short Rep.* 2010;1(6):55.
3. Yalcinkaya S, Sahin C, Sahin AF. Polyorchidism: sonographic and magnetic resonance imaging findings. *Can Urol Assoc J.* 2011;5(5):E84–E86.
4. Arlen AM, Holzman SA, Weiss AD, et al. Functional supernumerary testis in a child with testicular torsion and review of polyorchidism. *Pediatr Surg Int.* 2014;30(5):565–568.
5. Nane I, Ozkan L, Ander H. Inguinal orchiectomy for the extra testis with suspected tumor in a polyorchidic patient: a case report. *Int Urol Nephrol.* 2007;39(2):557–559.
6. Singer BR, Donaldson JG, Jackson DS. Polyorchidism: Functional classification and management strategy. *Urology.* 1992;39(4):384–388.