

RV lateral strain (%) -18.0 ± 4.4 , -14.7 ± 5.7 , 0.08.
 RV septal strain (%) -13.5 ± 6.9 , -14.7 ± 3.1 , 0.73.
 RV inferior strain (%) -17.4 ± 4.6 , -13.2 ± 5.0 , 0.11.
 RV inferolat strain (%) -16.3 ± 4.7 , -13.9 ± 3.9 , 0.13.

Conclusion.— In this population of Eisenmenger pts with severe PAH, conventional parameters of RV function are not different from those of pts with idiopathic PAH at the same level of systolic PAP. However, there is a tendency, although not significant, towards a lower alteration of RV longitudinal deformation parameters in pts with Eisenmenger, suggesting a relative preservation of RV function. The lack of significant difference between the two groups may be explained by the small sample size of this population with a significant number of pts with atrial shunt. However, the effect of sustained high level of PAP may perhaps also be almost the same on the RV after a long time of evolution whatever its etiology.

<http://dx.doi.org/10.1016/j.acvd.2013.03.022>

21

Detection of pulmonary arteriovenous malformation by contrast echocardiography in pediatric hereditary hemorrhagic telangiectasia

P. Balagny, C. Karam, J. Sellier, M. El Hajjam, S. Binsse, T. Chinet, J. Roume, A. Ozanne, I. Bourgault, G. Lesur, J.-H. Blondel, A. Cordier, S. Blivet, C. Fagnou, M. Bonay, P. Lacombe, O. Dubourg, N. Mansencal

AP-HP, Hôpital Ambroise-Paré, Boulogne, France

Background.— In hereditary hemorrhagic telangiectasia (HHT), assessment of pulmonary arteriovenous malformations (PAVMs) may be difficult in pediatric patients. The aim of this study was to assess the reliability of contrast echocardiography in a pediatric population presenting with HHT.

Patients.— We prospectively studied 22 pediatric patients presenting with HHT. All these patients underwent transthoracic contrast echocardiography (TTCE) and low-dose thoracic computed tomography (CT). Each TTCE examination was performed using second harmonic imaging, allowing to improve the quality of 2-dimensional imaging. The contrast protocol consisted of the injection of agitated 5% glucose solution through an upper extremity vein. We used the classification proposed by Barzilay et al.: grade 0 means no opacification of the left ventricle after the first three cardiac cycles following contrast appearance in the right atrium, grade 1 means minimal opacification; grade 2, moderate; grade 3, extensive opacification without outlining the endocardium; and grade 4, extensive opacification with clear endocardial definition. We considered CT as normal when no PAVMs or only one microscopic PAVMs was detected.

Results.— Mean age of the population was 11 ± 5 years (12 male). A PAVM was detected in 10 patients (45%) by CT. TTCE was feasible in all pediatric patients. Using TTCE, a grade 0 was found in four patients, a grade 1 in seven patients, a grade 2 in five patients, a grade 3 in six patients and no patient had a grade 4. In case of grade 0 or 1, no patient had a significant PAVMs, whereas for grade 2 and 3, all patients excepted one had PAVMs. The sensibility and specificity of TTCE for the detection of PAVMs was respectively 100% and 92%.

Conclusion.— Detection of PAVMs by TTCE is feasible in pediatric patients presenting with HHT. The reliability of TTCE is high in this specific population. Low-grade classification could presumably allow to avoid CT irradiation in pediatric patients.

<http://dx.doi.org/10.1016/j.acvd.2013.03.023>

Session n° 4 – Ischemic heart disease and stress-echo

22

Exercise systolic pulmonary artery pressure > 60 mmHg: A questionable threshold for clinical decision. Our experience in 509 patients

C. Chauvel, E. Bogino, P. Dehant, M. Jimenez, M. Simon, E. Abergel

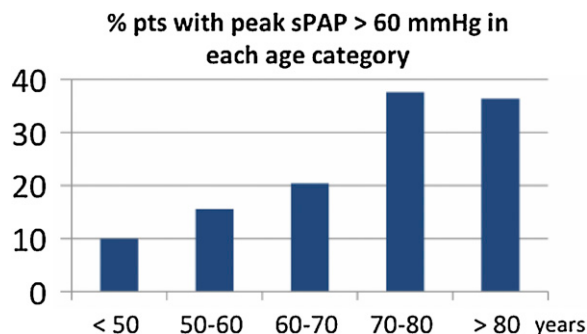
Clinique Saint-Augustin, Bordeaux, France

In the ACC/AHA and ESC guidelines, systolic pulmonary artery pressure (sPAP) during exercise > 60 mmHg is a criterion for surgery in asymptomatic mitral regurgitation or stenosis. Nevertheless, studies in normal volunteers have suggested that normal people > 60 years can reach this threshold. Unfortunately, only small series have been published and the usefulness of exercise sPAP in clinical practice remains subject of debate. Using Doppler exercise echocardiography, we prospectively measured sPAP at rest and during exercise in 509 patients.

Patients.— Between September 2011 and January 2013, we prospectively included all patients referred to our laboratory for exercise echocardiography with the following criteria: no significant valvular heart disease or pulmonary disease, normal rest left ventricular function and no myocardial ischemia at peak exercise. Tricuspid regurgitation velocity (Vmax) was measured using CW Doppler at rest, at 2 minutes exercise and at peak exercise. sPAP was calculated as $4 \times Vmax^2 + 5$ (mmHg). Correlations of sPAP with patients and exercise characteristics were evaluated.

Results.— Among 713 consecutive patients who fulfilled inclusion criteria, measurement of Vmax was feasible at all stages in only 509 (71.3%) patients. Mean age was 61 ± 14 years, 39% were female, 59% had treated hypertension. Mean sPAP was 29 ± 5 mmHg at rest, 37 ± 7 mmHg at low and 55 ± 11 mmHg at peak exercise. Thus, between rest and low exercise sPAP increase was low (28%) while between low and peak exercise, the increase was significantly higher (49%). sPAP at peak exercise was correlated with age ($r=0.27$, $P<0.0001$), with systolic arterial pressure ($r=0.21$, $P<.0001$). At peak exercise, sPAP was significantly higher in patients treated for hypertension as compared to patients without hypertension (51 vs. 47.7 mmHg, $P<0.0001$). Among all patients, 23% had a sPAP > 60 mmHg at peak exercise. After 70 years, 38% of patients had a peak exercise sPAP > 60 mmHg.

Conclusion.— In the present study, 23% of patients without significant cardiac disease had sPAP > 60 mmHg at peak exercise. Our data suggest that interpretation of exercise sPAP is complex and that age, systolic arterial pressure and rate of sPAP increase should be taken account for interpretation.



<http://dx.doi.org/10.1016/j.acvd.2013.03.024>

23