

## CASE REPORT

# Photodynamic Therapy in the Treatment of Choroidal Neovascularization Complicating Central Serous Chorioretinopathy

Chang-Sue Yang<sup>1,2\*</sup>, Kuan-Chieh Chen<sup>1</sup>, Shui-Mei Lee<sup>1,2</sup>, Fenq-Lih Lee<sup>1,2</sup>

<sup>1</sup>Department of Ophthalmology, Taipei Veterans General Hospital, and <sup>2</sup>Department of Ophthalmology, National Yang-Ming University School of Medicine, Taipei, Taiwan, R.O.C.

We report the favorable anatomic and functional outcome of photodynamic therapy with verteporfin in a case of chronic central serous chorioretinopathy complicated with choroidal neovascularization (CNV). This 37-year-old Chinese male with bilateral chronic central serous chorioretinopathy presented with central scotoma, reduced vision and metamorphopsia in his right eye. Fluorescein angiography (FA) disclosed macular hemorrhage, exudate and subfoveal classic CNV. Photodynamic therapy (PDT) with verteporfin was applied to the CNV according to standard protocol with 2.2-mm spot size. Best-corrected visual acuity (BCVA) improved from 6/20 to 6/10 1 month after PDT. BCVA recovered to 6/7.5 without leakage on FA 3 months after PDT. Neither recurrent CNV lesion nor new hemorrhage was noted over 12 months of follow-up. Short-term results suggest that PDT with verteporfin for CNV secondary to central serous chorioretinopathy is a safe and effective treatment modality. [*J Chin Med Assoc* 2009;72(9):501–505]

**Key Words:** central serous chorioretinopathy, choroidal neovascularization, photodynamic therapy, verteporfin

## Introduction

Central serous chorioretinopathy (CSC) is a disease that predominantly affects middle-aged adults. Males are 5–10 times more likely to develop CSC than females. CSC commonly involves the sensory retina and retinal pigment epithelium (RPE), and presents as either ink blot or smokestack type of hyperfluorescence on fluorescein angiography (FA). It may be associated with emotional stress, a type A achievement-oriented personality, systemic steroid use and pregnancy.<sup>1</sup> The disease is usually benign and self-limited, with good visual recovery. However, approximately 5% of CSC cases may have a poor visual outcome due to the disease being chronic. Persistent subretinal fluid, central RPE atrophy, atrophic RPE tracts inferior to the macula, cystoid macular edema, severe RPE degeneration, and choroidal neovascularization (CNV) are reported to be correlated with a poor visual outcome of chronic CSC.<sup>1,2</sup>

CNV secondary to CSC is a rare but potentially sight-threatening complication. Photodynamic therapy (PDT) with verteporfin has been proven to be beneficial for classic subfoveal CNV secondary to age-related macular degeneration (AMD) or pathologic myopia. CNV secondary to CSC may be potentially ameliorated by PDT because it usually presents as classic membrane on FA. Until recently, there were few studies concerning the outcome of PDT in patients with CSC complicated with CNV in Asia.<sup>3</sup> Herein, we report the successful treatment and good visual outcome of PDT in such a case.

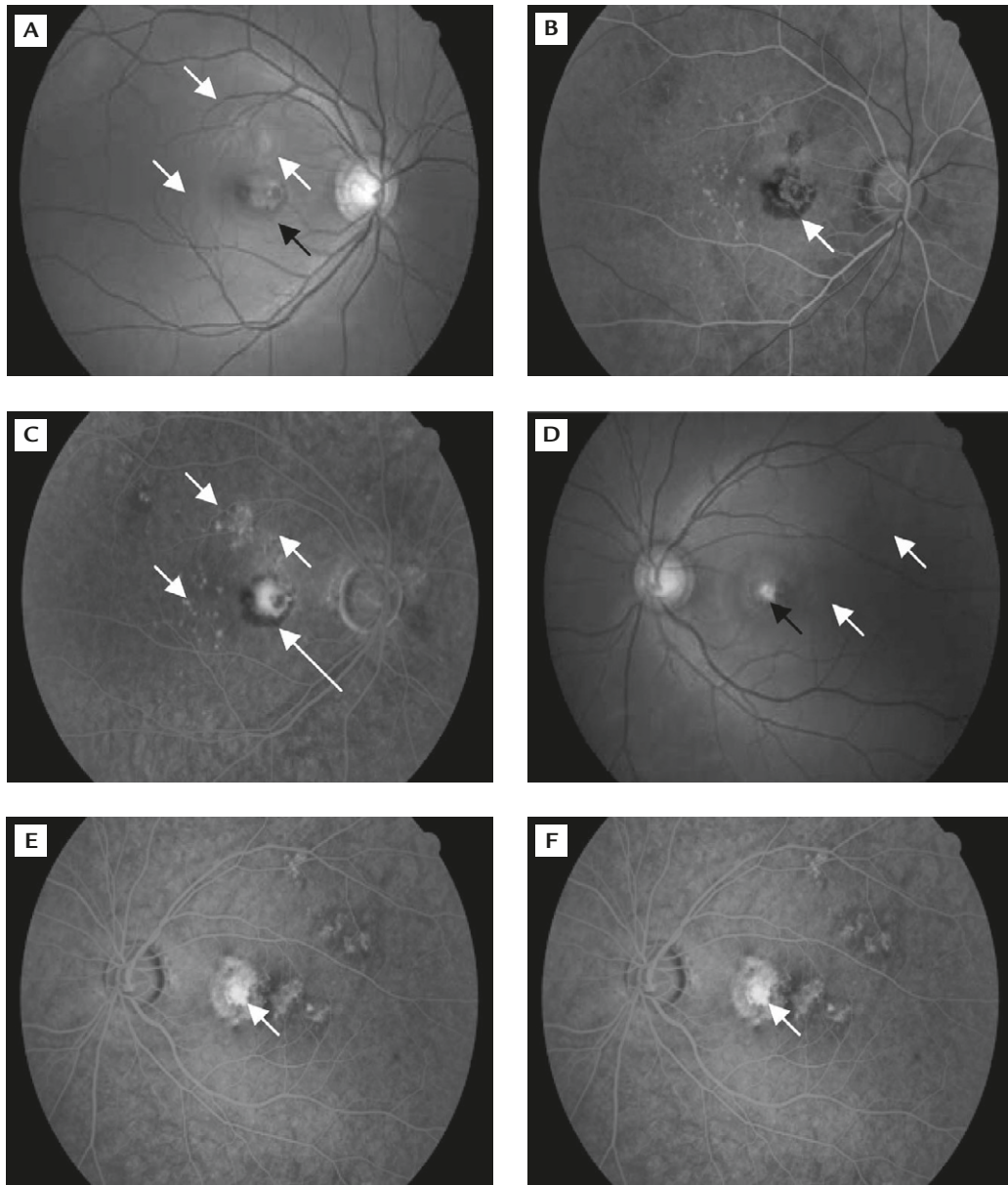
## Case Report

A 37-year-old man with a 6-year ocular history of bilateral chronic CSC with multiple recurrences presented with a 3-month history of central scotoma, reduced vision and metamorphopsia in his right eye.



\*Correspondence to: Dr Chang-Sue Yang, Department of Ophthalmology, Taipei Veterans General Hospital, 201, Section 2, Shih-Pai Road, Taipei 112, Taiwan, R.O.C.

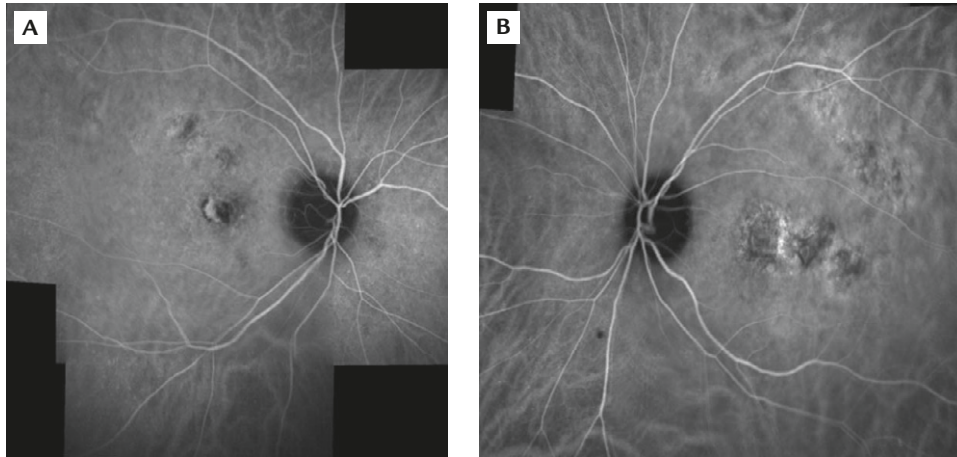
E-mail: [csyang@vghtpe.gov.tw](mailto:csyang@vghtpe.gov.tw) • Received: March 24, 2009 • Accepted: June 4, 2009



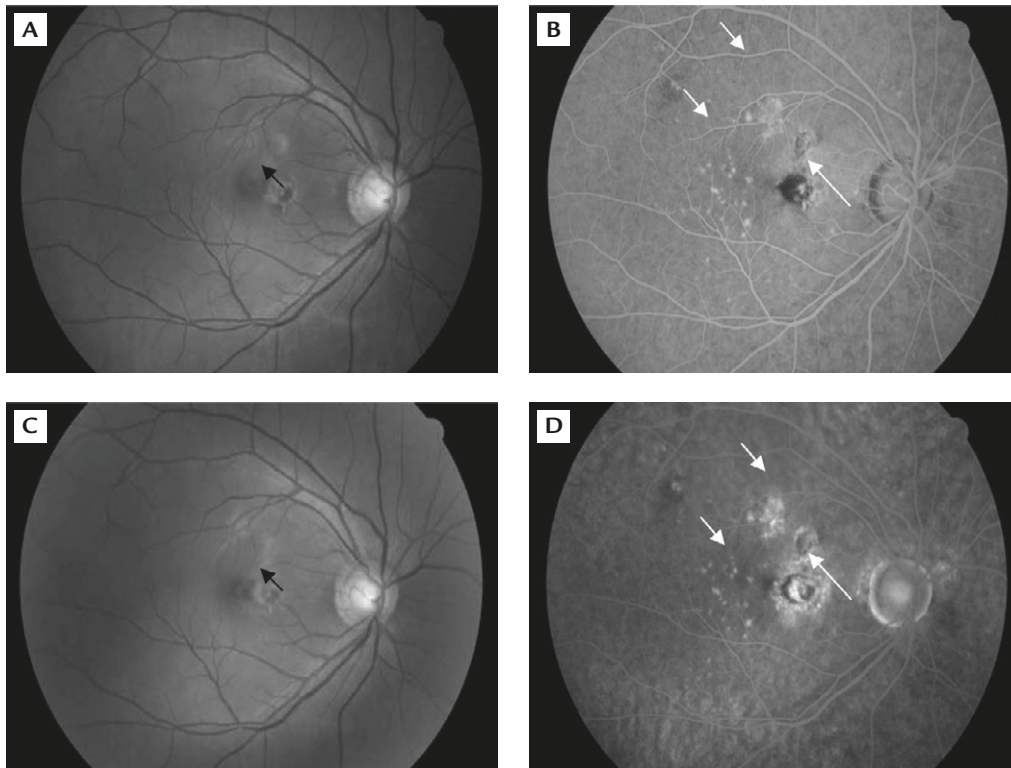
**Figure 1.** (A) At the initial presentation, fundus photograph showed macular hemorrhage with exudation and pigment clumping (black arrow) and multifocal retinal pigment epithelium (RPE) depigmentation (white arrows) in the right eye. Fluorescein angiography (FA) revealed: (B) early hyperfluorescence (arrow); and (C) late active dye leakage of classical choroidal neovascularization (CNV) with surrounding block fluorescence due to subretinal hemorrhage (long arrow). Multifocal areas of nodular hyperfluorescence due to depigmentation of the RPE (short arrows) were also noted. (D) Fundus photograph of the left eye showed an old glial scar (black arrow) and multifocal RPE depigmentation (white arrows). FA demonstrated: (E) early hyperfluorescence (arrow); and (F) late dye staining of the glial scar (arrow) and multifocal RPE window defects.

He had no history of systemic diseases. Best-corrected visual acuity (BCVA) was 6/20 in the right eye and 6/6.7 in the left eye. There was macular hemorrhage with exudation and pigment clumping within the posterior pole in the right eye (Figure 1A), whereas an old glial scar was evident in the posterior pole in the left eye (Figure 1D). Intravenous FA disclosed subfoveal CNV in the right eye with early hyperfluorescence and late leakage, and multifocal areas of nodular

hyperfluorescence due to depigmentation of the RPE (Figures 1B and 1C). FA in the left eye showed a gliotic scar with early hyperfluorescence and late staining without leakage (Figures 1E and 1F). Indocyanine green angiography (ICGA) revealed subfoveal CNV with hyperfluorescence dye leakage in the right eye (Figure 2A), and multiple areas of choroidal vascular hyperpermeability with associated late RPE leak in both eyes without polypoid-like lesions (Figure 2).



**Figure 2.** Indocyanine green angiography revealed: subfoveal choroidal neovascularization with hyperfluorescence dye leakage in the right eye (A); and multifocal areas of choroidal vascular hyperpermeability in both eyes (A, B) without polypoid-like lesions.



**Figure 3.** (A) Fundus photograph disclosed resolution of the macular edema and exudation 1 month after photodynamic therapy (PDT) (arrow). (B) Fluorescein angiography (FA) 1 month after PDT showed obviously less dye leakage from the choroidal neovascularization (CNV) (long arrow). The round hypofluorescent area is compatible with the spot of PDT. Multifocal areas of nodular hyperfluorescence due to RPE depigmentation (short arrows). (C) Fundus photograph showed no more hemorrhage or exudation 3 months after PDT (arrow), and visual acuity had improved to 6/10. (D) FA 3 months after PDT disclosed only staining with absence of CNV leakage (long arrow). Glial scar with depigmented RPE change and window defect were noted in the juxtafoveal and parafoveal areas (short arrows).

PDT with verteporfin was applied according to standard protocol with 2.2-mm spot size in the right eye 2 weeks after the initial event. One month after PDT, BCVA in the right eye had improved to 6/10 with improved symptoms. Biomicroscopic fundus examination showed resolution of the macular edema,

exudation and retinal hemorrhage with clearer foveal light reflex (Figure 3A). FA revealed much less dye leakage of CNV in the late phase (Figure 3B).

BCVA recovered to 6/7.5 at 3 months after PDT. No central scotoma was found on follow-up with Amsler Grid, and the clinical picture revealed no hemorrhage

and no exudation, with prominent fovea light reflex in the right eye (Figure 3C). There was only staining with absence of leakage on FA (Figure 3D). The left eye was stationary throughout the whole course during follow-up.

## Discussion

Central serous chorioretinopathy has a heterogeneous course. Most cases resolve spontaneously without any treatment. However, a small but meaningful subset of patients with CSC may develop chronic disease. Patients with chronic CSC may have a poor visual prognosis, especially those with clinical features such as persistent pigment epithelial detachment (PED) with subretinal fluid, multiple recurrences with foveal involvement, and subfoveal CNV.<sup>1</sup> These CNV commonly arise in patients with a history of longstanding CSC, persistent or recurrent attacks, chronic diffuse epitheliopathy, or an older age at presentation. Our patient belongs to this group of patients. The exact pathogenesis for the development of CNV in patients with CSC is unclear. We hypothesize that chronic decompensation or disruption at the RPE-Bruch membrane complex together with ischemic changes at the choriocapillaries may be important factors in CNV.

CSC develops primarily as a result of choroidal vascular hyperpermeability evidenced by ICGA study. PDT is a selective therapeutic modality that has been shown to occlude the hyperproliferative vessels and normalize the calibers of dilated and congested choroidal vasculature while leaving normal choroidal tissue unharmed, as compared to conventional laser therapy.<sup>3</sup> Recently, PDT with verteporfin has been used in the treatment of chronic CSC, with beneficial visual outcomes in the majority of patients in Western reports.<sup>3-7</sup> In the literature, there are few reports concerning PDT treatment of CSC in Asia.<sup>3,5</sup> We found a favorable anatomic and functional outcome at the 1- and 3-month follow-ups in a Chinese patient who remained stable without recurrence of CNV 12 months after PDT treatment.

ICGA is a very useful diagnostic tool with the advantage of being able to establish the correct diagnosis of CSC compared with FA. Characteristic ICGA findings include hyperpermeability of choroidal vessels with associated active RPE leaks, and multiple presumed occult serous RPE detachments in both eyes.<sup>8,9</sup> Differentiating CSC from other retinal diseases is the absence of polypoidal lesions and hot spots that are seen in polypoid choroidal vasculopathy and AMD.<sup>5,10,11</sup>

PDT treatment in patients with CSC associated with CNV might be successful because PDT also affects the longstanding non-neovascular component of CSC.<sup>6</sup> ICGA-guided PDT with verteporfin seems to aid in the resolution of exudative detachment in patients with chronic CSC.<sup>9</sup> PDT treatment is associated with a rapid reduction in subretinal fluid and improvement in visual acuity. In our patient, PDT was able to treat both the disease itself and CNV. Furthermore, PDT has the advantage of being less invasive than submacular surgery.<sup>2</sup> Due to long-term safety concerns and the possible risk of choroidal damage after PDT, recent reports have focused on reduced-dose verteporfin PDT for chronic CSC instead of the traditional standard protocol.<sup>12,13</sup> RPE tear following PDT in the treatment of CNV associated with AMD has also been reported to be a potential risk of PDT.<sup>14</sup>

In conclusion, PDT with verteporfin is an effective and promising treatment with good visual outcome in patients with CSC associated with CNV. Patient selection and early intervention remain vital in the treatment of this group of patients. Further prospective study would be beneficial to demonstrate the long-term safety and efficacy of PDT in treating CNV secondary to CSC in the Chinese population.

## Acknowledgments

This study was supported by grants from the National Science Council and Taipei Veterans General Hospital (V97C1-164, V98C1-187), Taiwan.

## References

1. Loo RH, Scott IU, Flynn HW Jr, Gass JD, Murray TG, Lewis ML, Rosenfeld PJ, et al. Factors associated with reduced visual acuity during long-term follow-up of patients with idiopathic central serous chorioretinopathy. *Retina* 2002;22:19-24.
2. Cooper BA, Thomas MA. Submacular surgery to remove choroidal neovascularization associated with central serous chorioretinopathy. *Am J Ophthalmol* 2000;130:187-91.
3. Chan WM, Lam DS, Lai TY, Tam BS, Liu DT, Chan CK. Choroidal vascular remodeling in central serous chorioretinopathy after indocyanine green guided photodynamic therapy with verteporfin: a novel treatment at the primary disease level. *Br J Ophthalmol* 2003;87:1453-8.
4. Taban M, Boyer DS, Thomas EL, Taban M. Chronic central serous chorioretinopathy: photodynamic therapy. *Am J Ophthalmol* 2004;137:1073-80.
5. Chan WM, Lam DS, Lai TY, Yuen KS, Liu DT, Chan CK, Chen WQ. Treatment of choroidal neovascularization in central serous chorioretinopathy by photodynamic therapy with verteporfin. *Am J Ophthalmol* 2003;136:836-45.
6. Ergun E, Tittl M, Stur M. Photodynamic therapy with verteporfin in subfoveal choroidal neovascularization secondary to

- central serous chorioretinopathy. *Arch Ophthalmol* 2004;122:37–41.
7. Cardillo Piccolino F, Eandi CM, Ventre L, Rigault de la Longrais RC, Grignolo FM. Photodynamic therapy for chronic central serous chorioretinopathy. *Retina* 2003;23:752–63.
  8. Guyer DR, Yannuzzi LA, Slakter JS, Sorenson JA, Ho A, Orlock D. Digital indocyanine green videoangiography of central serous chorioretinopathy. *Arch Ophthalmol* 1994;112:1057–62.
  9. Yannuzzi LA, Slakter JS, Gross NE, Spaide RF, Costa DL, Huang SJ, Klancnik JM Jr, et al. Indocyanine green angiography-guided photodynamic therapy for treatment of chronic central serous chorioretinopathy: a pilot study. *Retina* 2003;23:288–98.
  10. Sasahara M, Tsujikawa A, Musashi K, Gotoh N, Otani A, Mandai M, Yoshimura N. Polypoidal choroidal vasculopathy with choroidal vascular hyperpermeability. *Am J Ophthalmol* 2006;142:601–7.
  11. Yannuzzi LA, Freund KB, Goldbaum M, Scassellati-Sforzolini B, Guyer DR, Spaide RF, Maberley D, et al. Polypoidal choroidal vasculopathy masquerading as central serous chorioretinopathy. *Ophthalmology* 2000;107:767–77.
  12. Cervera E, Montero J, Torralba C, Palomares P, Hernández M. Low dose photodynamic therapy for chronic central serous chorioretinopathy. *Arch Soc Esp Ophthalmol* 2008;83:525–6.
  13. Chan WM, Lai TYY, Lai RYK, Liu DTL, Lam DSC. Half-dose verteporfin photodynamic therapy for acute central serous chorioretinopathy. *Ophthalmology* 2008;115:1756–65.
  14. Goldstein M, Heilweil G, Barak A, Loewenstein A. Retinal pigment epithelial tear following photodynamic therapy for choroidal neovascularization secondary to AMD. *Eye* 2005;19:1315–24.