




Available online at  
 ScienceDirect  
www.sciencedirect.com

Elsevier Masson France  
 EM|consulte  
www.em-consulte.com



## REVIEW

# Fate of the distal aorta after surgical repair of acute DeBakey type I aortic dissection: A review

Le devenir de l'aorte distale après réparation chirurgicale des dissections aortiques aiguës de type I de DeBakey : une mise au point

**Matthias Kirsch\***, Antoine Legras, Matthieu Bruzzi, Nicolas Louis

*Service de chirurgie vasculaire et cardiothoracique, hôpital Henri-Mondor, 51, avenue du Maréchal-de Lattre-de-Tassigny, 94000 Créteil, France*

Received 21 October 2010; received in revised form 15 November 2010; accepted 16 November 2010

Available online 17 February 2011

### KEYWORDS

Aorta;  
Dissection;  
Cardiac surgical  
procedures;  
Duty to follow-up

### MOTS CLÉS

Aorte ;  
Dissection ;  
Procédures  
chirurgicales  
cardiaques ;  
Suivi des patients

**Summary** Operated acute DeBakey type I aortic dissection has to be considered as a chronic aortic disease with the potential of late distal dilatation with aneurysm formation and need for reoperation. Several intraoperative strategies have been devised to prevent late complications. However, the increased operative risk associated with a more aggressive initial approach in an emergent setting has to be balanced against the relatively low incidence of late reoperations. Further studies will have to identify preoperative risk factors for late distal aortic complications more precisely in order to select patients who might benefit the most from these newer surgical strategies.

© 2011 Elsevier Masson SAS. All rights reserved.

**Résumé** Le traitement chirurgical des dissections aortique de type I de DeBakey reste palliatif. L'aorte distale reste le plus souvent disséquée en postopératoire et peut évoluer ultérieurement vers une dilatation anévrysmale et nécessiter une ré-intervention. Différentes stratégies chirurgicales ont été développées afin de limiter l'incidence de ces complications tardives. Toutefois, le risque opératoire plus élevé d'une intervention chirurgicale initiale plus agressive doit être pesé par rapport à l'incidence relativement faible des ré-interventions tardives. L'identification de facteurs de risques préopératoires prédictifs de complications

\* Corresponding author. Fax: +33 1 49 81 21 52.  
E-mail address: [matthias.kirsch@hmn.aphp.fr](mailto:matthias.kirsch@hmn.aphp.fr) (M. Kirsch).

aortiques tardives devrait permettre de mieux sélectionner les patients pour ces nouvelles techniques.

© 2011 Elsevier Masson SAS. Tous droits réservés.

## Background

Surgery has drastically improved the outcome of acute DeBakey type I aortic dissection. Immediate surgical intervention aims to prevent ascending aortic rupture, redirect blood flow into the true vessel lumen, and correct aortic valve insufficiency. However, surgical treatment remains essentially palliative, as most operative survivors have a residual dissected aorta, often with a patent false lumen. This exposes patients to distal aortic dilatation and subsequent aneurysm formation, with its inherent risks of aortic rupture or reoperation.

The precise natural history of operated acute DeBakey type I aortic dissection remains largely unknown. The objective of the present review is to summarize existing evidence regarding the fate of the distal aorta after surgical repair of acute DeBakey type I aortic dissection. Surgical strategies aimed at preventing distal aortic complications are also reviewed.

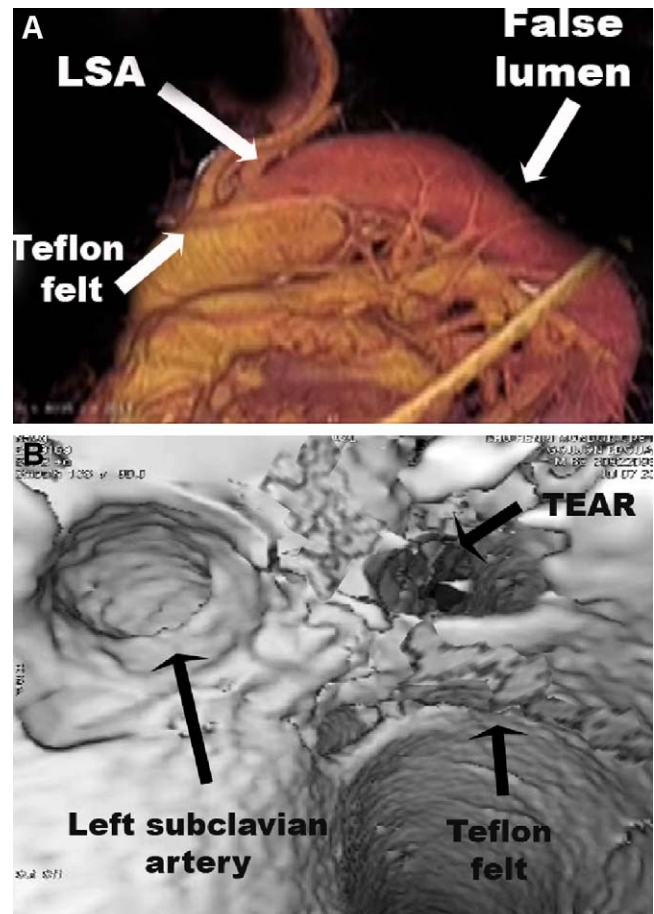
## Natural history of distal aorta after operated type A aortic dissection

The fate of the distal aorta after surgical repair of acute type A aortic dissection has been addressed using three inter-related endpoints: (1) the persistent patency of the distal false lumen; (2) distal aortic dilatation with aneurysm formation; and (3) actual reoperations on the distal aorta or its branches.

### Distal false lumen patency

The main objective of the distal surgical repair is obliteration of the false lumen in order to redirect blood flow into the true lumen. However, distal repair fails to achieve this objective in the majority of cases. Indeed, the incidence of partial or complete distal false lumen patency is reported to lie between 31% and 89% [1–8].

Persistent postoperative perfusion of the distal false lumen can be related to: (1) the presence of unresected or secondary entry sites in the distal aorta; (2) aortic clamp trauma that may injure the friable dissected aorta and create a new intimal tear immediately distal to the surgical repair; or (3) a leak at the level distal aortic anastomosis (Fig. 1). Sakaguchi et al. have shown that preoperative hypertension (requiring aggressive use of antihypertensive drugs) and preoperative size of the descending thoracic aorta  $\geq 35$  mm were significant and independent risk factors of postoperative false lumen patency [2]. Very recently, Zhao et al. have shown that complete distal false lumen thrombosis 1 year after operation was significantly lower in patients who required postoperative anticoagulation than in those who did not (87% vs 98%,  $p=0.005$ ) [9]. Thus, in



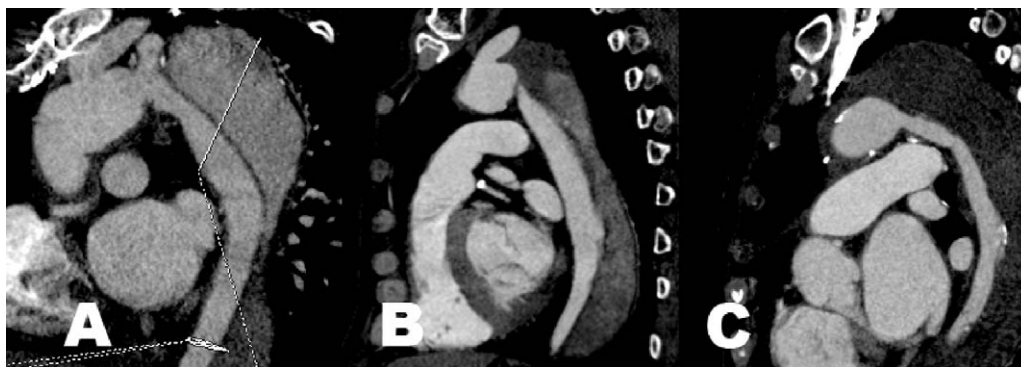
**Figure 1.** Long-term postoperative CT scan of a patient operated on for acute DeBakey type I aortic dissection with hemiarch replacement showing distal false lumen patency (A). Virtual angiography shows an intimal dehiscence at the level of the distal suture line (B). CT: computed tomography; LSA: left subclavian artery.

patients in whom the native aortic valve cannot be preserved, the choice of the heart valve substitute should be made with caution, and the long-term risk of distal aortic complications should be balanced against the risk of bioprosthetic structural deterioration.

The clinical consequences of distal false lumen patency remain controversial. Several studies have evaluated the association of distal false lumen patency with distal aortic dilatation or growth rates, and long-term clinical outcomes.

### Aortic dilatation

Postoperative distal false lumen patency is an independent predictor for distal aortic dilatation. Moreover, a large area of the patent false lumen ( $>70\%$  of the total area of the transectional diameter of the aorta) is a strong predictor



**Figure 2.** Long-term postoperative CT scans of patients operated on for acute DeBakey type I aortic dissection showing three different outcomes of the distal false lumen: completely patent (A), partial thrombosis (B) and complete thrombosis (C). CT: computed tomography.

for secondary dilatation of the diseased downstream aorta [10].

### Aortic growth rate

Several studies have shown that distal aortic growth rate is greater in patients with patent than with thrombosed distal false lumen [4,5,8,11]. For example, Fattouche et al. found yearly aortic growth rates of  $2.8 \pm 0.4$  mm and  $1.1 \pm 0.2$  mm in patients with patent and occluded false lumen, respectively ( $p=0.001$ ) [4]. Similarly, distal anastomotic leak after ascending aortic replacement for acute type A aortic dissection contributes to greater distal aortic growth rates [12].

### Clinical outcomes (reoperation, rupture, death)

Myrmel et al. applied criteria of evidence-based medicine on all clinical series published between 1980 and 2003, but could not find a consistent relationship between persistence of a patent distal false lumen and increased risk of reoperation, aortic rupture or death [13]. Similarly, more recent studies have failed to show significant differences in freedom from distal aortic reoperation or survival between patients with and without a patent false lumen [2,5]. In contrast, the recently published experience of the Palermo group showed significantly lower freedom from reoperation and survival rates in patients with patent false lumen [4].

### Partial thrombosis

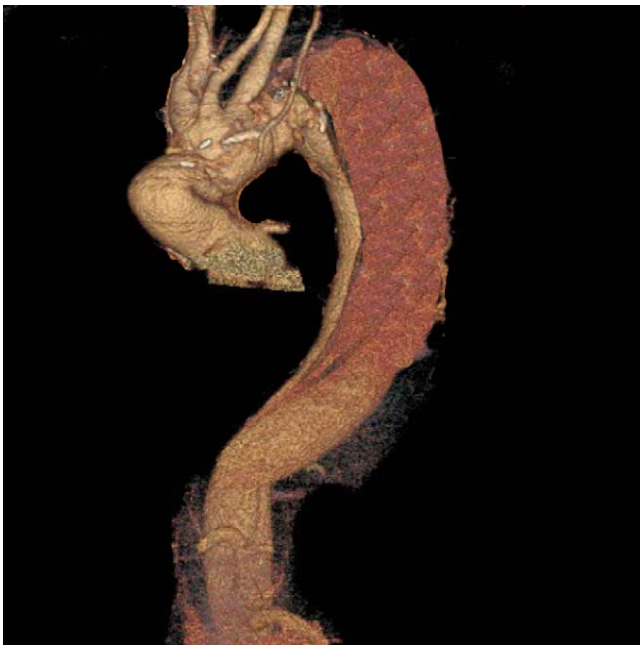Some of this discrepancy might be related to the fact that most studies do not differentiate between completely patent, partially thrombosed and completely thrombosed false aortic lumen (Fig. 2). Partial thrombosis can be defined as the concurrent presence of both flow and thrombus in the false lumen [14]. Fattori et al. have shown that partial thrombosis of the false lumen is protective against dilatation as suggested by an aortic growth rate of 0.34 cm/year in patients with partial thrombosis of the false lumen versus an increase of 0.56 cm/year in patients without thrombus in the false lumen [8]. Furthermore, the number of late postoperative events was lower in patients with partial thrombosis compared to patients with no thrombosis. In contrast, Tsai et al. have shown that partial thrombosis of the false lumen is a particularly grave sign in patients with acute DeBakey type III aortic dissection [14]. Similar findings have very recently been reported by Song et al., who show that partial

thrombosis of the false lumen after repair of acute DeBakey type I aortic dissection, compared with complete patency or complete thrombosis, is a significant and independent predictor of aortic enlargement, aorta-related reoperations and poor long-term survival [15]. However, the mechanisms by which partial thrombosis of the false lumen compromises long-term outcome remain speculative. In patients with a completely patent false lumen, the latter may be perfused by an entry tear and decompressed through another re-entry tear. In case of partial thrombosis, however, the thrombus may occlude the re-entry tear, thus impeding outflow. This may result in increased false lumen pressure and wall tension, favouring subsequent dilatation. Alternatively, aortic wall hypoxia at the level of the thrombus might lead to increased local inflammation and neovascularization, resulting in local aortic wall weakening.

### Distal aortic dilatation

Dilatation of the distal aorta occurs preferentially in the aortic arch and upper descending thoracic aorta (Fig. 3). Immer et al. have reported that 86% of late dilatations were found at the level of the aortic arch and/or descending thoracic aorta [10]. Aortic growth rates vary among aortic segments, and the highest rates are reported for the descending thoracic aorta (1–3.7 mm/year) [8,16]. The expansion of the distal aorta is caused mainly by dilatation of the false lumen [6]. This is probably related to mechanical instability of the dissected aortic wall, reduced to a thin layer of media with adventitia. Of note, the time of onset of aortic enlargement seems to be unpredictable, and can occur after several years of apparent stability [17]. This observation justifies long-term surveillance by repeated imaging studies.

Several studies have determined risk factors for late distal aortic enlargement after surgical correction of acute DeBakey type I aortic dissection. Patient-related variables include younger age [6,18], male sex [6] and connective tissue disorders such as Marfan syndrome [6,19]. The involvement of supra-aortic vessels and/or the presence of preoperative malperfusion syndrome indicating a more distal extent of the dissection are also associated with late distal aortic dilatation [18]. Different surgical repair techniques, however, do not seem to have an influence on late aortic dilatation [17,20]. After surgical correction, a greater diameter of the distal aorta is associated with late aneurysm



**Figure 3.** Long-term postoperative CT scan of a patient operated on for acute DeBakey type I aortic dissection showing aneurysmal dilatation of the upper descending thoracic aorta. CT: computed tomography.

formation [17,19–21]. As discussed previously, distal aortic dilatation occurs more frequently when the false lumen is patent [17,18,20] and larger than the true lumen [6,10]. In the long term, elevated systolic blood pressure [17] and elevated pulse pressure [21] have also been shown to influence late dilatation. These findings underscore the importance of long-term blood pressure control, with an objective of maintaining systolic blood pressure < 120–140 mmHg, and advocate the liberal use of beta-blocker therapy.

### Reoperation on the distal aorta

The reported incidence of reoperations on the distal aorta is relatively low and varies between 4 and 28% of hospital survivors [4,5,8,16,17,19,22,23]. In our experience, actuarial estimates of freedom from reoperation on the distal aorta or its side branches are 98, 93, 77, and 56% at 1, 5, 10, and 15 years, respectively, after initial operation [24]. Other groups report very similar results, with actuarial estimates of freedom from distal reoperation at 10 years ranging from 69% to 90% [5,17,23,25]. The variability between studies is related, at least in part, to different definitions of reoperation (whether one includes only aortic procedures or procedures performed on the aorta and its side branches) and different aortic size criteria to perform reoperation. However, because an unknown number of patients die of aortic complications before they can undergo reoperation or refuse reoperation, the real incidence of patients needing reoperation is probably underestimated.

Patient-related risk factors for reoperation on the distal aorta include younger patient age [24,25] and connective tissue disorders such as Marfan syndrome [17,25]. Dissection-related factors include a more distal extent of dissection at presentation [25]. The only identified

procedure-related factor seems to be non-resection of the primary entry site [17], while the extent of aortic replacement does not seem to have a significant impact. Postoperatively, persistent false lumen patency [20], elevated systolic blood pressure [17] and the absence of beta-blocker therapy at follow-up [17] have been identified as independent risk factors for late reoperation on the distal aorta.

### Surgical strategies to prevent distal aortic aneurysm formation

Several surgical strategies have been devised to prevent persistent false lumen patency, aortic dilatation, and reoperation. However, none have been adequately evaluated by randomized controlled trials and, therefore, no definite recommendation can be made.

### Circulatory arrest with open distal technique

Systematic use of circulatory arrest with “open-distal” repair in patients undergoing surgery for acute type A aortic dissection has been advocated by a number of surgeons [26–28]. This “no touch” found no significant differences [29]. Myrme et al. applied criteria of evidence-based medicine to all clinical series published between 1980 and 2003, but could not find conclusive evidence favouring the use of an open distal anastomosis in patients with acute DeBakey type I dissection [13].

We retrospectively compared early postoperative outcomes in 64 patients undergoing surgical repair of acute type A aortic dissection using the no-touch technique with those of 36 patients undergoing conventional repair with aortic cross-clamping and no hypothermic circulatory arrest (unpublished results). Although operative and 1-year mortality rates were similar in both groups, and no increase in neurological complications was noted, the no-touch technique was associated with significantly longer cardiopulmonary bypass times, a higher incidence of postoperative pulmonary and renal complications, and prolonged mechanical ventilation and intensive care unit durations. Whether this increased postoperative morbidity is the price to pay to reduce the incidence of long-term distal aortic complications remains to be determined.

### Distal extent of aortic replacement

There is now general agreement that the distal repair should be extended sufficiently in order to excise the segment of aorta containing the intimal entry tear [30]. Some studies have shown that extension of the distal resection into the arch can be performed without a significant increase in postoperative mortality [31,32]. Thus, a systematically extended or total aortic arch resection has been proposed for the initial surgical management of acute DeBakey type I aortic dissection, irrespective of the location of the intimal tear [33–35]. Although satisfying results have been reported (low mortality and reoperation rates), the use of systematic extensive or total aortic replacement performed as an emergent procedure will necessarily increase an already high operative risk. Accordingly, Campbell-Lloyd

et al. have shown that total aortic arch replacement was the only univariate risk factor for poor neurological outcome in a contemporary series of patients undergoing surgery for acute type A aortic dissection [36]. Similarly, Kim et al. have very recently reported that total arch replacement was associated with greater morbidity and mortality, without decreasing the reoperation rate, compared with hemiarch repair in acute type I aortic dissection [37]. We believe that the risk of systematic arch replacement largely outweighs the relatively low incidence of reoperation (> 70% freedom from distal reoperation at 10 years) and risk of reoperation.

### Open stent-graft procedures

More recently, hybrid approaches, combining surgical and endovascular techniques, have been used for the initial treatment of acute DeBakey type I aortic dissection in order to prevent aneurismal dilatation of the distal aorta and the need for late reoperations [38]. Thus, the stented (or frozen) elephant trunk technique combines conventional surgical replacement of the ascending aorta and the aortic arch with endovascular repair of the descending aorta. The latter is performed during the period of circulatory arrest by deploying a homemade or commercially available stent-graft in the descending thoracic aorta [39]. The expected benefit of this hybrid approach is immediate exclusion of additional intimal tears in the descending thoracic aorta. A recent best-evidence topic reviewing all the published series up to March 2010 concluded that this technique can be used without increasing operative mortality and morbidity, but at the price of longer cardiopulmonary bypass and circulatory arrest times. Spinal cord ischaemia and bowel ischaemia represent the main serious complications associated with this technique [40]. However, some series suggest that this procedure allows early thrombosis of the false channel [7,41,42], and a reduction of late thoracoabdominal aneurysm formation and reoperation rates [43,44].

Very recently, Chen et al. have reported a series of 30 patients operated on for acute DeBakey type I aortic dissection in whom they performed ascending aortic replacement combined with open placement of a triple-branched stent graft into the true lumen of the arch, arch vessels, and descending thoracic aorta [45]. This approach allows extensive repair of the dissected thoracic aorta and appears simpler and faster than the previously described stented elephant trunk technique. Although the theoretical foundations of these hybrid approaches are sound, and initial results are encouraging, the precise indications of these techniques remain to be determined.

### Conclusions

Operated acute DeBakey type I aortic dissection has to be considered as a chronic aortic disease with the potential of late distal dilatation, aneurysm formation and the need for reoperation. As such, this affection requires life-long surveillance of the residual dissected aorta. Furthermore, aggressive blood pressure control using beta-blocker therapy is mandatory for these patients.

Several intraoperative strategies have been devised to prevent late complications. However, the increased opera-

tive risk associated with a more aggressive initial approach in an emergent setting has to be balanced against the relatively low incidence of late reoperations. Further studies will have to identify more precisely preoperative risk factors for late distal aortic complications in order to select patients who might benefit the most from these newer strategies.

### Conflict of interest statement

None.

### References

- [1] Ergin MA, Phillips RA, Galla JD, et al. Significance of distal false lumen after type A dissection repair. *Ann Thorac Surg* 1994;57:820–4 [discussion 825].
- [2] Sakaguchi G, Komiya T, Tamura N, et al. Patency of distal false lumen in acute dissection: extent of resection and prognosis. *Interact Cardiovasc Thorac Surg* 2007;6:204–7.
- [3] Moore NR, Parry AJ, Trotman-Dickenson B, Pillai R, Westaby S. Fate of the native aorta after repair of acute type A dissection: a magnetic resonance imaging study. *Heart* 1996;75:62–6.
- [4] Fattouch K, Sampognaro R, Navarra E, et al. Long-term results after repair of type A acute aortic dissection according to false lumen patency. *Ann Thorac Surg* 2009;88:1244–50.
- [5] Kimura N, Tanaka M, Kawahito K, Yamaguchi A, Ino T, Adachi H. Influence of patent false lumen on long-term outcome after surgery for acute type A aortic dissection. *J Thorac Cardiovasc Surg* 2008;136:1160–6.
- [6] Park K-H, Lim C, Choi JH, et al. Midterm change of descending aortic false lumen after repair of acute type I dissection. *Ann Thorac Surg* 2009;87:103–8.
- [7] Jakob H, Tsagakis K, Tossios P, et al. Combining classic surgery with descending stent grafting for acute DeBakey type I dissection. *Ann Thorac Surg* 2008;86:95–101.
- [8] Fattori R, Bacchi-Reggiani L, Bertaccini P, et al. Evolution of aortic dissection after surgical repair. *Am J Cardiol* 2000;86:868–72.
- [9] Zhao X, Sun LZ, Zheng J, et al. Early influence of valve-related anticoagulation on false lumen thrombosis in aortic dissection patients after stented elephant trunk surgery. *Thorac Cardiovasc Surg* 2010;58:271–5.
- [10] Immer FF, Krähenbühl E, Hagen U, et al. Large area of the false lumen favors secondary dilatation of the aorta after acute type A aortic dissection. *Circulation* 2005;Suppl. 112:1249–52.
- [11] Bernard Y, Zimmermann H, Chocron S, et al. False lumen patency as a predictor of late outcome in aortic dissection. *Am J Cardiol* 2001;87:1378–82.
- [12] Tanaka H, Okada K, Kawanishi Y, Matsumori M, Okita Y. Clinical significance of anastomotic leak in ascending aortic replacement for acute aortic dissection. *Interact Cardiovasc Thorac Surg* 2009;9:209–12.
- [13] Myrmet T, Lai DT, Miller DC. Can the principles of evidence-based medicine be applied to the treatment of aortic dissections? *Eur J Cardiothorac Surg* 2004;25:236–42 [discussion 242–5].
- [14] Tsai TT, Evangelista A, Nienaber CA, et al. Partial thrombosis of the false lumen in patients with acute type B aortic dissection. *N Engl J Med* 2007;357:349–59.
- [15] Song SW, Chang BC, Cho BK, et al. Effects of partial thrombosis on distal aorta repair of acute DeBakey type I aortic dissection. *J Thorac Cardiovasc Surg* 2010;139:841–7 [e1; discussion 847].
- [16] Halstead JC, Meier M, Etz C, et al. The fate of the distal aorta after repair of acute type A aortic dissection. *J Thorac Cardiovasc Surg* 2007;133:127–35.

- [17] Zierer A, Voeller RK, Hill KE, Kouchoukos NT, Damiano Jr RJ, Moon MR. Aortic enlargement and late reoperation after repair of acute type A aortic dissection. *Ann Thorac Surg* 2007;84:479–86 [discussion 486–7].
- [18] Immer FF, Hagen U, Berdat PA, Eckstein FS, Carrel TP. Risk factors for secondary dilatation of the aorta after acute type A aortic dissection. *Eur J Cardiothorac Surg* 2005;27:654–7.
- [19] Song JM, Kim SD, Kim JH, et al. Long-term predictors of descending aorta aneurysmal change in patients with aortic dissection. *J Am Coll Cardiol* 2007;50:799–804.
- [20] Yeh CH, Chen MC, Wu YC, Wang YC, Chu JJ, Lin PJ. Risk factors for descending aortic aneurysm formation in medium-term follow-up of patients with type A aortic dissection. *Chest* 2003;124:989–95.
- [21] Almeida AG, Nobre AL, Pereira RA, et al. Impact of aortic dimensions and pulse pressure on late aneurysm formation in operated type A aortic dissection. A magnetic resonance imaging study. *Int J Cardiovasc Imaging* 2008;24:633–40.
- [22] Tan ME, Morshuis WJ, Dossche KM, Kelder JC, Waanders FG, Schepens MA. Long-term results after 27 years of surgical treatment of acute type A aortic dissection. *Ann Thorac Surg* 2005;80:523–9.
- [23] Gariboldi V, Grisoli D, Kerbaul F, et al. Long-term outcomes after repaired acute type A aortic dissections. *Interact Cardiovasc Thorac Surg* 2007;6:47–51.
- [24] Kirsch M, Soustelle C, Houël R, Hillion ML, Loisançe D. Risk factor analysis for proximal and distal reoperations after surgery for acute type A aortic dissection. *J Thorac Cardiovasc Surg* 2002;123:318–25.
- [25] Geirsson A, Bavaria JE, Swarr D, et al. Fate of the residual distal and proximal aorta after acute type A dissection repair using a contemporary surgical reconstruction algorithm. *Ann Thorac Surg* 2007;84:1955–64 [discussion 1955–64].
- [26] David TE, Armstrong S, Ivanov J, Barnard S. Surgery for acute type A aortic dissection. *Ann Thorac Surg* 1999;67:1999–2001 [discussion 2014–9].
- [27] Nguyen B, Müller M, Kipfer B, et al. Different techniques of distal aortic repair in acute type A dissection: impact on late aortic morphology and reoperation. *Eur J Cardiothorac Surg* 1999;15:496–500 [discussion 500–1].
- [28] Yamashita C, Okada M, Ataka K, et al. Open distal anastomosis in retrograde cerebral perfusion for repair of ascending aortic dissection. *Ann Thorac Surg* 1997;64:665–9.
- [29] Lai DT, Robbins RC, Mitchell RS, et al. Does profound hypothermic circulatory arrest improve survival in patients with acute type A aortic dissection? *Circulation* 2002;106(Suppl. 1):I218–28.
- [30] Bachet JE, Termignon JL, Dreyfus G, et al. Aortic dissection. Prevalence, cause, and results of late reoperations. *J Thorac Cardiovasc Surg* 1994;108:199–205 [discussion 205–6].
- [31] Moon MR, Sundt 3rd TM, Pasque MK, et al. Does the extent of proximal or distal resection influence outcome for type A dissections? *Ann Thorac Surg* 2001;71:1244–9 [discussion 1249–50].
- [32] Tan ME, Dossche KM, Morshuis WJ, Kelder JC, Waanders FG, Schepens MA. Is extended arch replacement for acute type A aortic dissection an additional risk factor for mortality? *Ann Thorac Surg* 2003;76:1209–14.
- [33] Hirotsuni T, Kameda T, Kumamoto T, Shirota S. Results of total aortic arch replacement for an acute arch dissection. *J Thorac Cardiovasc Surg* 2000;120:686–91.
- [34] Hirotsuni T, Nakamichi T, Munakata M, Takeuchi S. Routine extended graft replacement for an acute type A aortic dissection and the patency of the residual false channel. *Ann Thorac Surg* 2003;76:1957–61.
- [35] Kazui T, Washiyama N, Muhammad BA, et al. Extended total arch replacement for acute type A aortic dissection: experience with seventy patients. *J Thorac Cardiovasc Surg* 2000;119:558–65.
- [36] Campbell-Lloyd AJ, Mundy J, Pinto N, et al. Contemporary results following surgical repair of acute type A aortic dissection (AAAD): a single centre experience. *Heart Lung Circ* 2010;19:665–72.
- [37] Kim JB, Chung CH, Moon DH, et al. Total arch repair versus hemi-arch repair in the management of acute DeBakey type I aortic dissection. *Interact Cardiovasc Thorac Surg* 2010;11(Suppl. 2):S72 [abstract 038].
- [38] Karck M, Kamiya H. Progress of the treatment for extended aortic aneurysms; is the frozen elephant trunk technique the next standard in the treatment of complex aortic disease including the arch? *Eur J Cardiothorac Surg* 2008;33:1007–13.
- [39] Kato M, Matsuda T, Kaneko M, et al. Outcomes of stent-graft treatment of false lumen in aortic dissection. *Circulation* 1998;98(Suppl.):II305–11 [discussion II311–2].
- [40] Murzi M, Tiwari KK, Farneti PA, Glauber M. Might acute type A aortic dissection repair with the addition of a frozen elephant trunk improve long-term survival compared to standard repair? *Interact Cardiovasc Thorac Surg* 2010;11:98–102.
- [41] Uchida N, Shibamura H, Katayama A, Shimada N, Sutoh M. Total arch replacement with an open stent graft for acute type A aortic dissection: fate of the false lumen. *Eur J Cardiothorac Surg* 2009;35:83–8.
- [42] Tsagakis K, Pacini D, Di Bartolomeo R, et al. Arch replacement and downstream stent grafting in complex aortic dissection: first results of an international registry. *Eur J Cardiothorac Surg* 2011;39:87–94.
- [43] Uchida N, Shibamura H, Katayama A, Shimada N, Sutoh M, Ishihara H. Operative strategy for acute type A aortic dissection: ascending aortic or hemiarch versus total arch replacement with frozen elephant trunk. *Ann Thorac Surg* 2009;87:773–7.
- [44] Pochettino A, Brinkman WT, Moeller P, et al. Antegrade thoracic stent grafting during repair of acute DeBakey I dissection prevents development of thoracoabdominal aortic aneurysms. *Ann Thorac Surg* 2009;88:482–9 [discussion 489–90].
- [45] Chen LW, Dai XF, Lu L, Zhang GC, Cao H. Extensive primary repair of the thoracic aorta in acute type A aortic dissection by means of ascending aorta replacement combined with open placement of triple-branched stent graft: early results. *Circulation* 2010;122:1373–8.