

Contents lists available at [ScienceDirect](http://www.sciencedirect.com)

Biochimica et Biophysica Acta

journal homepage: www.elsevier.com/locate/bbadis

Review

The neuronal ceroid lipofuscinoses program: A translational research experience in Argentina[☆]



Romina Kohan^{a,b}, Favio Pesaola^{a,c}, Norberto Guelbert^a, Patricia Pons^d, Ana María Oller-Ramírez^a, Gisela Rautenberg^a, Adriana Becerra^a, Katherine Sims^e, Winnie Xin^e, Inés Adriana Cismondi^{a,b}, Inés Noher de Halac^{a,b,c,*}

^a Centro de Estudio de las Metabolopatías Congénitas (CEMECO), Facultad de Ciencias Médicas, Universidad Nacional de Córdoba, Ferrovianos 1250, 5014 Córdoba, Argentina

^b Facultad de Odontología, Universidad Nacional de Córdoba, Haya de la Torre s/n, 5000 Córdoba, Argentina

^c Consejo Nacional de Investigaciones Científicas y Técnicas (CONICET), Av. Rivadavia 1917, C1033AAJ CABA, Argentina

^d Centro de Microscopía Electrónica, Facultad de Ciencias Médicas, Universidad Nacional de Córdoba, Haya de la Torre esq. Enrique Barros, 1^a piso, 5000 Córdoba, Argentina

^e Massachusetts General Hospital, Neurology Department, Center for Genetic Research [CHGR], Boston, MA 02114, USA

ARTICLE INFO

Article history:

Received 28 April 2015

Received in revised form 29 April 2015

Accepted 5 May 2015

Available online 11 May 2015

Keywords:

Neuronal ceroid lipofuscinoses

Algorithm

Morphology

Enzymes

DNA variants

ABSTRACT

Background: The Argentinean program was initiated more than a decade ago as the first experience of systematic translational research focused on NCL in Latin America. The aim was to overcome misdiagnoses and underdiagnoses in the region.

Subjects: 216 NCL suspected individuals from 8 different countries and their direct family members.

Methods: Clinical assessment, enzyme testing, electron microscopy, and DNA screening.

Results and discussion: 1) The study confirmed NCL disease in 122 subjects. Phenotypic studies comprised epileptic seizures and movement disorders, ophthalmology, neurophysiology, image analysis, rating scales, enzyme testing, and electron microscopy, carried out under a consensus algorithm; 2) DNA screening and validation of mutations in genes *PPT1* (CLN1), *TPP1* (CLN2), *CLN3*, *CLN5*, *CLN6*, *MFSD8* (CLN7), and *CLN8*: characterization of variant types, novel/known mutations and polymorphisms; 3) Progress of the epidemiological picture in Latin America; and 4) NCL-like pathology studies in progress. The Translational Research Program was highly efficient in addressing the misdiagnosis/underdiagnosis in the NCL disorders. The study of “orphan diseases” in a public administrated hospital should be adopted by the health systems, as it positively impacts upon the family's quality of life, the collection of epidemiological data, and triggers research advances. This article is part of a Special Issue entitled: “Current Research on the Neuronal Ceroid Lipofuscinoses (Batten Disease)”.

© 2015 Elsevier B.V. All rights reserved.

1. Introduction

Neuronal ceroid lipofuscinoses (NCL), altogether the most common neurodegenerative disease in children, were sporadically recognized in Argentina before 2003. One publication of 1995 by Taratuto et al. [1]

Abbreviations: CL, curvilinear bodies; DBS, dried blood spots; EM, transmission electron microscopy; FP, fingerprint profiles; GRODs, granular osmiophilic deposits; LM, light microscopy; NCL, neuronal ceroid lipofuscinoses disorders; NGS, Next Generation Sequencing techniques; RL, rectilinear bodies; v, variant; WES, whole-exome sequencing

[☆] This article is part of a Special Issue entitled: “Current Research on the Neuronal Ceroid Lipofuscinoses (Batten Disease)”.

* Corresponding author at: CEMECO, Facultad de Ciencias Médicas, Universidad Nacional de Córdoba, Ferrovianos 1250, 5014 Córdoba, Argentina. Tel.: +54 351 4575974; fax: +54 351 4603628.

E-mail addresses: kohanromina@gmail.com (R. Kohan), favio.pesaola@gmail.com (F. Pesaola), nguelbert@arnet.com.ar (N. Guelbert), ppons@cmefcm.uncor.edu (P. Pons), ramirezoller@gmail.com (A.M. Oller-Ramírez), giselarautenberg@hotmail.com (G. Rautenberg), dra.adrianabecerra@hotmail.com (A. Becerra), sims@helix.mgh.harvard.edu (K. Sims), xin@helix.mgh.harvard.edu (W. Xin), ines.adriana.cismondi@unc.edu.ar (I.A. Cismondi), nclcemeco1789@gmail.com (I.N. de Halac).

collected the first data based on clinic and transmission electron microscopy (EM). The clinical cases from several Latin American countries have been reported (Table 1). The integrated NCL Program of Argentina allowed, during the past 12 years, the recognition of 122 new cases in the region, including patients from neighboring countries like Chile and Brazil and the complete characterization of 49 individuals. Mutations in these patients were identified in 7 of the 13 genes described worldwide [2]. The interdisciplinary approach included systematically the involved aspects of several medical and laboratory specialties, child neurology, ophthalmology, enzymology, pathology, and genetics using a consensus algorithm (Fig. 1). These integrated criteria consistently applied to the study of each NCL case were the clue for the success of the Translational Research Program. The presented algorithm was based and modified from the one published by Williams et al. (2012) [3] and Kohan et al. (2009) [4]. All the patients visiting our Hospital firstly received the clinical services and then, the electrophysiological and image studies were completed to assess compatibility with a NCL. The next step was to perform PPT1 and TPP1 enzyme activity assays in blood, saliva and DBS, followed by the electron microscopy

Table 1
NCL cohorts reported from Latin America (1995–2014).

Cases	Country	Diagnostic definition	Gene	References
30	Argentina	Clinical/EM	–	Taratuto et al. 1995 [1]
17	Brazil	Clinical/EM	–	Puga et al. 2000 [22]
13	Costa Rica	Molecular	<i>CLN6</i>	Gao et al. 2002 [23]
1	Venezuela	Molecular	<i>CLN6</i>	Gao et al. 2002 [23]
1	Argentina	Molecular	<i>CLN6</i>	Sharp et al. 2003 [24]
7	Argentina	Clinical/EEG	–	Caraballo et al. 2005 [25]
12	Brazil	Clinical/EM	–	Jardim et al. 2005 [26]
7	Venezuela	Clinical/EM	–	Peña et al. 2004 [27]
14	Chile	Clinical/EM	–	Troncoso et al. 2005 [28]
6	Mexico	Clinical/LM	–	Ruiz García et al. 2005 [29]
40	Argentina, Brazil, Chile, Paraguay, Perú, Spain	Clinical/EM/enzymatical/molecular	<i>PPT1 TPP1</i> <i>CLN3</i> <i>CLN5</i> <i>CLN6</i> <i>MFSD8</i> <i>CLN8</i>	Noher de Halac et al. 2005 [30], Kohan et al. 2008 [31], Kohan et al. 2009 [4], Cismondi et al. 2012 [6], Kohan et al. 2013 [32]
10	Brazil	Clinical/EM/molecular	<i>CLN3</i>	Valadares et al. 2011 [33]
9	Venezuela	Clinical/enzymatical	<i>TPP1</i>	Miranda Contreras et al. 2011 [34]

Abbreviations: EM, transmission electron microscopy; EEG, electroencephalogram; LM, light microscopy.

observation of a skin biopsy and the light-microscopically search for vacuolated lymphocytes. After that, if the criteria were compatible with a NCL, the screening for DNA variations related to these diseases was undertaken. Alternatively, we received inquiries from medical doctors established at distant regions of Argentina and sporadically from other Latin American countries; in those cases, laboratory samples were received by mail. The external patients were enzymatically studied, followed by the morphological and genetic approaches, according to the study algorithm (Fig. 1). Genetic counseling was performed in the hospital, or remotely mediated by the referring professionals. For the patients admitted in the NCL Program, the recommendation was a visit to the Hospital at least once each year.

Forty nine cases were positive for DNA variants validated as mutations in a known NCL gene. The DNA screening was done under a research protocol [5,6]. This methodology has emerged in recent years as a useful tool for NCL diagnosis and enhancing subtype classification [7–20]. Increasing recognition of variant phenotypes associated with specific NCL genetic etiologies challenges diagnosis based solely on clinical history or pathologic features. Thirteen NCL genetic forms have been described to date in different NCL disorders, with age at onset ranging from around birth to adult [3]. Mutations in different genes may cause similar phenotypes, and similar genetic mutations may give rise to variant phenotypic features. This makes difficult accurate candidate gene selection for direct sequencing [7]. Furthermore, it is

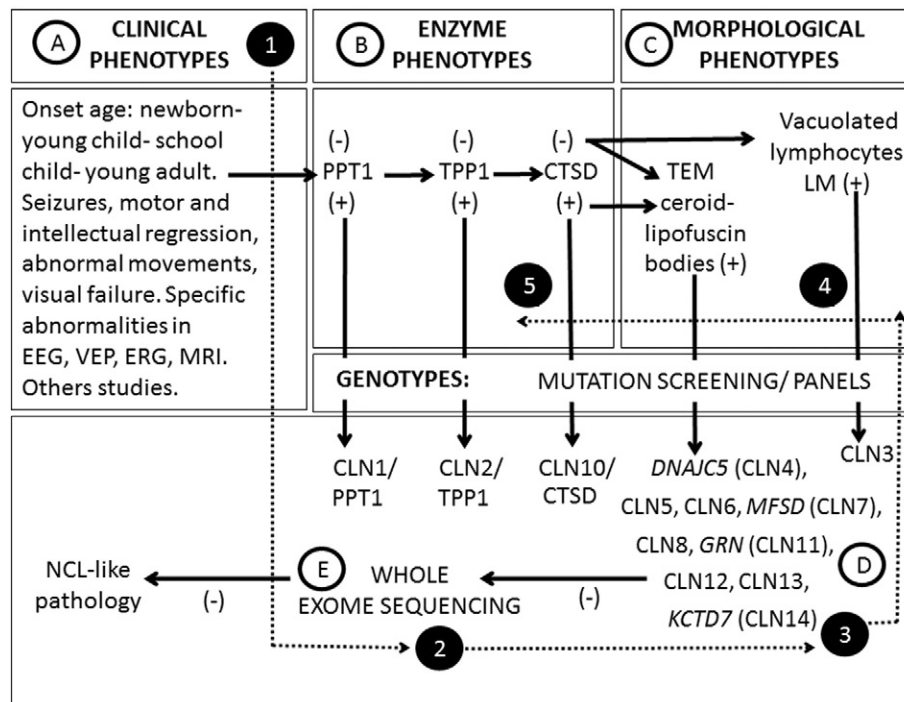


Fig. 1. Renewed diagnostic strategy proposed for the study of NCL in Latin America (modified from the one of Williams et al. 2012 [3], and Kohan et al. 2009 [4]). The algorithm starts with the study of the compatibility of the clinical phenotypes, using electrophysiological data, and image analysis, systematically followed by the PPT1 and TPP1 enzyme assays and the morphological analysis, and then by molecular studies to find the DNA variants of the patients and parents by Sanger sequencing (A–B–C–D). WES using available epilepsy and specific NCL panels were preliminary performed, but not in a systematic way (E). WES studies were performed in 4 patients according to the clinical compatibility, to set the genotypes (1–2–3). In one CLN2 case, the morphological analysis and the enzymatic assays were performed after WES, modifying the algorithm sequence from Williams et al. 2012; Kohan et al. 2009 (4–5).

estimated that ~8% of individuals diagnosed with NCL, by conservative clinical and histopathological criteria, have been ruled out for mutations in the known NCL-associated genes, suggesting that additional NCL genes remain unidentified [8].

In the remaining 73 individuals, clinical and electrophysiological data were considered compatible for a NCL, and they were enzymatically excluded for PPT1 and TPP1 deficiencies; the morphological studies also demonstrated the compatibility with a NCL (data not shown). However, at present they remain without a definitive molecular characterization because, in most of them, DNA variants related to the disease were excluded in several NCL genes by Sanger technology (*CLN3*, *CLN5*, *CLN6*, *MFSD8/CLN7* and *CLN8*), and are still awaiting a genotypic definition. The high economic resources needed for genotyping is a problem in this region, as these studies are frequently not covered by the social security. The genetic spectrum of these patients will be completed in the next step of the Translational Program through whole-exome sequencing (WES), under a research protocol. We excluded in the present paper the discussion of other 94/216 retrospective cases referred to our Program that remained without positive enzymological or electron microscopy data, and were not genotyped, or were diagnosed with other disease.

The extra value of a Translational Research Program on NCLs is that it integrates the complexity of these difficult to diagnose neurodegenerative diseases in one place offering the families advice and containment each time it is needed, favoring at the same time the accumulation of experience of the medical staff, the advance of the clinical and laboratory investigation, and allowing an epidemiological view of these diseases in our region. Few centers are able to perform such complex diagnostic studies in an integrated manner, even at an international level [21]. The patients frequently showed diagnostic delay due to the inexperience of child neurologists and other isolated professionals in remote locations of the countries, and the lack of awareness on these disorders. Another difficulty to cope was the high level of heterozygosity and the abundance of variant phenotypes in our countries due to the ethnic composition of the population, with mixed ancestors of diverse parts of the world and the autochthonous people of America.

2. Enzyme testing

To date, the known NCL forms have been associated to a protein in which mutations trigger the disease [35]. PPT1 (CLN1) [36], TPP1 (CLN2) [37], CTSD (CLN10) [38], and CTSF (CLN13) [13] are catalytic enzymes; CLN5 is a non-enzymatic lysosomal soluble protein [35];

pCLN3 seems to have a role related to the mitochondrial compartment [39]; MFSD8 (CLN7) is a lysosomal membrane transporter [40]; pCLN8 is related to the synthesis, transport or lipid modulation [41,42]; ATP13A2 (CLN12) is a transmembrane protein [43]; and the function of the other proteins remains unknown [35].

Knowing the role of a protein is important for research and diagnosis. First, it allows setting the protein in a metabolic context, which may be then studied to determine its relation with the disease. On the other hand, if we have substrate of an enzyme, protocols for enzymatic assays can be developed. Considering this last assumption, currently three soluble lysosomal enzymes can be tested for activity: PPT1 (CLN1) [44], TPP1 (CLN2) [4] and CTSD (CLN10) [45].

The cohort of patients and their parents studied in Argentina were systematically tested for PPT1 and TPP1 enzymatic activities in three tissues (as available): leukocytes (adapted from Sohar et al. [46,47]), saliva [48] and dried blood spots (DBS) (adapted from Lukacs et al. [49]). The integrity of each sample was verified by testing TPP1 and PPT1 in parallel assays. Briefly, the assays consisted in the incubation of the samples with the fluorogenic substrates 4-methylumbelliferyl 6-thio-palmitate- β -D-glucopyranoside (Santa Cruz Biotechnology, USA) for PPT1 or Ala-Ala-Phe-7-amido-4-methylcoumarin (Sigma, USA) for TPP1 at 37 °C during several hours (depending on the tissue). The fluorescence was measured on a LS 50 B fluorometer (Perkin Elmer, Waltham, MA, USA). Product formation was converted from fluorescent units to nanomol using 4-methylumbelliferyl (for PPT1) and 7-amino-4-methylcoumarin (for TPP1) calibrators. Leukocytes and saliva activities were standardized to protein concentration measured with Lowry method [50]. The population control's ranges were defined simultaneously for TPP1 and PPT1 in leukocytes, saliva and DBS in control samples from the local population (Table 2).

The standardization of the enzyme assays was performed in a statistically significant number of samples for both lysosomal enzymes. For this purpose, we used leukocytes, saliva and DBS from affected individuals, parents and population controls to carry out one or more repetitions in each sample to ensure the assay reproducibility. The box plot analysis [51] of all the data obtained in leukocytes, saliva and DBS for both enzymes, PPT1 and TPP1 are presented in Fig. 2. In DBS, the tendency of overlapped values between patients and controls is not in accordance to the provisional statement of Lukacs et al. [49]; whilst patients' diminished activities in leukocytes and saliva with respect to control's samples ($<3\times$ the standard deviation) demonstrated the greater accuracy of these techniques. Altogether, these results indicate TPP1 measurements in leukocytes and saliva having a greater sensibility

Table 2
Percentages of PPT1 and TPP1 activities in leukocytes, saliva and DBS in healthy controls and CLN1/CLN2 patient samples.

	PPT1			TPP1		
	Leukocytes ^a	Saliva ^b	DBS ^c	Leukocytes	Saliva	DBS
<i>Normal controls</i>						
n	86	110	139	100	117	243
Reference interval (RI)	6–67	64–494	0.34–2.18	62–368	92–476	0.10–0.81
Mean \pm SD	24 \pm 11	189 \pm 85	0.81 \pm 0.40	160 \pm 64	216 \pm 97	0.27 \pm 0.17
<i>CLN1 individuals</i>						
n	2	2	2			
Reference interval (RI)	0–2.26	0–56.4	0.01–0.26			
% from CR	0–9%	0–30%	1–33%			
<i>CLN2 individuals</i>						
n				24	23	28
Reference interval (RI)				0–9.82 [#]	0–31.9	0–0.26
% CR				0–6%	0–15%	0–100%*

Abbreviations: n, number of individuals tested; SD, standard deviation; RI, reference intervals.

^a Leukocytes: values are expressed in nmol/h/mg protein.

^b Saliva: values are expressed in nmol/24 h/mg protein.

^c DBS: values are expressed in nmol/spot.

[#] An extreme value of 15.85 nmol/h/mg protein was obtained in one patient. This value was not included in the statistic evaluation.

* 2/28 false negatives with values overlapping the mean value of the normal controls' range.

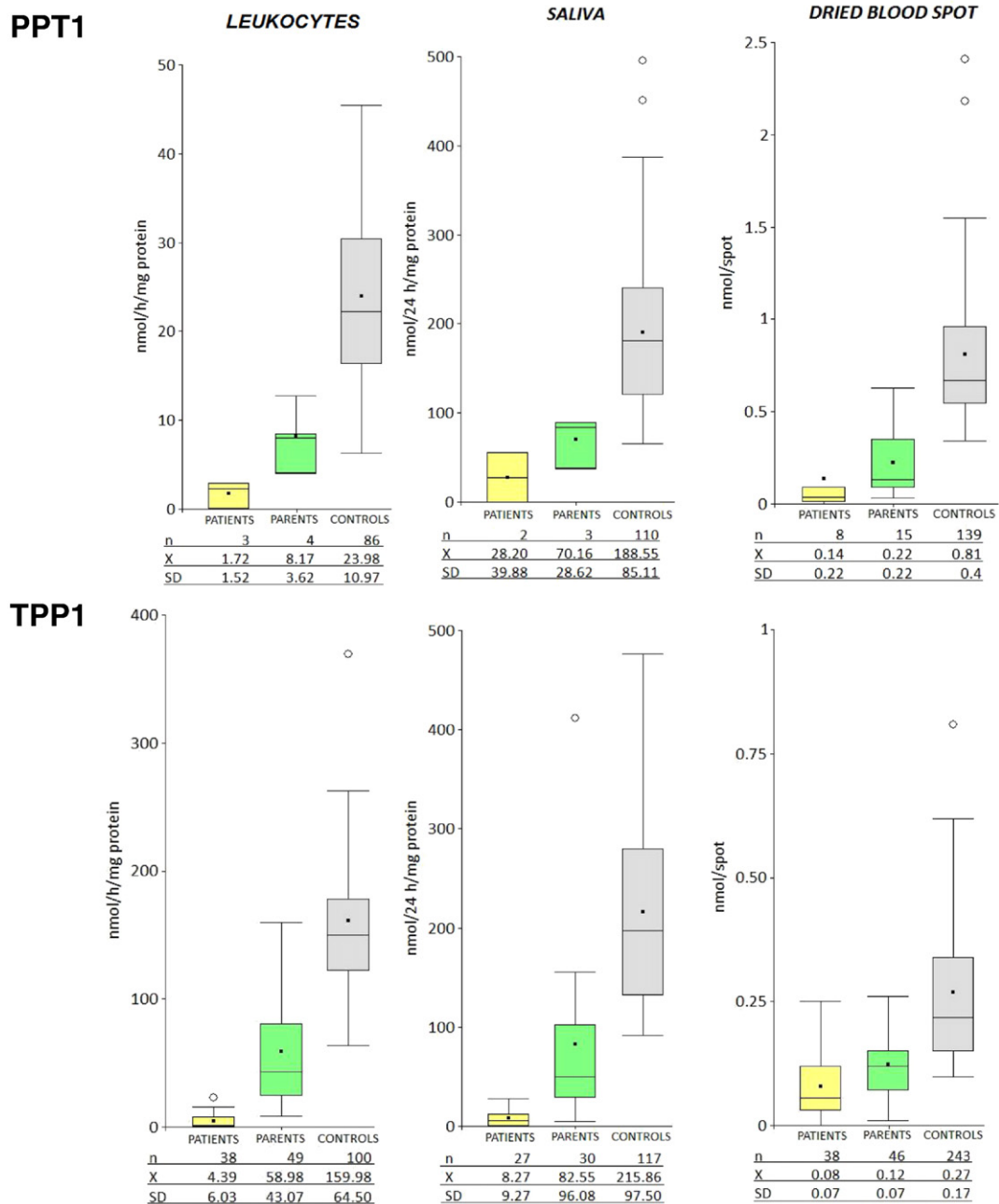


Fig. 2. Standardization process for PPT1 (upper panel) and TPP1 (lower panel) enzyme assays in biological samples from healthy controls, parents (obligated heterozygotes), and patients. The total number of determinations (n), the mean (\bar{x}) and 3 times the standard deviation (± 3 SD) are shown.

than in DBS. No technique allowed us to discriminate obligate heterozygous parent's activities, however, a general tendency to be lower than control's was noted (Fig. 2).

Two individuals showed PPT1 deficiency in leukocytes with percentages of activity respectively of 0 and 9% from the mean value of the control's range; in saliva and DBS, the same subjects showed an activity of 0 and 30%, and 1 and 33% respectively (Table 2). Noticeable is that the individual with 0% of activity in all the tested samples is a living boy now 21 years old with a juvenile phenotype [4,52] (Table 3). Because of the small number of patients, percentages of enzyme activities could not be valued regarding the correlation with phenotypes.

TPP1 activity was measured in samples from 32 CLN2 affected individuals, showing 0–6% activity of the mean of the normal controls in leukocytes, 0–15% in saliva, and 0–100% in DBS. Nine out of 28 (32%) TPP1 assays in DBS were considered false negative enzyme

results, with values overlapping the normal controls ranges (Table 2); although these negative TPP1 results in DBS, each patient was genetically characterized and both mutations were found in the *TPP1* gene (Table 3). It was assumed a deficient enzymatic TPP1 phenotype when the values were decreased in two different leukocyte samples of the same subject, or both in leukocytes and saliva, with percentages of activity ranging 0% to 15% from the mean of the population control's range, even when that deficiency was not reflected in DBS.

3. Electron microscopy

Transmission electron microscopy (EM) confirmed a presumed NCL disease when typical lipofuscin bodies were seen in skin biopsies: granular osmiophilic deposits (GRODs) in CLN1, curvilinear bodies (CL) in CLN2, and fingerprint profiles (FP) in CLN3 [4,6,32]. Variant

Table 3
Summary of the phenotypical variability and genotypes.

Gene/enzyme	No of patients (%)	Phenotypes/ (age at onset range) onset symptoms	Disease evolution	Pathology (EM)	Mutations
<i>PPT1/CLN1</i> PPT1 in leukocytes 0–2.26 (RI = 6–67 mg/h/prot)	n = 2 (4%)	CLN1 disease, juvenile, n = 2 (6–7 y) Learning difficulties, tonic clonic seizures, visual failure, ataxia, myoclonus.	EEG abnormal (6–11 y); MRI, cerebellar atrophy (9.6–10 y). Case 1, wheel chair bound, gastrostomy; current age, 21 y.	Mixed (CL + FP + GRODs), n = 1 nd, n = 1 ^a	I3, c.363-3T > G [62] E5, p.Arg151*
<i>TPP1/CLN2</i> TPP1 in leukocytes 0–9.82 (RI = 62–368 mg/h/prot.)	n = 32 (62.7%)	CLN2 disease, late infantile, n = 20 (2–4 y) Refractory epileptic syndrome, speech delay or loose, cognitive regression, ataxia, myoclonus. CLN2 disease, juvenile, n = 12 (5–10 y) Febrile seizures; hyperkinesia; behavioral disorders; language difficulties or delay; tonic-clonic seizures; visual failure; mental retardation; motor regression.	Tonic-clonic seizures (2–3.6 y); motor regression (2–9 y); intellectual delay (2.5–6 y); ataxia (3–10 y); language difficulties (3–11 y); EEG abnormalities (3–6.6 y); MRI with cerebellar and cerebral atrophy (3.3–11 y); VEP/ERG abnormalities (3.6–6.6 y); evolution time (11–17 y). Tonic-clonic seizures (5–11.3 y); motor regression (5–10 y); intellectual delay (5–12 y); VEP/ERG abnormalities (5–12 y); language difficulties (6–15 y); ataxia (6.6–13 y); EEG abnormalities (7–17 y); MRI with cerebellar and cerebral atrophy (9–16 y); evolution time (19–39 y).	CL, n = 11 FP, n = 2 Mixed (CL, GRODs +/- FP), n = 5 nd, n = 14 ^a	I1, c.17 + 3G > T [this publication] I2, c.89 + 5G > C [63] E3, p.Gln66* [54] E4, p.Leu104* [4,64] I5, c.509-1G > C [54] ^b E6, p.Arg208* [54] ^b E7, p.Asp276Val [4] I7, c.887-10A > G [65] E8, p.Arg339Gln [63] E8, p.Glu343Asp [this publication] E8, p.Arg350Trp [32] E9, c.1107-1108delITG [32] E11, p.Arg447His [54] E11, p.Ala453Val [4] E11, p. Ala453Asp [32] E11, p.Ser475Leu [54] E13, p.Gly535Arg [32] E6-7, p.[Gly154Alafs*29, Val155_Gly264del], del. 966 bp [66] ^b E6, p.Cys134Arg [63] E13, p.Arg334Cys [67] E14, p.Glu399* [63]
<i>CLN3</i>	n = 6 (11.6%)	CLN3 disease, juvenile, n = 6 (4–7 y) Visual loss, rapidly progressing to blindness secondary to a pigmentary retinopathy; intellectual decline.	Ataxia (5 y); generalized tonic-clonic seizures (4–10 y); VEP and ER conduction abnormalities (4–13 y); MRI with cerebellar atrophy (5–13 y); language difficulties (4–13 y); vacuolated lymphocytes.	FP + CL, n = 4 Atypical CL, n = 1 nd, n = 1 ^a	E1, c.291insC = p.Ser98Leufs*13 [69] E4, c.1002-1006delAACA = p.Lys368Serfs*15 [31]
<i>CLN5</i>	n = 2 (4%)	CLN5 disease, juvenile, n = 2 (2–4 y) Absence seizures; motor regression	Motor regression (2–6 y); intellectual regression (6 y); tonic-clonic seizures (6–7 y); MRI with cerebellar atrophy (6–8 y); abnormal EEG (7 y); visual failure (7–9 y); myoclonus (8–10 y) language difficulties (10 y).	Atypical CL (RL), n = 1 CL, n = 1 [68]	E1, c.291insC = p.Ser98Leufs*13 [69] E4, c.1002-1006delAACA = p.Lys368Serfs*15 [31]
<i>CLN6</i>	n = 2 (4%)	CLN6 disease, juvenile, n = 2 (2–3 y) Seizures; motor and psycho-intellectual regressions, followed by visual impairment.	Seizures (2–3 y); motor regression (2 y); language difficulties (3 y); EEG, abnormalities with paroxysms (3–4 y); mental regression (3.3 y); visual loss (3.3–7 y); myoclonus (4 y); MRI with cerebellar atrophy (4–6 y) and bilateral cerebral atrophy (5 y); ERG and VEP abnormalities (4.3 y); age at death, 15.6 y.	Densely packed FP or atypical CL, n = 2	E4, p.Arg103Trp [70] I4, c.486 + 8C > T [63] E6, c.552dupC = p.Phe185Leufs*17 [71] E7, p.Arg252His [63]
<i>MFSD8/CLN7</i>	n = 4 (7.7%)	CLN7 disease, juvenile, n = 3 (1.5–4 y) nd, n = 1 ^a Absence and tonic-clonic seizures; emotional disturbances.	Seizures (1.5–4 y); severe refractory epilepsy; generalized seizures and absences (7 y); speech disorder, mild global hypotonia, developmental and psychomotor retardation, obesity and frequent falls; abnormal MRI (hemispherical atrophy, thinning of the corpus callosum, extensive hypointense lesions on T1 and hyperintense on T2; 3.6–14 y); motor regression (3.3 y); mental regression (4 y) EEG with abnormalities (3.6–11 y); abnormal funduscopy (3.6 y). Severe hypotonia; language never developed; generalized tonic-clonic seizures (3 y); myoclonus (6 y); ataxia (6.6 y); MRI, cerebellar atrophy (6 y); age at death, 12.3 y.	Atypical CL (RL), n = 1 CL, n = 1 [68] FP, n = 2	E3, p.Arg35* [55,72] I2, c.63-4delC [72] E10, p.Thr294Lys [55,72] E13, p.Arg482* [55]
<i>CLN8</i>	n = 1 (2%)	CLN8 disease, congenital, n = 1 Psychomotor retardation (birth)	Twins; developmental delay; EEG with pathological features (2 y); abnormal MRI, VEP, and ER (5 y); altered visual behavior (6 y). Heparin-N-sulfatase and GAG analysis, in progress. Total NCL = 49 (+2 <i>SGSH</i>)	GRODs,FP + CL, n = 1	E2, p.Met1Val [73] E3, p.Asn264Lys [74]
<i>SGSH</i> (Differential diagnose in progress)	n = 2 (4%)	n = 2 (10 m) Refractory seizures		Atypical electron dense bodies n = 1 nd = 1	E2, p.His49Pro [this publication] E8, p.Val387Met [75]

Abbreviations: RI, reference intervals; y, years; m, months; °, no clinical data were available; EEG, electroencephalogram; MRI, magnetic resonance images; CL, curvilinear bodies; RL, rectilinear bodies; FP, fingerprint profiles; GRODs, granular osmiophilic deposits; nd, not done; E, exon; I, intron; b, bases.

^a EM was not performed because the contact with the family was lost, the family did not authorize the biopsy procedure, or because it is a brotherhood (in these cases, the morphological studies are done in only one of the siblings).

^b Most common European mutations.

morphologies were observed in the remaining genotypes. In Fig. 3, inclusions in skin or muscle of individuals with *CLN3*, *CLN5*, *CLN6*, *MFS8/CLN7* and *CLN8* genotypes are shown. A review of the morphological variations in the studied group of patients is presented in Table 3. There were no diagnosed cases included in this review where typical storage was looked for but not seen.

4. Genotypes/phenotypes

DNA variations were studied by PCR followed by Sanger sequencing, or through WES technology according with the concordance of the clinical, enzymatic and morphological features with those of the published literature, with special attention to electron microscopy

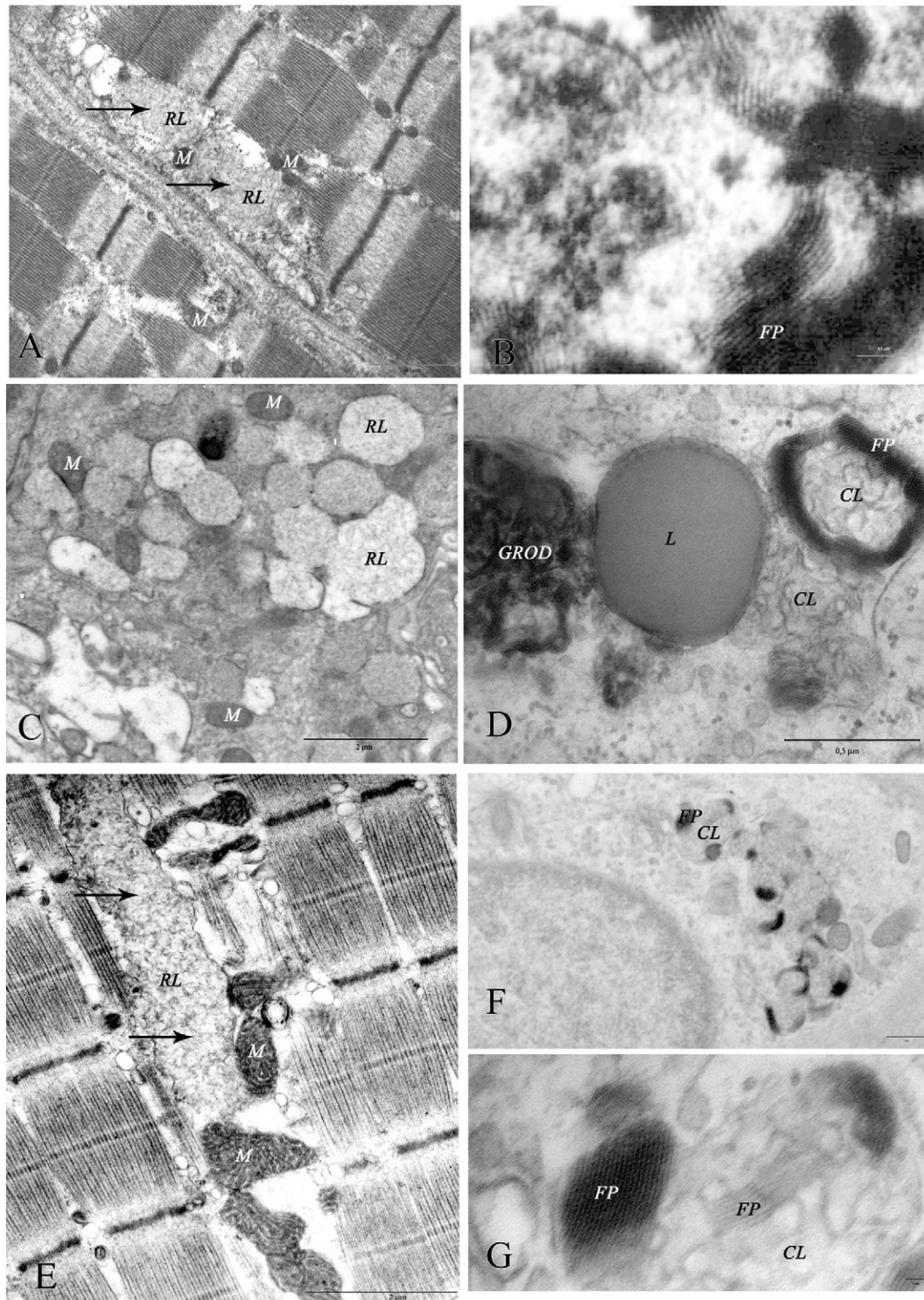


Fig. 3. Electron microscopy results. A. *CLN5* disease, juvenile: muscle biopsy showing RL (arrows) (courtesy of A. L. Taratuto). B. *CLN6* disease, juvenile: muscle biopsy showing densely packed FP (courtesy of A. L. Taratuto). C. *CLN7* disease, juvenile: skin biopsy showing vesicles with RL in an eccrine secretory gland. D. *CLN8* disease, congenital: skin biopsy with GRODs, CL and FP neighboring a lipid droplet (L). E. *CLN3* disease, juvenile: muscle biopsy showing CL predominantly at the subsarcolemmal compartment (arrow); notice the enlarged mitochondria (M) (courtesy of A. L. Taratuto). F. *CLN3* disease, juvenile: skin biopsy with mixed FP and CL in an eccrine sweat gland. G. *CLN3* disease, juvenile (detail of F): mixed FP + CL bodies. Abbreviations: CL, curvilinear bodies; RL, rectilinear bodies; FP, fingerprint profiles; GRODs, granular osmiophilic deposits; M, mitochondrion; L, lipid droplet.

data useful to orient the search of the NCL genes [53] (Table 3). However, in one case WES was carried out before electron microscopy and enzyme testing, being inconclusive because only one *TPP1* mutation was found (exon 6- p.Arg208*) [54]. This child was corroborated later as *TPP1* deficient, with an electron microscopy showing CL in the skin biopsy; the second *TPP1* mutation remains elusive. Another case with positive electron microscopy data showing CL in a muscle biopsy, and *TPP1* and *PPT1* enzyme values in the control's range, was efficiently stated as *CLN7* using WES, which showed one homozygous known mutation (exon 3- p.Arg35*) [55], segregating from the parents.

The new DNA variants were validated as disease causing mutations by a combination of methods that included: direct Sanger sequencing in a new DNA sample, restriction enzymes, co-segregation within the families, absence of the sequence change in 200 control alleles, and bioinformatic tools: ClustalW2 program (<http://www.ebi.ac.uk/Tools/clustalw2/index.html>), UniproKw (<http://www.uniprot.org>), Polymorphism Phenotyping-2 (PolyPhen-2, <http://genetics.bwh.harvard.edu/pph2>), Sorting Intolerant from Tolerant (SIFT, <http://sift.jcvi.org>), PopMusic 2.1 (<http://babylone.ulb.ac.be/popmusic>), Pongo server (<http://www.hsls.pitt.edu/obrc/index.php?page=URL1153413945>), Phobius (<http://phobius.sbc.su.se/>), ESEfinder (http://rulai.cshl.edu/cgi-bin/tools/ESE3/ese_finder.cgi?process=home), PMut (<http://mmb2.pcb.us.es:8080/PMut/>), Protein Data Bank (PDB, <http://www.rcsb.org/pdb/home/home.do>) and PyMOL version 1.1 (<http://www.pymol.org>). The combination of the results obtained through all these studies was used to validate the DNA missense changes as disease causing mutations in the studied CLN genes (data not shown). DNA variants were excluded as disease causing mutations if they were mentioned as SNPs in the database <http://www.ncbi.nlm.nih.gov/snp/>. Known NCL mutations were found in the international database, <https://www.ucl.ac.uk/ncl/mutation.shtml>.

Seventy three banked DNA samples still remain genetically uncharacterized and require analysis and molecular screening; this will be done under a systematic WES research protocol using a NCL panel including *PPT1/CLN1*, *TPP1/CLN2*, *CLN3*, *CTSD/CLN10* [56,57], *DNAJC5/CLN4* [17], and the most recently NCL associated genes: *CLN11/GRN* [58], *CLN12/ATP13A2* [43], *CLN13/CTSF* [59,60], *KCTD7/CLN14* [8], and *CLCN6* [61]. As variant clinical phenotypes are increasingly recognized in the NCL disorders, it is difficult to exclude specific genetic loci based on pathologic data. The lack of available clinical functional studies to support specific diagnosis means that complete NCL panel molecular genetic analysis is warranted. These studies are in progress.

DNA disease related variants were found in 49/122 NCL individuals, and both pathological alleles were identified in 40. One pathological allele is still unknown in 1 *CLN3*, and 2 *MFSD8/CLN7* suspected patients, all of them with clinical and microscopically compatible data. One *PPT1* and 5 *TPP1* deficient individuals are waiting the confirmation of the DNA changes. All the missing genetic studies are currently in progress. The phenotypic spectrum and the DNA variants found in 7 different NCL genes are summarized in Table 3.

5. Discussion and concluding remarks

A NCL Translational Research Program has great value in assisting, from an interdisciplinary scope, with clinical and molecular characterization and subsequent clarification of misdiagnosis and establishment of diagnosis. The study of "rare diseases" in a public administrated hospital should be adopted by the health systems, as the impact on patient and family quality of life, the collection of epidemiological data, and potential for research enrollment and advance are highly significant.

The regional genotypes and phenotypes can be compared with European and US published cohorts [67,76]. With the exception of *PPT1* and *TPP1* [4,32], the molecular data of this paper reflect new published results for the other genotypes. Additional data on DNA variants throughout the world are compiled at <https://www.ucl.ac.uk/ncl/mutation.shtml>. A total of 34 mutations were identified in 7 NCL

genes: missense (n = 16), nonsense (n = 6), splice site (n = 7), small/large deletions (n = 3), and insertions/duplications (n = 2). From these, 14 mutations were novel (41%), and 20 were previously reported in other countries (59%). Complex heterozygosity predominated in our cohort of patients in all the studied genes. Correlations between compound heterozygosity and protracted phenotypes were described for many NCL forms [32,77–79].

Information on the actual incidence and prevalence of childhood NCL is based mainly on data gathered from clinical and morphological studies conducted in the pre-genetic era [80–86]. Over the past 10 years, the use of molecular genetics to corroborate clinical diagnoses has made it possible to obtain more accurate epidemiological data on the NCLs, which have been shown to have a worldwide distribution [87,88]. Moreover, some studies seem to indicate a higher-than-expected incidence in specific geographical regions [89,90]. The relative incidence of childhood forms of NCL in Italy and the phenotypic spectrum related to mutations in known NCL genes was investigated [87]. Descriptive epidemiology data, collected through the application of shared clinical and morphological diagnostic criteria and direct gene sequencing of eight known NCL genes, reveal an incidence rate of 0.98/100,000 live births in the period 1992–2004. This figure is 58% higher than that recorded in the pre-genetic era [81]. The incidence rate of NCLs in Italy was still found to be lower than in other European countries where epidemiological investigations were recently performed [90,91]. In Italy, LI-NCL appear to be the most frequent forms, accounting for an incidence of 0.78/100,000 live births. About half of the cohort had a genetic diagnosis of LI-NCL, the single most affected gene being *TPP1*. High frequencies of LI-NCL and *TPP1* mutations have been reported in only two studies, carried out in restricted geographic areas, namely British Columbia [92] and Newfoundland [89], respectively. In the latter study, LI-NCL patients mutated in *CLN5* and *CLN6* accounted for 26% of the whole LI-NCL population. Molecular findings in 124 NCL patients according to both clinical form and mutated gene in the Italian population [57,87,93] showed *CLN1* (13.7%), *CLN2* (23.5%), *CLN3* (12.9%), *CLN5* (5.6%), *CLN6* (16.9%), *CLN7* (11.3%), *CLN8* (5.6%), *CLN10* (0.8%) and about 10% of the NCL cases in this survey remained without a genetic diagnosis as shown elsewhere [57, 93]. The genetic studies in Argentina stated that *CLN2* is the most common NCL type, accounting for a 65.3% of the diagnosed subjects, followed by *CLN3* (12.2%) and *CLN7* (8.2%). The molecular studies rendered a total of 17 *TPP1* mutations in Latin America, from which 47% were world-wide known mutations and 53% were novel for this region. The most common mutations identified in *TPP1* gene are p.Asp276Val exon 7 (30.5% of disease alleles), p.Arg208* exon 6 (12.5% of disease alleles), and c.887-10A > G intron 7 (10.8% of disease alleles). To simplify the future genetic analysis of *TPP1*-deficient patients in our region, we might consider ruling out E7 p.Asp276Val, I7 c.887-10A > G, E6 p.Arg208*, E3 p.Gln66* and E4 p.Leu104* before starting costly complete *TPP1* screening. At present, these five most common Latin American mutations comprise 64.8% of the detected pathological alleles [32].

Rare Diseases epidemiology is a novel action field still largely unexplored. The rare disease community suffers from the absence of reliable epidemiological data on the prevalence and incidence of rare diseases in the national and global populations [94].

The application of a unified algorithm and the centralization of all the diagnostic steps in one center were the main factors underlying the success of the Argentinean NCL Program. The pathological features assayed by LM and EM were characterized and differentiated for congenital-onset NCL, infantile-onset NCL, "classical" and "variant" late infantile-onset NCL and for juvenile-onset NCL phenotypes with variant genotypes. In one case, it oriented other differential diagnostic activities with MPS Type IIIA. Coincidences were found regarding the morphology of the bodies in the pathological poorly or incompletely known NCL forms (*CLN5*, *CLN6*, *CLN7*, and *CLN8*) with the statements of Radke et al. [53].

5.1. CLN1 disease, juvenile

Two CLN1 subjects were enrolled in the NCL program since 2003. Another 7 Mexican patients showed PPT1 deficiency measured only in DBS, and the study could not be completed [4]. In the first case, the boy from Brazil showed a juvenile phenotype with PPT1 deficiency in leukocytes (0 nmol/h/mg protein for a normal range: 6–67). The second case, an Argentinean girl, was not seen again and did not complete all the requested exams. She showed PPT1 activity in leukocytes of 2.26 nmol/h/mg protein. The CLN1 index case was genetically studied, and he showed a compound heterozygotic combination of the nonsense mutation exon 5- p.Arg151*, the most common variant worldwide [2,62], and intron 3- c.363-3T > G, a South American splice site mutation—seen for the first time in this individual [4]. Present age is 21 years old.

5.2. CLN2 disease, late infantile and juvenile

Both complete and partial TPP1 deficiencies were documented. Residual TPP1 activity was demonstrable in leukocytes and saliva, but not in DBS (Table 2). CLN2 disease, juvenile variant phenotypes were more frequently described than expected through the literature (37.5% of the cases), in several cases correlating with residual TPP1 enzyme activity, especially when measured in blood or saliva [4,32]. The heterozygous combination of intronic mutations in non-consensus sites with missense/nonsense mutations correlated with the residual TPP1 activity [32]. Correlations of CLN2 phenotypes in relation to the amount of TPP1 deficiency are reviewed: 1) CLN2 disease, late infantile: “classical or severe” phenotype was stated in individuals with undetectable TPP1 activity in leukocytes, saliva and DBS [32]; 2) CLN2 disease, juvenile: slightly, to significantly “later-onset” phenotype was stated in individuals with a 10–15% of control mean TPP1 activity in leukocytes [32]; 3) CLN2 disease, adult: ataxia (SCAR7), a later-onset and more restricted phenotype, with no ophthalmologic abnormalities or epilepsy, showed a considerable overlap in enzyme activity with CLN2 disease patients (values in SCAR7 patient's leukocytes correlated with a mean residual activity ranging from 10 to 15% of the lowest control TPP1 activity in Sun Y et al. 2013 [11]). In one Australian ‘later-onset’ case (CLN2 disease, adult) the measured TPP1 activity in leukocytes was ~2% of mean normal activity, which is very similar to that observed in Australia for CLN2 disease, late infantile patients; the clinical presentation was totally consistent with that reported for SCAR7, but it is not clear why the residual activity measured is so low (Dr. Michael Fietz, Adelaide—Australia, personal communication). One 11 y old US girl also presented with SCAR7 phenotype (CLN2 disease, adult); a partial TPP1 deficiency was detected in both blood and fibroblasts. EM results were inconclusive. WES by NGS was performed, allowing the identification of one common mutation in *TPP1* (intron 5- c.509-1G > C) and a novel mutation, exon 8- p.Glu343Asp (KS, Boston). However, on looking at the published cases, it appears that some of the SCAR7 individuals also showed very low levels of TPP1 leukocyte activity; and 4) variations in TPP1 activities correlated with variant phenotypes in CLN2 knock-out mice [95].

5.3. CLN3 disease, juvenile

This is the second most frequent NCL type [6], with 6 identified patients. 3/6 children carry the p.[Gly154Alafs*29, Val155_Gly264del] or 966 base pair (bp) deletion mutation in homozygous state; the other 2/6 had this deletion in heterozygous combination with two Argentinean *CLN3* DNA variants, exon 6- p.Cys134Arg and exon 13- p.Arg334Cys. Finally, 1/6 showed a nonsense mutation exon 14- p.Glu399*, with the second allele remaining elusive. The *CLN3* DNA variants are listed in the database <https://www.ucl.ac.uk/ncl/mutation.shtml>, and in Kousi et al. [63]. Ultrastructural features are shown in Fig. 3E–G. Summarizing data of the Argentinean group of patients

with CLN3 disease, 50% of subjects carry the most common deletion in homozygous state, 33.4% are heterozygous for this deletion in combination with other “rare” *CLN3* variants, and 16.7% is identified with single “rare” *CLN3* DNA variant (no second *CLN3* mutation identified). In Great Britain and the US [5,49,63], CLN3 disease, juvenile reports showed prevalence of homozygous individuals for the most common 966 bp deletion in ~75%, with greater than 90% having at least a copy of this common mutation.

5.4. CLN5 disease, juvenile

DNA variants in *CLN5* were found in 2 girls in combination with a complete clinical and pathological characterization. Both individuals had juvenile phenotypes and positive ultrastructural data, with atypical CL—called rectilinear bodies, RL by Radke et al. [53]—in the muscle biopsy of one Argentinean girl (Fig. 3A). By Sanger sequencing a unique insertion (homozygous) was identified in the Argentinean girl: exon 1- c.291insC, p.Ser98Leufs*13 [69]; in addition, it was also found a presumed polymorphism in *CLN6* intron 2: c.198+104T > C. Whether this *CLN6* polymorphism may alter phenotypic expression remains unproven. In the second case, a girl from Spain, it was stated a deletion, exon 4- c.1002-1006delAACA, p.Lys368Serfs*15 in homozygosity [31]. The Spanish girl was not seen in Argentina, but the DNA variant was found in the frame of our Translational Program and published by the Spanish group [31,68].

5.5. CLN6 disease, juvenile

Two CLN6 cases were studied through our Program, a boy and a girl. Both showed juvenile phenotypes and FP profiles were seen by EM (Fig. 3B). The variant clinical presentations in these two CLN6 cases did not provide evidence of genetic and allelic heterogeneity accompanying intra-familial variability [24], because only 1 member was affected in these two unrelated CLN6 families from Argentina. Sanger sequencing demonstrated in the girl two *CLN6* variants: exon 7- p.Arg252His and c.486 + 8C > T (exon/intron 4, rs149692285), predicted as probably damaging and aberrant splicing respectively by computational approaches (p.Arg252His: ClustalW2, conserved among *Pan troglodytes*, *Macaca mulatta*, *Rattus norvegicus*, *Mus musculus*, *Bos taurus*, *Canis lupus familiaris*, *Gallus gallus* and *Danio rerio*; SIFT, tolerant; Pongo server and Phobius, cytoplasmic region; PolyPhen-2, possibly damaging; ESEFinder, altered splicing modifiers; PMut, pathologic). One polymorphism was detected in the same gene, c.198 + 104T > C (rs8025947) [63]. Age at death was 18 y. The boy's DNA was analyzed through Sanger sequencing and compound heterozygosity for two different South American variants were stated: exon 4- p.Arg103Trp and exon 6- p.Phe185Leufs*17 [70,71]. The age at death was 13 years. Mutations in *CLN6* gene seem to be family specific.

5.6. CLN7 disease, juvenile

The first Argentinean CLN7 confirmed case is a boy, currently 5 years old, of unknown migrant and American Indian Guarany ancestors. Genotyping was through WES using a NCL panel, after rendering normal PPT1 and TPP1 enzyme activities, and EM observation of typical CL profiles in the muscle biopsy. The confirmation of the DNA variants in the *MFSD8/CLN7* gene was through segregation in the same family and Sanger sequencing, showing a known homozygous variant, exon 3- p.Arg35* [55,72]. Other two Argentinean boys were suspected as CLN7 cases, remaining genetically unconfirmed. The first of them with Eastern European ancestry showed one DNA change, intron 2- c.63-4delC segregating from the mother. This change was previously identified, also in heterozygous form, in a patient of Polish origin. Although this intronic change was studied by the authors with RT-PCR and it was absent in 200 control chromosomes, it remains open whether it is a disease-associated mutation or a rare non-pathogenic polymorphism

[72]. The second, with Italian-Spanish ancestry, showed one nonsense mutation, exon 13– p.Arg482* known before in one French subject [55]. In another Spanish girl from the Balears Islands, MFSD7/CLN7 was suspected, and the most frequent missense mutation exon 10– p.Thr294Lys was found in heterozygosity. The case was published elsewhere [55,72]. The suspicion of MFSD8/CLN7 was sustained in the Argentinean cases based on clinical and electron microscopy data. All patients showed childhood onset (ages 1.5–4 y). Interesting peculiarities are that visual failure was a later symptom, and none had ataxia or other movement abnormalities. EM showed in the 2 unconfirmed cases, a variant of CL profiles in the skin biopsy (Fig. 3C). These clinical and pathologic features may prompt consideration of CLN7 disease, particularly in this South American region.

5.7. CLN8 disease, congenital

One Argentinean girl with onset at birth and a life span of 12 years, is the first confirmed CLN8 case in Latin America, and the first congenital phenotype described worldwide. The ultrastructure with GRODs, CL and FP profiles is shown in Fig. 3D. Sanger sequencing of CLN8 showed two DNA changes in heterozygous state, exon 2– p.Met1Val (rs143730802) was previously identified in heterozygous state in one patient of African descent, with a general frequency of less than 0.01% [73]. The other DNA variant, exon 3– p.Asn264Lys (rs587779411) was previously identified in homozygous state in an Iberian patient [74]. Both were predicted as deleterious DNA changes by computational approaches (PolyPhen-2 and SIFT software predicted them as “probably damaging” and “damaging”, respectively). Moreover, the polymorphisms c.257G > C (rs71499040) and c.280_279insG (rs71209699) in exon 1 were also found in Argentinean patients.

5.8. Differential diagnoses

SGSH mutations were mentioned in the literature in a patient who was diagnosed with adult onset NCL [96]. In this same issue the article of Radke et al. [53] calls attention to the differential diagnose among MPS type III A, Sanfilippo Syndrome and NCL. The onset age in a pair of Argentinean twins was at 10 months with refractory seizures, followed by developmental delay. EEG was pathological (2 years). MRI, VEP, and ERG were normal at the age of 5 years. By 6 years, altered visual behavior was observed. PPT1 and TPP1 were normal. EM of a skin biopsy showed atypical osmiophilic bodies. WES studies were performed (INDEAR/Bioceres, Santa Fe, Argentina) and revealed in one of the twins the presence of two heterozygous DNA variants, exon 8– p.Val387Met [75] and the novel missense change exon 2– p.His49Pro in the SGSH gene (Mucopolysaccharidosis IIIA, Sanfilippo Syndrome) (Table 3). Sulfamidase studies in blood, heparin sulfate and GAG analysis in urine are in progress.

5.9. Whole exome sequencing in NCL disease

As an example of the power of the WES screening approach, using a recessive model to filter the identified variants, a KCTD7/CLN14 homozygous variant, c.550C > T, p.Arg184Cys was identified in a Mexican family with infantile-onset NCL [8]. The mutation was predicted to be deleterious and was absent in over 6000 controls. The identified variant altered the localization pattern of KCTD7 and abrogated interaction with cullin-3, a ubiquitin-ligase component and known KCTD7 interactor. Intriguingly, murine cerebellar cells derived from a juvenile NCL model (CLN3) showed enrichment of endogenous KCTD7. Whereas KCTD7 mutations have previously been linked to progressive myoclonic epilepsy, with or without lysosomal storage, this study clearly demonstrated that KCTD7 mutations also cause a rare, infantile-onset NCL subtype (designated CLN14) [8,9].

WES can be remarkably helpful in identifying genetic disorders, but as a technology at the current time there are limitations reflecting depth

of coverage and gaps in sequencing that may yield false negative results in any particular patient and/or within some specific genes. The expenses may be warranted, but focused NCL-panel testing, with technologies which allow for complete nucleotide coverage, may offer best and most cost-effective strategies for testing those in whom the phenotype suggests possible NCL disorder (seizures, visual failure, cognitive regression, ataxia/movement abnormalities). In the next step of the Translational Research Program 25/73 banked DNA samples that remain genetically uncharacterized will undergo molecular screening under a specific NCL directed WES protocol.

In conclusion, in previous papers of our group the main features of the two types of NCL with enzyme deficiencies, CLN1 disease and CLN2 disease, were published [4,32]. The review of these results, and the data of other 5 NCL types, CLN3 disease, CLN5 disease, CLN6 disease, CLN7 disease, and CLN8 disease are presented in this paper. The phenotypes were late infantile, or juvenile except CLN8, that was congenital with severe infantile phenotype. The subjects showed known and new mutations, and family specific DNA variants. Clinical features and electron microscopy data were stated for each type (Table 3). The aggregate value of a Translational Research Program with focus on NCLs in a public hospital is the systematic use of a unified study algorithm; the education of practitioners that become expertise in recognizing these difficult to diagnose diseases and manage the symptoms; the integration with clinical research; and having a site with a staff that can provide advice and contention to the families each time they need. An epidemiological view is gradually developed. In our future work we intend to reveal the DNA variants of the still genetically uncharacterized individuals in the frame of the study algorithm (Fig. 1).

Conflicts of interest

We declare no conflicts of interest.

Transparency document

The Transparency document associated with this article can be found, in the online version.

Acknowledgments

We kindly acknowledge the NCL families from Latin America, the personnel of the Centro de Estudio de las Metabolopatías Congénitas (CEMECO) at the Children’s Hospital, Córdoba–Argentina, and the National University Córdoba. We thank the Science and Technology Organizations that provided grant support to our research: Argentinean National Research Council (CONICET-RA: PIP 6185-2005, PIP 112-2011), Secretary of Science and Technology of the National University Córdoba (SECYT-UNC: 05/J155, 05/H295, 05/J079), Ministry of Science and Technology from the Province of Córdoba (MENCYT: PID 2009), NIH (Fogarty Program “Brain Disorders in the Developing World”: 1R21TW008433-01), and Batten Disease Support and Research Association (BDSRA-US: years 2001-2002-2003-2005-2006). We thank Michael Fietz from Australia for the comments on his SCAR7 patient, Ana Lía Taratou from Argentina for her contribution with EM photographs, and all the colleagues that derived patients and samples for study, from Chile (Mónica Troncoso, Sacarlett Witting, Gloria Duran), Brazil (Roberto Giugliani, Marta Regina Clivati), Mexico (Sandra Nieto-Martínez, Matilde Ruiz-García), Uruguay (Roberto Quadrelli), Colombia (Liseth Cabarcas Castro), Argentina (Raquel Dodelson de Kremer, María del Rosario Aldao, Liliana Czornyj, Alejandra Visich, Ana María Guercio, Mercedes Villanueva, Santiago Sfaello, Hugo Arroyo, Rosana Ocampo, Gabriel Vazquez, Soledad Monges, Ines Denzler, Laura Cassar, Silvia Tenembaun, Marcela Pereyra, Griselda Ray, Fernanda Garro, Ricardo Fauze, and other neuropediatricians and clinical geneticists, residents and fellows of our country).

References

- [1] A.L. Taratuto, M. Saccoliti, G. Sevlever, V. Ruggieri, H. Arroyo, M. Herrero, et al., Childhood neuronal ceroid-lipofuscinoses in Argentina, *Am. J. Med. Genet.* 57 (1995) 144–149, <http://dx.doi.org/10.1002/ajmg.1320570207>.
- [2] V. Warriar, M. Vieira, S.E. Mole, Genetic basis and phenotypic correlations of the neuronal ceroid lipofuscinoses, *Biochim. Biophys. Acta* 1832 (2013) 1827–1830, <http://dx.doi.org/10.1016/j.bbdis.2013.03.017>.
- [3] R.E. Williams, S.E. Mole, New nomenclature and classification scheme for the neuronal ceroid lipofuscinoses, *Neurology* 79 (2012) 183–191, <http://dx.doi.org/10.1212/WNL.0b013e31825f0547>.
- [4] R. Kohan, I.A. Cismondi, R. Dodelson de Kremer, V.J. Muller, N. Guelbert, V. Tapia Anzoloni, et al., An integrated strategy for the diagnosis of neuronal ceroid lipofuscinoses types 1 (CLN1) and 2 (CLN2) in eleven Latin American patients, *Clin. Genet.* 76 (2009) 372–382, <http://dx.doi.org/10.1111/j.1399-0004.2009.01214.x>.
- [5] R. Kohan, Caracterización morfológica, bioquímica y molecular de las Lipofuscinoses Ceroideas Neuronales Tipos CLN1 y CLN2 en pacientes argentinos con proyección hacia Latinoamérica, Escuela de Graduados en Ciencias de la Salud. Facultad de Ciencias Médicas, Universidad Nacional de Córdoba, 2011.
- [6] I.A. Cismondi, Estudio Integral de las Lipofuscinoses Ceroideas Neuronales Genotipos CLN3, CLN5, CLN6, CLN7 y CLN8 en familias de Latinoamérica, Escuela de Graduados en Ciencias de la Salud. Facultad de Ciencias Médicas, Universidad Nacional de Córdoba, 2012.
- [7] L.C. Patiño, R. Battu, O. Ortega-Recalde, J. Nallathambi, V.R. Anandula, U. Renukaradhya, et al., Exome sequencing is an efficient tool for variant late-infantile neuronal ceroid lipofuscinoses molecular diagnosis, *PLoS One* 9 (2014) e109576, <http://dx.doi.org/10.1371/journal.pone.0109576>.
- [8] J.F. Staropoli, A. Karaa, E.T. Lim, A. Kirby, N. Elbalalesy, S.G. Romansky, et al., A homozygous mutation in KCTD7 links neuronal ceroid lipofuscinoses to the ubiquitin–proteasome system, *Am. J. Hum. Genet.* 91 (2012) 202–208, <http://dx.doi.org/10.1016/j.ajhg.2012.05.023>.
- [9] P. Van Bogaert, R. Azizieh, J. Désir, A. Aebly, L. De Meirleir, J.-F. Laes, et al., Mutation of a potassium channel-related gene in progressive myoclonic epilepsy, *Ann. Neurol.* 61 (2007) 579–586, <http://dx.doi.org/10.1002/ana.21121>.
- [10] D.M. Andrade, T. Paton, J. Turnbull, C.R. Marshall, S.W. Scherer, B.A. Minassian, Mutation of the CLN6 gene in teenage-onset progressive myoclonus epilepsy, *Pediatr. Neurol.* 47 (2012) 205–208, <http://dx.doi.org/10.1016/j.pediatrneurol.2012.05.004>.
- [11] Y. Sun, R. Almomani, G.J. Breedveld, G.W.E. Santen, E. Aten, D.J. Lefeber, et al., Autosomal recessive spinocerebellar ataxia 7 (SCAR7) is caused by variants in TPP1, the gene involved in classic late-infantile neuronal ceroid lipofuscinoses 2 disease (CLN2 disease), *Hum. Mutat.* 34 (2013) 706–713, <http://dx.doi.org/10.1002/humu.22292>.
- [12] T. Arsov, K.R. Smith, J. Damiano, S. Franceschetti, L. Canafoglia, C.J. Bromhead, et al., Kufs disease, the major adult form of neuronal ceroid lipofuscinoses, caused by mutations in CLN6, *Am. J. Hum. Genet.* 88 (2011) 566–573, <http://dx.doi.org/10.1016/j.ajhg.2011.04.004>.
- [13] K.R. Smith, H.-H.M. Dahl, L. Canafoglia, E. Andermann, J. Damiano, M. Morbin, et al., Cathepsin F mutations cause Type B Kufs disease, an adult-onset neuronal ceroid lipofuscinoses, *Hum. Mol. Genet.* 22 (2013) 1417–1423, <http://dx.doi.org/10.1093/hmg/ddt558>.
- [14] N. Dolzhanskaya, M.A. Gonzalez, F. Sperziani, S. Stefl, J. Messing, G.Y. Wen, et al., A novel p.Leu(381)Phe mutation in presenilin 1 is associated with very early onset and unusually fast progressing dementia as well as lysosomal inclusions typically seen in Kufs disease, *J. Alzheimers Dis.* 39 (2014) 23–27, <http://dx.doi.org/10.3233/JAD-131340>.
- [15] M. Velinov, N. Dolzhanskaya, M. Gonzalez, E. Powell, I. Konidari, W. Hulme, et al., Mutations in the gene DNAJC5 cause autosomal dominant Kufs disease in a proportion of cases: study of the Parry family and 8 other families, *PLoS One* 7 (2012) e29729, <http://dx.doi.org/10.1371/journal.pone.0029729>.
- [16] R. Ehling, L. Nosková, V. Stránecký, H. Hartmannová, A. Přistoupilová, K. Hodaňová, et al., Cerebellar dysfunction in a family harboring the PSEN1 mutation cosegregating with a cathepsin D variant p.A58V, *J. Neurol. Sci.* 326 (2013) 75–82, <http://dx.doi.org/10.1016/j.jns.2013.01.017>.
- [17] L. Nosková, V. Stránecký, H. Hartmannová, A. Přistoupilová, V. Barešová, R. Ivánek, et al., Mutations in DNAJC5, encoding cysteine-string protein alpha, cause autosomal-dominant adult-onset neuronal ceroid lipofuscinoses, *Am. J. Hum. Genet.* 89 (2011) 241–252, <http://dx.doi.org/10.1016/j.ajhg.2011.07.003>.
- [18] B.A. Benitez, D. Alvarado, Y. Cai, K. Mayo, S. Chakraverty, J. Norton, et al., Exome-sequencing confirms DNAJC5 mutations as cause of adult neuronal ceroid lipofuscinoses, *PLoS One* 6 (2011) e26741, <http://dx.doi.org/10.1371/journal.pone.0026741>.
- [19] M. Cadioux-Dion, E. Andermann, P. Lachance-Touchette, O. Ansong, C. Meloche, A. Barnabé, et al., Recurrent mutations in DNAJC5 cause autosomal dominant Kufs disease, *Clin. Genet.* 83 (2013) 571–575, <http://dx.doi.org/10.1111/cge.12020>.
- [20] J. Greaves, K. Lemonidis, O.A. Gorleku, C. Cruchaga, C. Grefen, L.H. Chamberlain, Palmitoylation-induced aggregation of cysteine-string protein mutants that cause neuronal ceroid lipofuscinoses, *J. Biol. Chem.* 287 (2012) 37330–37339, <http://dx.doi.org/10.1074/jbc.M112.389098>.
- [21] S.E. Mole, R.E. Williams, H.H. Goebel (Eds.), *The Neuronal Ceroid Lipofuscinoses (Batten Disease)*, 2nd ed. Oxford University Press, New York, 2011.
- [22] A.C. Puga, L.B. Jardim, L. Chimelli, C.F. De Souza, M. Clivati, Neuronal ceroid lipofuscinoses: a clinical and morphological study of 17 patients from southern Brazil, *Arq. Neuropsiquiatr.* 58 (2000) 597–606.
- [23] H. Gao, R.-M.N. Boustany, J.A. Espinola, S.L. Cotman, L. Srinidhi, K.A. Antonellis, et al., Mutations in a novel CLN6-encoded transmembrane protein cause variant neuronal ceroid lipofuscinoses in man and mouse, *Am. J. Hum. Genet.* 70 (2002) 324–335, <http://dx.doi.org/10.1086/338190>.
- [24] J.D. Sharp, R.B. Wheeler, K.A. Parker, R.M. Gardiner, R.E. Williams, S.E. Mole, Spectrum of CLN6 mutations in variant late infantile neuronal ceroid lipofuscinoses, *Hum. Mutat.* 22 (2003) 35–42, <http://dx.doi.org/10.1002/humu.10227>.
- [25] R. Caraballo, A. Sologustua, V.L. Ruggieri, S. Monges, R. Cersósimo, A.L. Taratuto, et al., Lipofuscinoses neuronal ceroides infantil tardía: aspectos clínicos y electroencefalográficos, 40 (2005) 135–140.
- [26] L.B. Jardim, L. Chimelli, M. Clivati, S. Carpenter, H.H. Goebel, L.F.B. Torres, et al., Ultrastructural analyses in a case series of 34 progressive encephalopathies, in: I. Noher de Halac, R. Dodelson de Kremer (Eds.), *Neuronal Ceroid Lipofuscinoses (Batten Dis. Lat. Am. Updat., Secretaría de Extensión, Universidad Nacional de Córdoba, Córdoba 2005, pp. 117–130.*
- [27] J.A. Peña, C. Montiel-Nava, W. Delgado, M.L. Hernández, J.J. Cardozo, E. Mora, et al., Characterization of neuronal ceroid lipofuscinoses in Venezuelan children, *Rev. Neurol.* 38 (2004) 42–48.
- [28] L. Troncoso, R. Erazo, M. Troncoso, S. Wilting, C. Quijada, F. Mena, Neuronal ceroid lipofuscinoses: description of 14 cases, in: I. Noher de Halac, R. Dodelson de Kremer (Eds.), *Neuronal Ceroid Lipofuscinoses (Batten Dis. Lat. Am. Updat., Secretaría de Extensión, Universidad Nacional de Córdoba, Córdoba 2005, pp. 151–156.*
- [29] M. Ruiz-García, G. Hernández-Antunez, S. Nieto-Martínez, E. Lieberman, J. Carrillo-Fraga, Neuronal ceroid lipofuscinoses. Clinical experience in 5 Mexican families, in: I. Noher de Halac, R. Dodelson de Kremer (Eds.), *Neuronal Ceroid Lipofuscinoses (Batten Dis. Lat. Am. Updat., Secretaría de Extensión, Universidad Nacional de Córdoba, Córdoba 2005, pp. 157–162.*
- [30] I. Noher de Halac, R. Dodelson de Kremer (Eds.), *Neuronal Ceroid Lipofuscinoses (Batten Disease) in Latin America—An Update*, Secretaría de Extensión, Universidad Nacional de Córdoba, Córdoba 2005, pp. 1–96.
- [31] R. Kohan, N. Cannelli, C. Aiello, F.M. Santorelli, I.A. Cismondi, M. Mià-Recasens, et al., Gene symbol: CLN5. Disease: neuronal ceroid lipofuscinoses, Finnish variant, *Hum. Genet.* 123 (2008) 552.
- [32] R. Kohan, M.N. Carabelos, W. Xin, K. Sims, N. Guelbert, I.A. Cismondi, et al., Neuronal ceroid lipofuscinoses type CLN2: a new rationale for the construction of phenotypic subgroups based on a survey of 25 cases in South America, *Gene* 516 (2013) 114–121, <http://dx.doi.org/10.1016/j.gene.2012.12.058>.
- [33] E.R. Valadares, M.X. Pizarro, L.R. Oliveira, R.H.C. de Amorim, T.M.M. Pinheiro, U. Grieben, et al., Juvenile neuronal ceroid-lipofuscinoses: clinical and molecular investigation in a large family in Brazil, *Arq. Neuropsiquiatr.* 69 (2011) 13–18.
- [34] L.M. Contreras, W.D. Luengo, N. Zerpa, J.C. Hernández, C.J. Chávez, S.G. Ferrer, Tripeptidyl peptidase 1 in patients with late infantile neuronal ceroid lipofuscinoses, *An. Pediatr. (Barc.)* 76 (2012) 148–152, <http://dx.doi.org/10.1016/j.anpedi.2011.09.020>.
- [35] A. Simonati, F. Pezzini, F. Moro, F.M. Santorelli, Neuronal ceroid lipofuscinoses: the increasing spectrum of an old disease, *Curr. Mol. Med.* 14 (2014) 1043–1051.
- [36] L.A. Camp, S.L. Hofmann, Purification and properties of a palmitoyl-protein thioesterase that cleaves palmitate from H-Ras, *J. Biol. Chem.* 268 (1993) 22566–22574.
- [37] M.J. Warburton, F. Bernardini, Tripeptidyl-peptidase I deficiency in classical late-infantile neuronal ceroid lipofuscinoses brain tissue. Evidence for defective peptidase rather than proteinase activity, *J. Inher. Metab. Dis.* 23 (2000) 145–154.
- [38] H. Sun, X. Lou, Q. Shan, J. Zhang, X. Zhu, J. Zhang, et al., Proteolytic characteristics of cathepsin D related to the recognition and cleavage of its target proteins, *PLoS One* 8 (2013) e65733, <http://dx.doi.org/10.1371/journal.pone.0065733>.
- [39] K. Luoro, O. Kopra, T. Blom, M. Gentile, H.M. Mitchison, I. Hovatta, et al., Batten disease (JNCL) is linked to disturbances in mitochondrial, cytoskeletal, and synaptic compartments, *J. Neurosci. Res.* 84 (2006) 1124–1138, <http://dx.doi.org/10.1002/jnr.21015>.
- [40] E. Siintola, M. Topcu, N. Aula, H. Lohi, B.A. Minassian, A.D. Paterson, et al., The novel neuronal ceroid lipofuscinoses gene MFS8 encodes a putative lysosomal transporter, *Am. J. Hum. Genet.* 81 (2007) 136–146, <http://dx.doi.org/10.1086/518902>.
- [41] L. Lonka, A. Kytälä, S. Ranta, A. Jalanko, A.E. Lehesjoki, The neuronal ceroid lipofuscinoses CLN8 membrane protein is a resident of the endoplasmic reticulum, *Hum. Mol. Genet.* 9 (2000) 1691–1697.
- [42] E. Winter, C.P. Ponting, TRAM, LAG1 and CLN8: members of a novel family of lipid-sensing domains? *Trends Biochem. Sci.* 27 (2002) 381–383.
- [43] J. Bras, A. Verloes, S.A. Schneider, S.E. Mole, R.J. Guerreiro, Mutation of the parkinsonism gene ATP13A2 causes neuronal ceroid lipofuscinoses, *Hum. Mol. Genet.* 21 (2012) 2646–2650, <http://dx.doi.org/10.1093/hmg/ddt089>.
- [44] O.P. Van Diggelen, J.L. Keulemans, W.J. Kleijer, S. Thobois, C. Tiilikete, Y.V. Voznyi, Pre- and postnatal enzyme analysis for infantile, late infantile and adult neuronal ceroid lipofuscinoses (CLN1 and CLN2), *Eur. J. Paediatr. Neurol.* 5 (Suppl. A) (2001) 189–192, <http://dx.doi.org/10.1053/ejpn.2001.0509>.
- [45] S. Partanen, S. Storch, H.G. Löffler, A. Hasilik, J. Tyynelä, T. Braulke, A replacement of the active-site aspartic acid residue 293 in mouse cathepsin D affects its intracellular stability, processing and transport in HEK-293 cells, *Biochem. J.* 369 (2003) 55–62, <http://dx.doi.org/10.1042/BJ20021226>.
- [46] I. Sohar, D.E. Sleat, M. Jadot, P. Lobel, Biochemical characterization of a lysosomal protease deficient in classical late infantile neuronal ceroid lipofuscinoses (LINCL) and development of an enzyme-based assay for diagnosis and exclusion of LINCL in human specimens and animal models, *J. Neurochem.* 73 (1999) 700–711.
- [47] I. Sohar, L. Lin, P. Lobel, Enzyme-based diagnosis of classical late infantile neuronal ceroid lipofuscinoses: comparison of tripeptidyl peptidase I and pepstatin-insensitive protease assays, *Clin. Chem.* 46 (2000) 1005–1008.
- [48] R. Kohan, I. Noher de Halac, V. Tapia Anzoloni, I.A. Cismondi, A.M. Oller-Ramírez, A. Paschini Capra, et al., Palmitoyl Protein Thioesterase1 (PPT1) and Tripeptidyl Peptidase-I (TPP-I) are expressed in the human saliva. A reliable and non-invasive source for the diagnosis of infantile (CLN1) and late infantile (CLN2) neuronal ceroid lipofuscinoses, *Clin. Biochem.* 38 (2005) 492–494, <http://dx.doi.org/10.1016/j.clinbiochem.2004.12.007>.

- [49] Z. Lukacs, P. Santavuori, A. Keil, R. Steinfeld, A. Kohlschütter, Rapid and simple assay for the determination of tripeptidyl peptidase and palmitoyl protein thioesterase activities in dried blood spots, *Clin. Chem.* 49 (2003) 509–511.
- [50] O.H. Lowry, N.J. Rosebrough, A.L. Farr, R.J. Randall, Protein measurement with the Folin phenol reagent, *J. Biol. Chem.* 193 (1951) 265–275.
- [51] J.A. Di Rienzo, F. Casanoves, M.G. Balzarini, L. Gonzalez, M. Tablada, C.W. Robledo, InfoStat, Grupo InfoStat, FCA, Universidad Nacional de Córdoba, Argentina, 2014.
- [52] R. Kohan, I.A. Cismondi, A.M. Oller-Ramirez, N. Guelbert, V. Tapia Anzolini, G. Alonso, et al., Therapeutic approaches to the challenge of neuronal ceroid lipofuscinoses, *Curr. Pharm. Biotechnol.* 12 (2011) 867–883.
- [53] J. Radke, W. Stenzel, H.H. Goebel, Human NCL neuropathology, *Biochim. Biophys. Acta* 1852 (2015) 2262–2266.
- [54] D.E. Sleat, R.M. Gin, I. Sohar, K. Wisniewski, S. Sklower-Brooks, R.K. Pullarkat, et al., Mutational analysis of the defective protease in classic late-infantile neuronal ceroid lipofuscinosis, a neurodegenerative lysosomal storage disorder, *Am. J. Hum. Genet.* 64 (1999) 1511–1523, <http://dx.doi.org/10.1086/302427>.
- [55] C. Aiello, A. Terracciano, A. Simonati, G. Discepoli, N. Cannelli, D. Claps, et al., Mutations in MFSD8/CLN7 are a frequent cause of variant-late infantile neuronal ceroid lipofuscinosis, *Hum. Mutat.* 30 (2009) E530–E540, <http://dx.doi.org/10.1002/humu.20975>.
- [56] R. Steinfeld, K. Reinhardt, K. Schreiber, M. Hillebrand, R. Kraetzner, W. Bruck, et al., Cathepsin D deficiency is associated with a human neurodegenerative disorder, *Am. J. Hum. Genet.* 78 (2006) 988–998, <http://dx.doi.org/10.1086/504159>.
- [57] E. Siintola, S. Partanen, P. Strömme, A. Haapanen, M. Haltia, J. Maehlen, et al., Cathepsin D deficiency underlies congenital human neuronal ceroid-lipofuscinosis, *Brain* 129 (2006) 1438–1445, <http://dx.doi.org/10.1093/brain/awl107>.
- [58] K.R. Smith, J. Damiano, S. Franceschetti, S. Carpenter, L. Canafoglia, M. Morbin, et al., Strikingly different clinicopathological phenotypes determined by progranulin-mutation dosage, *Am. J. Hum. Genet.* 90 (2012) 1102–1107, <http://dx.doi.org/10.1016/j.ajhg.2012.04.021>.
- [59] C.-H. Tang, J.-W. Lee, M.G. Galvez, L. Robillard, S.E. Mole, H.A. Chapman, Murine cathepsin F deficiency causes neuronal lipofuscinosis and late-onset neurological disease, *Mol. Cell. Biol.* 26 (2006) 2309–2316, <http://dx.doi.org/10.1128/MCB.26.6.2309-2316.2006>.
- [60] R. Di Fabio, F. Moro, L. Pestillo, M.C. Meschini, F. Pezzini, S. Doccini, et al., Pseudodominant inheritance of a novel CTSF mutation associated with type B Kufs disease, *Neurology* 83 (2014) 1769–1770, <http://dx.doi.org/10.1212/WNL.0000000000000953>.
- [61] M. Poët, U. Kornak, M. Schweizer, A.A. Zdebek, O. Scheel, S. Hoelzer, et al., Lysosomal storage disease upon disruption of the neuronal chloride transport protein CLC-6, *Proc. Natl. Acad. Sci. U. S. A.* 103 (2006) 13854–13859, <http://dx.doi.org/10.1073/pnas.0606137103>.
- [62] H.M. Mitchison, S.L. Hofmann, C.H. Becerra, P.B. Munroe, B.D. Lake, Y.J. Crow, et al., Mutations in the palmitoyl-protein thioesterase gene (PPT; CLN1) causing juvenile neuronal ceroid lipofuscinosis with granular osmiophilic deposits, *Hum. Mol. Genet.* 7 (1998) 291–297.
- [63] M. Kousi, A.-E. Lehesjoki, S.E. Mole, Update of the mutation spectrum and clinical correlations of over 360 mutations in eight genes that underlie the neuronal ceroid lipofuscinoses, *Hum. Mutat.* 33 (2012) 42–63, <http://dx.doi.org/10.1002/humu.21624>.
- [64] R. Kohan, V.J. Muller, M.J. Fietz, I.A. Cismondi, A.M. Oller-Ramirez, I. Noher de Halac, Gene symbol: TPP1. Disease: neuronal ceroid lipofuscinosis, late infantile. *Hum. Genet.* 123 (2008) 553.
- [65] C. Bessa, C.A. Teixeira, A. Dias, M. Alves, S. Rocha, L. Lacerda, et al., CLN2/TPP1 deficiency: the novel mutation IVS7-10A > G causes intron retention and is associated with a mild disease phenotype, *Mol. Genet. Metab.* 93 (2008) 66–73, <http://dx.doi.org/10.1016/j.ymgme.2007.08.124>.
- [66] The International Batten Disease Consortium, Isolation of a novel gene underlying Batten disease, CLN3, *Cell* 82 (1995) 949–957.
- [67] P.B. Munroe, H.M. Mitchison, A.M. O'Rawe, J.W. Anderson, R.M. Boustany, T.J. Lerner, et al., Spectrum of mutations in the Batten disease gene, CLN3, *Am. J. Hum. Genet.* 61 (1997) 310–316.
- [68] M. del S. Pérez-Poyato, M. Milà-Recasens, I. Ferrer-Abizanda, V. Cusi-Sánchez, M. Vázquez-López, R. Camino-León, et al., Neuronal ceroid lipofuscinosis: diagnostic algorithm and clinical description of the Finnish (CLN5) and Turkish (CLN7) variants late infantile, *Rev. Neurol.* 54 (2012) 544–550.
- [69] I.A. Cismondi, N. Cannelli, C. Aiello, F.M. Santorelli, R. Kohan, A.M. Oller-Ramirez, et al., Gene symbol: CLN5. Disease: neuronal ceroid lipofuscinosis, Finnish variant, *Hum. Genet.* 123 (2008) 554.
- [70] I.A. Cismondi, R. Kohan, A. Ghio, A.M. Oller-Ramirez, I. Noher de Halac, Gene symbol: CLN6. Disease: neuronal ceroid lipofuscinosis, late Infantile. *Hum. Genet.* 124 (2008) 324.
- [71] I.A. Cismondi, R. Kohan, A. Ghio, A.M. Oller-Ramirez, I. Noher de Halac, Gene symbol: CLN6. Disease: neuronal ceroid lipofuscinosis, late infantile. *Hum. Genet.* 124 (2008) 323–324.
- [72] M. Kousi, E. Siintola, L. Dvorakova, H. Vlaskova, J. Turnbull, M. Topcu, et al., Mutations in CLN7/MFSD8 are a common cause of variant late-infantile neuronal ceroid lipofuscinosis, *Brain* 132 (2009) 810–819, <http://dx.doi.org/10.1093/brain/awn366>.
- [73] Exome Variant Server, NHLBI GO Exome Sequencing Project (ESP), <http://evs.gs.washington.edu/EVS/2015> (accessed April 12, 2015).
- [74] A. Fernández-Marmiesse, M. Morey, M. Pineda, J. Eiris, M.L. Couce, M. Castro-Gago, et al., Assessment of a targeted resequencing assay as a support tool in the diagnosis of lysosomal storage disorders, *Orphanet J. Rare Dis.* 9 (2014) 59, <http://dx.doi.org/10.1186/1750-1172-9-59>.
- [75] P. Di Natale, G. Pontarelli, G.R.D. Villani, C. Di Domenico, Gene symbol: SGSH. Disease: Sanfilippo type A syndrome, mucopolysaccharidosis IIIA. *Hum. Genet.* 119 (2006) 679.
- [76] S.L. Cotman, J.F. Staropoli, The juvenile Batten disease protein, CLN3, and its role in regulating anterograde and retrograde post-Golgi trafficking, *J. Clin. Lipidol.* 7 (2012) 79–91, <http://dx.doi.org/10.2217/clp.11.70>.
- [77] L. Lauronen, P.B. Munroe, I. Järvelä, T. Autti, H.M. Mitchison, A.M. O'Rawe, et al., Delayed classic and protracted phenotypes of compound heterozygous juvenile neuronal ceroid lipofuscinosis, *Neurology* 52 (1999) 360–365.
- [78] T. Autti, J.D. Cooper, O.P. van Diggelen, M. Haltia, A. Jalanko, C. Kitzmuller, et al., CLN1, in: S.E. Mole, R.E. Williams, H.H. Goebel (Eds.), *Neuronal Ceroid Lipofuscinoses (Batten Dis)*, Oxford University Press, New York 2011, pp. 55–79.
- [79] S.E. Mole, R.E. Williams, H.H. Goebel, Correlations between genotype, ultrastructural morphology and clinical phenotype in the neuronal ceroid lipofuscinoses, *Neurogenetics* 6 (2005) 107–126, <http://dx.doi.org/10.1007/s10048-005-0218-3>.
- [80] M. Claussen, P. Heim, J. Knispel, H.H. Goebel, A. Kohlschütter, Incidence of neuronal ceroid-lipofuscinoses in West Germany: variation of a method for studying autosomal recessive disorders, *Am. J. Med. Genet.* 42 (1992) 536–538, <http://dx.doi.org/10.1002/ajmg.1320420422>.
- [81] F. Cardona, E. Rosati, Neuronal ceroid-lipofuscinoses in Italy: an epidemiological study, *Am. J. Med. Genet.* 57 (1995) 142–143, <http://dx.doi.org/10.1002/ajmg.1320570206>.
- [82] Y.J. Crow, J.L. Tolmie, A.G. Howatson, W.J. Patrick, J.B. Stephenson, Batten disease in the west of Scotland 1974–1995 including five cases of the juvenile form with granular osmiophilic deposits, *Neuropediatrics* 28 (1997) 140–144, <http://dx.doi.org/10.1055/s-2007-973690>.
- [83] M. Elleder, J. Franc, J. Kraus, S. Nevsímalová, K. Sixtová, J. Zeman, Neuronal ceroid lipofuscinosis in the Czech Republic: analysis of 57 cases. Report of the “Prague NCL group”, *Eur. J. Paediatr. Neurol.* 1 (1997) 109–114.
- [84] P. Uvebrant, B. Hagberg, Neuronal ceroid lipofuscinoses in Scandinavia. Epidemiology and clinical pictures. *Neuropediatrics* 28 (1997) 6–8, <http://dx.doi.org/10.1055/s-2007-973654>.
- [85] P.E. Taschner, P.F. Franken, L. van Berkel, M.H. Breuning, Genetic heterogeneity of neuronal ceroid lipofuscinosis in The Netherlands, *Mol. Genet. Metab.* 66 (1999) 339–343, <http://dx.doi.org/10.1006/mgme.1999.2810>.
- [86] J.A. Rider, D.L. Rider, Thirty years of Batten disease research: present status and future goals, *Mol. Genet. Metab.* 66 (1999) 231–233, <http://dx.doi.org/10.1006/mgme.1999.2827>.
- [87] F.M. Santorelli, B. Garavaglia, F. Cardona, N. Nardocci, B.D. Bernardina, S. Sartori, et al., Molecular epidemiology of childhood neuronal ceroid-lipofuscinosis in Italy, *Orphanet J. Rare Dis.* 8 (2013) 19, <http://dx.doi.org/10.1186/1750-1172-8-19>.
- [88] R.E. Williams, NCL incidence and prevalence data, in: S.E. Mole, R.E. Williams, H.H. Goebel (Eds.), *Neuronal Ceroid Lipofuscinoses (Batten Dis)*, 2nd ed. Oxford University Press, Oxford 2011, pp. 361–363.
- [89] S.J. Moore, D.J. Buckley, A. MacMillan, H.D. Marshall, L. Steele, P.N. Ray, et al., The clinical and genetic epidemiology of neuronal ceroid lipofuscinosis in Newfoundland, *Clin. Genet.* 74 (2008) 213–222, <http://dx.doi.org/10.1111/j.1399-0004.2008.01054.x>.
- [90] C. Verity, A.M. Winstone, L. Stellitano, R. Will, A. Nicoll, The epidemiology of progressive intellectual and neurological deterioration in childhood, *Arch. Dis. Child.* 95 (2010) 361–364, <http://dx.doi.org/10.1136/adc.2009.173419>.
- [91] L.B. Augustad, W.D. Flanders, Occurrence of and mortality from childhood neuronal ceroid lipofuscinoses in Norway, *J. Child Neurol.* 21 (2006) 917–922.
- [92] P.M. MacLeod, C.L. Dolman, E. Chang, D.A. Applegarth, B. Bryant, The neuronal ceroid lipofuscinoses in British Columbia: a clinical epidemiologic and ultrastructural study, *Birth Defects Orig. Artic. Ser.* 12 (1976) 289–296.
- [93] A. Kohlschütter, A. Schulz, Towards understanding the neuronal ceroid lipofuscinoses, *Brain Dev.* 31 (2009) 499–502, <http://dx.doi.org/10.1016/j.braindev.2008.12.008>.
- [94] S.C. Groft, M.P. de la Paz, Rare diseases—avoiding misperceptions and establishing realities: the need for reliable epidemiological data, *Adv. Exp. Med. Biol.* 686 (2010) 3–14, http://dx.doi.org/10.1007/978-90-481-9485-8_1.
- [95] D.E. Sleat, M. El-Banna, I. Sohar, K.-H. Kim, K. Dobrenis, S.U. Walkley, et al., Residual levels of tripeptidyl-peptidase I activity dramatically ameliorate disease in late-infantile neuronal ceroid lipofuscinosis, *Mol. Genet. Metab.* 94 (2008) 222–233, <http://dx.doi.org/10.1016/j.ymgme.2008.01.014>.
- [96] D.E. Sleat, L. Ding, S. Wang, C. Zhao, Y. Wang, W. Xin, et al., Mass spectrometry-based protein profiling to determine the cause of lysosomal storage diseases of unknown etiology, *Mol. Cell. Proteomics* 8 (2009) 1708–1718, <http://dx.doi.org/10.1074/mcp.M900122-MCP200>.