

Eosinophilia and pulmonary dysfunction during Cuprophan hemodialysis

EDWARD A. MICHELSON, LEONARD COHEN, RAND E. DANKNER,
and ANTHONY KULCZYCKI, JR.

Division of Allergy and Immunology, Department of Medicine, and Howard Hughes Medical Institute Laboratory, Washington University School of Medicine, St. Louis, Missouri

Four types of adverse events resembling immunological reactions have been reported in patients undergoing chronic maintenance hemodialysis: anaphylaxis [1], hyper eosinophilia [1–5], asthmatic attacks [4–6], and pulmonary leukostasis with compromised pulmonary function [7–10]. We evaluated three successive chronic dialysis patients who had developed acute hypersensitivity reactions manifested by increased airway obstruction in response to hemodialysis. Each patient also had a non-acute reaction to dialysis, hyper eosinophilia, and one patient had urticaria. All dialyzers were ethylene oxide sterilized and none were reused. In these three patients the adverse reactions abated after changing from dialyzers containing Cuprophan (ENKA Ag, Wuppertal, Germany) to dialyzers not containing Cuprophan. In each patient a second exposure to Cuprophan caused recurrence of one or more of the adverse reactions. These case studies and our re-examination of previous observations [1–6] suggest that in some patients both acute and chronic adverse reactions may be related to the use of Cuprophan.

Methods and Results. Patient 1. A 50-year-old black female with renal failure secondary to hypertension began chronic hemodialysis in December 1975. It is uncertain which dialyzers were used during the first 10 months of dialysis, but during her ninth and tenth months of dialysis differential counts showed 18 and 20% eosinophils (Fig. 1). In October 1976, a one antigen-matched cadaver kidney transplant was attempted but was rejected and, 3 weeks later, removed. Hemodialysis was continued using coil dialyzers containing Cuprophan (ENKA Ag) from 1976 to June 1978 (U₂ dialyzers from Travenol, Deerfield, Illinois, and ALT 100 dialyzers from Bentley Labs, Irvine, California). Three different dialyzers containing Cuprophan hollow fibers (ENKA Ag) were used from June to November 1978. The HD plate dialyzer (Travenol) containing Cuprophan (ENKA Ag) membranes was used from September 1979 to July 1981. The patient's course was marked by persistence of 35 to 60% eosinophilia for 5 years and was complicated by frequent mild dyspneic episodes. On August 18 and October 16, 1981, the patient experienced particularly severe episodes of wheez-

ing, nausea, flushing, and periorbital edema within 30 min of the initiation of dialysis with an HPF 100 dialyzer (Erika, Inc., Rockleigh, New Jersey) containing Cuprophan hollow fibers (ENKA Ag) which prompted discontinuation of dialysis and administration of diphenhydramine intramuscularly. During a subsequent asymptomatic dialysis session using the HPF 100 dialyzer pulmonary function studies (Table 1) demonstrated decreases in volume of air expired during first second of forced vital capacity (FEV₁), peak expiratory flow rate (PEFR), and maximal mid-expiratory flow rate (MMEF).

The patient was switched to C-DAK 4000 dialyzers (Cordis Dow Corp., Concord, California) on November 10, 1981 (none of the Cordis Dow dialyzers contain Cuprophan). On December 8, the patient was dialyzed once again using the Cuprophan-containing HPF 100 dialyzer. Fifteen minutes after initiation of dialysis, a routine blood sample was drawn which later revealed leukopenia (1,800 cells/mm³). Twenty-five minutes after the onset of dialysis, the patient complained of dyspnea and her systolic blood pressure fell 50 mm Hg. Cessation of dialysis and injection of diphenhydramine resulted in resolution of symptoms. All subsequent dialysis sessions have employed C-DAK 4000 (cellulose acetate) dialyzers with reduction of eosinophilia and symptoms, although relatively minor dyspneic episodes still occur during dialysis. Pulmonary function studies have demonstrated increases in FEV₁ and PEFR during dialysis sessions using C-DAK 4000 cellulose acetate dialyzers (Table 1).

A positive serum antinuclear antibody (ANA) at a dilution of 1:360 was attributed to prior use of hydralazine (anti-DNA antibodies were negative). Multiple stool examinations revealed neither ova nor parasites. Skin testing revealed little immediate skin reactivity to common aeroallergens, and serum IgE levels were consistently between 480 and 1,000 IU/ml.

Patient 2. A 44-year-old black female with endstage renal disease secondary to hypertension began hemodialysis in March, 1977, using UF2 dialyzers (Travenol, Deerfield, Illinois) containing Cuprophan coils (ENKA, Ag). The patient received a cadaveric renal transplant in October, 1978, and required corticosteroids for episodes of graft rejection which occurred shortly after transplantation, in December, 1978, and January, 1979.

Following multiple bouts of pneumonia and renal graft rejection, chronic hemodialysis was resumed in April, 1981, using

Received for publication August 10, 1982
and in revised form January 19, 1983

© 1983 by the International Society of Nephrology

Table 1. Parameters of pulmonary function before and during hemodialysis, patient 1^a

Membrane	Time min	FVC liters	FEV ₁ liters	PEFR liters/sec	MMEF liters/sec
Cuprophane (10/22/81)	Before	2.5	2.17	4.3	2.5
	30	2.4 (-4%)	1.9 (-12%)	3.2 (-26%)	1.9 (-24%)
	90	2.5 (0%)	2.0 (-8%)	3.3 (-23%)	1.9 (-24%)
Cellulose acetate (1/19/82)	Before	2.2	1.5	1.9	1.0
	90	2.2 (0%)	1.8 (+20%)	2.5 (+32%)	1.8 (+80%)
Cellulose acetate (2/4/82)	Before	2.2	1.5	1.9	0.8
	90	2.2 (0%)	1.8 (+20%)	3.2 (+68%)	1.7 (+112%)

Abbreviations: FVC, forced vital capacity; FEV₁, volume of air expired during first second of FVC; MMEF, maximal mid-expiratory flow rate; PEFR, peak expiratory flow rate. (During hemodialysis one normally expects improvement in pulmonary function related to removal of excess lung water [16].)

^a Percentage increase or decrease from pre-dialysis value is given in parentheses.

HD 1000 dialyzers (Travenol) containing Cuprophane plate membranes (ENKA Ag) (Fig. 2). During many dialysis sessions, episodes of hypotension associated with increases in jugular venous pressure, wheezing, coarse rales, and epigastric pain occurred. Hypereosinophilia was noted 3 months after initiation of dialysis with HD 1000 dialyzers, with eosinophil counts (calculated from the differential count) rising to 7,200 cells/mm³. On July 23, 1981, dialysis was discontinued due to marked hypotension and shortness of breath. Subsequent dialyses employing C-DAK 1.3 regenerated cellulose dialyzers (Cordis-Dow) have been marked by a profound decrease in eosinophilia and an absence of episodes of hypotension and dyspnea.

Patient 3. A 20-year-old white male with endstage renal disease secondary to hereditary medullary cystic kidney disease began chronic hemodialysis in October, 1971, using C-DAK 1.8 (regenerated cellulose) dialyzers (Cordis-Dow) (Fig. 3). A cadaver kidney was transplanted in August, 1972, and, despite four episodes of rejection treated with corticosteroids and immunosuppressives, it continued to function for 5 years. Chronic hemodialysis was reinstated in August, 1977. During the first week after the patient was switched to CF 1200 dialyzers (Travenol) containing Cuprophane hollow fibers (ENKA Ag) in July 1978, he developed pruritis and urticaria while undergoing dialysis. The urticaria did not entirely resolve between dialysis sessions but gradually worsened. Approximately 2 hr into one dialysis session he developed a marked worsening of the pruritis with shortness of breath and flushing. After returning to the C-DAK 1.8 dialyzer, the urticaria resolved over a period of days. A second cadaver kidney was transplanted in November of 1978, but functioned only for a period of 3 months. In early 1979, the patient returned to chronic hemodialysis with the C-DAK 1.8 dialyzers and experienced no adverse reactions.

In June 1981 he was rechallenged in three consecutive dialysis sessions with CF 1200 dialyzers (which contain Cuprophane hollow fibers) and approximately 30 to 40 min into each dialysis, he developed hives and pruritis involving the trunk and upper extremities. The third dialysis session was terminated due to development of shortness of breath and tachycardia. Subsequently, the patient has been dialyzed only with regenerated cellulose dialyzers without adverse reactions.

Discussion

The first patient has had two types of adverse reactions to hemodialysis; chronically elevated eosinophil counts over a 5-

year period and acute episodes of respiratory impairment with angioedema. Both reactions appear to be related to the type of dialyzer since making only one change in therapy, converting from Cuprophane-containing dialyzers to cellulose acetate dialyzers, was followed by marked reduction in the severity of adverse respiratory reactions and a marked decrease in absolute eosinophil count. The second patient had eosinophilia during hemodialysis with Cuprophane coils during 1977 and 1978 which subsided after successful transplantation. She had acute episodes of respiratory impairment in 1981 when dialysis was resumed using a plate dialyzer which contained Cuprophane. Marked eosinophilia also developed during the third month of dialysis using the Cuprophane plate dialyzer (steroid use may have prevented an earlier increase). After discontinuing use of Cuprophane dialyzers, she had no further respiratory difficulties nor marked eosinophilia. The third patient had acute respiratory difficulty and chronic problems with urticaria during the initial week of dialysis (and subsequent rechallenges) with Cuprophane hollow-fiber dialyzers. Using non-Cuprophane dialyzers such symptoms did not occur. Eosinophilia (> 450 cells/mm³) was noted in his two blood samples obtained during the period of dialysis with Cuprophane dialyzers but was not as marked as those in the first two patients. Of 19 samples obtained at other times, only three demonstrated eosinophilia. Retrospective evaluation of eosinophilia is limited by the rarity of eosinophil counts and the inaccuracy of the occasional differential counts. However, patients 1 and 2 demonstrated unequivocal eosinophilia during use of Cuprophane-containing dialyzers.

It is our suggestion that dialyzers containing Cuprophane may induce both acute anaphylaxis-like reactions and chronic reactions (especially eosinophilia) in some patients. Logically, both types of reactions should abate when use of Cuprophane is discontinued.

A previous study, interpreted as associating eosinophilia with dialyzer reuse and/or formaldehyde, found that four (13%) of 30 patients developed eosinophilia during hemodialysis with various types of Cuprophane dialyzers [1]. In another study eosinophilia was present in 19 (25%) of 77 patients undergoing hemodialysis [2] using exclusively RSP artificial kidneys with Cuprophane coils (Travenol). The study concluded that eosinophilia "was somehow maintained by repetitive dialysis," but it was not associated with reuse of membranes. In a study of IgE levels in 62 patients undergoing hemodialysis with dialyzers containing Cuprophane hollow fibers, it was noted that 28 (45%)

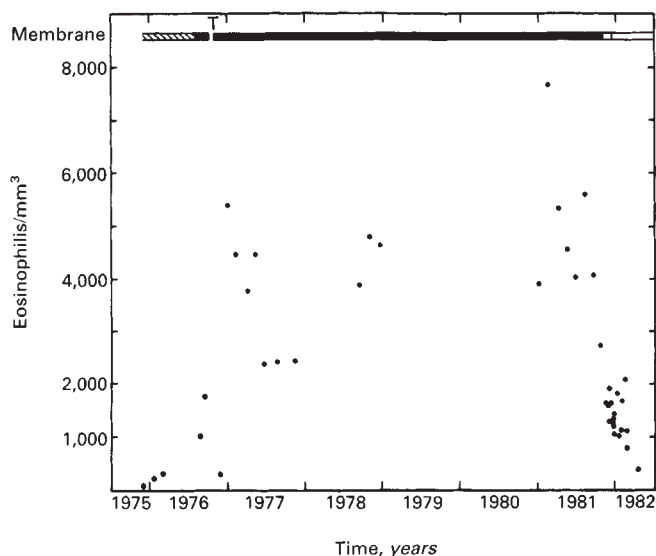





Fig. 1. Eosinophils/mm³ in patient 1. After November 1981 most values were derived from absolute eosinophil counts; prior values were calculated from differential counts. No corticosteroids were used except during the period of transplantation, denoted as T. In this and subsequent figures the type of dialyzer membrane is denoted by different bars: , Cuprophan membrane; , membrane-type not known; , non-Cuprophan membrane.

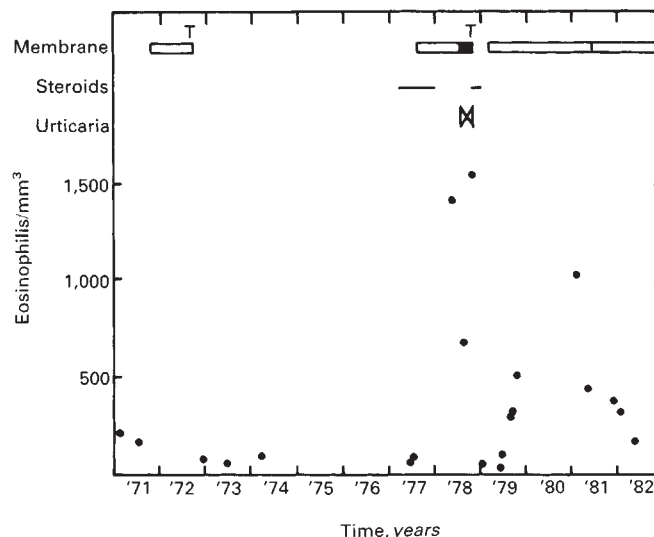


Fig. 3. Eosinophils/mm³ and urticaria symptoms (X) in patient 3. T denotes transplantation, solid bars denote Cuprophan hemodialysis, open bars denote non-Cuprophan dialysis, and lines indicate steroid use as in other figures.

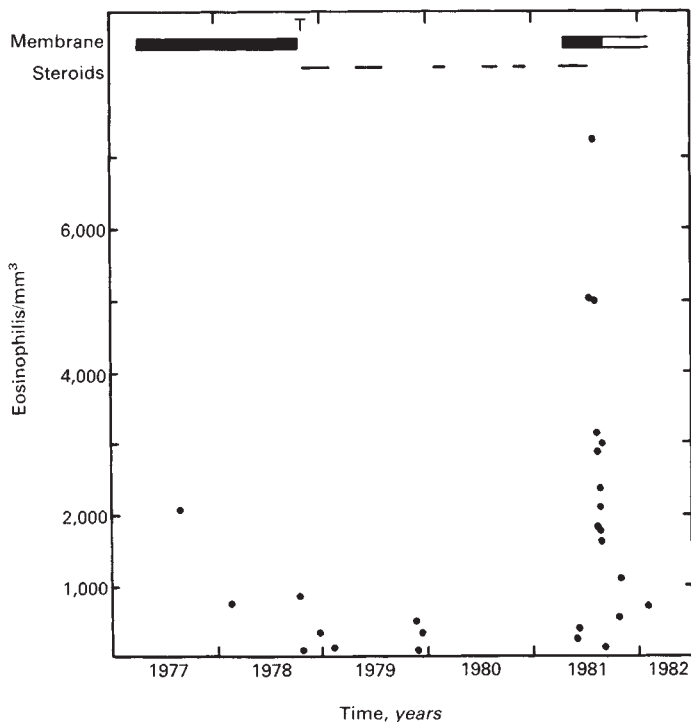


Fig. 2. Eosinophils/mm³ of blood in patient 2. T denotes transplantation and bars denote hemodialysis as in Figure 1. Lines indicate periods of corticosteroid use.

had eosinophilia [3]. Two patients were reported with asthmatic attacks and eosinophilia associated with hemodialysis although the dialysis membrane was not identified in one patient [4] and

formaldehyde sterilization of the dialyzer may have been responsible for the other patient [1, 11]. In one patient (without eosinophilia) asthmatic symptoms during hemodialysis with Cuprophan dialyzers subsided with non-Cuprophan hemodialysis [6], although significant bronchospasm ordinarily occurs only in hemodialysis patients with eosinophilia [5].

Our patient series suggests that those maintained on chronic hemodialysis using Cuprophan who experience unexplained eosinophilia and/or adverse symptoms resembling immunologic reactions might benefit by switching to non-Cuprophan dialyzers. A larger prospective study to test this suggestion certainly is warranted. Although our patients appear to have Cuprophan-specific reactions and the majority of the previous studies involve patients using Cuprophan dialyzers, it does not necessarily follow that all hemodialysis-induced eosinophilia results from exposure to Cuprophan. The earliest study of dialysis-induced eosinophilia [1] reported a higher incidence of eosinophilia in the hospital using non-Cuprophan membranes; however, it is now suspected that these patients may have resulted from formaldehyde sterilization [11]. Another study [5] reported that the incidence of persistent eosinophilia was comparable in Cuprophan-dialyzed patients and non-Cuprophan-dialyzed patients, although it did not indicate how long patients had been using their respective dialyzers nor which dialyzer was used by the five patients with bronchospasm. These two studies are not contradictory to ours, in fact in the first study patients switched to Cuprophan dialyzers were noted to have persistent eosinophilia [1]. Nonetheless, these two studies and reports associating eosinophilia with peritoneal dialysis [12, 13] suggest that substances other than Cuprophan may also be involved in initiating eosinophilia.

A number of studies suggest that complement is activated by exposure of blood to dialyzers containing Cuprophan and that the complement fragments so generated lead to granulocyte and monocyte entrapment in the pulmonary vasculature and, conse-

quently, to pulmonary dysfunction [7–10]. It appears that Cuprophane membranes cause greater leukopenia than non-Cuprophane membranes [14–15]. Thus, one possible mechanism to explain our observations is that Cuprophane-generated complement fragments might cause basophils and mast cells to release histamine, leukotriene B₄, and other substances causing chemotaxis and/or production of eosinophils.

Note added in proof

Eosinophilia was found in 27% of hemodialysis patients who were studied over a period of time using Cuprophane membranes [17].

Acknowledgments

This work was supported in part by National Institutes of Health grants AI-16946, AI-00112, and AI-15322. The authors thank Dr. H. Harter for reviewing the manuscript and C. Weerts of Barnes Hospital, Dr. T. Pohlman, Kathryn Johnson of the Jewish Hospital, St. Louis, and C. Anderson of the City Hospital, for information retrieval.

Reprint requests to Dr. A. Kulczycki, Jr., Box 8122, Divisions of Allergy and Immunology, 660 South Euclid Avenue, Washington University School of Medicine, St. Louis, Missouri 63110, USA

References

- HOY WE, CESTERO RVM: Eosinophilia in maintenance hemodialysis patients. *J Dial* 3:73–87, 1979
- MONTOLIU J, LOPEZ-PEDRET J, ANDREU L, REVERT L: Eosinophilia in patients undergoing dialysis. *Br Med J* 282:2098, 1981
- DRATWA M, TIELEMANS C, BRENEZ D: IgE levels in patients with chronic renal failure. *N Engl J Med* 305:960–961, 1981
- HANAI KEI, HORUCHI T, HANAI J, GOLAH H, HIRASWA Y, GEJYO F, ALZAW Y: Hemodialysis associated asthma in a renal failure patient. *Nephron* 25:247–248, 1979
- SPINOWITZ BS, SIMPSON M, MANU P, CHARYTAN C: Dialysis eosinophilia. *Trans Am Soc Artif Intern Organs* 27:161–167, 1981
- ALJAMA P, BROWN P, TURNER P, WARD MK, KERR DNS: Haemodialysis-triggered asthma. *Br Med J* 2:251–252, 1978
- CRADDOCK PR, FEHR J, BRIGHAM KL, KRONENBERG RS, JACOB HS: Complement and leukocyte-mediated pulmonary dysfunction in hemodialysis. *N Engl J Med* 296:769–773, 1977
- CRADDOCK PR, FEHR J, DALMASSO AP, BRIGHAM KL, JACOB HS: Hemodialysis leukopenia. Pulmonary vascular leukostasis resulting from complement activation by dialyzer cellophane membranes. *J Clin Invest* 59:879–888, 1977
- CRADDOCK PR, HAMMERSCHMIDT DE, MOLDOW CF, YAMADA O, JACOB HS: Granulocyte aggregation as a manifestation of membrane interactions with complement: Possible role of leukocyte margination, microvascular occlusion, and endothelial damage. *Semin Hematol* 16:140–147, 1979
- JACOB HS, CRADDOCK PR, HAMMERSCHMIDT DE, MOLDOW CF: Complement-induced granulocyte aggregation. *N Engl J Med* 302:789–794, 1980
- CESTERO RVM: Discussion of reference 5. *Trans Am Soc Artif Intern Organs* 27:166, 1981
- HUMAYUN HM, ING TS, DAUGIRDAS JT, GANDHI VC, POPLI S, ROBINSON JA, HANO JE, ZAYAS I: Peritoneal fluid eosinophilia in patients undergoing maintenance peritoneal dialysis. *Arch Intern Med* 141:1172–1173, 1981
- SPINOWITZ B, GOLDEN R, RASCOTT J, CHARYTAN C: Eosinophilic peritonitis in CAPD patients (abstract). *Artif Organs* 5:457, 1981
- BAUER H, BULTMANN B, FRANZ HE: Biocompatibility of Cuprophane and non-Cuprophane dialysis membranes. *Am Soc Artif Int Organs, Abst* 11:41, 1982
- SHENOUDA AN, YIUM JJ, PATY JG, MILLER FJ, SWAFFORD D, EDMONS R: Effects of hemodialysis on pO₂, WBC, platelets, and complement by two different membrane dialyzers. *Am Soc Artif Int Organs, Abst* 11:65, 1982
- ZIDULKA A, DESPAS PJ, MILIC-EMILI J, ANTHONISEN NR: Pulmonary function with acute loss of excess lung water by hemodialysis in patients with chronic uremia. *Am J Med* 55:134–141, 1973
- SCHUEERMANN EH, FASSBINDER W, FREI U, KOCH KM, BALDAMUS CA: Eosinophilia in hemodialysis. *Contrib Nephrol* 36:133–138, 1983