Initial experience with endovascular aneurysm repair: Comparison of early results with outcome of conventional open repair

David C. Brewster, MD, Stuart C. Geller, MD, John A. Kaufman, MD, Richard P. Cambria, MD, Jonathan P. Gertler, MD, Glenn M. LaMuraglia, MD, Susan Atamian, RN, and **William M. Abbott, MD,** *Boston, Mass.*

Purpose: **To determine the safety, effectiveness, and problems encountered with endovascular repair of abdominal aortic aneurysm (AAA). Initial experience with endoluminal stent grafts was examined and compared with outcome for a matched concurrent control group undergoing conventional operative repair of AAA.**

Methods: **Over a 3-year period, 30 patients underwent attempts at endovascular repair of infrarenal AAA. Of the 28 (93%) successfully implanted endografts, 8 were tube endografts, 8 bifurcated grafts, and 12 aortouniiliac grafts combined with femorofemoral bypass. Most of the procedures were performed in the past year because the availability of bifurcated and aortoiliac endografts markedly expanded the percentage of patients with AAA who might be treated with endoluminal methods. The follow-up period ranged from 1 to 44 months, with a mean value of 11 months.**

Results: **Endovascular procedures demonstrated significant advantages with respect to reduced blood loss (408 versus 1287 ml), use of an intensive care unit (0.1 versus 1.75 days), length of hospitalization (3.9 versus 10.3 days), and quicker recovery (11 versus 47 days). Although the total number of postoperative complications was identical for the two groups, the nature of the complications differed considerably. Local and vascular complications characteristic of endovascular repair could frequently be corrected at the time of the procedure and tended to be less severe than systemic or remote complications, which predominated among the open surgical repair group. On an intent-to-treat basis, 23 (77%) of the 30 AAAs were successfully managed with endoluminal repair. The seven (23%) failures were attributable to two immediate conversions caused by access problems, three persistent endoleaks, one late conversion caused by AAA expansion, and one late rupture.**

Conclusions: **Although less definitive than those for conventional operations, these early results suggest that endovascular AAA repair offers considerable benefits for appropriate patients. The results justify continued application of this method of AAA repair, particularly in the treatment of older persons at high risk. (J Vasc Surg 1998;27:992-1005.)**

From the Division of Vascular Surgery and Section of Vascular Radiology, Massachusetts General Hospital, and Departments of Surgery and Radiology, Harvard Medical School.

Supported in part by the Gordon P. Lovell Fund for Vascular Research and Education.

Presented at the Twenty-fourth Annual Meeting of the New England Society for Vascular Surgery, Bolton Landing, N.Y., Sep. 18–19, 1997.

Reprint requests: Dr. David C. Brewster, One Hawthorne Pl., Boston, MA 02114.

Copyright © 1998 by The Society for Vascular Surgery and International Society for Cardiovascular Surgery, North American Chapter.

0741-5214/98/$5.00 + 0 24/6/88139

The possibility of repair of abdominal aortic aneurysm (AAA) by means of placement of a prosthetic graft inserted from a remote site, guided to the desired location intraluminally under radiologic control, and secured with an expandable stent attachment system to exclude the AAA has been demonstrated in several early reports after the initial successful application of the method by Parodi et al. in 1991.[1-6] A growing number of studies detailing experience with a variety of transluminally placed endovascular graft (TPEG) devices have been published to document the effi-

Table I. Anatomic selection criteria for endovascular repair of abdominal aortic aneurysm

Criterion	*Specification*
Proximal aneurysm neck	≥1.5 cm long, ≤26 mm in diameter
Distal attachment site	
Tube endograft	Distal aortic cuff ≥1.5 cm long, ≤26 mm in diameter
Bifurcated graft	Distal common iliac ≥1.5 cm long, ≤14 mm in diameter
Aortouniiliac	Ipsilateral common or external iliac ≤14 mm in diameter with AAA morphology that allowed preservation of at least one internal iliac artery
Proximal aortic neck angulation	<75 degrees
Iliac artery	≥7-8 mm diameter without excessive tortuosity or calcification
Other factors	No significant accessory renal artery or "critical" inferior mesenteric artery arising from AAA sac

AAA, Abdominal aortic aneurysm.

cacy and generally satisfactory early results of endovascular AAA repair.[7-16]

Although the prospects of lower morbidity and mortality rates, possible cost savings, and quicker patient recovery hold tremendous appeal for this less invasive method of treatment, much uncertainty continues to exist about its proper application in the treatment of patients with AAA and its success and reliability compared with conventional open operative repair. To examine some of these issues and determine the safety, early effectiveness, and problems encountered with endoluminal repair, initial experience at a large tertiary center with development of a program of endovascular AAA repair was reviewed and outcome measures compared with those for a similar concurrent control group undergoing conventional surgical repair.

METHODS

From January 1994 through May 1997, a total of 36 patients underwent TPEG repair of aneurysmal disease. Six endoluminal stent grafts for thoracic, iliac, or other unusual or complex aneurysms were successfully deployed but not considered further in the analysis. This left 30 patients undergoing attempts at endovascular management of elective infrarenal AAA.

Patients were selected as possible candidates for endovascular repair on the basis of various anatomic criteria with respect to the aneurysm and adjacent vessels. Selection criteria are outlined in Table I. These anatomic features were evaluated with a combination of preprocedural imaging techniques. All patients underwent contrast-enhanced spiral computed tomography (CT) with 3.0 mm cuts and three-dimensional vascular reconstruction. If initial measurements and morphologic characteristics of the AAA appeared favorable for possible endovascular repair, contrast-enhanced multiplanar angiography was performed with a special catheter with radiopaque markers at 1 cm intervals (Cook, Bloomington, Ind.) to allow correction for magnification and precise length and diameter measurements.

Anatomic measurements and other morphologic features derived from the combination of imaging studies included distance between the lowest renal artery and the AAA (length of proximal neck), distance between the end of the AAA and aortic bifurcation, if any (length of distal neck), overall lengths between the renal arteries and both the aortic and iliac bifurcations, diameter and configuration of the proximal and distal necks, and length and diameter of the common and external iliac arteries. Degree of angulation of the proximal neck, tortuosity of the iliac vessels, and extent of calcification and mural thrombus in all locations also were determined. The angiogram also provided important information regarding patency and potential importance of the inferior mesenteric artery in terms of colonic perfusion and helped with identification of any aberrant anatomic features of the renal artery. If anatomic delineation suggested that endovascular AAA repair would be feasible, the options of open and endoluminal repair were discussed with the patient. If the patient chose to proceed with endovascular repair, informed consent was obtained from all participants after the technique, risks, and possible complications of both forms of treatment had been discussed in detail. The protocol for endovascular AAA repair was approved by the institutional review board of Massachusetts General Hospital.

Of the 30 patients for whom endovascular AAA repair was attempted, two patients (7%) needed conversion to open surgical repair because small, diseased iliac arteries precluded satisfactory access to the aneurysm for endovascular graft deployment

despite prolonged efforts from both sides. Of the 28 (93%) successfully implanted endografts, 25 were EVT devices (EndoVascular Technologies, Menlo Park, Calif.) used as part of United States Food and Drug Administration–approved phase I and II multiinstitutional trials of EVT devices. The EVT device and method of insertion have been well described by Moore and Rutherford for the EVT investigators.[10] Three endografts were custom-made devices we fabricated from available stent (Gianturco Z-shaped self-expanding stents; Cook) and vascular prosthetic graft materials, as described by Dake et al.[17] The custom-made endografts were used when the morphologic features of the aneurysm were not suitable for the EVT devices according to the protocol criteria as outlined in Table I. In one of these patients, the AAA neck exceeded 26 mm in maximal diameter. In the other two complex iliac aneurysmal disease necessitated use of an aortouniiliac configuration with occlusion of the contralateral iliac artery. The custom-made devices were inserted through a Keller-Timmermans introducer set with a Rutner adapter (Cook) and deployed with a pusher rod as described by Dake et al.[17]

Endograft configurations included eight tube, eight bifurcated, and 12 aortouniiliac grafts combined with contralateral iliac occlusion and femorofemoral bypass. With the aortouniiliac graft method of endovascular AAA repair, occlusion of the contralateral common iliac artery was achieved by means of transcatheter insertion of multiple coils or transluminal deployment of a special occluding covered stent (Endosoc; EndoVascular Technologies). Standard Dacron polyester or polytetrafluoroethylene (PTFE) vascular grafts were used for the femorofemoral bypasses. A transfemoral approach through limited groin incisions was used to treat 26 patients. A limited retroperitoneal approach allowed insertion of the endograft through an iliac artery graft conduit anastomosed end to side to the common iliac artery in the treatment of two patients with small, diseased external iliac artery segments, as previously described by May et al.[4]

All procedures were performed by a team consisting of vascular surgeons and interventional radiologists, and all were performed in an operating room under general anesthesia. All patients were judged to be acceptable candidates for conventional open operation if endoluminal repair was not feasible. Intraoperative radiologic imaging was performed with a high-quality portable C-arm fluoroscopic device with digital imaging and road-mapping capability on a special radiolucent operating table with movable top compatible with use of the imaging system. Most of the procedures were performed in the last year of the study, when development and availability of both bifurcated and aortouniiliac endografts enabled approximately 50% of patients with AAA to be candidates for endovascular repair as opposed to less than 10% of patients when only a tube endograft was available in the initial interval of the study period.

Initial assessment of endograft function and verification of satisfactory exclusion of the AAA were evaluated by means of intraoperative postdeployment angiography and predischarge contrast-enhanced CT, both with delayed filming, to determine whether any contrast enhancement of the aneurysmal sac was present. Plain abdominal radiographs to identify the position of the attachment devices and longitudinal radiopaque graft markers were obtained, as were color flow duplex scans of the abdomen to assess flow through the endograft and confirm absence of flow within the AAA itself. CT, plain abdominal radiography, and physical examinations including pulse evaluation and ankle-brachial index measurements were repeated 6 months and 1 year after the procedure and annually thereafter.

Outcome parameters evaluated for endovascular repair included operative time, blood loss, use of an intensive care unit, length of hospital stay, death, and both local or vascular and systemic or remote complications of the procedure, as suggested by the Ad Hoc Committee for Standardized Reporting Practices in Vascular Surgery of the Society for Vascular Surgery and International Society for Cardiovascular Surgery.[18] Time from hospital discharge to return of a feeling of preoperative well-being was determined by means of a retrospective questionnaire completed by all patients at the time of initial follow-up visit. The follow-up period after endovascular repair ranged from 1 to 44 months with a mean follow-up time of 11 months.

These early results of endovascular AAA repair were compared with those of similar outcome assessment for a concurrent cohort of 28 patients of similar age, sex, risk factor status, AAA size, and aneurysm extent and morphologic features who underwent conventional open operative repair during the same time.[18,19] Mean AAA size (5.52 cm open, 5.50 cm endovascular) and size ranges (4.5 to 8.9 cm open, 4.2 to 8.5 cm endovascular) were nearly identical. Six of these surgical control patients were participants in the first phase of the randomized EVT device protocol who were assigned to the

Table II. Demographic and clinical characteristics of patients in each group

Characteristic	*Open repair (n = 28)*	*Endovascular repair (n = 28)*	*p Value*
Mean age (yr)	73.9	75.8	NS
Sex (M/F)	20/8	24/4	NS
Maximum diameter of abdominal aortic aneurysm (cm; mean value)	5.52	5.50	NS
Current tobacco use	5 (18)	3 (11)	NS
Hypertension	13 (46)	16 (57)	NS
Diabetes mellitus	2 (7)	3 (11)	NS
Hyperlipidemia	8 (29)	9 (32)	NS
Cardiac disease	15 (54)	17 (61)	NS
Cerebrovascular disease	4 (14)	5 (18)	NS
Pulmonary disease	8 (29)	12 (43)	NS
Creatinine >1.7 mg/dl	3 (11)	4 (14)	NS
Peripheral vascular disease	6 (21)	5 (18)	NS

Unless indicated otherwise, values are number of patients with percentages in parentheses.
NS, not significant.

surgical repair group. When the EVT device study design was altered to become a nonrandomized protocol, control patients were selected from patients with AAAs anatomically suitable for either form of treatment but who preferred conventional operative repair to endoluminal grafting because of its proved track record in contrast to the more uncertain results of TPEG repair.

Patients undergoing nonelective surgical repair because of symptomatic aneurysms or with anatomy unfavorable to endoluminal repair that would make the procedure more challenging and candidates with adverse circumstances for open surgical repair were specifically excluded. In the control group, 50% of patients underwent tube graft repair, and 50% were treated with bifurcated grafts. Surgical repair was performed through a transperitoneal route for 24 patients and a retroperitoneal flank approach for four patients. As shown in Table II, patients undergoing open surgical repair and those undergoing endovascular repair were well matched without significant differences in any parameter.

Comparisons between the two groups were performed with two-sample t tests (with equal or unequal variances assumption) for continuous variables or Fisher exact tests for discrete variables. All statistical analyses were conducted with SAS software (SAS Institute, Cary, N.C.). A two-tailed p value less than 0.05 was considered statistically significant.

RESULTS

A comparison of outcome parameters for the two groups is shown in Table III. Mean operative time for endovascular repair was approximately one-half hour longer than that of conventional open repair, although this difference was not statistically significant. As would be anticipated, tube endografts took the shortest time (mean value 181 minutes) and aortouniiliac TPEG, with the concomitant need to occlude the contralateral iliac artery and construct a femorofemoral bypass to revascularize the contralateral limb, took the longest time to perform (mean value 230 minutes). Endovascular repairs were prolonged to some extent by the need for retroperitoneal access for endograft insertion for two patients, concomitant femoral artery aneurysm repair by means of a segmental interposition graft at the insertion site for two patients, and the occasional need to repair damaged arterial access sites.

There were no perioperative deaths in either group, and no late deaths occurred during the follow-up period to the date of this report. Compared with conventional repair, endoluminal grafting demonstrated substantial advantages with respect to reduced blood loss, use of an intensive care unit, length of hospital stay, rate of postoperative systemic or remote complications, and time to return of a feeling of preprocedural state of health (Table III). These benefits were somewhat offset by the significantly higher incidence of perioperative local or vascular complications among patients undergoing endovascular repair. Overall, the total number of postoperative complications was identical between the two groups. In terms of the number of patients experiencing any problems, 54% of patients undergoing endovascular repair were free of complications, and 50% of those undergoing open repair sustained no perioperative complications.

Complications. Perioperative complications

Table III. Comparison of outcome parameters

Parameter	*Open repair (n = 28)*	*Endovascular repair (n = 28)*	*p Value*
Operative time (hr)	3.25	3.52	NS
Blood loss (ml)	1287	498	<0.01
Intensive care unit stay (d)	1.75	0.1	0.008
Hospital stay (d)	10.3	3.9	0.0001
No. of deaths	0	0	NS
Total no. of complications	20	20	NS
No. of local or vascular complications	2	16	<0.001
No. of systemic or remote complications	18	4	<0.001
Recovery time (d)	47	11	0.0001

All parameters are mean values.

Table IV. Complications of open surgical repair

Complication	*No. of patients*	
Local or vascular	2	
Abdominal wound dehiscence		1
Subcutaneous wound separation		1
Systemic or remote	18	
Cardiac (2 myocardial infarction, 2 congestive heart failure, 2 arrhythmia)		6
Pulmonary (3 pneumonia, 1 respiratory failure)		4
Gastrointestinal (2 prolonged ileus, 1 *Clostridium difficile* colitis)		3
Renal (1 transient acute tubular necrosis, 1 urinary sepsis)		2
Neurologic (1 stroke, 1 seizure, 1 encephalopathy)		3

Table V. Complications of endovascular repair

Complication	*No. of patients*	
Local or vascular	16	
Groin wound problem		4
Arterial injury		2
Limb ischemia		4
Persistent endoleak		3
Minor thromboemboli		1
Late conversion to open repair		1
Late rupture leading to conversion		1
Systemic or remote	4	
Subendocardial myocardial infarction		1
Transient arrhythmia		1
Mild congestive heart failure		1
Pulmonary infiltrate		1

among the two groups are listed in Tables IV and V. Although there was no difference in overall incidence of complications, the nature of the problems differed considerably between the two groups. Many of the local or vascular problems that predominated after endovascular repair could be readily corrected by means of immediate reintervention or outpatient care, whereas a large portion of the systemic or remote postoperative problems in the surgical cohort tended to be more serious and often led to need for continuing hospitalization, as reflected in the marked difference in length of stay between the two groups. For example, two patients who underwent endovascular repair sustained arterial damage to the femoral artery at the insertion site. The damage necessitated local endarterectomy and patch repair for one patient and a segmental distal external iliac to femoral interposition graft for another patient. Both problems were readily corrected at the time of the procedure and did not lead to any sequelae. There were no instances of arterial perforation during passage of the endovascular devices through the iliofemoral system or aneurysm during positioning for endograft deployment.

A similar type of local or vascular complication that occurred much more commonly after endovascular repair is illustrated by three patients who had symptoms of flow obstruction and limb ischemia 2 to 6 hours after endograft placement. Immediate groin reexploration under local anesthesia and repeat angiography demonstrated no thrombus but rather kinking of the unsupported graft limb in tortuous or angulated native segments of iliac artery. The problems had not been evident when the procedures were completed. The angiographic appearance of the endograft had been satisfactory, good distal perfusion had been assessed at pulse examination, and pulse volume recordings and Doppler pressure measurements were good. We presume that apparent shifting of position of the endoprostheses within the native arterial segments occurred in the early hours after implantation. This was readily corrected in each instance by means of deployment of a Wallstent device in the narrowed portion of the endograft (Fig. 1). There were no further problems nor was length of stay prolonged. The final case of limb flow obstruction with limb ischemia was that of

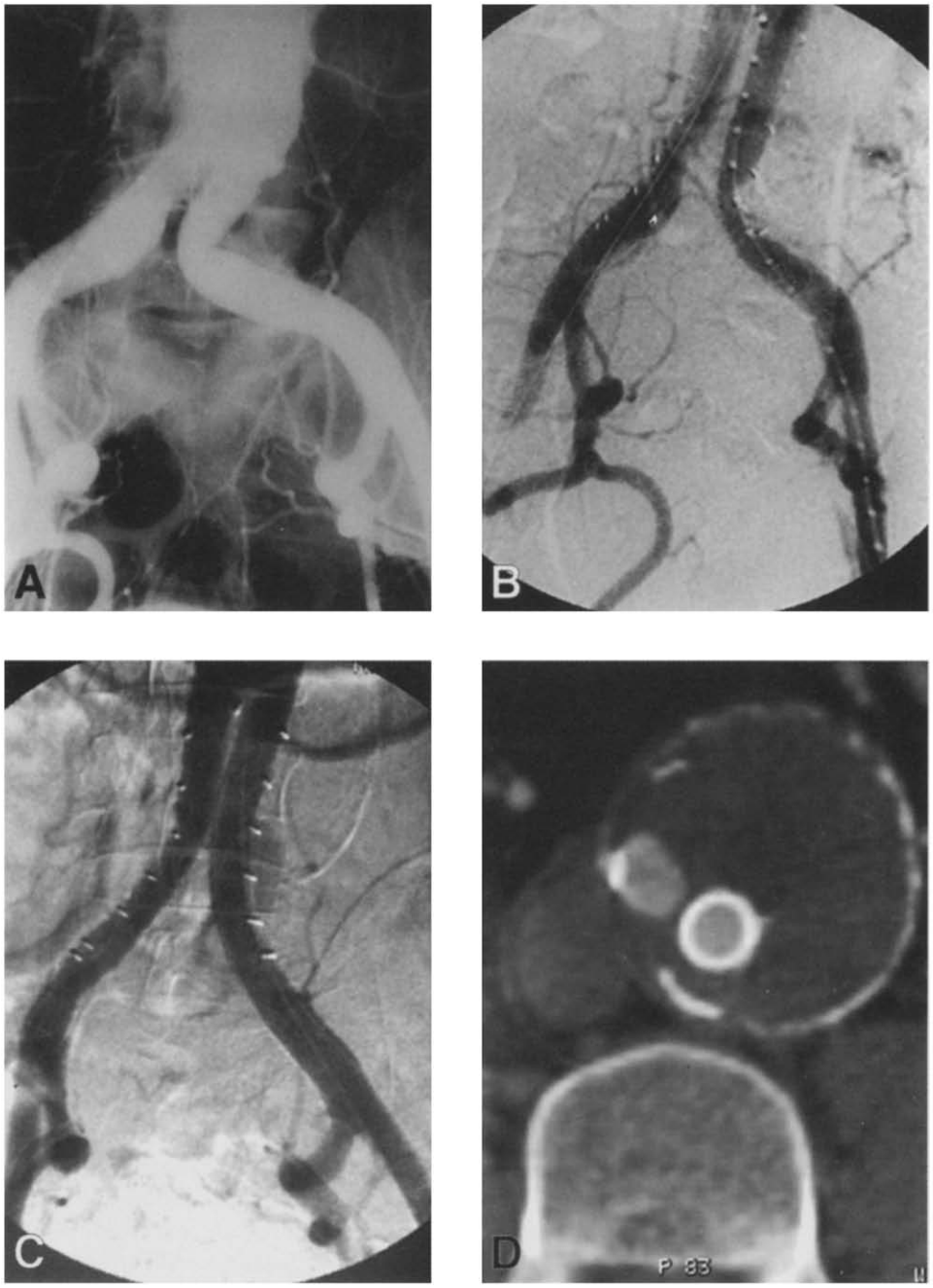

Fig. 1. Example of endograft limb kinking. **A,** Preoperative angiogram shows angulation of left common iliac artery. **B,** Intraprocedural angiogram demonstrates kinking of endograft limb within angulated native arterial segment. **C,** Correction of compromised flow with insertion of Wallstent device. **D,** Postprocedural CT scan reveals widely patent left stented endograft limb within excluded abdominal aortic aneurysmal sac.

a patient with thrombosis of one limb of an EVT bifurcated endograft 7 weeks after discharge. Clot lysis was readily achieved with a short course of urokinase therapy. Repeated radiographs demonstrated a similar endograft limb kink in a tortuous native iliac arterial segment. This kink was corrected with a Wallstent device. Graft limb patency was well maintained thereafter.

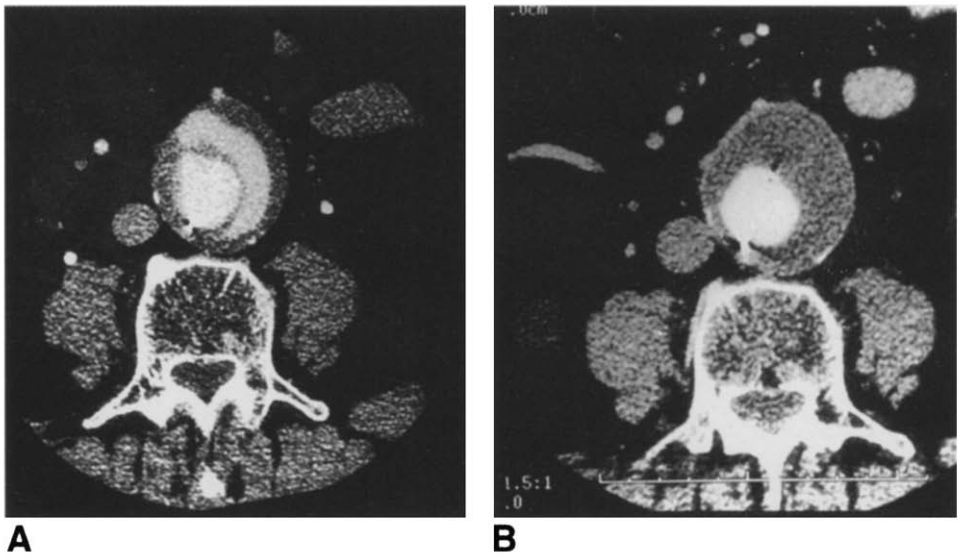

Fig. 2. A, Discharge CT scan shows endoleak with crescent-shaped accumulation of contrast material outside confines of endograft lumen but within sac of abdominal aortic aneurysm. **B,** Follow-up CT scan 6 weeks after discharge demonstrates spontaneous sealing of endoleak and no contrast enhancement of AAA sac.

Groin wound healing problems were fairly common after endovascular repair, presumably because of the time these access sites were open and the multiple manipulations performed through them. The problems usually were minor but were judged clinically significant for four patients. Outpatient management was possible for three of these patients, but one patient needed readmission for local dressings and antibiotic therapy. None of these wound problems led to graft exposure or infection.

One patient who underwent endovascular repair had a small discolored area of one toe tip 2 days after the procedure, presumably representing a small thromboembolic event. This event was self-limited and not of clinical importance. No patient had serious thromboembolic complications. No deterioration of renal function occurred among any patient undergoing endovascular repair, either from contrast agent–induced dysfunction, embolic debris, or obstruction of renal arterial flow caused by malpositioning of the endoprosthesis. The average volume of contrast agent administered during endograft insertion was 145 ml of dilute medium, a smaller volume and reduced iodine load than a conventional diagnostic angiogram or CT scan. No signs or symptoms suggestive of colonic ischemia occurred among patients in the study group, although such a complication of endovascular repair has been reported[14] and one patient treated by our group recently and not included in the study series had clinical signs and colonoscopic evidence of colonic ischemia after endograft coverage of a patent inferior mesenteric artery. Fortunately this problem could be managed nonoperatively with intestinal rest and antibiotic therapy.

Endoleaks. A potentially important complication among patients undergoing endovascular repair is failure to totally exclude the AAA from the arterial system. Persistent contrast enhancement of the AAA sac at postdeployment angiography or contrast CT scan has been called *endoleak* by White et al.[20] Such endoleaks were detected at the time of discharge among six (21%) patients. For five of these six patients, it was our judgment that such contrast enhancement represented continued perfusion of the AAA sac by patent branch arteries such as the inferior mesenteric artery or lumbar arteries (branch-to-branch flow) rather than leak of contrast material at either the proximal or distal attachment sites. On follow-up CT scans, three of these six endoleaks had disappeared, presumably representing spontaneous sealing (Fig. 2). However, one endoleak that had sealed spontaneously at 6 weeks was demonstrated on the 1-year follow-up scan. This patient and two other patients with persistent endoleaks have undergone observation for as long as 1 year after endograft placement without development of symptoms or any expansion of AAA size on follow-up CT scans. One

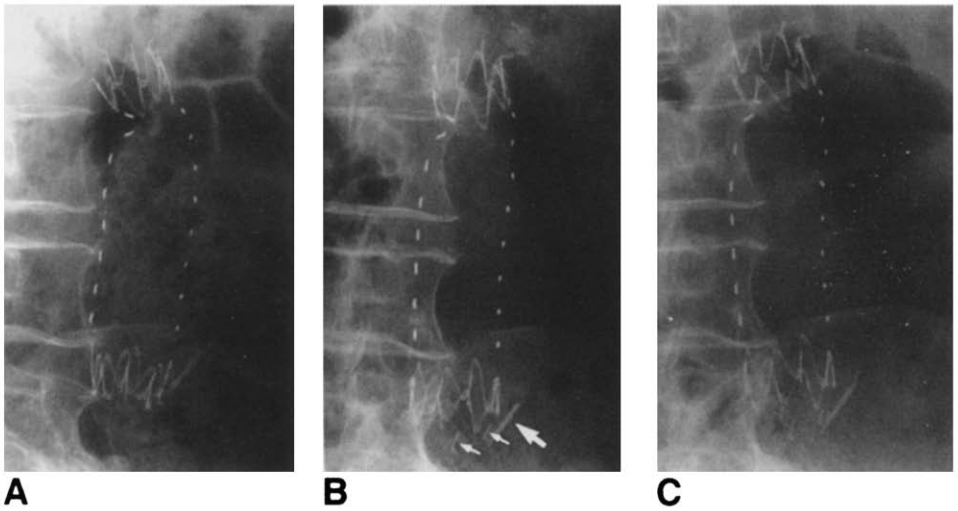

Fig. 3. Serial plain abdominal radiographs suggest probable migration of distal attachment system in patient with AAA rupture 2.5 years after endoluminal repair. **A,** Six-month radiograph. **B,** Two-year radiograph. Two strut fractures are present in the distal attachment frame (*small arrows*) and the attachment system is higher relative to calcified plaque in the distal AAA wall (*large arrow*). **C,** Two and one-half year radiograph 2 weeks before rupture. Attachment system appears further separated from fractured hooks and area of calcification. No contrast leak was evident on CT scan.

patient with a large persistent proximal leak around the attachment system, which occurred after endograft repair of an AAA with a very angulated and technically challenging proximal neck, had acute back pain within 4 weeks of his procedure and had CT evidence of aneurysm expansion without rupture. He underwent urgent surgical conversion and did well.

Late rupture. One patient who underwent apparently successful endovascular repair who had late rupture of the aneurysm merits more detailed description. A tube endograft repair was performed early in the series, October 1994. The patient did well during the ensuing 2 ½ years with no endoleak evident on five follow-up CT scans. The AAA had been documented to diminish in size from 5.0 cm at the time of repair to 3.6 cm in maximal diameter at the 2 ½ year CT scan. Two weeks later, however, he had sudden back and abdominal pain. Emergency abdominal CT at a local hospital suggested a 5 cm AAA with a retroperitoneal hematoma. The patient was transferred to Massachusetts General Hospital and underwent emergency surgical repair. At operation, the distal endograft attachment system was found floating freely in the AAA sac. The proximal attachment system was juxtarenal and securely fixed. Supraceliac clamping allowed suturing of a standard Dacron graft to the proximal body of the prior endograft, which was then anastomosed to the aortic bifurcation to make a composite endovascular–conventional prosthetic tube repair. The patient recovered satisfactorily.

In retrospect, careful review of the patient's serial plain abdominal follow-up radiographs suggested likely migration of the distal attachment system (Fig. 3). Although no endoleak was evident on multiple CT scans, we believe this was likely a harbinger of insecure distal endograft attachment despite the absence of endoleak and speculate that the sudden appearance of a late endoleak reperfused an atretic AAA sac and led to immediate rupture. This was the only instance of endograft device migration in the series. The importance of plain radiographs in follow-up care after insertion of an endograft device was emphasized in the report of May et al.,[21] who described a fairly similar situation.

Change in aneurysm size. In a small group of patients undergoing endovascular repair with adequate follow-up intervals of 1 year or more, there was a mean 1 cm decrease in AAA size. Aneurysm size remained unchanged among the other patients, even the three patients with persistent endoleak. Other patients without changes in aneurysm size were early in their follow-up periods.

DISCUSSION

Conventional operative repair of AAA, with the goal of preventing aneurysm rupture and perhaps prolonging patient survival, is well documented as a very effective and durable method of treatment that can be performed with highly acceptable morbidity and mortality rates at many experienced centers.[22-25] Nonetheless, the risk of operation may be considerably higher (as high as 10%) in community-based reports,[26] and patients at high risk often are denied surgical repair because of presumed hazards of the procedure. In addition, conventional repair represents a considerable expense and drain on hospital resources, and convalescence commonly requires a prolonged period of many months. The possibility that a less invasive method of treatment might reduce risks and achieve cost savings and other patient benefits has tremendous appeal to patients and physicians alike and has generated considerable enthusiasm in the development and use of such devices.

Our data, and that from multiple other reports within the past few years, support the concept that many properly selected patients with AAA can be successfully treated with endoluminal repair, at least in the short- to midterm time frame. The primary determinants of feasibility of endovascular AAA repair are, and will likely continue to be, anatomic features as outlined in Table I. It is not entirely clear what percentage of patients it may be possible to treat successfully with endoluminal methods, but several authors have estimated from anatomic studies that between 30% and 60% of patients with AAA have suitable AAA morphologic features for TPEG repair with currently available devices.[15,16,27-29] In our initial experience, endoluminal repair was possible for less than 10% of patients when only a tube endograft was available, but possible use increased to approximately 50% of patients with aneurysms as bifurcation and tapered aortouniiliac endografts became available. The expanded potential use of endovascular repair is reflected by the fact that an additional 21 patients with AAA have been treated with endovascular stent grafts by our group in the past 5 months alone between the end of the study period and preparation of this report. This brings our total experience to treatment of 57 patients in this way with ongoing results of endoluminal repair similar to those of the initial experience detailed herein.

Aortouniiliac endografts offer perhaps the greatest anatomic flexibility.[4,7,8,14] Further development of modular endografts that allow individualization of each device to meet the wide variety of aortoiliac anatomy and corresponding wide range of length and diameter requirements among individual patients may increase potential use of endovascular repair.[30] Because of somewhat complex patterns of aneurysmal involvement of differing extent in both iliac arteries in many patients, aortouniiliac endografts were the most common endograft configuration in our series. Their utility and the fact that they provide the maximum anatomic flexibility and widest potential application of the method of endovascular repair of AAA have been described in several other series.[4,7,8,14] Although no modular or component endografts were used in our early experience, it seems clear that further development of modular devices that enable use of iliac limbs of differing lengths and calibers will allow greater individualization of each device, better ability to meet the wide variety of anatomic requirements of potential patients, and likely application of endovascular repair to an even higher percentage of patients with AAA.[30]

An even higher percentage of AAA patients with complex anatomy and extensive aneurysmal disease involving both common iliac arteries may be treated with endoluminal techniques if one is willing to exclude both internal iliac arteries. Most groups currently performing endoluminal repair of AAA have avoided this step because of potential consequences of pelvic and colonic ischemia. Marin et al.,[7,31] however, showed that this step often may be taken without serious clinical consequences and can certainly increase potential application of TPEG management.

According to an intent-to-treat analysis, our data indicate that it was possible to treat successfully 23 (77%) of 30 patients by means of endoluminal methods. Included within this clinical success group are four patients with obstruction of lower extremity blood flow who needed additional endovascular interventions. The seven (23%) patients with results judged clinical failures include the two patients who needed immediate conversion to surgical repair because of the iliac arteries presented access problems, the two patients who needed late conversion to open repair (one symptomatic expanding AAA, one late rupture), and three patients with persistent endoleak, even though no symptoms of AAA or size increase occurred. This clinical success rate is within the 75% to 85% range of initial success reported by many groups.[8,10,15,16,32] When persistent endoleaks or other technical complications have been addressed with interventional methods such as additional stent grafts and coil embolization of leak sites, secondary success rates as high as 97% have been described for endoluminal repair.[15]

Our results appear to validate the anticipated potential benefits of successful endovascular management of AAA. Particularly impressive was the marked reduction in mean values for use of an intensive care unit (0.1 versus 1.75 days) and hospital length of stay (3.9 versus 10.3 days) and the much more rapid recovery time (11 versus 47 days) after endovascular repair. These parameters are all reflective of the significantly lower rate of systemic or remote complications among patients treated with the less invasive method. Although the mean hospital length of stay for patients who underwent open surgical repair may seem excessive, this was adversely influenced by the prolonged stays of several patients with particularly severe postoperative systemic complications. Length of stay for the surgical group ranged from 4 to 44 days. Even with elimination of an outlier with length of stay of 44 days due to postoperative respiratory failure, tracheostomy, and prolonged mechanical ventilatory support, mean length of stay was 9.1 days. Such data are in accord with other reported experiences, even in contemporary practice. For example, Muluk et al.[33] found that use of clinical care pathways and case managers at the University of Pittsburgh helped reduce hospital length of stay for surgical repair of AAA from 13.8 to 10.2 days, a hospital stay almost identical to that for our cohort who underwent open surgical repair.

Although the local or vascular variety of periprocedural complications is relatively high after TPEG repair, as noted in series besides ours,[32] such problems often are not as serious as those with open surgical repair. We believe such complications will likely continue to diminish as further technologic advances in endoluminal graft devices occur, as they inevitably will. For example, smaller caliber and more flexible delivery systems will help offset problems in access and reduce potential arterial damage during insertion. Endograft design likely will shift toward devices with an entire endoskeleton of stent support throughout the prosthesis, which will help reduce many of the limb blood flow problems caused by kinking of unsupported endografts that we found in this initial experience. Similar observations regarding need for stenting unsupported endograft limbs that are prone to kinking and obstruction were made by Chuter et al.[11] Although we did not use it, intraoperative intravascular ultrasonography might help in recognition and correction of technical problems related to kinking or twisting of endograft limbs.

The decrease in AAA size documented among our patients with adequate follow-up intervals supports the clinical success of endoluminal grafting. Other reports demonstrated that successful AAA exclusion with TPEG repair results in marked reduction of arterial pressure in the AAA sac[34-36] and a marked decrease in size of the aneurysm on follow-up CT scans.[15,16,37-39] Conversely, prior studies clearly showed that persistent endoleaks are correlated with further AAA expansion and possibly rupture.[11,37,39,40] Indeed, failure to totally exclude the AAA sac from arterial perfusion appears to be one of the principal shortcomings of endoluminal repair in experience reported by all investigators to date; the reported incidence of early endoleak ranges from 10% to 44%.[8-11,15,16,32,41] Our 21% incidence of endoleak at initial discharge falls in the middle of this range. Although as many as 50% of these early endoleaks may seal spontaneously weeks to months after endograft implantation,[10] some of these apparently self-correcting leaks may recur later as seen in our series and others. In our experience, most endoleaks were of the branch-to-branch variety caused by backbleeding into the sac from the inferior mesenteric artery or lumbar vessels. Although it seems intuitively logical that such leaks would likely perfuse the AAA sac at lower pressures than perigraft leaks occurring at the proximal or distal attachment sites and thus be less likely to cause AAA expansion or possible rupture, this phenomenon has not been documented. Surgical experience with exclusion and bypass procedures for popliteal aneurysms or AAA suggests that subsequent aneurysm expansion caused by persistent flow in the excluded sac is quite unusual, although scattered cases of late expansion and even rupture have been described.[42-44] It is our bias often to place multiple endoluminal coils within the AAA sac at the time of endovascular repair to promote intrasacular thrombus and potentially reduce the incidence of persistent endoleak caused by branch flow. Further study is needed to see whether this proves a useful adjunct. It seems fair to conclude that the ultimate fate of many endoleaks remains unknown. Reported experience with the EVT device shows that persistent endoleaks often may continue to be observed without AAA enlargement or other clinical consequences up to 27 months after endovascular repair.[10] However, until more data and experience are available, persistent endoleaks should be regarded as potentially harmful and a failure of endoluminal treatment.

Large endoleaks at either proximal or distal attachment sites appear to be harbingers of poor outcome and likely warrant fairly aggressive reintervention.[32,41] Such a leak led to the need for urgent

conversion 4 weeks after endograft treatment of one of our patients. In some of these situations, successful correction may be achieved with endoluminal reintervention rather than open conversion.[15,32,41]

We believe all TPEG procedures are best performed in an operating room. This belief is based not so much on the possible need for conversion to open repair, which is quite infrequent among properly selected patients, but on the fairly common requirement for adjunctive vascular surgical procedures such as repair of damaged access vessels or construction of a femorofemoral bypass in aortouniiliac endograft implantation, our most common procedure. These procedures are best performed in the sterile, well-equipped, and appropriately staffed environment of an operating room. Although the question of who should perform these procedures remains quite controversial, our perception is that optimal results are best achieved by a team who combines the individual skills and knowledge of both vascular surgeons and interventional radiologists. Treatment is coordinated by one person familiar with vascular disease, its natural history, and all management options.[19,45]

On an intent-to-treat basis, our clinical success rate of 77% and similar data from multiple other reports of endoluminal repair suggest that this method of treatment is not currently as definitive as conventional open operation. However, early results are acceptable, and other benefits of the less-invasive approach are impressive and appealing. The possibility of conventional operative repair is not necessarily precluded, although it may clearly be more difficult or complex if prior endovascular grafting has been performed. These conclusions are reflected in the report by May et al.[46] of a large 4-year experience with TPEG repair. Their data demonstrate that conventional operation remains the most reliable method of AAA repair. However, the safety of endoluminal management was emphasized with the equivalent mortality and complication rates among their two groups even though 44% of patients who underwent endovascular repair had been rejected as unfit for open repair.[46]

We believe these data and the benefits documented in our experience support continued use of endovascular repair, particularly in the treatment of older patients at high risk. As technologic advances occur and endoluminal treatment evolves, and if future studies document acceptable durability of the method, we believe the demonstrated benefits of endovascular repair will justify its use in the care of most patients with appropriate anatomic features.

We gratefully acknowledge the assistance of YuChiao Chang, PhD, Medical Practices Evaluation Center, Massachusetts General Hospital, in statistical analysis, and Karen R. Barbarisi in manuscript preparation.

REFERENCES

1. Parodi JC, Palmaz JC, Barone HD. Transfemoral intraluminal graft implantation for abdominal aortic aneurysms. Ann Vasc Surg 1991;5:491-9.
2. Chuter TAM, Green RM, Ouriel K, Fiore WM, DeWeese JA. Transfemoral endovascular aortic graft placement. J Vasc Surg 1993;18:185-95.
3. Moore WS, Vescera CL. Repair of abdominal aortic aneurysm by transfemoral endovascular graft placement. Ann Surg 1994;220:331-41.
4. May J, White GH, Yu W, Waugh R, Harris JP. Treatment of complex abdominal aortic aneurysms by a combination of endoluminal and extraluminal aortofemoral grafts. J Vasc Surg 1994;19:924-33.
5. White GH, Yu W, May J, Waugh RC, Stephen M. A new non-stented endoluminal graft for straight or bifurcated repair of aneurysms. J Endovasc Surg 1994;1:16-24.
6. Yusuf SW, Baker DM, Chuter TAM, Whitaker SC, Wenham PW, Hopkinson BR. Transfemoral endoluminal repair of abdominal aortic aneurysm with bifurcated graft. Lancet 1994;344:650-1.
7. Marin ML, Veith FJ, Cynamon J, Sanchez LA, Lyon RT, Levine BA, et al. Initial experience with transluminally placed endovascular grafts for the treatment of complex vascular lesions. Ann Surg 1995;222:449-69.
8. Parodi JC. Endovascular repair of abdominal aortic aneurysms and other arterial lesions. J Vasc Surg 1995; 21:549-57.
9. Edwards WH Jr, Naslund TC, Edwards WH Sr, Jenkins JM, McPherson K. Endovascular grafting of abdominal aortic aneurysms: a preliminary study. Ann Surg 1996;223:568-75.
10. Moore WS, Rutherford RB, for the EVT Investigators. Transfemoral endovascular repair of abdominal aortic aneurysm: results of the North American EVT phase I trial. J Vasc Surg 1996;23:543-53.
11. Chuter TAM, Risberg B, Hopkinson BR, Wendt G, Scott AP, Walker PJ, et al. Clinical experience with a bifurcated endovascular graft for abdominal aortic aneurysm repair. J Vasc Surg 1996;24:655-66.
12. Balm R, Eikelboom BC, May J, Bell PRF, Swedenborg J, Collin J. Early experience with trans-femoral endovascular aneurysm management (TEAM) in the treatment of aortic aneurysms. Eur J Vasc Endovasc Surg 1996;11:214-20.
13. White GH, May J, McGahan T, Yu W, Waugh RC, Stephens MS, et al. Historic control comparison of outcome for matched groups of patients undergoing endoluminal versus open repair of abdominal aortic aneurysms. J Vasc Surg 1996;23:201-12.
14. Yusuf SW, Whitaker SC, Chuter TAM, Ivancev K, Baker DM, Gregson RHS, et al. Early results of endovascular aortic aneurysm surgery with aortouniiliac graft, contralateral iliac occlusion and femorofemoral bypass. J Vasc Surg 1997; 25:165-72.
15. Blum U, Voshage G, Lammer J, Beyersdorf F, Tollner D, Kretschmer G, et al. Endoluminal stent-grafts for infrarenal abdominal aortic aneurysms. N Engl J Med 1997;336:13-20.
16. Mialhe C, Amicabile C, Becquemin JP, for the Stentor Retrospective Study Group. Endo-vascular treatment of

infrarenal abdominal aneurysms by the Stentor system: preliminary results of 79 cases. J Vasc Surg 1997;26:199-209.
17. Dake MD, Miller DC, Semba CP, Mitchell RS, Walker PJ, Lindell RP. Transluminal placement of endovascular stent-grafts for the treatment of descending thoracic aortic aneurysms. N Engl J Med 1994;331:1729-34.
18. Ahn SS, Rutherford RB, Johnston KW, May J, Veith FJ, Baker JD, et al. Reporting standards for infrarenal endovascular abdominal aortic aneurysm repair. J Vasc Surg 1997;25:405-10.
19. Veith FJ, Abbott WM, Yao JST, Goldstone J, White RA, Abel D, et al., for the Endovascular Graft Committee. Guidelines for development and use of transluminally placed endovascular prosthetic grafts in the arterial system. J Vasc Surg 1995;21:670-85.
20. White GH, Yu W, May J. "Endoleak": a proposed new terminology to describe incomplete aneurysm exclusion by an endovascular graft. J Endovasc Surg 1996;3:124-5.
21. May J, White GH, Yu W, Sieunarine K. Importance of plain x-ray in endoluminal aortic graft surveillance. Eur J Vasc Endovasc Surg 1997;13:202-6.
22. Ernst CB. Abdominal aortic aneurysm. N Engl J Med 1993;328:1167-73.
23. Johnston KW, Canadian Society for Vascular Surgery Aneurysm Study Group. Nonruptured abdominal aortic aneurysm: six-year follow-up results from the multicenter prospective Canadian aneurysm study. J Vasc Surg 1994;20:163-70.
24. Kazmers A, Jacobs L, Perkins A, Lindenauer SM, Bates E. Abdominal aortic aneurysm repair in Veterans Affairs medical centers. J Vasc Surg 1996;23:191-200.
25. Hallett JW, Marshall DM, Petterson TM, Gray DT, Bower TC, Cherry KJ, et al. Graft-related complications after abdominal aortic aneurysm repair: reassurance from a 36-year population-based experience. J Vasc Surg 1997;25:277-86.
26. Katz DJ, Stanley JC, Zelenock GB. Operative mortality rates for intact and ruptured abdominal aortic aneurysm in Michigan: an eleven-year statewide experience. J Vasc Surg 1994;19:804-17.
27. Chuter TAM, Green RM, Ouriel K, DeWeese JA. Infrarenal aortic aneurysms structure: implications for transfemoral repair. J Vasc Surg 1994;20:44-50.
28. Balm R, Stokking R, Kaatee R, Blankensteijn JD, Eikelboom BC, Van Leeuwen MS. Computed tomographic angiographic imaging of abdominal aortic aneurysms: implications for trans-femoral endovascular aneurysm management. J Vasc Surg 1997;26:231-7.
29. Bayle O, Branchereau A, Rosset E, Guillemot E, Beaurain P, Ferdani M, et al. Morphologic assessment of abdominal aortic aneurysms by spiral computed tomographic scanning. J Vasc Surg 1997;26:238-46.
30. Armon MP, Yusuf SW, Whitaker SC, Gregson RHS, Wenham PW, Hopkinson BR. The anatomy of abdominal aortic aneurysms: implications for sizing of endovascular grafts. Eur J Vasc Endovasc Surg 1997;13:398-402.
31. Marin ML, Veith FJ, Cynamon J, Wain RA, Sanchez LA, Ohki T, et al. Intentional iliac artery occlusion to facilitate endovascular repair of aortoiliac aneurysms and occlusions. Am J Surg. In press.
32. May J, White GH, Yu W, Waugh RC, Stephens MS, McGahan T, et al. Surgical management of complications following endoluminal grafting of abdominal aortic aneurysms. Eur J Vasc Endovasc Surg 1995;10:51-9.
33. Muluk SC, Painter L, Sile S, Rhee RY, Makaroun MS, Steed DL, et al. Utility of clinical pathway and prospective case management to achieve cost and hospital stay reduction for aortic aneurysm surgery at a tertiary care hospital. J Vasc Surg 1997;25:84-93.
34. Chuter T, Ivancev K, Malina M, Resch T, Brunkwall J, Lindblad B, et al. Aneurysm pressure following endovascular exclusion. Eur J Vasc Endovasc Surg 1997;13:85-7.
35. Marston WA, Criado E, Baird CA, Keagy BA. Reduction of aneurysm pressure and wall stress after endovascular repair of an abdominal aortic aneurysm in a canine model. Ann Vasc Surg 1996;10:166-73.
36. Sanchez LA, Faries PL, Marin ML, Ohki T, Parsons RE, Marty B, et al. Chronic intra-aneurysmal pressure measurement: an experimental method for evaluating the effectiveness of endovascular aortic aneurysm exclusion. J Vasc Surg 1997;26:222-30.
37. Matsumura JS, Pearce WA, McCarthy WJ, Yao JST, for the EVT Investigators. Reduction in aortic aneurysm size: early results after endovascular graft placement. J Vasc Surg 1997;25:113-23.
38. White RA, Denayre CE, Walot I, Kopchok GE, Wilson EP, deVirgilio C. Regression of an abdominal aortic aneurysm after endograft exclusion. J Vasc Surg 1997;26:133-7.
39. May J, White G, Yu W, Stephen M, Harris J. A prospective study of anatomico-pathological changes in abdominal aortic aneurysms following endoluminal repair: is the aneurysmal process reversed? Eur J Vasc Endovasc Surg 1996;12:11-7.
40. Lumsden AB, Allen RC, Chaikof EL, Resnikoff M, Moritz MW, Gerhard H, et al. Delayed rupture of aortic aneurysms following endovascular stent grafting. Am J Surg 1995; 170:174-8.
41. White GH, Yu W, May J, Chanfour X, Stephen MS. Endoleak as a complication of endoluminal grafting of abdominal aortic aneurysms: classification, incidence, diagnosis and management. J Endovasc Surg 1997;4:152-68.
42. Shah DM, Chaug BB, Paty PSK, Kaufman JL, Koslow AR, Leather RP. Treatment of abdominal aortic aneurysm by exclusion and bypass: an analysis of outcome. J Vasc Surg 1991;13:15-20.
43. Blumenberg RM, Skudder PA Jr, Gelfand ML, Bowers CA, Barton EA. Retroperitoneal nonresective staple exclusion of abdominal aortic aneurysms: clinical outcome and fate of the excluded abdominal aortic aneurysms. J Vasc Surg 1995;21:623-34.
44. Paty PSK, Darling RC III, Chang BB, Shah DM, Leather RP. A prospective randomized study comparing exclusion technique and endo-aneurysmorrhapy for treatment of infrarenal aortic aneurysm. J Vasc Surg 1997;25:442-5.
45. Veith FJ. Presidential address: transluminally placed endovascular stented grafts and their impact on vascular surgery. J Vasc Surg 1994;20:855-60.
46. May J, White GH, Yu W, Ly CN, Waugh RC, Stephen MS, et al. Concurrent comparison of endoluminal versus open repair in the treatment of abdominal aortic aneurysms: analysis of 303 patients by life-table method. J Vasc Surg 1998; 27:213-21.

Submitted Sep. 22, 1997; accepted Dec. 3, 1997.

DISCUSSION

Dr. Robert M. Zwolak (Lebanon, N.H.). This was a superb presentation on a most timely clinical issue that affects vascular surgery today. It is a brand new world. Terms like "drop zone" and "full deployment" have left their rightful home in the pages of a Tom Clancy novel to land in the vascular operating suite. Dr. Brewster has shown that 50% of aortic aneurysms may now be treated endovascularly relying on an ever-expanding array of tube grafts, bifurcated grafts, component grafts, and increasingly intelligent guide wires. The overall short-term results in both groups are excellent. There were no deaths in 60 patients, a minimal blood loss, and short hospital stays. This reflects state-of-the-art vascular surgery. However, there are still more questions than answers, and I would like to pose a few of these to Dr. Brewster.

Postoperative kinking of graft limbs in three patients must have been a frustrating problem because the patients left the operating room with normal distal pulses. Have the technical issues surrounding that problem been resolved? Why should the grafts reposition themselves so much as to thrombose an iliac limb? On the basis of less than perfect patency of femorofemoral crossover grafts, the combination of the aortouniiliac graft in addition to a femorofemoral crossover graft remains uninspiring to me. What kind of patient deserves this procedure instead of an open aortic reconstruction? What about these endoleaks? Three of 28 patients (11%) who were successfully engrafted had persistent endoleaks. Those few patients with persistent endoleaks comprise our most frustrating subset at Dartmouth. A patient of Dr. Brewster's cohort had an endoleak and experienced aneurysm expansion that required semiurgent operative repair. Have you decided on a therapeutic algorithm regarding when to intervene on these patients with endoleaks?

Your manuscript also speaks of a tendency to place multiple endoluminal coils within the aneurysm sac at the time of endovascular repair to promote intravascular thrombus and potentially reduce the incidence of persistent endoleak. I am not familiar with this. Can you tell exactly how you accomplished that and whether you have evidence that it is doing what you had hoped? What about cost considerations? Saving a day in an intensive care unit and almost a week in the hospital may represent a cash savings in excess of $10,000 per patient. However, the devices are vastly more expensive than the traditional aortic prosthesis, and the savings will dwindle if some or perhaps even all of the patients need to be followed-up at regular intervals with computed tomography scan for years after surgery.

In view of your patient who ruptured 2.5 years after surgery—in fact, I think this was a patient who did not have an early endoleak—will all patients need to be followed-up for years with computed tomography scans? At what point do you break even on the savings that you have from reduced hospitalizations being spent on outpatient computed tomography scans? From a medical standpoint, do endovascular aneurysm repairs actually prevent aortic aneurysm rupture? With an 11-month follow-up on average and a natural history risk somewhere in the range of 5% to 8%, we would have expected that 1 or 2 of your 30 patients would rupture if unrepaired. You had one rupture with an endovascular repair in place. We were told by Dr. Parodi about six other patients who ruptured their aneurysms after endovascular repair. Do we know yet that this technology has a truly beneficial impact on preventing aneurysm rupture? If so, where does it stand between the natural history curve and the established track record of traditional surgical repair?

Finally, because this technology seems to be here to stay, which surgeons will be performing endovascular aneurysm repairs 5 or 7 years from now? Right now, this appears to be limited to a few highly technical centers that are performing a substantial number. When I watch or help with these procedures, it seems that endovascular gadgetry is incredibly complex and sophisticated. C-arm requirements are mandatory. Will this limit the number of surgeons actually repairing aneurysms? Will the community-based surgeon ever perform endovascular aneurysm repair? Now that we know it is probably here to stay, what does your crystal ball tell us about endovascular aneurysm repair in the year 2002?

Dr. David C. Brewster. You have obviously raised some timely and thorny issues that I will not be able to answer entirely.

In regard to the problems related to kinking of endograft limbs, this was indeed frustrating. The endografts that we were using were mostly EndoVascular Technologies endografts, which are unsupported. It is increasingly clear to most investigators that future devices should have a full endoskeleton or stent framework support of the entire endoluminal conduit to minimize such kinking issues. I think that will be an important technologic advance. Because we are only in the early developmental phases of such rapidly evolving endoluminal therapy, we are sure to see other technologic advances that will certainly reduce complexity of the procedures, decrease local vascular complications, and lead to even better outcome results. Many of your other questions relate to the need for further long-term follow-up to confirm durability. Obviously, we do not have this information yet.

The femorofemoral component of a treatment strategy employing aortouniiliac grafts and contralateral iliac occlusion might be considered a "weak link". However, femorofemoral grafts have generally had good long-term durability, especially in patients without significant occlusive disease. Thus, I think such procedures remain useful, especially in elderly high-risk patients with difficult iliac artery anatomy or extensive aneurysmal disease. This method of treatment will certainly extend ability to treat a greater number of patients with aneurysms by means of endoluminal techniques.

As I tried to emphasize in my report, endoleaks remain a significant concern. The EndoVascular Technologies trial, which now has follow-up for up to 3 years in some patients, frequently observes these problems, and their natural history has been rather benign. However, other investigators are beginning to realize that some endoleaks, particularly those at an attachment site, perhaps have a much more ominous implication. I think that it is best to restudy and perhaps reintervene at an earlier interval on such patients. In addition, it is important to emphasize that reintervention does not necessarily have to be surgical intervention. In many instances, further endoluminal treatments—balloon dilatation of the stent attachments, deployment of additional segmental endograft, and so forth—can often take care of these problems.

The endoluminal coiling that we have done within the aneurysm sac is designed to promote thrombosis. This is a method that is used in many other instances by our interventional radiology colleagues. We have not proven that it enhances thrombosis of the sac, but it seems a logical step to help with the problem of back bleeding from lumbar or inferior mesenteric artery branches into abdominal aortic aneurysm sac, which, in our experience, is the source of at least one half of the endoleaks.

Finally, your questions about cost are important. You are right that these endografts at the moment are rather expensive. This somewhat offsets the savings from intensive care units and hospital stays. We simply do not know yet whether this is a cost effective treatment or not. I think that you are right that further analysis in this regard is necessary.